

Biomechanics of the upper cervical spine ligaments in axial rotation and flexion-extension: Considerations into the clinical framework

ABSTRACT

Context: The motion of the upper cervical spine (UCS) has a great interest for analyzing the biomechanical features of this joint complex, especially in case of instability. Although investigators have analyzed numerous kinematics and musculoskeletal characteristics, there are still little data available regarding several suboccipital ligaments such as occipito-atlantal, atlantoaxial, and cruciform ligaments.

Objective: The aim of this study is to quantify the length and moment arm magnitudes of suboccipital ligaments and to integrate data into specific 3D-model, including musculoskeletal and motion representation.

Materials and Methods: Based on a recent method, suboccipital ligaments were identified using UCS anatomical modeling. Biomechanical characteristics of these anatomical structures were assessed for sagittal and transversal displacements regarding length and moment arm alterations.

Results: Outcomes data indicated length alterations >25% for occipito-atlantal, atlanto-axial and apical ligaments. The length alteration of unique ligaments was negligible. Length variation was dependent on the motion direction considered. Regarding moment arm, larger magnitudes were observed for posterior ligaments, and consistent alteration was depicted for these structures.

Conclusion: These outcomes supply relevant biomechanical characteristics of the UCS ligaments in flexion-extension and axial rotation by quantifying length and moment arm magnitude. Moreover, 3D anatomical modeling and motion representation can help in the process of understanding of musculoskeletal behaviors of the craniovertebral junction.

Keywords: Ligament biomechanics, moment arm, musculoskeletal modeling, spinal motion, upper cervical spine

INTRODUCTION

The upper cervical spine (UCS) represents the most flexible vertebral complex of the remaining cervical spine. Regarding the total cervical motion ranges (ROM), approximately 40% of flexion-extension and 60% of axial rotation occur at the UCS.^[1] The major function of the UCS is the completion of motion patterns to compensate/adjust the motion components occurring at the lower cervical segments. Suboccipital ligaments such as alar ligaments (ALs), transverse ligament, and tectorial membrane (TM) have been demonstrated to play an essential function in the stability of the UCS.^[2-5] However, much less is known about the biomechanical properties of

**BENOÎT BEYER^{1,2}, VÉRONIQUE FEIPEL^{1,2},
PIERRE-MICHEL DUGAILLY^{1,3}**

¹Department of Physiotherapy and Rehabilitation, Faculty of Motor Sciences, Laboratory of Functional Anatomy, Université Libre de Bruxelles, ²Department of Anatomy, Faculty of Medicine, Laboratory of Anatomy, Biomechanics and Organogenesis, Université Libre de Bruxelles, Brussels, Belgium, ³Department of Osteopathy, CESPU - Escola Superior de Saúde do Vale do Ave, Famalicão, Portugal

Address for correspondence: Prof. Pierre-Michel Dugailly, Laboratory of Functional Anatomy, G1.1.104/G2.1.213 (CP619), Université Libre de Bruxelles, 808 route de Lennik, 1070 Bruxelles, Belgium.
E-mail: pdugail@gmail.com

Submitted: 01-Jun-20
Published: 14-Aug-20

Accepted: 26-Jun-20

Video available on: www.jcvjs.com

Access this article online

Website:

www.jcvjs.com

DOI:

10.4103/jcvjs.JCVJS_78_20

Quick Response Code



This is an open access journal, and articles are distributed under the terms of the Creative Commons Attribution-NonCommercial-ShareAlike 4.0 License, which allows others to remix, tweak, and build upon the work non-commercially, as long as appropriate credit is given and the new creations are licensed under the identical terms.

For reprints contact: WKHLRPMedknow_reprints@wolterskluwer.com

How to cite this article: Beyer B, Feipel V, Dugailly PM. Biomechanics of the upper cervical spine ligaments in axial rotation and flexion-extension: Considerations into the clinical framework. *J Craniovert Jun Spine* 2020;11:217-25.

apical, occipito-atlantal, and atlantoaxial ligaments during sagittal and transversal cervical motions.^[4] Instability of the UCS is generally related to various clinical and anatomical conditions^[6,7] that may occur during specific motion directions.^[4,8,9] Ligamentous injuries have been stressed for compromising upper spine stability^[4,10] that may occasionally induce medullar and vascular diseases.^[11,12]

In clinical practice, various procedures are described to screen the UCS function (i.e. hypomobility, instability) before manual therapeutic management.^[13-15] Concerning instability tests, the value of the latter is usually supported by clinical criteria and specific biomechanical *in-vitro* investigations. Interestingly, several UCS tests are defined to detect atlantoaxial instability with moderate to substantial sensitivity and specificity,^[16] and clinical consistency is partly established for some of those tests^[17,18] However, the clinical test did not seem to correlate with imaging findings.^[19]

On the other hand, the biomechanical function of a ligament is dependent on its moment arm, which represents the distance from the ligament's line of action to the joint's axis of rotation. This mechanism is not only necessary to understand how important is the moment generated but also to appraise what may be the potential ligament's loading during joint motion. In summary, for a constant force, the smaller in the moment arm, the lower is the ligament's loading and the moment generated, and vice versa. There are little data regarding the function of the suboccipital ligaments during UCS flexion-extension and axial rotation motions involving length and moment arm. Hence, a better understanding of these biomechanical features may provide insight into how the latter relates to cervical motion direction. Furthermore, from a clinical point of view, it should be noteworthy for the practitioner to understand how suboccipital ligaments may be involved during UCS motion and clinical testing.

The aim of this study is to appraise the suboccipital ligaments function based on length and moment arm changes during UCS flexion-extension and axial rotation.

MATERIALS AND METHODS

Study design

The present investigation was conducted according to an early *in vitro* study consisting of assessing 3D kinematics of the UCS.^[20] The same experimental design combining 3D motion data and musculoskeletal anatomical modeling was used to process eight anatomical specimens for flexion-extension (FE) and axial rotation (AR) motions. Details about the whole experimental set-up and protocol validation can be found elsewhere.^[21,22]

Kinematics data collection

Kinematics was analyzed from five sagittal UCS positions (from neutral to intermediate and maximal range in flexion, extension, and axial rotation directions). The output of discrete joint displacements was carried out according to a usual mathematical method for processing motion computation.^[23] The latter consists of lateral bending, axial rotation, and flexion-extension motion components provided from the decomposition of the helical axis rotation into helical angles around the axes of the anatomical reference system.^[20] To express the global motion range, norm vector computation from XYZ components, i.e., the helical rotation was computed with respect to each UCS level.^[22]

In addition, the mean helical axis (MHA) was computed^[24] for each UCS level in a local reference system (i.e. C_1 for C_0-C_1 ; C_2 and for C_0-C_2 or C_1-C_2). Data were integrated into a subject-specific 3D-model and provided anatomical motion representation using customized software.^[25]

Ligament data collections

Ten ligaments were identified on each specific 3D anatomical model using virtual palpation.^[26] Spatial coordinates of insertion sites were computed for the following structures: anterior and posterior atlantoaxial ligaments (AAA; AAP), AL, anterior and posterior occipito-atlantal ligaments (OAMA; OAMP), TM, transverse ligament (TR), apical ligament (APIC) and cruciform ligament inferior (XI) and superior (XS) pars. Note that, left and right portions were considered for the transverse ligament with respect to the posterior aspect of the dens of C_2 .^[27]

Besides, each ligament was computed considering a straight line running between the attachment sites. Therefore, no wrapping around bony structures or other anatomical elements was taken into account [Figure 1a-c]. For each UCS pose, instantaneous ligament length was computed [Figure 1].

Moment arm computation was based on the direct method for calculating lever arms, i.e., the perpendicular distance between the helical axis (e.g. MHA) and the action line vector of ligaments.^[28] Figure 2a and b represents 3D anatomical models, including ALs and their respective moment arms during axial rotation.

The virtual palpation procedure was repeated three times to estimate the reliability of the method and the error propagation on the resulting data.

Statistical analysis

Descriptive statistics (i.e., mean and standard deviation) were performed for each ligament length and moment arm during

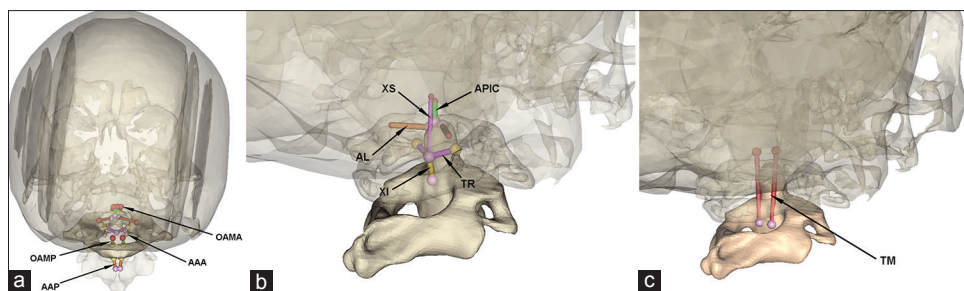


Figure 1: 3D models of C0-C1 and C2 vertebra and corresponding upper cervical spine ligament attachment sites displayed by colored anatomical landmarks and lines. (a) Posterior view with respect to OAMA, OAMP, AAA and AAP. (b) Back three-quarter view of the upper cervical spine with respect to XS, XI, APIC and TR. (c) Back three-quarter view of the upper cervical spine with respect to tectorial membrane: between C0 and C2

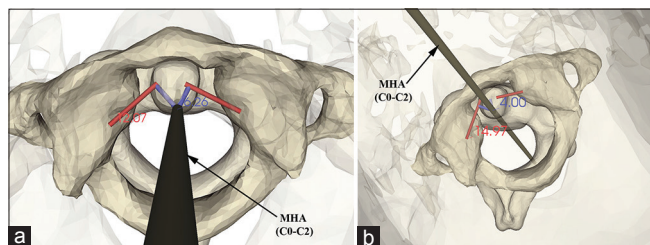


Figure 2: 3D representation of alar ligaments (in red) with respect to the mean helical axis of C0 relative to C2 during axial rotation. The moment arm is displayed in blue as the shortest distance from the line of action of the alar ligament to the axis of rotation

both AR and FE movements. Analysis of variance (ANOVA) for repeated measurements was applied to evaluate the influence of the following factors: laterality (left and right) and joint position (5 positions as described above for both sagittal and transverse plane). Values of $P < 0.05$ were considered statistically significant. When ANOVA demonstrated a significant effect, the Bonferroni *post-hoc* test was then conducted to determine which side and positions affect significantly length or lever arm measure. In addition, to simplify results, significant differences were expressed relative to the length or lever arm values in neutral position (NP).

RESULTS

Data reliability

Reliability of palpation following repetitive identification of attachment sites demonstrated an average RMS error (all landmarks) of 1.3 mm and a related ligament length error of 1.1 mm in average with a maximal value of 2.4 mm. The propagation of palpation error on moment arm computation was estimated to 0.7 mm on average with maximal values of 1.5 mm and 2.3 mm for axial rotation and flexion-extension, respectively.

Kinematics data

Average helical rotations are found in Table 1. Ranges of motion (ROM) are given for segmental (C_0-C_1 and C_1-C_2) and regional (C_0-C_2) displacements regarding middle and maximal UCS positions.

Table 1: Average segmental range of motion in degree (standard deviation) regarding to flexion, extension and axial rotation at intermediate (middle) and maximal range

	C_0-C_1	C_1-C_2	C_0-C_2
Flexion			
Middle	5.8 (3.2)	4.4 (3.8)	9.7 (3.1)
Maximal	11.0 (3.9)	6.3 (4.9)	15.4 (7.4)
Extension			
Middle	4.1 (1.5)	3.6 (2.9)	10.8 (5.6)
Maximal	8.3 (3.8)	7.6 (3.5)	19.2 (5.7)
Axial rotation			
Left			
Middle	1.1 (0.9)	15.2 (3.1)	16.8 (3.9)
Maximal	2.1 (1.8)	24.8 (3.7)	27.6 (5.0)
Right			
Middle	1.5 (0.9)	13.0 (8.3)	15.9 (6.4)
Maximal	4.0 (1.6)	25.0 (7.6)	27.7 (8.7)

Ligaments data in flexion extension

Descriptive data are presented relative to length values obtained in NP in Table 2. Ligaments' length ranged between 5.5 and 30.8 mm regarding the NP.

Length and moment arm magnitudes are illustrated graphically with respect to UCS poses in Figure 3. ANOVA demonstrated a significant effect of FE ($P < 0.001$) on ligament length and moment arm with an exception for TR and XI.

Bonferroni *post hoc* test indicated when ligament displayed significant length and moment arm alterations relative to NP [Figure 3].

In general, as UCS moved from flexion to extension length, ligament increased for AAA, AL, OAMA, APIC, XS, and TM and decreased for AAP, OAMP. The remaining ligaments (TR, XI, XS) displayed nonsignificant length variations.

For several structures, significant length variation was related to one motion direction only when compared to the NP (e.g. AAP only in flexion while XS only in extension).

Table 2: Relative length of each ligament during flexion-extension and both ipsi/contralateral axial rotation with respective length in neutral position

	Absolute length in NP (mm)		Relative length at maximal motion range			
	Mean	SD	Extension		Flexion	
			Mean	SD	Mean	SD
AAA	7.9	1.8	1.11	0.12	0.83	0.13
AAP	6.1	2.6	0.76	0.27	1.61	0.40
AL	9.2	3.5	1.06	0.19	0.84	0.12
OAMA	8.8	2.9	1.23	0.17	0.93	0.08
OAMP	12.3	1.7	0.58	0.15	1.23	0.06
TM	29.8	2.6	1.08	0.03	0.96	0.02
TR	10.1	2	1.02	0.04	1.02	0.05
APIC	5.5	2.1	1.50	0.34	1.00	0.28
XI	6.9	1.4	1.00	0.01	1.00	0.01
XS	18.8	1.7	1.11	0.05	0.96	0.03
	Mean	SD	Ipsilateral AR		Contralateral AR	
			Mean	SD	Mean	SD
AAA	9.3	2.9	0.77	0.17	1.31	0.14
AAP	11.7	2.2	2.13	1.02	2.91	0.91
AL	10.1	3.9	1.20	0.17	0.75	0.20
OAMA	11.0	6.1	1.02	0.06	1.08	0.10
OAMP	13.5	6.1	0.95	0.06	0.90	0.05
TM	30.8	2.7	0.98	0.01	1.01	0.01
TR	10.5	2.7	0.83	0.09	1.16	0.12
APIC	6.2	2.8	1.04	0.20	1.04	0.20
XI	7.0	8.2	0.99	0.01	1.00	0.01
XS	19.6	2.2	0.99	0.02	0.99	0.02

Values are presented as mean and standard deviation in millimetre unit – abbreviations are detailed in text. SD - Standard deviation, NP - Neutral position, AL - Alar ligament, TM - Tectorial membrane, TR - Transverse ligament, APIC - Apical ligament, XI - Cruciform ligament inferior, XS - Cruciform ligament superior, AR - Axial rotation, AAA - Anterior atlantoaxial ligament, AAP - Posterior atlantoaxial ligament, OAMA - Anterior occipito-atlantal ligament, OAMP - Posterior occipito-atlantal ligament

Considering the entire FE ROM, length alteration was >25% for AAA, AAP, OAMA, OAMP, and APIC, while other ligaments displayed lower variations [Table 2].

Regarding moment arm, larger magnitudes were observed for the posterior ligaments such as AAP and OAMP and a greater moment arm variation was found for OAMP.

Post hoc test indicated that significant alterations were found for OAMA, OAMP, and TM only when compared to NP [Figure 3].

Ligaments data in axial rotation

Relative length data are depicted in Table 2 for maximal axial rotation. Figure 4 reports length and moment arm average outcomes relative to each AR pose. Regardless of the UCS motion direction, there was no significant difference between the left and right data for both length and moment arm ($P > 0.05$). Considering the overall AR range (right and left) AAA, AAP and AL ligaments displayed the largest length

changes. Significant length alterations relative to the NP are displayed in Figure 4 ($P < 0.05$).

Regarding the moment arm, there was a significant effect of the UCS axial rotation on data magnitude (ANOVA, $P < 0.05$). *Post hoc* test demonstrated significant moment arm changes relative to NP [Figure 4].

AAP displayed the larger moment arm magnitude and variation compared to the other ligaments, with increasing values in both motion directions. In contrast, AAA showed a significant decrease of moment arm only in maximal ipsilateral rotation. Regarding TR, moment arm is significantly increased in maximal ipsilateral axial rotation and decreased in maximal contralateral rotation.

DISCUSSION

The main objectives of this study were to explore UCS ligaments length and moment arm for FE and AR using 3D modeling approach and to provide a quantitative and qualitative description of such ligaments behaviors.

The reliability of 3D attachment identification using a virtual palpation method showed a root mean square error of 1.3 mm on average. This magnitude is comparable to previous studies based on instrumental^[20] and virtual palpation.^[24,29] In addition, propagation of such palpation error on length and moment arm magnitudes demonstrated average RMS of 1.1 mm and 0.7 mm, respectively. These values are somewhat low in consideration of the most moment arm magnitudes, although the shorter is the moment arm; the greater is its relative variation.

In NP, ligaments length obtained in the present work are in line with previous studies for alar,^[3,30-32] transverse^[33,34] and apical ligaments^[35] while the remaining ligaments are not yet quantified on this subject.

The main findings of this study suggest that suboccipital ligaments, other than alar and transverse ligaments, may play a substantial role in the function of the UCS in FE and AR. Indeed, length variations larger to 20% were observed for AAP, OAMA, OAMP, and APIC in FE and for AAA, AAP, and AL in AR. Regarding moment arm, consistent variations were also demonstrated for OAMP, TM, and OAMA in FE and for AAA and AAP in AR.

UCS is a large flexible area that may represent an increased risk for ligament, neurological, and vascular impairments.^[36,37] Suboccipital ligaments are associated with the mechanical stabilization of the UCS segments, mainly in the sagittal^[4,32,34] and in the transversal planes.^[8,38,39] More precisely, AL injuries are commonly reported with rotation attitude of the neck, whereas transverse ligament and posterior

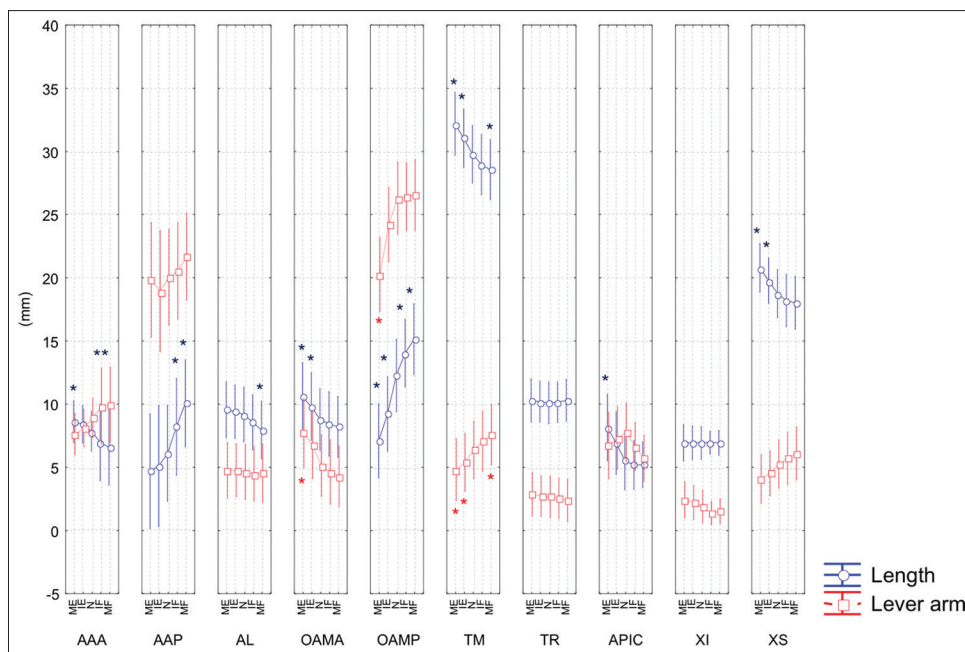


Figure 3: Length (in blue) and lever arm (in red) in millimeter of each ligament as function of upper cervical spine position from maximal extension to maximal flexion. Asterisks represent significant difference relative to the neutral position. Further details are described in the result section

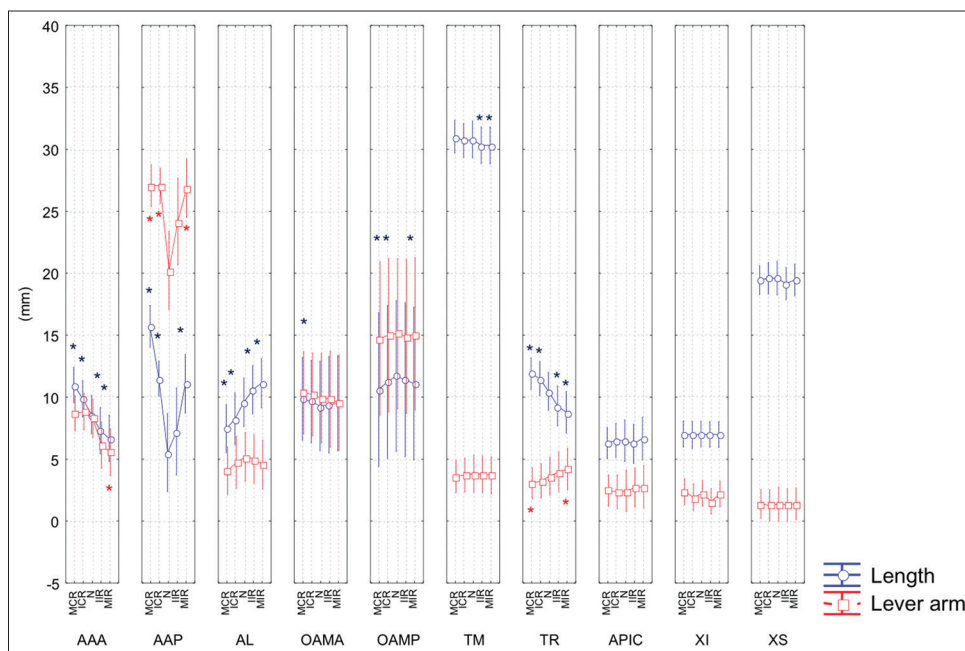


Figure 4: Length (in blue) and lever arm (in red) in millimeter of each ligament as function of upper cervical spine position from maximal contralateral rotation to maximal ipsilateral rotation. Asterisks represent significant difference relative to the neutral position. Further details are described in the result section

atlanto-occipital membrane are more affected during frontal collisions.^[33] Previous studies using radiological and finite element modeling approach have shown that additional structures such as the TM and the apical ligament may be also compromised during frontal and rear head impact.^[37,40]

Our outcomes provide additional information for occipito-atlantal and atlanto-axial membranes (i.e. AAA,

AAP, OAMP, OAMA in the present study) while the literature on these specific ligaments is sparse, probably due to the anatomical complexity and the presence of connective tissue bridges with other structures.^[8] A more complete analysis of ligaments contribution in AR and FE, as described in the present study, may represent substantial data for UCS modeling of various clinical conditions.

In clinical practice, several manual procedures (i.e. mobilization, manipulation) have been considered with regard to UCS musculoskeletal conditions.^[41-44] Furthermore, complications have been reported following cervical manual applications, resulting in various injury patterns.^[45] However, potential risk related to how biomechanical characteristics of ligaments, such as length and moment arm alterations, may be affected during physiological motion remains unclear, and the present descriptions partly fill this gap of knowledge.

Length alteration of UCS ligaments would be accounted as a substantial factor during the clinical examination as well as the therapeutic procedure such as manual mobilization or posttraumatic immobilization positioning of the UCS. Interestingly, our results [Table 3] suggest that length increase occurred more likely in axial rotation (in both directions) for AAP, from ipsi-to contra-lateral rotation for AAA and from contra-to ipsi-lateral rotation for AL. For sagittal motion, length increases from extension to flexion for OAMP, AAP and TR, and in the opposite direction for AAA, AL, TM, and OAMA.

As summarized in Table 3, the most ligaments could be stressed during extension with an exception for the posterior ligaments. Inversely, most ligaments are shortened in flexion that may lead to an increase of intrinsic UCS instability in the anterior part. Consequently, it confirms that neutral or slightly flexed posture may be suggested as a satisfactory strategy to decrease UCS ligament strain when neck immobilization is required after trauma.^[46]

Regarding AR, only anterior atlantoaxial and AL length is increased for contralateral and ipsilateral displacements, respectively. Note that posterior atlantoaxial ligament is lengthened in both motion directions that may suggest its multidimensional involvement during AR. As depicted in the supplementary material, the 3D anatomical model enables visualization of both alar ligaments length and moment arm during AR [Video 1].

Moment arm magnitude reflects the mechanical advantage of the suboccipital structure about the corresponding UCS level and is subsequently related to the contribution to UCS stability. Our results suggest a significant involvement of AAP and OAMP since similar or larger magnitude is displayed compared to alar or apical structures (AL, APIC). These data support the biomechanical function of AAP and OAMP and their propensity to maintain the sagittal or rotational stability of the UCS complex.^[32,34] Interestingly, moment arm changes are mainly observed in maximal extension for OAMP, meaning that small modification occurred around the NP. These

Table 3: Ligaments testing related to upper cervical spine motion directions

	Flexion	Extension	Ipsi AR	Hetero AR
AAA	–	+	–	+
AAP	+	–	+	+
AL ^(#)	–	+	+	–
OAMA	–	+		NA
OAMP	+	–	–	–
TM	–	+		
TR		NA	–	+
APIC	–	+		NA
XI		NA		NA
XS	–	+		NA

+ and – correspond to lengthening and shortening, respectively. NA means that alteration is negligible. Supplementary material (#) enables visualization of such phenomenon for alar ligaments. AL - Alar ligament, TM - Tectorial membrane, TR - Transverse ligament, APIC - Apical ligament, XI - Cruciform ligament inferior, XS - Cruciform ligament superior, AR - Acoustic reflex, NA - Not available, AAA - Anterior atlantoaxial ligament, AAP - Posterior atlantoaxial ligament, OAMA - Anterior occipito-atlantal ligament, OAMP - Posterior occipito-atlantal ligament

outcomes are consistent with the procedure commonly used during cervical spinal immobilization after trauma.^[47]

In contrast, apical, cruciform, alar, and transverse ligaments displayed a small moment arm. This may predict a limited role and small loading of these structures during sagittal UCS motion. However, despite a reduced moment arm, TM limits the anterior motion of the atlas by ensuring coaptation between the dens and the anterior arch of atlas and subsequently restrains the flexion motion range.^[30,34,35]

Consideration into the clinical framework

In the current study, the moment arm was computed challenging the knowledge of additional biomechanical characteristics of UCS ligaments. Indeed, this parameter is involved both in ligament strain and the resulting ligament moment.^[48] Therefore, a small increase of ligament moment arm may have substantial modifications on an articular joint and its surrounding structures. Subsequently, ligaments that displayed an increase of length and moment arm simultaneously during motion are more likely to be involved during large ROM as observed for OAMP in maximal flexion or for AAP in maximal axial rotation. On the opposite, shortened ligament and poor moment arm may represent a lower stabilizing capacity but, conversely, a lower degree of vulnerability to strain. This latter aspect may be useful for preventing ligament strain during various therapeutic applications such as surgical procedure^[49] or manual approaches of UCS (i.e., passive mobilization or clinical testing).^[15,50]

Indeed, based on our protocol, we may not extrapolate this hypothesis to active motion knowing the muscle capacity to

stabilize the cervical spine.^[9] Moreover, the specific material properties of UCS ligament was not considered in the present work.^[51]

In general, three patterns of length and moment arms variations could be categorized for sagittal motion [Table 4]. A first category is represented with both negligible length and moment arm variations (i.e., OAMA and OAMP in AR). A second category is defined when the simultaneous length and moment arm variation of an identical sign occurred (i.e., AAP in both AR and FE), and a third category, for which length and moment arm variations with an opposite sign are observed (i.e., TM in FE).

On the other hand, the representation of ligaments biomechanical features by anatomical modeling may be of great interest to enhance education and skills in functional anatomy and manual procedures through the use of various qualitative and quantitative feedback processes.^[52,53]

Limitations

There are certainly several limitations to this study. First, our method considered the linear distance between attachment sites, which is not specifically corresponding to the real length of the ligament. Indeed, wrapping has been described for the ALs in relation to the dens of the axis^[54] as for some UCS muscles at maximal motion range.^[55,56] Thus, further consideration of this latter aspect may be necessary to take into account several structures. In addition, in a particular position (i.e., NP), some structures may be untightened or lax,^[31] and therefore, potential vulnerability to strain would be limited.

Second, the biomechanical analysis was limited to discrete UCS positions, while specific 3D behavior may occur during continuous motion or combined motions such as during the clinical tests. Moreover, movement speed or acceleration was not taken into account in the present work. Therefore, *in vivo* behavior could differ from the present observations. Furthermore, our motion data remained under physiological

motion ranges, and thus, extreme ranges were not investigated.

Finally, although our motion and length data were similar to previous studies, our results obtained in unloaded spine specimens may not be generalized to loading conditions^[9,57] such as during active motion.^[58]

CONCLUSION

The present study is the first comprehensive description of UCS ligaments function involving their length and moment arm characteristics during flexion-extension and axial rotation motion. These outcomes provide extended musculoskeletal data showing that UCS ligaments exhibited various biomechanical patterns that might be integrated to earlier data to improve understanding of functional anatomy and specialized clinical procedures (i.e. techniques, clinical tests).

In addition, using a specific 3D-model, including musculoskeletal and motion representation, is certainly of interest to enhance steering education methods.

Financial support and sponsorship

Nil.

Conflicts of interest

There are no conflicts of interest.

REFERENCES

1. Ishii T, Mukai Y, Hosono N, Sakaura H, Nakajima Y, Sato Y, et al. Kinematics of the upper cervical spine in rotation: *In vivo* three-dimensional analysis. *Spine (Phila Pa 1976)* 2004;29:E139-44.
2. Oda T, Panjabi MM, Crisco JJ 3rd, Bueff HU, Grob D, Dvorak J. Role of tectorial membrane in the stability of the upper cervical spine. *Clin Biomech (Bristol, Avon)* 1992;7:201-7.
3. Panjabi MM, Oxland TR, Parks EH. Quantitative anatomy of cervical spine ligaments. Part I. Upper cervical spine. *J Spinal Disord* 1991;4:270-6.
4. Radcliff KE, Hussain MM, Moldavsky M, Klocke N, Vaccaro AR, Albert TJ, et al. *In vitro* biomechanics of the craniocervical junction—a sequential sectioning of its stabilizing structures. *Spine J* 2015;15:1618-28.
5. Tubbs RS, Hallock JD, Radcliff V, Naftel RP, Mortazavi M, Shoja MM, et al. Ligaments of the craniocervical junction. *J Neurosurg Spine* 2011;14:697-709.
6. Joaquim AF, Appenzeller S. Cervical spine involvement in rheumatoid arthritis – A systematic review. *Autoimmun Rev* 2014;13:1195-202.
7. Krauss WE, Bledsoe JM, Clarke MJ, Nottmeier EW, Pichelmann MA. Rheumatoid arthritis of the craniocervical junction. *Neurosurgery* 2010;66:83-95.
8. Dvorak J, Panjabi M, Gerber M, Wichmann W. CT-functional diagnostics of the rotatory instability of upper cervical spine. 1. An experimental study on cadavers. *Spine (Phila Pa 1976)* 1987;12:197-205.
9. Kettler A, Hartwig E, Schultheiss M, Claes L, Wilke HJ. Mechanically

Table 4: Categorization of upper spine ligaments biomechanical features

	Category 1 (–/–)	Category 2 (+/+)	Category 3 (+/–)
FE	AL, XI, TR	AAP, OAMA, OAMP, (APIC)	AAA, TM, XS
AR	OAMA, OAMP, APIC, TM, XI, XS	AL, AAA, AAP	(TR)

Category according to length (numerator) and moment arm (denominator) changes. + and – correspond to increase and decrease, respectively. Structure in brackets means that alteration is inconclusive. AL - Alar ligament, TM - Tectorial membrane, TR - Transverse ligament, APIC - Apical ligament, XI - Cruciform ligament inferior, XS - Cruciform ligament superior, AR - Acoustic reflex, NA - Not available, AAA - Anterior atlantoaxial ligament, AAP - Posterior atlantoaxial ligament, OAMA - Anterior occipito-atlantal ligament, OAMP - Posterior occipito-atlantal ligament

- simulated muscle forces strongly stabilize intact and injured upper cervical spine specimens. *J Biomech* 2002;35:339-46.
10. Steinmetz MP, Mroz TE, Benzel EC. Craniovertebral junction: Biomechanical considerations. *Neurosurgery* 2010;66:7-12.
 11. Cusick JF, Yoganandan N. Biomechanics of the cervical spine 4: Major injuries. *Clin Biomech (Bristol, Avon)* 2002;17:1-20.
 12. de Carvalho M, Swash M. Neurologic complications of craniovertebral dislocation. *Handb Clin Neurol* 2014;119:435-48.
 13. Hall TM, Briffa K, Hopper D, Robinson K. Comparative analysis and diagnostic accuracy of the cervical flexion-rotation test. *J Headache Pain* 2010;11:391-7.
 14. Hutting N, Scholten-Peeters GG, Vijverman V, Keesenberg MD, Verhagen AP. Diagnostic accuracy of upper cervical spine instability tests: A systematic review. *Phys Ther* 2013;93:1686-95.
 15. Takasaki H, Hall T, Oshiro S, Kaneko S, Ikemoto Y, Jull G. Normal kinematics of the upper cervical spine during the Flexion-Rotation Test – *In vivo* measurements using magnetic resonance imaging. *Man Ther* 2011;16:167-71.
 16. Uitylugt G, Indenbaum S. Clinical assessment of atlantoaxial instability using the Sharp-Purser test. *Arthritis Rheum* 1988;31:918-22.
 17. Osmotherly PG, Rivett DA. Knowledge and use of craniovertebral instability testing by Australian physiotherapists. *Man Ther* 2011;16:357-63.
 18. Osmotherly PG, Rivett DA, Rowe LJ. The anterior shear and distraction tests for craniocervical instability. An evaluation using magnetic resonance imaging. *Man Ther* 2012;17:416-21.
 19. Kaale BR, Krakenes J, Albrektsen G, Wester K. Clinical assessment techniques for detecting ligament and membrane injuries in the upper cervical spine region – A comparison with MRI results. *Man Ther* 2008;13:397-403.
 20. Dugaillly PM, Sobczak S, Sholukha V, Van Sint Jan S, Salvia P, Feipel V, et al. *In vitro* 3D-kinematics of the upper cervical spine: Helical axis and simulation for axial rotation and flexion extension. *Surg Radiol Anat* 2010;32:141-51.
 21. Dugaillly PM, Sobczak S, Lubansu A, Rooze M, Jan SS, Feipel V. Validation protocol for assessing the upper cervical spine kinematics and helical axis: An *in vivo* preliminary analysis for axial rotation, modeling, and motion representation. *J Craniovertebr Junction Spine* 2013;4:10-5.
 22. Dugaillly PM, Sobczak S, Moiseev F, Sholukha V, Salvia P, Feipel V, et al. Musculoskeletal modeling of the suboccipital spine: Kinematics analysis, muscle lengths, and muscle moment arms during axial rotation and flexion extension. *Spine (Phila Pa 1976)* 2011;36:E413-22.
 23. Cappozzo A, Catani F, Croce UD, Leardini A. Position and orientation in space of bones during movement: Anatomical frame definition and determination. *Clin Biomech (Bristol, Avon)* 1995;10:171-8.
 24. Beyer B, Sholukha V, Salvia P, Rooze M, Feipel V, Van Sint Jan S. Effect of anatomical landmark perturbation on mean helical axis parameters of *in vivo* upper costovertebral joints. *J Biomech* 2015;48:534-8.
 25. Van Sint Jan S, Wermenbol V, Van Bogaert P, Desloovere K, Degelaen M, Dan B, et al. A technological platform for cerebral palsy – The ICT4Rehab project. *Med Sci (Paris)* 2013;29:529-36.
 26. Van Sint Jan S, Salvia P, Feipel V, Sobzack S, Rooze M, Sholukha V. *In vivo* registration of both electrogoniometry and medical imaging: Development and application on the ankle joint complex. *IEEE Trans Biomed Eng* 2006;53:759-62.
 27. Goel VK, Clark CR, Gallae K, Liu YK. Moment-rotation relationships of the ligamentous occipito-atlanto-axial complex. *J Biomech* 1988;21:673-80.
 28. Boyd SK, Ronsky JL. Instantaneous moment arm determination of the cat knee. *J Biomech* 1998;31:279-83.
 29. Beyer B, Sholukha V, Dugaillly PM, Rooze M, Moiseev F, Feipel V, et al. *In vivo* thorax 3D modelling from costovertebral joint complex kinematics. *Clin Biomech (Bristol, Avon)* 2014;29:434-8.
 30. Dvorak J, Schneider E, Saldinger P, Rahn B. Biomechanics of the craniocervical region: The alar and transverse ligaments. *J Orthop Res* 1988;6:452-61.
 31. Möller J, Nolte LP, Visarius H, Willburger R, Crisco JJ, Panjabi MM. Viscoelasticity of the alar and transverse ligaments. *Eur Spine J* 1992;1:178-84.
 32. Panjabi M, Dvorak J, Crisco J 3rd, Oda T, Hilibrand A, Grob D. Flexion, extension, and lateral bending of the upper cervical spine in response to alar ligament transections. *J Spinal Disord* 1991;4:157-67.
 33. Kaale BR, Krakenes J, Albrektsen G, Wester K. Head position and impact direction in whiplash injuries: Associations with MRI-verified lesions of ligaments and membranes in the upper cervical spine. *J Neurotrauma* 2005;22:1294-302.
 34. Li-Jun L, Ying-Chao H, Ming-Jie Y, Jie P, Jun T, Dong-Sheng Z. Biomechanical analysis of the longitudinal ligament of upper cervical spine in maintaining atlantoaxial stability. *Spinal Cord* 2014;52:342-7.
 35. Mesfar W, Moglo K. Effect of the transverse ligament rupture on the biomechanics of the cervical spine under a compressive loading. *Clin Biomech (Bristol, Avon)* 2013;28:846-52.
 36. Krakenes J, Kaale BR, Moen G, Nordli H, Gilhus NE, Rorvik J. MRI assessment of the alar ligaments in the late stage of whiplash injury—a study of structural abnormalities and observer agreement. *Neuroradiology* 2002;44:617-24.
 37. Krakenes J, Kaale BR, Moen G, Nordli H, Gilhus NE, Rorvik J. MRI of the tectorial and posterior atlanto-occipital membranes in the late stage of whiplash injury. *Neuroradiology* 2003;45:585-91.
 38. Antinnes JA, Dvorák J, Hayek J, Panjabi MM, Grob D. The value of functional computed tomography in the evaluation of soft-tissue injury in the upper cervical spine. *Eur Spine J* 1994;3:98-101.
 39. Dvorak J, Hayek J, Zehnder R. CT-functional diagnostics of the rotatory instability of the upper cervical spine. Part 2. An evaluation on healthy adults and patients with suspected instability. *Spine (Phila Pa 1976)* 1987;12:726-31.
 40. Fice JB, Cronin DS. Investigation of whiplash injuries in the upper cervical spine using a detailed neck model. *J Biomech* 2012;45:1098-102.
 41. Creighton DS, Marsh D, Gruca M, Walter M. The application of a pre-positioned upper cervical traction mobilization to patients with painful active cervical rotation impairment: A case series. *J Back Musculoskelet Rehabil* 2017;30:1053-9.
 42. Dunning JR, Cleland JA, Waldrop MA, Arnot CF, Young IA, Turner M, et al. Upper cervical and upper thoracic thrust manipulation versus nonthrust mobilization in patients with mechanical neck pain: A multicenter randomized clinical trial. *J Orthop Sports Phys Ther* 2012;42:5-18.
 43. Malo-Urriés M, Tricás-Moreno JM, Estébanez-de-Miguel E, Hidalgo-García C, Carrasco-Uribarren A, Cabanillas-Barea S. Immediate effects of upper cervical translatoric mobilization on cervical mobility and pressure pain threshold in patients with cervicogenic headache: A randomized controlled trial. *J Manipulative Physiol Ther* 2017;40:649-58.
 44. Mello MS, Pagnez MA, Cabral Rde S, Taciro C, Nogueira LA. Occipitoatlantoaxial manipulation for immediate increase to cervical rotation. *Altern Ther Health Med* 2016;22:18-22.
 45. Swait G, Finch R. What are the risks of manual treatment of the spine? A scoping review for clinicians. *Chiropr Man Therap* 2017;25:37.
 46. Podolsky S, Baraff LJ, Simon RR, Hoffman JR, Larmon B, Ablon W. Efficacy of cervical spine immobilization methods. *J Trauma* 1983;23:461-5.
 47. Theodore N, Hadley MN, Aarabi B, Dhall SS, Gelb DE, Hurlbert RJ, et al. Prehospital cervical spinal immobilization after trauma. *Neurosurgery* 2013;72 Suppl 2:22-34.
 48. Panjabi MM, Greenstein G, Duranceau J, Nolte LP. Three-dimensional quantitative morphology of lumbar spinal ligaments. *J Spinal Disord* 1991;4:54-62.
 49. Joaquim AF, Ghizoni E, Tedeschi H, Lawrence B, Brodke DS,

- Vaccaro AR, *et al.* Upper cervical injuries-a rational approach to guide surgical management. *J Spinal Cord Med* 2014;37:139-51.
50. Greenman PE. Principles of Manual Medicine. 3rd ed. Philadelphia, USA: Lippincott Williams & Wilkins; 2003.
 51. Yoganandan N, Kumaresan S, Pintar FA. Geometric and mechanical properties of human cervical spine ligaments. *J Biomech Eng* 2000;122:623-9.
 52. Descarreaux M, Dugas C, Lalanne K, Vincelette M, Normand MC. Learning spinal manipulation: The importance of augmented feedback relating to various kinetic parameters. *Spine J* 2006;6:138-45.
 53. Lee M, Moseley A, Refshauge K. Effect of feedback on learning a vertebral joint mobilization skill. *Phys Ther* 1990;70:97-102.
 54. Kim HJ, Jun BY, Kim WH, Cho YK, Lim MK, Suh CH. MR imaging of the alar ligament: Morphologic changes during axial rotation of the head in asymptomatic young adults. *Skeletal Radiol* 2002;31:637-42.
 55. Dugailly PM. *In vitro* and *in vivo* study of the upper cervical spine kinematics and the suboccipital muscle moment arms: 3D modeling of the musculoskeletal system (PhD dissertation). Brussels: Université Libre de Bruxelles; 2011.
 56. Kruidhof J, Pandy MG. Effect of muscle wrapping on model estimates of neck muscle strength. *Comput Methods Biomech Biomed Engin* 2006;9:343-52.
 57. Panjabi MM, Miura T, Crompton PA, Wang JL, Nain AS, DuBois C. Development of a system for *in vitro* neck muscle force replication in whole cervical spine experiments. *Spine (Phila Pa 1976)* 2001;26:2214-9.
 58. Dvorak J, Froehlich D, Penning L, Baumgartner H, Panjabi MM. Functional radiographic diagnosis of the cervical spine: Flexion/extension. *Spine (Phila Pa 1976)* 1988;13:748-55.