

Intermediate uveitis: Etiologies and outcomes in a tertiary referral hospital in KSA

Haneen Al-Hujaili^{1,2}, Khaled AlAbduljabbar³, Adel AlAkeely¹, Hassan A. Al-Dhibi¹

Access this article online
Quick Response Code:

Website: www.saudijophthalmol.org
DOI: 10.4103/1319-4534.337853

Abstract:

PURPOSE: The purpose of the study is to evaluate the common causes of intermediate uveitis (IU) and outcomes of this disease in patients presenting to King Khaled Eye Specialist Hospital (KKESH) in Riyadh, KSA.

METHODS: This retrospective cohort study evaluated medical files of patients with IU was reviewed. A total of 109 patients were included in the study. The diagnosis followed the Standardization of Uveitis Nomenclature criteria. Data analysis included personal data, etiology of IU, treatment, and complications.

RESULTS: We identified 109 patients with IU. The mean age at diagnosis was 26.45 ± 15.31 years. Most were female (64.9%), and 86% were bilateral at presentation. The etiology of IU was idiopathic in 63.3%. Multiple sclerosis (MS) (19.3%) and tuberculosis (14.7%) were frequent systemic causes of IU. The pattern of complications included macular edema (42.1%), cataract (48.2%), and secondary glaucoma (30.7%); 28.9% of the patients had none of the complications. Treatment comprised topical, local, and systemic steroids, immunosuppressive agents, and biologics. The best-corrected visual acuity was better than 20/40 in 57.5% of the eyes after more than 10 years of follow-up.

CONCLUSION: This study demonstrated that at KKESH, most of the IU cases were idiopathic or associated with MS and tuberculosis. Visual prognosis is favorable even with the long duration of IU and numerous complications.

Keywords:

Complications, etiology, intermediate uveitis, systemic associations, treatment

INTRODUCTION

Intermediate uveitis (IU) is an inflammation that mainly involves the anterior vitreous, peripheral retina, and the ciliary body.^[1,2] It accounts for 12.7% of the uveitis cases^[3] and is usually bilateral; it affects children and young adults. IU can be idiopathic (pars planitis) or secondary to infectious or noninfectious causes. Common infectious causes that lead to IU are tuberculosis and Lyme's disease; noninfectious causes are sarcoidosis and multiple sclerosis (MS).^[4] Clinical features are anterior vitreous cells, peripheral vasculitis, and the presence of snowballs and snowbanks. This is a chronic disease, and it can lead to blindness if left untreated.^[5] Macular edema, cataracts, and vitreous opacities are the most common

complications and causes of vision loss.^[6] This study aimed to evaluate the common causes of IU and outcomes of this disease in patients presenting to King Khalid Eye Specialist Hospital.

METHODS

The study was approved by the Research Committee in King Khaled Eye Specialist Hospital. Patient consent was not required because this was a retrospective study. The medical files of all patients with IU were retrieved and reviewed. IU was classified according to recommendations by the Standardization of Uveitis Nomenclature working group.^[1,2] Patients diagnosed with any disorder other than IU were excluded. Data analysis included demographics, etiology of IU, treatment modalities, complications, and visual acuity at the first and last visit.

This is an open access journal, and articles are distributed under the terms of the Creative Commons Attribution-NonCommercial-ShareAlike 4.0 License, which allows others to remix, tweak, and build upon the work non-commercially, as long as appropriate credit is given and the new creations are licensed under the identical terms.

For reprints contact: WKHLRPMedknow_reprints@wolterskluwer.com

How to cite this article: Al-Hujaili H, AlAbduljabbar K, AlAkeely A, Al-Dhibi HA. Intermediate uveitis: Etiologies and outcomes in a tertiary referral hospital in KSA. Saudi J Ophthalmol 2021;35:81-3.

¹Vitreoretinal Division, King Khaled Eye Specialist Hospital, Riyadh, Kingdom of Saudi Arabia, ²Ophthalmology Department, Ohud General Hospital, Madinah, Kingdom of Saudi Arabia, ³Ophthalmology Department, Shemisee Hospitals, Riyadh, Kingdom of Saudi Arabia

Address for correspondence:

Dr. Haneen Al-Hujaili, Vitreoretinal Division, King Khaled Eye Specialist Hospital, Al- Oruba Street, PO Box 7191 Riyadh 11462, Kingdom of Saudi Arabia.
E-mail: dr.haneenophtha@gmail.com

Submitted: 18-Aug-2019

Revised: 15-Mar-2020

Accepted: 13-Dec-2020

Published: 18-Feb-2022

Statistical analysis

Continuous factors are presented as mean, standard deviation (SD), standard error of the mean, and confidence interval. Categorical data are presented as percentages. The analysis was performed using SPSS, Version 21.0. Armonk, NY: IBM Corp.

RESULTS

A total of 109 patients with IU were included. The mean follow-up period was 11.7 years (range: 0.7–30.0 years). Nearly two-thirds of these patients were female (65.1%); 93.9% of patients had bilateral involvement, and 86% of the patients had bilateral involvement at presentation. The rest had symptoms and signs affecting only one eye initially; the other eye became involved later in the course of the disease. Here, 63.3% (*n* = 69) of the IU cases were idiopathic. MS accounted for 19.3% (*n* = 21), tuberculosis for 14.7% of the patients (*n* = 16), and 2.7% (*n* = 3) had sarcoidosis [Figure 1]. The mean age at diagnosis was 26.45 ± 15.31, and it varied with the underlying origin of IU. Patients with idiopathic IU were the youngest (mean: 22 years (SD: 14) followed by the MS group (mean: 28 years; SD: 12). Patients with tuberculosis (mean: 40 years; SD: 12) and sarcoidosis (mean: 47 years; SD: 17) were older at the time of diagnosis. Most of the pediatric cases (age 13 or less) were idiopathic (*n* = 20/22).

In terms of treatment, 22.8% of the IU patients were controlled with topical steroids only. The rest needed systemic treatment such as systemic steroids (56.1%), local steroids (intra-vitreous or transseptal steroids) (25.4%), and systemic immunosuppression (azathioprine, methotrexate, mycophenolate mofetil, or cyclosporine A (24%). Biologics were only used in 3.5% (mainly anti-TNF drug) [Figure 2]. Most of the patients required more than one therapy. There were no differences in treatments employed based on etiology except in patients with tuberculosis. Antituberculosis therapy was started in all patients with adjunctive therapy in the form of oral steroids (*n* = 16) and azathioprine (*n* = 4).

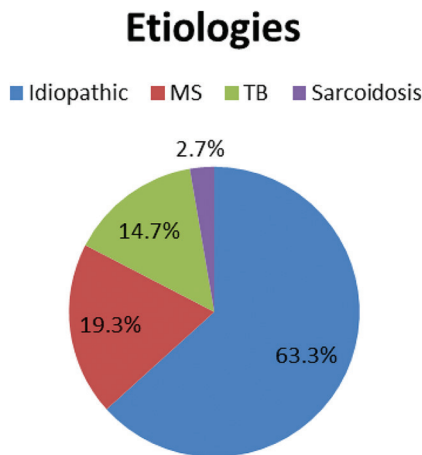


Figure 1: Etiologies

A total of 71.1% of the IU patients developed at least one complication. Cataracts (48.2%) and cystoid macular edema (CME) (42.1) were the most frequent complication followed by glaucoma (30.7) [Figure 3]. Visual acuity was stable among the patients. At the end of follow-up, 57.5% of the eyes had a best-corrected visual acuity of 20/40 or better [Table 1]. As shown in [Figure 4], the percentage of eyes with visual acuity of 20/40 or better increased with follow-up.

DISCUSSION

Our study showed that IU in patients presenting to KKESH was mostly bilateral and idiopathic. This was consistent with other studies around the world.^[3,5,7-10] Most patients have retained a best-corrected visual acuity of 20/40 or better^[7,8] despite numerous complications.

In our study, MS was the second most common cause of IU. This was a similar finding to those of Ness *et al.* and Donaldson *et al.* Visual prognosis in patients with MS was good compared to the tuberculosis group [Figure 4 and Table 2]. Tuberculosis was a frequent underlying disease in IU in our patients and India^[9] in contrast to other countries where it is rare.^[7,8] Sarcoidosis was rare in our patients. We observed a marked difference in age at diagnosis depending on the underlying disease. The youngest patients suffered from idiopathic IU and the oldest from tuberculosis IU similar to Ness *et al.*

We found that ocular complications were frequent among IU patients. The development of cataract, CME, glaucoma, or epiretinal membrane formation is similar worldwide.^[7,8,11] Similar to other studies, nearly two-thirds of our patients required systemic treatment. The main systemic treatment indications in our study were the failure to control the

Table 1: BCVA 1st visit VS Last visit

VA then range of VA then %	Range of VA	Percentage
BCVA eyes, initial visit	20/20-20/40	48.2
	<20/40-20/200	39.9
	<20/200	11.8
	20/20-20/40	57.5
BCVA eyes, final visit	<20/40-20/200	33.8
	<20/200	8.8

BCVA: Best-corrected visual acuity

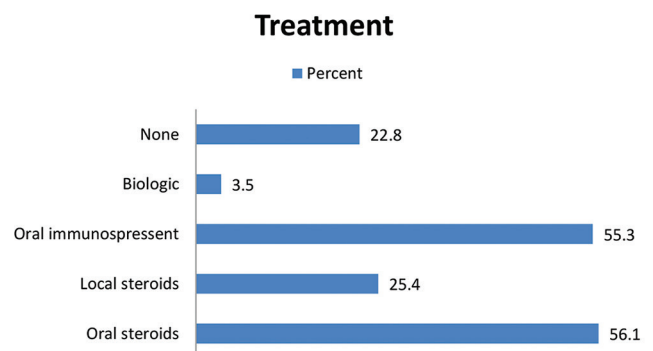


Figure 2: Treatment

Table 2: BCVA 1st visit VS Last visit

	BCVA better eye initial visit (count)			BCVA better eye final visit (count)		
	20/20-20/40	<20/40-20/200	<20/200	20/20-20/40	<20/40-20/200	<20/200
Idiopathic	48	20	1	55	13	1
TB	8	7	1	8	8	0
MS	17	4	0	18	3	0
Sarcoidosis	2	1	0	1	2	0

BCVA: Best-corrected visual acuity, TB: Tuberculous, MS: Multiple sclerosis

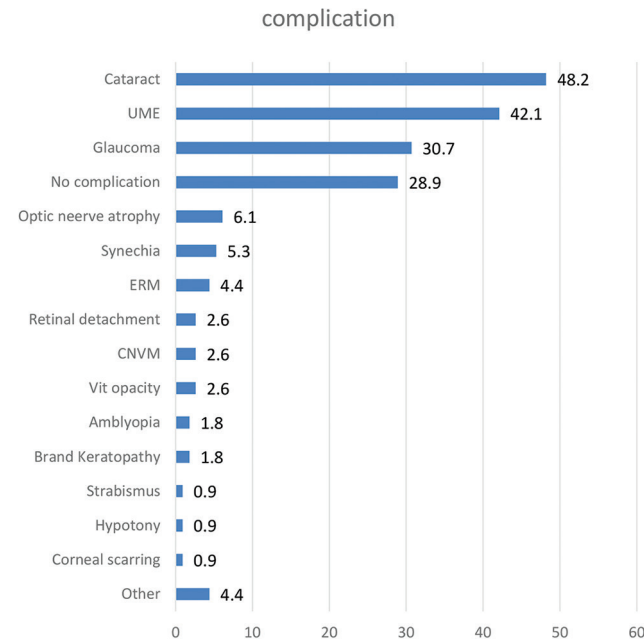


Figure 3: Complications

inflammation or the development of a complication; 45% of our patients received immunosuppressive agents – this is more common than in other studies;^[7,8,11] only 3.5% of the patients received biologics – mainly anti-TNF drugs.

This study does have some limitations. First, the study was carried out using a retrospective study design that raises the possibility of systematic bias. Another limitation was the number of patients selected for the sample. A larger sample would provide additional accuracy. Although the sample size is small, it is in line with other studies carried out in different parts of the world. However, the results are useful for daily clinical practice.

CONCLUSION

Most of the IU cases in KKESH were idiopathic or associated with MS or tuberculosis. A majority of the patients needed systemic treatment, and the visual prognosis was favorable even with multiple complications.

Financial support and sponsorship

Nil.

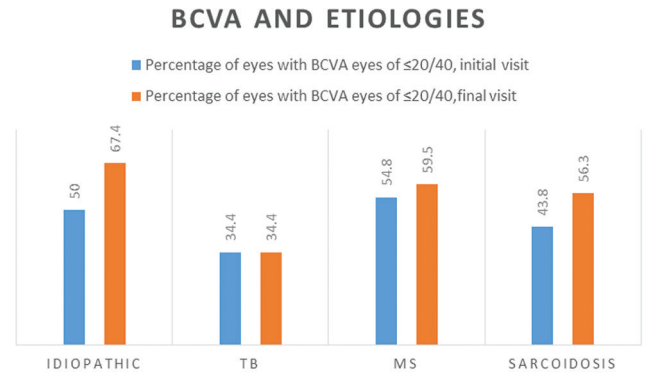


Figure 4: BCVA and etiologies

Conflicts of interest

There are no conflicts of interest.

REFERENCES

- Bloch-Michel E, Nussenblatt RB. International Uveitis Study Group recommendations for the evaluation of intraocular inflammatory disease. *Am J Ophthalmol* 1987;103:234-5.
- Jab DA, Nussenblatt RB, Rosenbaum JT. Standardization of uveitis nomenclature for reporting clinical data: Result of the first international workshop. *Am J Ophthalmol* 2005;140:509-16.
- Al Dhibi HA, Al Shamsi HN, Al-Mahmood AM, Al Taweel HM, Al Shamrani MA, Arevalo JF, *et al.* Patterns of uveitis in a tertiary care referral institute in Saudi Arabia. *Ocul Immunol Inflamm* 2017;25:388-95.
- Bonfioli AA, Damico FM, Curi AL, Orefice F. Intermediate uveitis. *Semin Ophthalmol* 2005;20:147-54.
- Babu BM, Rathinam SR. Intermediate uveitis. *Indian J Ophthalmol* 2010;58:21-7.
- Vidovic-Valentincic N, Kraut A, Hawlina M, Stunf S, Rothova A. Intermediate uveitis: long-term course and visual outcome. *Br J Ophthalmol* 2009;93:477-80.
- Ness T, Boehringer D, Heinzlmann S. Intermediate uveitis: Pattern of etiology, complications, treatment and outcome in a tertiary academic center. *Orphanet J Rare Dis* 2017;12:81.
- Chan CK, Wu ZH, Luk FO, Liu DT, Fan AH, Lee VY, *et al.* Clinical characteristics of intermediate uveitis in Chinese patients. *Ocul Immunol Inflamm* 2013;21:71-6.
- Rathinam SR, Namperumalsamy P. Global variation and pattern changes in epidemiology of uveitis. *Indian J Ophthalmol* 2007;55:173-83.
- Biswas J, Narain S, Das D, Ganesh SK. Patterns of uveitis in a referral unit in India. *Int Ophthalmol* 1996-1997;20:223-8.
- Donaldson MJ, Pulido JS, Herman DC, Diehl N, Hodge D. Pars planitis: A 20-years study of incidence, clinical features, and outcomes. *Am J Ophthalmol* 2007;144:812-7.