

A Case of Metastatic Urothelial Carcinoma Treated with Pemetrexed as Third-Line Chemotherapy with Discussion and Literature Review

Keitaro Iida^a Noriyasu Kawai^a Taku Naiki^a Toshiki Etani^a
Ryosuke Ando^a Takashi Nagai^a Yosuke Sugiyama^c Aya Naiki-Ito^b
Hidenori Nishio^a Atsushi Okada^a Kenjiro Kohri^a Takahiro Yasui^a

Departments of ^aNephro-urology and ^bExperimental Pathology and Tumor Biology, Nagoya City University, Graduate School of Medical Sciences, and ^cDepartment of Pharmacy, Nagoya City University Hospital, Nagoya, Japan

Key Words

Pemetrexed · Urothelial carcinoma · Third-line chemotherapy · Docetaxel · Programmed death ligand 1

Abstract

Pemetrexed is an antifolate agent that is regarded as an alternative second-line chemotherapy against advanced or metastatic urothelial carcinoma (UC). However, there is limited information on pemetrexed in a third-line setting. We report a case of metastatic UC treated with pemetrexed as third-line chemotherapy following gemcitabine and cisplatin (GC) and gemcitabine and docetaxel (GD) therapies. A 73-year-old man with a history of transurethral resection of bladder carcinoma presented with pollakiuria. CT revealed a mass in the left renal pelvis that had invaded into the parenchyma of the left kidney, as well as para-aortic and mediastinum lymph node enlargement. Urinary cytology of the lesion in the left renal pelvis revealed UC. Thus, the patient was diagnosed with left renal pelvic carcinoma (cT3N2M0). After having received 4 courses of GC therapy, another mediastinum lymph node was enlarged. He subsequently received 3 courses of GD therapy as second-line chemotherapy, which showed little efficacy against the metastatic lesions. The patient was administered 3 courses of pemetrexed as third-line chemotherapy; however, its effect on tumor reduction was not sufficient. Finally, metastasis to the liver was observed, and he died 21 months after initiation of chemotherapy. For pathological confirmation, needle biopsy of a metastatic lymph node performed after death revealed high-grade UC and a high positivity of pro-

Iida et al.: A Case of Metastatic Urothelial Carcinoma Treated with Pemetrexed as Third-Line Chemotherapy with Discussion and Literature Review

grammed death ligand 1 (PD-L1) in the tumor, which suggested that he could have benefited from anti-PD-L1 antibody immunotherapy. This report describes the outcome of pemetrexed treatment and proposes another possible candidate as third-line chemotherapy against metastatic UC.

© 2015 The Author(s)
Published by S. Karger AG, Basel

Introduction

Platinum-based combination chemotherapies were established for advanced or metastatic urothelial carcinoma (UC) more than 2 decades ago [1]. Methotrexate, vinblastine, doxorubicin, and cisplatin (MVAC) regimen was a standard first-line treatment for advanced or metastatic UC until 2000, but gemcitabine and cisplatin (GC) therapy has replaced it due to its lower level of toxicity and similar efficacy [1]. Progression-free survival (PFS) associated with MVAC and GC therapies was 8.3 and 7.7 months, respectively, and overall survival (OS) was 15.2 and 14.0 months, respectively, which indicated that cisplatin-based chemotherapy has a limited effect on survival. Several new regimens have recently been developed as second-line chemotherapy for advanced or metastatic UC with moderate outcome [2–6]; however, their efficacy was not sufficient to be established as a standard second-line treatment.

At our institute, we have been treating cisplatin-resistant advanced or metastatic UC with gemcitabine and docetaxel (GD) chemotherapy since 2006 despite it only showing moderate outcome [5], due to the lack of treatment options for patients who demonstrate a good performance status following GC or GD therapy. Recently, immunotherapies using checkpoint blocking antibodies, such as those against programmed death ligand 1 (PD-L1), have been gaining attention as alternative treatment for drug-resistant tumors.

Ours is the first report to demonstrate a case of metastatic UC treated with pemetrexed as third-line chemotherapy following GC and GD therapies, and a new strategy against metastatic UC is also discussed.

Case Report

Our male patient underwent transurethral resection of bladder carcinoma at the age of 64, but he ceased periodical follow-up after surgery. At 73 years of age, he presented with pollakiuria and visited our hospital. Urinalysis showed >100 white blood cells/high-power field and 30–49 red blood cells/high-power field. No bladder tumor was detected by cystoscopy. On enhanced CT, the left kidney had less radiocontrast effect than the right kidney at equilibrium phase, and a defect in the left pelvis was evident at delayed phase. In addition, the para-aortic and mediastinum lymph nodes were enlarged to a maximum of 35 mm. Retrograde pyelography showed an irregularity of the wall of his left calices, and urinary cytology of the left pelvis showed UC. Thus, he was clinically diagnosed with left pelvic carcinoma, and the clinical stage was cT3N2M0.

After providing informed consent, he started GC therapy as first-line systemic chemotherapy. After finishing 2 courses of GC therapy, the left pelvic carcinoma and the metastatic lymph nodes had regressed. However, following another 2 courses of GC therapy, CT showed another mediastinum lymph node enlargement, and thus, the case was classified as progressive disease. The patient received 3 courses of gemcitabine 800 mg/m² and docetaxel 40 mg/m² administered intravenously on days 1 and 8 as second-line chemotherapy according

to the protocol at our institute. However, little efficacy against the mediastinum lymph node lesions was seen, and further, another mediastinum and the cervical lymph nodes were enlarged. The case was classified as progressive disease with failure of second-line GD chemotherapy. Pemetrexed 500 mg/m² every 3 weeks was suggested as third-line chemotherapy for metastatic UC with the approval of the Institutional Review Board at Nagoya City University Hospital (approval No. 41-12-0009). After informed consent, the patient received 3 courses of third-line pemetrexed therapy; however, its effect on tumor growth reduction was insufficient. Finally, metastasis to the liver was observed, and he died 21 months after initiation of the first-line chemotherapy. For pathological confirmation, needle biopsy of the metastatic cervical lymph node was performed after death. The final pathological findings revealed high-grade UC (fig. 1a). Furthermore, immunostaining for PD-L1 expression in the metastatic cervical lymph node taken after death demonstrated a >5% positivity in the tumor (fig. 1b, c).

Discussion

Pemetrexed is an antifolate agent that is included in the same antitumor drug category as methotrexate [7]. The latter has been used for advanced or metastatic UC together with vinblastine, doxorubicin, and cisplatin more than 2 decades ago. Pemetrexed inhibits thymidylate synthase and folate-dependent enzymes involved in purine synthesis [7]. Its mechanism of action differs from gemcitabine which acts as a nucleoside analog [8], from cisplatin which causes crosslinking of DNA purine bases, and from docetaxel which binds to the β -subunit of tubulin and interferes with mitosis [9].

Three trials have evaluated the role of pemetrexed against advanced or metastatic UC in a second-line setting. Galsky et al. [10] performed a phase 2 trial of pemetrexed (500 mg/m² every 21 days) in metastatic UC patients who had previously received platinum-based therapy. This study was closed because of a low objective response rate (ORR) at 8%, but the incidence of grade ≥ 3 adverse events was relatively low (neutropenia 20%, febrile neutropenia 15%, and thrombocytopenia 20%). Sweeny et al. [7] conducted a phase 2 trial using pemetrexed (500 mg/m² every 21 days) for the treatment of patients with advanced UC. They reported an ORR of 28%, a median PFS of 2.9 months, and a median OS of 9.6 months. The incidence of grade ≥ 3 adverse events was <10% (neutropenia 8.5%, thrombocytopenia 8.5%, and anemia 4.3%). Von der Maase et al. [11] treated 47 patients every 21 days with gemcitabine 1,250 mg/m² on days 1 and 8, and pemetrexed 500 mg/m² on day 1. This phase 2 study showed an ORR of 28% and a median OS of 10.3 months. These results were somewhat better than the single-agent use of pemetrexed; however, the incidence of grade ≥ 3 adverse events was much higher (neutropenia 38%, febrile neutropenia 17%, thrombocytopenia 9%, and anemia 19%) including one toxic death due to neutropenic sepsis.

Recently, GC combination chemotherapy has become a standard treatment for advanced or metastatic UC, which results in a median OS of 14.0 months and a median PFS of 7.7 months [1]. For second-line chemotherapy for advanced or metastatic UC, only vinflunine has been validated to extend OS (vinflunine 6.9 months vs. best supportive care 4.3 months); however, it is approved only in the European Union [2]. A number of reports focus on second-line chemotherapy for advanced or metastatic UC which contains a single agent or a combination of gemcitabine, carboplatin, paclitaxel, docetaxel, ifosfamide, and pemetrexed. We summarized the regimens recently reported for advanced or metastatic UC in a second-line setting in table 1 [2–7]. Their ORR was 21.7–47.4%, median PFS 2.9–4.4 months, and median OS 4.8–10.8 months. All of them were somewhat effective, but none of them were

sufficiently effective to be established as a second-line treatment for advanced or metastatic UC.

At our institute, we have used GD therapy as second-line treatment since 2006 (gemcitabine 800 mg/m² and docetaxel 40 mg/m² administered intravenously on days 1 and 8, every 21 days), and a therapeutic benefit was reported [5]. However, the efficacy of this type of chemotherapy is limited, and there is a need to adopt an alternative treatment following the failure of second-line chemotherapy. We chose a single-agent therapy using pemetrexed for several reasons. First, it is an antifolate agent of the same class as the one in MVAC therapy which had been previously used for advanced or metastatic UC. Second, its antitumor mechanism is different from that of gemcitabine, cisplatin, and docetaxel. Finally, its toxicity profile is tolerable and it is thus suitable for outpatient administration. We used pemetrexed as third-line treatment for 4 cases of metastatic UC including the current case, as summarized in table 2. In all 4 cases, the median PFS was 1.9 months, and ORR was 0%. There was no occurrence of grade ≥4 or adverse event, but the efficacy of pemetrexed as a single agent was not satisfactory as third-line treatment in metastatic UC. Further suitable regimens or new drugs are desirable.

New candidate anticancer drugs include those used in cancer immunotherapy, such as checkpoint blocking antibodies which have recently been reported in several cancers, including melanoma, non-small cell lung cancer, ovarian cancer, and renal cell cancer [13]. In the immune system, T cells activated by antigen-presenting cells express programmed death 1 (PD1) after antigen exposure in the peripheral tissue. The ligand of PD1, PD-L1, is expressed on the surface of tumor cells, and the PD1 receptor-ligand interaction results in the negative regulation of T cells in the tumor microenvironment. Blockade of PD-L1 results in the activation of T cells, leading to apoptosis [14]. A recent phase 1 study revealed that patients who had >5% of PD-L1-positive tumor cells had a high ORR (43%) to anti-PD-L1 antibody immunotherapy [14]. In the current case, PD-L1 expression in the metastatic cervical lymph node taken after death was >5% (fig. 1c). This indicated that anti-PD-L1 antibody immunotherapy could have been an appropriate alternative treatment for this case after the acquisition of resistance to several drugs including cisplatin or taxon.

Conclusion

We treated this case of metastatic UC with pemetrexed as third-line chemotherapy after the failure of GC and GD therapies. However, the single-agent pemetrexed treatment was not efficacious, and the patient eventually died. We later demonstrated a high ratio of PD-L1-positive cancer cells in the patient's metastatic cervical lymph node taken after death, which implied that anti-PD-L1 antibody immunotherapy could have been an appropriate alternative treatment. Further studies on the failure of systemic cisplatin-based chemotherapy should be carried out in the future.

Statement of Ethics

This study was conducted in accordance with the Declaration of Helsinki.

Iida et al.: A Case of Metastatic Urothelial Carcinoma Treated with Pemetrexed as Third-Line Chemotherapy with Discussion and Literature Review

Disclosure Statement

The authors have no potential conflicts of interest to disclose.

References

- 1 von der Maase H, Sengelov L, Roberts JT, Ricci S, Dogliotti L, Oliver T, Moore MJ, Zimmermann A, Arning M: Long-term survival results of a randomized trial comparing gemcitabine plus cisplatin, with methotrexate, vinblastine, doxorubicin, plus cisplatin in patients with bladder cancer. *J Clin Oncol* 2005;23:4602–4608.
- 2 Bellmunt J, Fougerey R, Rosenberg JE, von der Maase H, Schutz FA, Salhi Y, Culine S, Choueiri TK: Long-term survival results of a randomized phase III trial of vinflunine plus best supportive care versus best supportive care alone in advanced urothelial carcinoma patients after failure of platinum-based chemotherapy. *Ann Oncol* 2013;24:1466–1472.
- 3 Kouno T, Ando M, Yonemori K, Matsumoto K, Shimizu C, Katsumata N, Komiyama M, Okajima E, Matsuoka N, Fujimoto H, Fujiwara Y: Weekly paclitaxel and carboplatin against advanced transitional cell cancer after failure of a platinum-based regimen. *Eur Urol* 2007;52:1115–1122.
- 4 Albers P, Park SI, Niegisch G, Fechner G, Steiner U, Lehmann J, Heimbach D, Heidenreich A, Fimmers R, Siener R; AUO Bladder Cancer Group: Randomized phase III trial of 2nd line gemcitabine and paclitaxel chemotherapy in patients with advanced bladder cancer: short-term versus prolonged treatment [German Association of Urological Oncology (AUO) trial AB 20/99]. *Ann Oncol* 2011;22:288–294.
- 5 Naiki T, Kawai N, Hashimoto Y, Okamura T, Ando R, Yasui T, Okada A, Etani T, Tozawa K, Kohri K: Gemcitabine and docetaxel, an effective second-line chemotherapy for lung metastasis of urothelial carcinoma. *Int J Clin Oncol* 2014;19:516–522.
- 6 Lin CC, Hsu CH, Huang CY, Keng HY, Tsai YC, Huang KH, Cheng AL, Pu YS: Gemcitabine and ifosfamide as a second-line treatment for cisplatin-refractory metastatic urothelial carcinoma: a phase II study. *Anticancer Drugs* 2007;18:487–491.
- 7 Sweeney CJ, Roth BJ, Kabbinavar FF, Vaughn DJ, Arning M, Curiel RE, Obasaju CK, Wang Y, Nicol SJ, Kaufman DS: Phase II study of pemetrexed for second-line treatment of transitional cell cancer of the urothelium. *J Clin Oncol* 2006;24:3451–3457.
- 8 Lorusso V, Pollera CF, Antimi M, Luporini G, Gridelli C, Frassinetti GL, Oliva C, Pacini M, De Lena M: A phase II study of gemcitabine in patients with transitional cell carcinoma of the urinary tract previously treated with platinum. *Italian Co-operative Group on Bladder Cancer. Eur J Cancer* 1998;34:1208–1212.
- 9 Crown J, O’Leary M: The taxanes: an update. *Lancet* 2000;355:1176–1178.
- 10 Galsky MD, Mironov S, Iasonos A, Scattergood J, Boyle MG, Bajorin DF: Phase II trial of pemetrexed as second-line therapy in patients with metastatic urothelial carcinoma. *Invest New Drugs* 2007;25:265–270.
- 11 von der Maase H, Lehmann J, Gravis G, Joensuu H, Geertsens PF, Gough J, Chen G, Kania M: A phase II trial of pemetrexed plus gemcitabine in locally advanced and/or metastatic transitional cell carcinoma of the urothelium. *Ann Oncol* 2006;17:1533–1538.
- 12 Yonemori K, Katsumata N, Uno H, Matsumoto K, Kouno T, Tokunaga S, Yamanaka Y, Shimizu C, Ando M, Takeuchi M, Fujiwara Y: Efficacy of weekly paclitaxel in patients with docetaxel-resistant metastatic breast cancer. *Breast Cancer Res Treat* 2005;89:237–241.
- 13 Kyi C, Postow MA: Checkpoint blocking antibodies in cancer immunotherapy. *FEBS Lett* 2014;588:368–376.
- 14 Powles T, Eder JP, Fine GD, Braiteh FS, Lortot Y, Cruz C, Bellmunt J, Burris HA, Petrylak DP, Teng SL, Shen X, Boyd Z, Hegde PS, Chen DS, Vogelzang NJ: MPDL3280A (anti-PD-L1) treatment leads to clinical activity in metastatic bladder cancer. *Nature* 2014;515:558–562.

Table 1. Comparison of recent trials of second-line treatment for advanced or metastatic UC

Regimen	Patients, n	ORR patients, n (%)	Median PFS, months	Median OS, months
Carboplatin/paclitaxel [3]	35	10 (32.3)	3.7	7.9
Gemcitabine/paclitaxel [4]	41	17 (41.5)	3.1	8.0
GD [5]	38	18 (47.4)	4.4	10.8
Gemcitabine/ifosfamide [6]	23	5 (21.7)	3.5	4.8
Pemetrexed [7]	47	13 (27.7)	2.9	9.6

Table 2. Profiles of patients who underwent pemetrexed therapy as third-line treatment for metastatic UC

Case No.	Age, years	ECOG PS	Duration of first-line treatment, months	Duration of second-line treatment, months	Median PFS of patients on pemetrexed, months
1	77	1	10.8	33.6	1.6
2	75	1	3.4	25.8	3.0
3	77	1	4.3	1.8	0.9
Current case	73	1	7.1	5.1	2.1
Median	76	–	5.7	15.5	1.9

All 4 cases were initially treated with platinum-based chemotherapy as first-line and GD as second-line treatment. ECOG PS = Eastern Co-operative Oncology Group performance status.

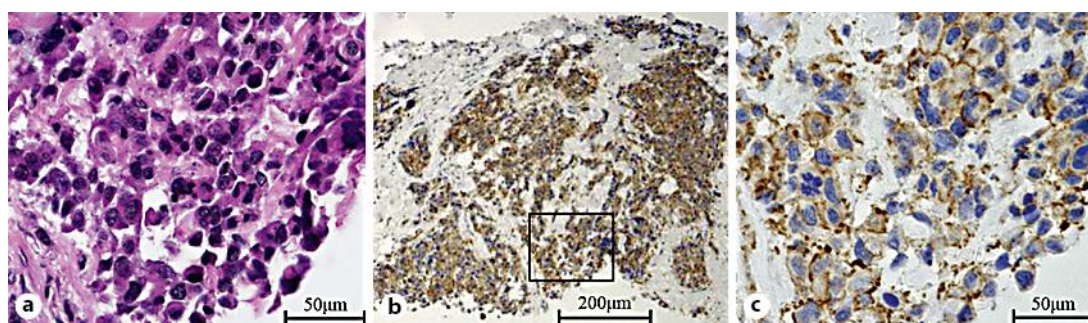


Fig. 1. a High-grade UC. HE staining. b, c Immunohistochemistry for PD-L1. c Magnified image of the inset in b.