

## CASE REPORT

# Torsade de pointes caused by citalopram during the pacemaker battery-depletion phase: A case report

Junwen Wang MD<sup>1</sup>  | Ziyi Sun MD<sup>2</sup>  | Siming Tao PhD<sup>1</sup> 

<sup>1</sup>Department of Cardiology, The Affiliated Hospital of Yunnan University, Kunming, China

<sup>2</sup>Department Intensive Care Unit, The Seventh Affiliated Hospital, Sun Yat-sen University, Shenzhen, China

**Correspondence**

Siming Tao, Department of Cardiology, The Affiliated Hospital of Yunnan University, Kunming, Yunnan, 650032, China.

Email: [taosiming@126.com](mailto:taosiming@126.com)

**Funding information**

This study was supported by Yunnan High-level Personnel Training Support Program (YNWR-MY-2020-024), and Medical Reserve Talents of Yunnan Provincial Health and Planning Commission (H-2017019). The funding covered the time spent during the research process

**Abstract**

Drug-induced QT prolongation, primarily antiarrhythmic drugs, is a common cause of torsade de pointes (TdP). Although there have been previous reports of drug-induced TdP in patients, it has not been well documented when caused by citalopram during the pacemaker battery-depletion phase. To improve delirium recognition, we report a case of citalopram-induced TdP during the pacemaker battery-depletion phase. An 84-year-old Chinese female was brought to the hospital presenting recurrent syncope. She lost consciousness and was admitted after her syncope TdP was documented. Her pacemaker was inspected and found to be operating in an extremely ineffective manner. Although she had prolonged QT interval after the pacemaker was replaced, she did not suffer another syncope attack, and ECG monitoring revealed no cardiac arrhythmia or TdP. During her admission, she was treated with citalopram for depression. Citalopram was discontinued when the QT interval shortened progressively. In this study, we described a case of citalopram-induced TdP during the depletion phase of a pacemaker battery. This case should serve as a cautionary lesson to clinicians to avoid using citalopram during the pacemaker battery-depletion phase.

**KEYWORDS**

case report, citalopram, pacemaker battery depletion, torsade de pointes

## 1 | BACKGROUND

Pacemaker battery depletion is a gradual process that is usually divided into two stages: elective replacement indication and end of life (Bian et al., 2020). To prolong administration of working hours during the first stage, modifications to the procedures of pacemaker are required (Bian et al., 2020; Crépeau-Gendron et al., 2019). The first phase can last many months, providing a perfect opportunity to replace the pacemaker and epicardial leads (Crépeau-Gendron et al., 2019). If the pacemaker is not replaced on time, it gradually stops working, resulting in lethal adverse and nonfatal complications (Crépeau-Gendron et al., 2019; Drew et al., 2010). Citalopram, a selective serotonin reuptake inhibitor, is now critical in the treatment

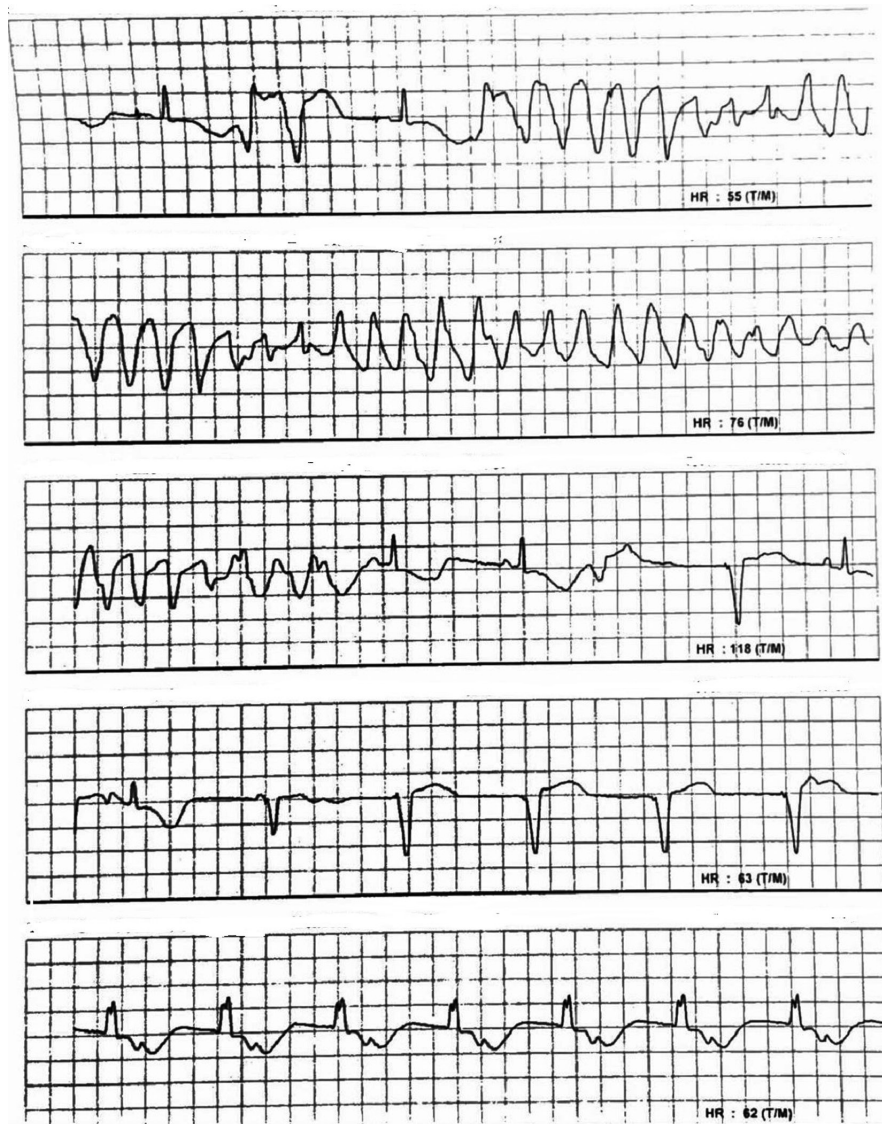
of several psychiatric disorders (Lasocka et al., 2021). Citalopram causes a delayed lengthening of the QT interval and sudden cardiac death (Lasocka et al., 2021). In this study, citalopram was used to treat depression in a patient who had torsade de pointes during pacemaker battery depletion.

## 2 | CASE PRESENTATION

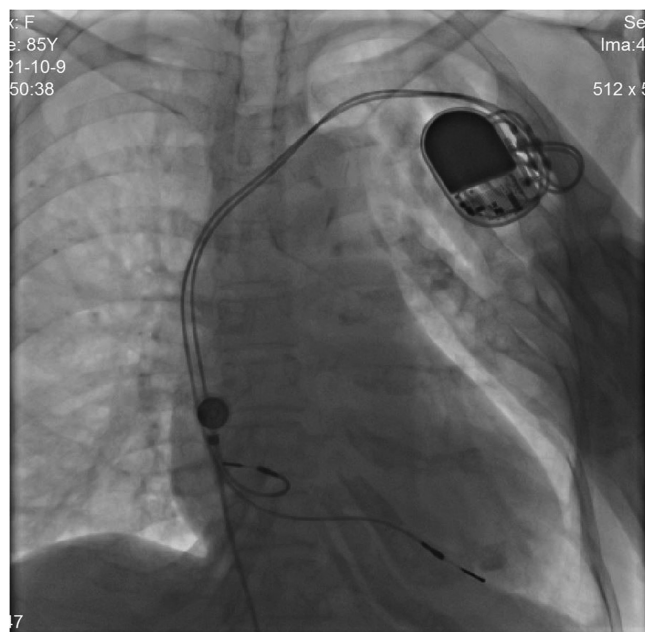
An 84-year-old female with angina, loss of consciousness, and syncope was admitted to our cardiology department. She had a history of depression and was orally taking citalopram and lorazepam on a regular basis. Because of sick sinus syndrome, the patient acquired a

This is an open access article under the terms of the [Creative Commons Attribution-NonCommercial-NoDerivs](https://creativecommons.org/licenses/by-nc-nd/4.0/) License, which permits use and distribution in any medium, provided the original work is properly cited, the use is non-commercial and no modifications or adaptations are made.

© 2022 The Authors. *Annals of Noninvasive Electrocardiology* published by Wiley Periodicals LLC.



**FIGURE 1** Electrocardiogram showing that torsade de pointes was an induced phenomenon of R on T



**FIGURE 2** The new pacemaker was placed

pacemaker eight years ago. When her pacemaker battery died a year ago, she obtained a new generator against medical advice.

The patient was awake on arrival, with a blood pressure of 146/79 mmHg and a heart rate of 55 bpm with regular rhythm. The patient suffered a witnessed syncope after 10 min of admission. During ECG monitoring, we observed third-degree AV block with QT interval prolongation, and the sinus rhythm was accompanied by torsade de pointes (TdP; [Figure 1](#)). Laboratory tests revealed that blood potassium was 4.15 mmol/L, hypersensitive troponin T was 0.059 ng/ml (<0.026 ng/ml), CK-MB was 1.30 ng/ml (< 4.0 ng/ml), and blood calcium was 2.22 mmol/L. The N-terminal probrain natriuretic peptide (NT-proBNP), liver, and renal function were within normal limits. Cardiac ultrasonography showed that the left ventricular ejection fraction (LVEF) and heart structure were both normal. The patient was intravenously instilled with given 10 ml of magnesium sulfate. Pacing was performed using a temporary pacing lead, and escitalopram and miconazole were immediately discontinued. The next day, the patient underwent dual chamber permanent pacemaker implantation for sick sinus syndrome ([Figure 2](#)). The QT interval shortened after one day, but it remained prolonged.

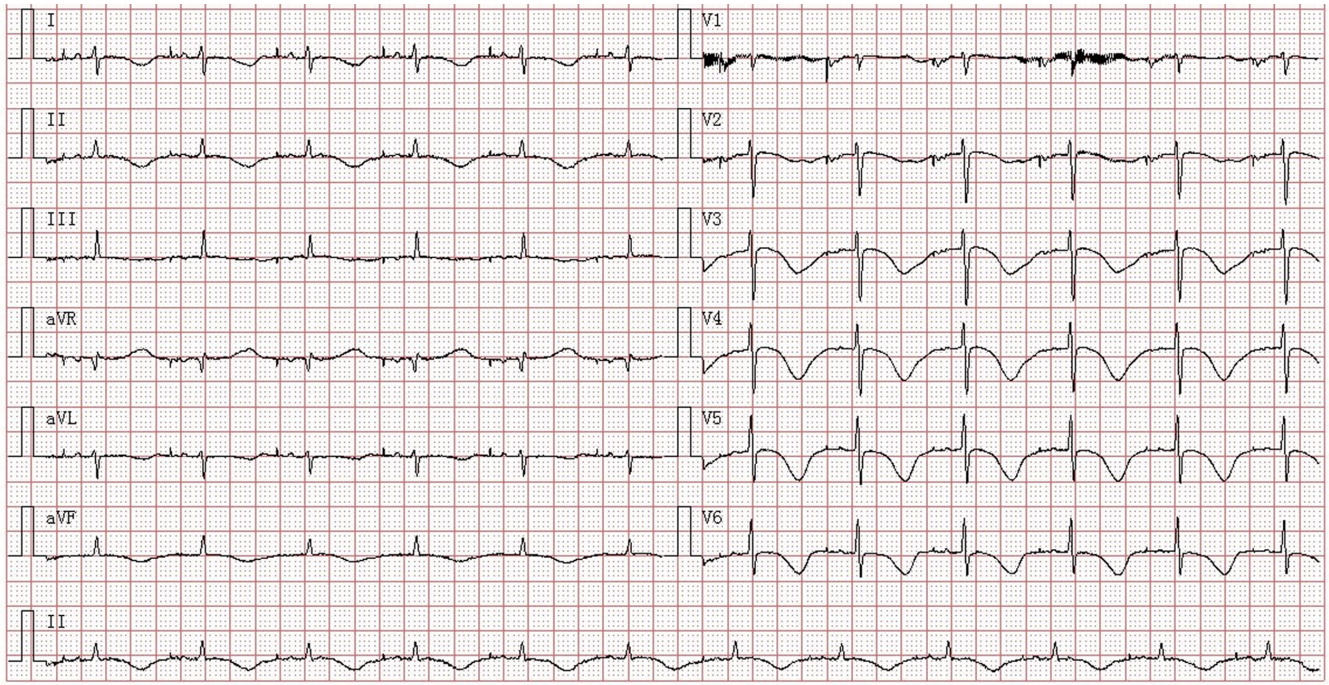


FIGURE 3 The re-examined electrocardiogram revealed heart rate recovery and QT interval prolongation after pacemaker replacement

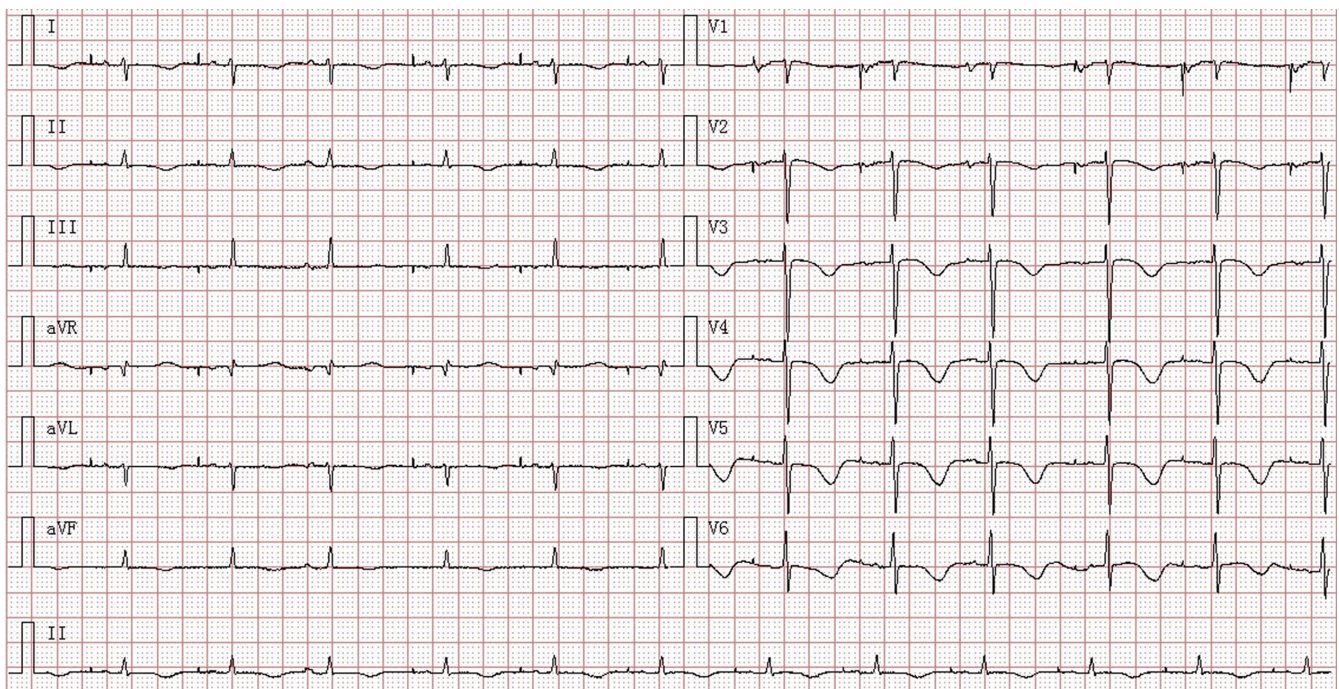


FIGURE 4 The QT interval was significantly shortened before discharge

The QT interval shortens with increasing heart rates (Martinez-Raga et al., 2013). In this study, heart rate was constantly maintained at 70 bpm by pacing. The QT interval was gradually reduced (Figures 3 and 4), and it normalized after 1 month. At the time of writing, the patient was still under follow-up with their setons in place, and she remained syncope free without antidepressant medication changes.

### 3 | DISCUSSION

QTc prolongation can cause malignant cardiac arrhythmias such as torsade de pointes and sudden cardiac death (Vieweg et al., 2012). QT interval can be influenced by many factors including heart rate, age, electrolytes, drugs, cardiac diseases, and metabolic and infectious diseases (Bian et al., 2020; Roden, 2019). In the current study, there

were at least two causes of markedly prolonged QTc interval in the patient, one of which may be citalopram. Citalopram is a depression drug with a high cardiac safety profile (Straley et al., 2021). Therefore, it is widely used for the treatment of depression (Straley et al., 2021). However, it can induce QT interval prolongation. Previous research found no significant linear correlation between QT interval and citalopram dose (Crépeau-Gendron et al., 2019).

In this study, the patient was treated with 10 mg of escitalopram daily. The QT interval shortened after escitalopram was withdrawn, an indication that it was one of the causes of the QT interval prolongation. Furthermore, it is notable that pacemaker battery depletion reduced heart rate. Pacemaker reprogramming and causes of pacing mode occur spontaneously in the early stages of the disease (Liu et al., 2020). The symptoms worsen as the pacemaker battery drains. The most common presenting symptoms are syncope and sudden death (Sinha et al., 2018). However, syncope is not always caused by bradycardia and may be induced in part by torsade de pointes (TdP) (Drew et al., 2010). Torsade de pointes is triggered by R on T phenomenon (Lasocka et al., 2021). The studied patient presented a recurrent episode of syncope, and the electrocardiogram revealed that she had TdP and a distinct prolonged QT interval.

#### ACKNOWLEDGEMENT

We thank the patient for her consent to report this case.

#### CONFLICT OF INTEREST

There are no conflicts of interest reported by any of the authors in relation to the research, authorship, and/or publication of this article.

#### AUTHOR CONTRIBUTIONS

WJ and SZ acquired case data. WJ, SZ, and TS drafted the manuscript. All authors read and approved the final manuscript.

#### ETHICS APPROVAL AND CONSENT TO PARTICIPATE

Ethics approval was not needed according to the Moffitt Cancer Center's policy for case reports.

#### INFORMED CONSENT

The patient signed written informed consent for this article to be published.

#### DATA AVAILABILITY STATEMENT

Data sharing not applicable to this article as no datasets were generated or analysed during the current study.

#### ORCID

Junwen Wang  <https://orcid.org/0000-0003-2426-8944>

Ziyi Sun  <https://orcid.org/0000-0002-0621-8997>

Siming Tao  <https://orcid.org/0000-0002-8074-1938>

#### REFERENCES

- Bian, S., Tang, X., & Lei, W. (2020). A case of torsades de pointes induced by the third-generation EGFR-TKI, osimertinib combined with moxifloxacin. *BMC Pulmonary Medicine*, 20(1), 181. <https://doi.org/10.1186/s12890-020-01217-4>
- Crépeau-Gendron, G., Brown, H., Shorey, C., Madan, R., Szabuniewicz, C., Koh, S., Veinish, S., & Mah, L. (2019). Association between citalopram, escitalopram and QTc prolongation in a real-world geriatric setting. *Journal of Affective Disorders*, 250, 341–345. <https://doi.org/10.1016/j.jad.2019.02.060>
- Drew, B., Ackerman, M., Funk, M., Gibler, W., Kligfield, P., Menon, V., Philippides, G. J., Roden, D. M., & Zareba, W. (2010). Prevention of torsade de pointes in hospital settings: a scientific statement from the American Heart Association and the American College of Cardiology Foundation. *Circulation*, 121(8), 1047–1060. <https://doi.org/10.1161/circulationaha.109.192704>
- Lasocka, Z., Dąbrowska-Kugacka, A., Lewicka, E., Liżewska-Springer, A., & Królak, T. (2021). Successful catheter ablation of the "R on T". *Ventricular Fibrillation*, 18(18), 9587. <https://doi.org/10.3390/ijerp18189587>
- Liu, J., Wen, L., Yao, S., Zheng, P., Zhao, S., & Yang, J. (2020). Adverse clinical events caused by pacemaker battery depletion: two case reports. *BMC Cardiovascular Disorders*, 20(1), 344. <https://doi.org/10.1186/s12872-020-01622-x>
- Martinez-Raga, J., Knecht, C., Szerman, N., & Martinez, M. (2013). Risk of serious cardiovascular problems with medications for attention-deficit hyperactivity disorder. *CNS Drugs*, 27(1), 15–30. <https://doi.org/10.1007/s40263-012-0019-9>
- Roden, D. M. (2019). A current understanding of drug-induced QT prolongation and its implications for anticancer therapy. *Cardiovascular Research*, 115(5), 895–903. <https://doi.org/10.1093/cvr/cvz013>
- Sinha, S., Carlson, D., Chrispin, J., Barth, A., Rickard, J., Spragg, D., Berger, R., Love, C., Calkins, H., Tomaselli, G. F., & Marine, J. E. (2018). Symptoms and Clinical events associated with Automatic Reprogramming (SCARE) at replacement notification study. *Pacing and Clinical Electrophysiology*, 41(12), 1611–1618. <https://doi.org/10.1111/pace.13532>
- Straley, C., Sochacki, M., Reed, E., Carr, C., & Baugh, T. B. (2022). Comparison of the effect of citalopram, bupropion, sertraline, and tricyclic antidepressants on QTc: A cross-sectional study. *Journal of Affective Disorders*, 296, 476–484. <https://doi.org/10.1016/j.jad.2021.08.149>
- Vieweg, W. V., Hasnain, M., Howland, R. H., Hettema, J. M., Kogut, C., Wood, M. A., & Pandurangi, A. K. (2012). Citalopram, QTc interval prolongation, and torsade de pointes. How should we apply the recent FDA ruling? *American Journal of Medicine*, 125(9), 859–868. <https://doi.org/10.1016/j.amjmed.2011.12.002>

**How to cite this article:** Wang, J., Sun, Z., & Tao, S. (2022).

Torsade de pointes caused by citalopram during the pacemaker battery-depletion phase: A case report. *Annals of Noninvasive Electrocardiology*, 27, e12936. <https://doi.org/10.1111/anec.12936>