

Main Article

Dr G C Ho takes responsibility for the integrity of the content of the paper

Cite this article: Ho GC, Thind R, Yap D, Hunt A. A change in clinical practice for aural foreign bodies – what we learnt from the coronavirus disease 2019 pandemic. *J Laryngol Otol* 2021; 1–4. <https://doi.org/10.1017/S0022215121002048>

Accepted: 12 July 2021

Key words:

Foreign Bodies; Ear; COVID-19; Retrospective Studies; Ear Canal; Tympanic Membrane

Author for correspondence:

Dr G C Ho, ENT Department,
Milton Keynes University Hospital,
Milton Keynes, UK
E-mail: justinhogc@gmail.com

Abstract

Objective. This case series, conducted during the coronavirus disease 2019 pandemic, investigates the impact of leaving aural foreign bodies in situ for a prolonged period of time, including the risk of complications and success rates of subsequent removal attempts.

Method. A retrospective study of aural foreign body referrals over a six-month period was carried out.

Results. Thirty-four patients with 35 foreign bodies were identified (6 organic and 29 inorganic). The duration of foreign bodies left in situ ranged from 1 to 78 days. Four patients suffered from traumatic removal upon initial attempts. First attempts made by non-ENT specialists (68.8 per cent) all failed and were associated with a high risk of trauma (36.4 per cent).

Conclusion. Because of the coronavirus disease 2019 pandemic, this is the first case series to specifically investigate the relationship between the duration of aural foreign bodies left in situ and the risk of complications. Our data suggest that prolonged duration does not increase the incidence of complications.

Introduction

During the initial stages of the coronavirus disease 2019 (Covid-19) pandemic, our ENT department minimised the risk of healthcare professionals' exposure to potential infection by reducing the number of aerosol-generating procedures performed. Overall, this has inevitably led to a change in our clinical practice regarding the management of foreign bodies in the ear, in particular allowing foreign bodies to be left in situ for longer.

According to literature, our case series is the first to specifically investigate the relationship between foreign body duration for up to three months from presentation and the risk of complications.

Aim

ENT UK has published a clinical guide on surgical prioritisation during the pandemic.¹ Table 1 summarises this guidance.

Our ENT department has since transitioned away from the practice of seeing patients presenting with a foreign body in the ear urgently, to seeing patients up to 78 days after their initial presentation.

This case series aimed to answer the following questions: (1) does leaving a foreign body in the ear for a prolonged period of time (up to three months) increase the risk of complications?; (2) does leaving a foreign body in the ear for a prolonged period of time increase the success rate of removal in subsequent attempts?; (3) does a foreign body clear itself after a prolonged period of time?; and (4) does the grade or specialty of clinician affect the chances of foreign body removal?

Materials and methods

Study design

This case-control study was designed and conducted in adherence with the Strengthening the Reporting of Observational Studies in Epidemiology ('STROBE') checklist.

Participants

This study included patients of all ages who presented with a foreign body within the external auditory canal. Patients with foreign bodies in the remainder of the external ear, including the lobule, helix and pinna, were excluded.

Data collection

A retrospective study was conducted of all aural foreign body referrals to our ENT emergency clinic between 1 April 2020 and 31 October 2020.

Table 1. Summary of ENT UK surgical prioritisation guidance

Level of priority	Example of procedure
Priority 1a – Emergency procedures conducted within 24 hours	Button battery removal from nose or ear
Priority 1b – Urgent procedures conducted within 72 hours	Uncontrolled epistaxis or acute mastoiditis
Priority 2 – Procedures conducted within 1 month	Organic foreign body in ear
Priority 3 – Procedures conducted within 3 months	CSF fistula repair
Priority 4 – Procedures conducted within 3 months	Non-organic foreign body

CSF = cerebrospinal fluid

Results

Our search yielded 35 foreign bodies in 34 patients, including 1 patient with bilateral aural foreign bodies. Patients' ages ranged from 2 to 81 years, with 14 female patients and 20 male patients. The total duration of a foreign body in the ear ranged from 1 to 78 days in total. Seven patients required examination and removal of the aural foreign body under general anaesthesia (GA) (20.6 per cent). The type and duration of all foreign bodies, and outcomes and complications, are summarised in [Table 2](#).

First removal attempt

Successful removal

The foreign body was visualised for all 34 patients at the first removal attempt. Eighteen patients (52.9 per cent) had their foreign body successfully removed on the first attempt. Of these 18 patients, 14 foreign bodies were removed by ENT senior house officers (SHOs) (77.8 per cent) and 4 by ENT registrars (22.2 per cent) ([Figure 1](#)).

Unsuccessful removal

First attempts at removal failed in 16 patients (47.1 per cent). Among them, seven were attempted by emergency department doctors (43.8 per cent), three by urgent care centre doctors (18.8 per cent), three by ENT registrars (18.8 per cent), one by an ENT SHO (6.3 per cent), one by a general practitioner (6.3 per cent) and one case was undocumented (6.3 per cent) ([Figure 1](#)).

Second removal attempt

Two patients were consented for examination and removal under GA after their first attempt. Fourteen patients attended for a second attempt at removal. Four attempts were successful (28.6 per cent) and were all conducted by ENT SHOs ([Figure 2](#)). Two patients had no foreign body visualised on their second attempt (14.3 per cent), indicating the foreign bodies had spontaneously cleared on their own.

Among the eight patients for whom a second attempt failed (57.1 per cent), five of those attempts were made by ENT SHOs and three by ENT registrars ([Figure 2](#)). Subsequently, five patients were scheduled to have the foreign body removed under GA, one patient attended for a third attempt at removal which was successful (by ENT registrars), and two patients did not attend follow up despite multiple attempts to contact them.

Of the two patients who did not attend, one patient had a small segment of tissue paper in the external auditory canal on examination, and the other patient had a drowned ant in the external auditory canal. Both patients were unable to tolerate

microsuctioning. As there were no re-presentations to the department for over four months, we assumed there were no further complications ([Figure 2](#)).

Duration of foreign body in situ

The duration of foreign bodies left in situ ranged from 1 to 78 days, with a mean duration of 25.3 days. For the seven patients who underwent removal under GA, the foreign body had been in situ for between 16 and 75 days (mean of 34.1 days). Among the non-GA group, the foreign body was left in situ for a mean of 19.25 days.

Complications

Four patients (11.7 per cent) suffered from traumatic removal of the foreign body upon the initial attempt at removal, resulting in otalgia and mild bleeding from the external auditory canal. The removal attempts in these patients were all made by non-ENT doctors (three by emergency department doctors and one by an urgent care centre doctor). One patient was discovered to have suffered a small slit-like perforation of the tympanic membrane after removal of a diamond-shaped sticker under GA, where the foreign body had been in situ for 28 days.

Organic versus inorganic foreign bodies

Among the 35 foreign bodies, 6 (17.1 per cent) were organic and 29 (82.9 per cent) were inorganic. Three organic (50 per cent) and 16 inorganic (55.2 per cent) foreign bodies were successfully removed on first attempt. Upon the second attempt, none of the organic foreign bodies were removed, and four inorganic foreign bodies were removed. Among all removals under GA, six foreign bodies (85.7 per cent) were inorganic and one (14.3 per cent) was organic. Of the six organic foreign bodies, one (16.7 per cent) resulted in a complication. In contrast, of the 29 inorganic foreign bodies, 4 (13.8 per cent) were associated with complications.

The initial success rates of removal for the organic and inorganic foreign bodies were similar. There was also no significant difference in complication rates between the two groups ([Table 2](#)).

Discussion

Foreign body duration and complication risk

Two large retrospective studies on all ENT foreign bodies have previously been conducted, both of which showed a correlation and a statistically significant relationship between non-iatrogenic complications and the permanence of foreign

Table 2. Summary of type and duration of all foreign bodies, and outcome and complications

Type of FB	Outcome	Duration in situ (days)	Complications
Organic			
- Popcorn	Successful on 1st attempt	57	Nil
- Popcorn	Two attempts failed. FB removed under GA	37	Mild otalgia & bleeding
- Moth	FB drowned with olive oil; successful on 1st attempt	1	Nil
- Ant	FB drowned. Two attempts failed. Patient did not re-present to clinic	Remained in situ after 3 mth	Nil
- Bug	FB drowned with olive oil; successful on 1st attempt	1	Nil
- Beetle	FB drowned with water. No foreign body visualised on 2nd attempt	Uncertain	Nil
Inorganic			
- Non-specific plastic FB	Successful on 1st attempt	78	Nil
- Cotton bud	Successful on 1st attempt	68	Nil
- Plastic earring stud	Successful on 3rd attempt	60 (approx)	Nil
- Rubber hearing aid tip	Successful on 1st attempt	60 (approx)	Nil
- Plastic gem	Successful on 1st attempt	2	Nil
- Plastic gem	No foreign body visualised on 2nd attempt	Uncertain	Nil
- Non-specific plastic FB	FB removed under GA. No other attempts documented	75	Nil
- Silver ear piercing	Successful on 2nd attempt	4	Nil
- Pencil rubber tip	Successful on 1st attempt	17	Nil
- Cotton wool	Successful on 1st attempt	56	Nil
- Plastic bead	Two attempts failed. FB removed under GA	17	Nil
- Cotton bud	Successful on 1st attempt	3	Nil
- Silicon ear bud	Successful on 1st attempt	7	Nil
- Plastic hearing aid	Successful on 1st attempt	Uncertain	Nil
- Plastic bead	Two attempts failed. FB removed under GA	34	Mild bleeding from initial attempt
- Non-specific plastic FB	Two attempts failed. FB removed under GA	30 (approx)	Mild bleeding from initial attempt
- Tissue paper fragments	Fragments not entirely removed after 2 attempts. Patient did not re-present to clinic	Uncertain	Mild bleeding from initial attempt
- Rubber hearing aid tip	Successful on 1st attempt	Uncertain	Nil
- Tissue paper	Successful on 1st attempt	1	Nil
- Tissue paper	Successful on 1st attempt	1	Nil
- Plastic bead	Successful on 1st attempt	9	Nil
- Silicon ear bud	Successful on 2nd attempt	2	Nil
- Diamond sticker	Patient refused otoscope examination. FB removed under GA	30 (approx)	Small slit-like perforation of left TM
- Cotton bud	Successful on 2nd attempt	6	Nil
- Plastic bead	Two attempts failed. FB removed under GA	16	Nil
- Cotton bud	Successful on 1st attempt	3	Nil
- Paper	Successful on 1st attempt	Uncertain	Nil
- Rubber hearing aid tip	Successful on 1st attempt	3	Nil
- Non-specific plastic FB	Successful on 1st attempt	Uncertain	Nil

FB = foreign body; GA = general anaesthesia; mth = months; TM = tympanic membrane

bodies.^{2,3} One study included foreign bodies in situ for 'more than 72 hours' and the other included those in situ for up to 30 days.

Given the unique circumstances of the Covid-19 pandemic, this is the first case series to look specifically at the relationship

between the duration of aural foreign bodies left in situ for over 30 days from presentation and the risk of complications. Contrary to the two retrospective studies mentioned above, our data suggest that prolonged duration does not increase the number of complications, despite our study having a

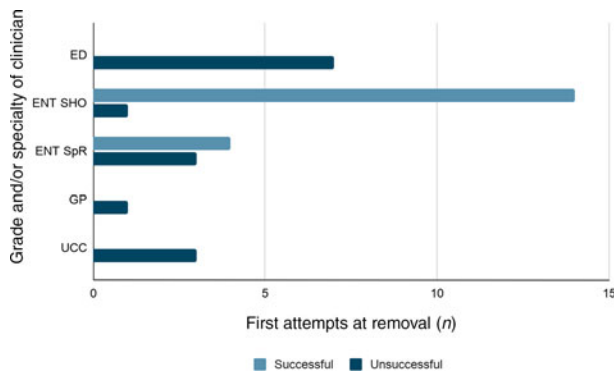


Fig. 1. Summary of first attempts at removal by grade and/or specialty of clinician. ED = emergency department; SHO = senior house officer; SpR = specialist registrar; GP = general practitioner; UCC = urgent care centre

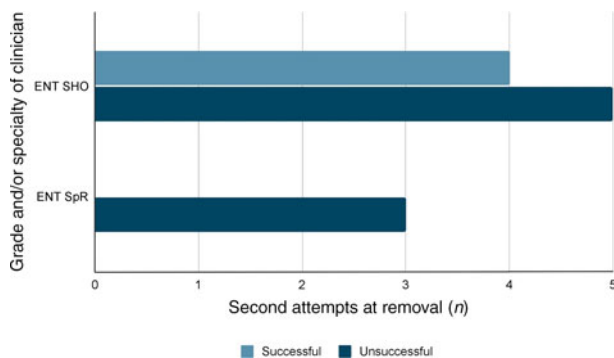


Fig. 2. Summary of second attempts at removal by grade and/or specialty of clinician. SHO = senior house officer; SpR = specialist registrar

smaller sample size. There were no evident major complications associated with a foreign body remaining in situ for up to 78 days.

- There was no correlation between prolonged duration of a foreign body in ear (up to three months) and risk of complications
- Most complications (80 per cent) were from traumatic first attempts conducted by non-ENT specialists
- Prolonged duration of a foreign body does not improve the chances of successful removal
- First attempts made by non-ENT specialists had a high rate of failure (68.8 per cent), with a high risk of trauma (36.4 per cent)
- There is scope for change in clinical practice to allow some aural foreign bodies to be safely removed at a later date

Foreign body duration and removal likelihood

The results showed that the chances of successful removal on the second attempt (28.6 per cent) decreased dramatically when compared to the first attempt (52.9 per cent).

From our results, we concluded that the duration of a foreign body left in the ear does not affect the chances of removal. There are other many factors involved, including: the size, shape and position of the foreign body; how co-operative the patient is at the time of removal; the ability to visualise the foreign body; any prior trauma to the ear from previous attempts at removal; the equipment and tools available; and the skill and experience of the doctor attempting removal.⁴

Clinician grade and specialty

Our results revealed that first attempts at removal made by non-ENT specialists had a low success rate, with a high risk of trauma (36.4 per cent).

Although primary care and emergency department doctors have the advantage of being able to remove foreign bodies at first presentation, ENT specialists have the benefit of accessing more advanced equipment and tools, as well as experience in managing such cases. Previous studies have highlighted the benefit of referring for ENT specialist review with microscopy techniques when a foreign body is more medial or approaching the tympanic membrane, as this would be far less likely to be removed under direct visualisation.^{4,5,6}

Limitations

We are unable to comment on the influence of foreign body position in the external auditory canal, and whether this affected the likelihood of removal, given the lack of documentation.

Conclusion

This case series aimed to investigate the relationship between the duration of foreign bodies in the ear for over 30 days from presentation and the risk of complications. We found no correlation; our data suggested that prolonged duration did not increase the number of complications.

It can be concluded that the prolonged duration of a foreign body in situ does not increase the likelihood of removal. Our results also demonstrate that attempts made by ENT clinicians were far more likely to be successful and that the specialty of clinician directly affects the chances of successful foreign body removal.

The implication of these results may be significant in the post-Covid-19 world where resources are strained. It may be possible for practice to change to allow asymptomatic patients with low-risk foreign bodies to be safely discharged with appropriate safety-netting advice, with a plan to present at a later date for removal by an experienced ENT professional under more optimal circumstances, using adequate equipment.

Competing interests. None declared

References

- 1 ENT UK. Clinical guide to surgical prioritisation during the coronavirus pandemic (ENT specific). In: <https://www.entuk.org/sites/default/files/Clinical%20guide%20to%20surgical%20prioritisation%20during%20the%20coronavirus%20pandemic%20%28ENT%20specific%29.pdf> [25 July 2021]
- 2 Figueiredo R, de Azevedo A, de Ávila Kós A, Tomita S. Complications of ENT foreign bodies: a retrospective study. *Braz J Otorhinolaryngol* 2008;74:7–15
- 3 Ibekwe T, Folorunsho D, Ore A. Actualities of management of aural, nasal, and throat foreign bodies. *Ann Med Health Sci Res* 2015;5:108–14
- 4 Schulze SL, Kerschner J, Beste D. Pediatric external auditory canal foreign bodies: a review of 698 cases. *Otolaryngol Head Neck Surg* 2002;127:73–8
- 5 Grigg S, Grigg C. Removal of ear, nose and throat foreign bodies: a review. *Aust J Gen Pract* 2018;47:682–5
- 6 Heim SW, Maughan KL. Foreign bodies in the ear, nose, and throat. *Am Fam Physician* 2007;76:1185–9