


Contents lists available at [ScienceDirect](http://www.elsevier.com/locate/aott)

Acta Orthopaedica et Traumatologica Turcica

journal homepage: <https://www.elsevier.com/locate/aott>

Treatment of post-traumatic elbow deformities in children with the Ilizarov distraction osteogenesis technique



Cenk Özkan ^a, Mehmet Ali Devenci ^{a,*}, Mustafa Tekin ^a, Ömer Sunkar Biçer ^a, Kadir Gökçe ^b, Mahir Gülşen ^c

^a Çukurova University, Faculty of Medicine, Department of Orthopedics and Traumatology, Adana, Turkey

^b Mut State Hospital, Mersin, Turkey

^c Ortopedia Hospital, Adana, Turkey

ARTICLE INFO

Article history:

Received 30 May 2016

Received in revised form

19 August 2016

Accepted 23 August 2016

Available online 17 October 2016

Keywords:

Cubitus varus

Cubitus valgus

Distraction osteogenesis

Ilizarov technique

ABSTRACT

Objective: The present study assessed functional and radiographic outcomes of distraction osteogenesis treatment of post-traumatic elbow deformities in children.

Methods: Eight children were treated between 2008 and 2013 for post-traumatic elbow deformities using distraction osteogenesis. Mean age at time of operation was 10.9 years. Six patients had varus and 2 had valgus deformity. Magnitude of correction, fixator index, complications, carrying angle, and elbow range of motion were assessed. Functional results were graded according to protocol of Bellemore et al.

Results: Mean follow-up was 43 months. Mean preoperative varus deformity in 6 patients was 29.2° and valgus deformity in 2 patients was 28.5°. Preoperative flexion and extension of elbow were 123.8° and -10.6°, respectively. Mean carrying angle was 9° valgus at last follow-up. Mean flexion and extension were 134.4° and -6.0°, respectively. Change in carrying angle was statistically significant ($p = 0.002$). There were 2 grade 1 pin tract infections and 1 diaphyseal fracture of humerus. Functional outcome was rated excellent in 7 patients and good in 1 patient.

Conclusion: Ilizarov distraction osteogenesis is a valuable alternative in treatment of elbow deformities in children. The surgical technique is simple and correction is adjustable. Gradual correction prevents possible neurovascular complications and minimally invasive surgery produces less scarring. Compliance of patient and family is key factor in the success of the outcome.

Level of evidence: Level IV, therapeutic study

© 2016 Turkish Association of Orthopaedics and Traumatology. Publishing services by Elsevier B.V. This is an open access article under the CC BY-NC-ND license (<http://creativecommons.org/licenses/by-nc-nd/4.0/>).

Introduction

Fractures of distal humerus constitute approximately 10% of all childhood fractures.¹ Cubitus varus and valgus deformities are frequently encountered as sequela of malunion after supracondylar fracture and nonunion of lateral condyle fracture (9–58%).² Varus angulation, extension, and internal rotation deformity with accompanying flexion contracture or hyperextension of elbow may occur after supracondylar fracture, and nonunion of lateral condyle fracture may present with cubitus valgus deformity and tardy ulnar palsy.

Cosmetic deformity or functional impairment may be indication for corrective surgery. Anatomy of distal humerus with open growth plates requires detailed 3-dimensional planning of complex geometrical osteotomies and it is usually hard to achieve stable fixation between poorly apposed thin bony fragments.³ Acute correction and fixation with plates, K-wires, or unilateral or circular external fixators have been the established methods of treatment.^{4–6} However, acute correction may result in over or undercorrection, neurological deficit, or poor cosmetic appearance. Loss of fixation may cause recurrence of deformity and elbow contracture due to prolonged immobilization.

Distraction osteogenesis has several advantages in deformity surgery such as providing adjustable, 3-dimensional correction, stable fixation, and allowing immediate range of motion (ROM) with less soft tissue damage and scar formation.⁴ The aim of this study was to assess functional and radiographic outcomes of

* Corresponding author.

E-mail address: drmehmetali@hotmail.com (M.A. Devenci).

Peer review under responsibility of Turkish Association of Orthopaedics and Traumatology.

distraction osteogenesis using a hybrid frame with short oblique osteotomy to treat post-traumatic elbow deformities in children and to define the technique and possible complications.

Patients and methods

Records of 8 children (5 female and 3 male) treated for post-traumatic elbow deformities between 2008 and 2013 using distraction osteogenesis with a minimum of 2 years follow-up were evaluated retrospectively after ethical board approval and receiving written, informed consent from parents of the patients. Mean age at time of operation was 10.88 years (range: 4–15 years), while mean age at the time of initial trauma was 5.38 years (range: 2–14 years). Six patients had varus deformity after supracondylar fracture of humerus, and 2 had valgus deformity with accompanying nonunion of lateral condylar fracture of humerus. One patient with cubitus valgus deformity had been previously operated on at another medical center; all remaining deformities were sequelae of nonsurgical treatment. Coronal plane deformity exceeding 10° was indication for corrective surgery. Carrying angle of both sides, flexion and extension of elbow, and forearm rotation were measured with goniometer clinically and noted. Anteroposterior and lateral radiographies of both elbows were obtained for preoperative planning. Lateral condyle prominence index (LCPI) was calculated preoperatively from radiographic images and at last follow-up using method described by Wong et al.⁷ Magnitude of deformity and degree of correction were calculated in reference to carrying angle of contralateral side.

Surgical technique

All operations were done in supine position with arm on radiolucent table under general anesthesia and without tourniquet application. Ilizarov frame assembly consisted of 2 full rings. Distal ring was positioned at level of epicondyle and proximal ring was located above level of olecranon fossa. The 2 rings were angulated at predetermined angle and were connected by 2 parallel hinges located at apex of deformity on either side of distal humeral cortex or farther in a distractive position to allow open wedge correction. Oblique plane deformity planning was conducted for 1 patient with accompanying posterior angulation. K-wires and Schanz screws were placed parallel to distal ring and elbow joint from medial and lateral epicondylar area, aligned in approximately 30° angle to each other. Ulnar nerve was protected from iatrogenic damage with use of mini-incision. Offset Schanz screws were placed on proximal ring from anteromedial and anterolateral cortex above level of radial nerve. An additional proximal half-ring was used in 3 patients to support the system. Short, oblique osteotomy proximal to olecranon fossa was performed with stab incision using multiple drilling technique. Contralateral cortex was left intact. Opening of osteotomy site and future correction were checked intraoperatively under fluoroscopy. System was locked, and active and passive elbow ROM exercises were allowed in early postoperative period (Fig. 1).

Postoperative care and evaluation

Calculation for deformity correction was done according to method described by Herzenberg and Waanders.⁸ Distraction was initiated after 5 days at a rate of 4 full turns/day. Once symmetrical correction to carrying angle of contralateral side was achieved, hinges and motor unit were removed, and the 2 rings were connected with straight rods. Anterior portion of distal full ring was cut with Gigli saw to allow full flexion of elbow. Radiographs were taken at this stage, and again at 4, 8, and 12 weeks postoperatively.

Fixator was removed after radiographic union of osteotomy site under general anesthesia and no protective brace was added. Magnitude of correction, fixator index, complications, carrying angle, and elbow ROM were assessed. Functional results were evaluated at last follow-up visit and were graded as excellent, good, or poor according to protocol of Bellemore et al.⁹ An excellent result was defined as loss of carrying angle of 5° or less, and loss of range of flexion and extension of 10° or less. A good result was loss of carrying angle between 6° and 10°, and loss of flexion and extension of 20° or less. Difference in carrying angle greater than 10°, or range of flexion and extension limited by more than 20° was considered poor result.

Statistical analysis

Statistical Package for Social Sciences (SPSS) software version 16.0 (SPSS Inc., Chicago, IL, USA) was used for data analysis. Paired sample t-test was used to assess changes in carrying angle and elbow flexion and extension from preoperative measurement to last follow-up. $P < 0.05$ was considered statistically significant.

Results

Mean follow-up was 43 months (range: 24–65 months). Demographic data of patients, side of deformity, hand dominance, preoperative varus and valgus deformity, and carrying angle are summarized in Table 1. Mean preoperative varus deformity in 6 patients was 29.16° and 1 patient had accompanying extension deformity of 55°. Mean valgus deformity in the remaining two patients was 28.5°.

Preoperative and postoperative ROM, carrying angle, complications, and functional results are summarized in Table 2. Mean preoperative flexion and extension of elbow were $123.75 \pm 17.68^\circ$ and $-10.63 \pm 8.63^\circ$, respectively. None of the patients had limitation of forearm rotation. Mean time for correction was 4.5 weeks and fixator index was 13.25 weeks. Mean carrying angle was $9 \pm 3.2^\circ$ of valgus at last follow-up. Mean flexion and extension ROM at last follow-up were $134.38 \pm 4.95^\circ$ and $-6.0 \pm 5.15^\circ$, respectively. Change in the carrying angle was statistically significant ($p = 0.002$), while no significant change occurred in flexion and extension of elbow ($p = 0.109$ and 0.110 , respectively).

Mean LCPI was +0.0375 (between -0.25 and +0.14) preoperatively, and was corrected to mean of +0.02 (between -0.18 and +0.16). Prominent lateral condyle was seen in 1 patient.

Regarding complications, there were 2 grade 1 pin tract infections treated with appropriate dressing and oral antibiotic, and 1 diaphyseal fracture of humerus at proximal Schanz screw insertion caused by forceful manipulation during physiotherapy after removal of fixator. Circular external fixator was reapplied until solid union of fracture was achieved. No neurovascular complications occurred. Functional outcome was rated excellent in 7 patients, and good in 1 patient. Clinical and radiographic views of 2 patients each treated for cubitus varus and valgus deformity are provided in Figs. 2 and 3, respectively.

Discussion

There is limited number of studies reporting good results in treatment of post-traumatic elbow deformities with distraction osteogenesis.^{1,4,10,11} Success of the technique is associated with facilitated planning and application of 3-dimensional correction without complex geometrical osteotomies. Furthermore, gradual correction avoids possible neurovascular complications, while stable fixation allows early ROM exercises. It is usually hard to achieve stable fixation of corrective osteotomy because of small

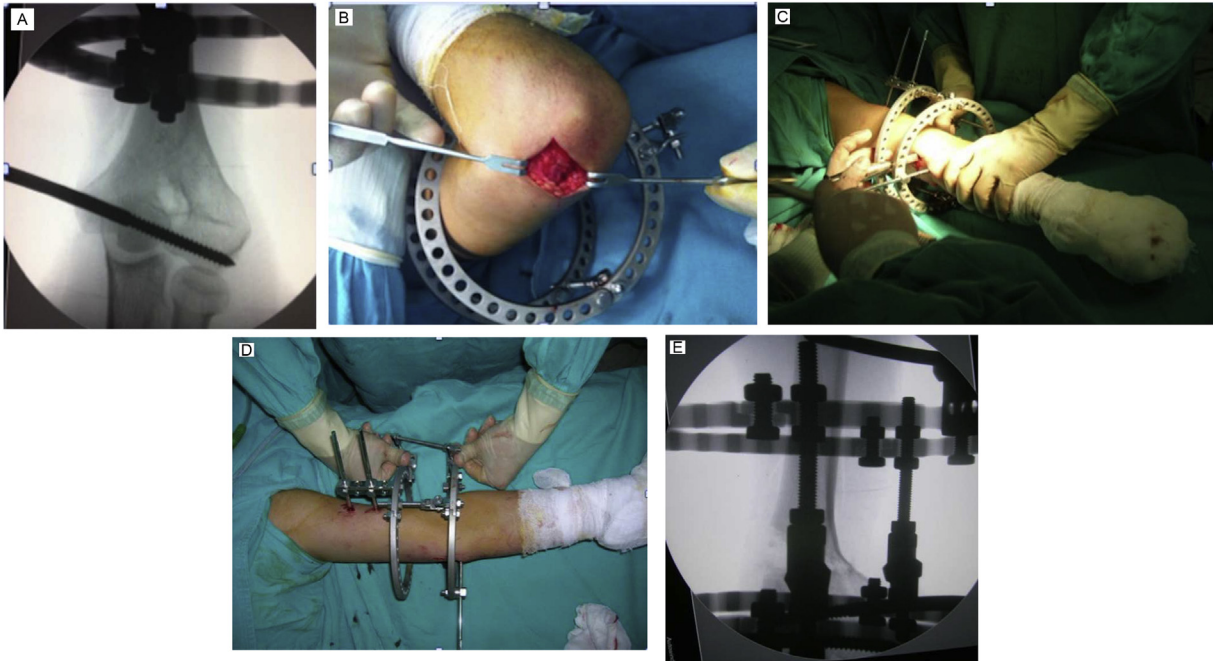


Fig. 1. Surgical technique (a) Placement of distal reference Schanz pin. (b) Medial incision to protect ulnar nerve. (c) Performing percutaneous osteotomy. (d) Clinical and (e) radiological confirmation of correction after osteotomy.

Table 1
Demographic data and preoperative evaluation of the patients.

Patient	Sex	Age at trauma (years)	Age at surgery (years)	Side	Preoperative carrying angle (degree)	Contralateral carrying angle (degree)	Deformity (degree)
1	Female	7	8	Left*	20	8	28 varus 55 procurvatum
2	Female	3	10	Left	22	10	32 varus
3	Male	4	12	Left	18	10	28 varus
4	Male	14	15	Right*	15	10	25 varus
5	Male	2	13	Right*	42	12	30 valgus
6	Female	3	11	Left	35	8	27 valgus
7	Female	7	14	Left	20	12	32 varus
8	Female	3	4	Left*	24	6	30 varus
Mean		5.38	10.88				Varus: 29.16 Valgus: 28.5

*Dominant hand.

distal fragment with limited contact area and open growth plates in children. Hernandez and Rouch emphasized that deformity cannot be controlled in case of unstable fixation of distal fragment.¹² Acute correction and fixation with Ilizarov frame has been reported by

Song et al for treatment of cubitus varus.¹¹ The authors did not apply gradual correction and used the system only for fixation of osteotomy site. They reported union within an average 12 weeks in 15 patients. Karatosun et al reported excellent clinical outcome of

Table 2
Postoperative evaluation of deformity, range of motion, complications, and functional results.

Patient #	Preoperative carrying angle (degree)	Carrying angle at last follow-up (degree)*	Preoperative flexion (degree)	Preoperative extension (degree)	Flexion at last follow-up (degree)#	Extension at last follow-up (degree)¶	Complications	Functional result
1	20	8	90	-10	135	-5	Grade 1 pin tract infection	Excellent
2	22	10	135	0	135	0	None	Excellent
3	18	10	140	-5	140	-5	None	Excellent
4	15	10	115	-20	125	-5	None	Excellent
5	42	12	125	-25	130	-18	Diaphyseal humerus fracture	Good
6	35	8	140	-15	140	-5	Grade 1 pin tract infection	Excellent
7	20	12	135	-5	135	-5	None	Excellent
8	24	2	110	-5	135	-5	None	Excellent
Mean		9 ± 3.2 valgus	123.75 ± 17.68	-10.63 ± 8.63	134.38 ± 4.95	-6.0 ± 5.15		

*p = 0.002; #p = 0.109; ¶p = 0.110.

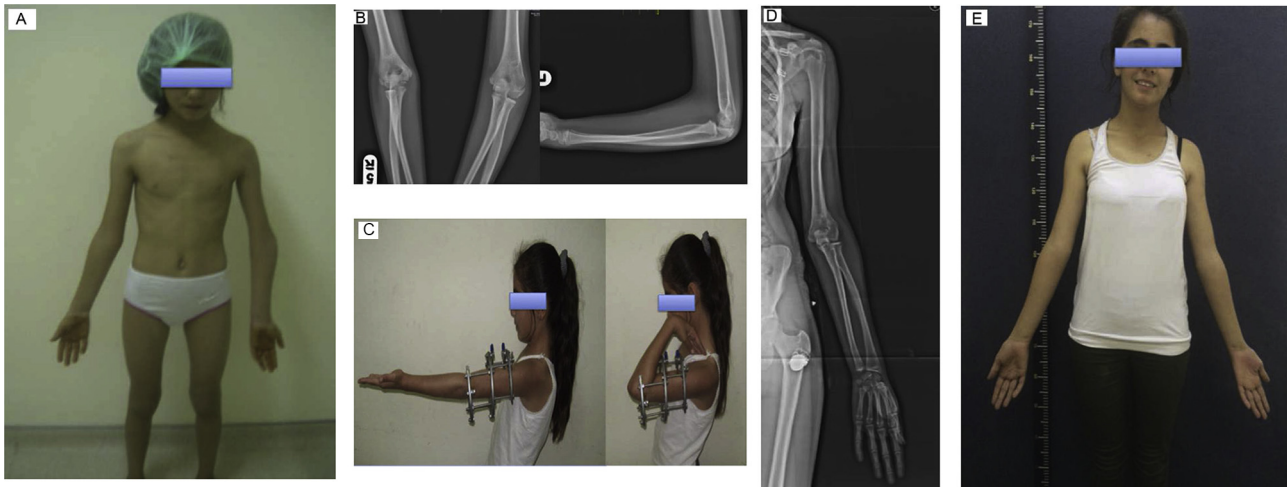


Fig. 2. Ten-year-old girl with cubitus varus (patient #2). (a) Clinical appearance. (b) Anteroposterior and lateral radiographs before correction. (c) Flexion and extension after correction. (d) Anteroposterior radiograph at last follow-up. (e) Clinical appearance at last follow-up.

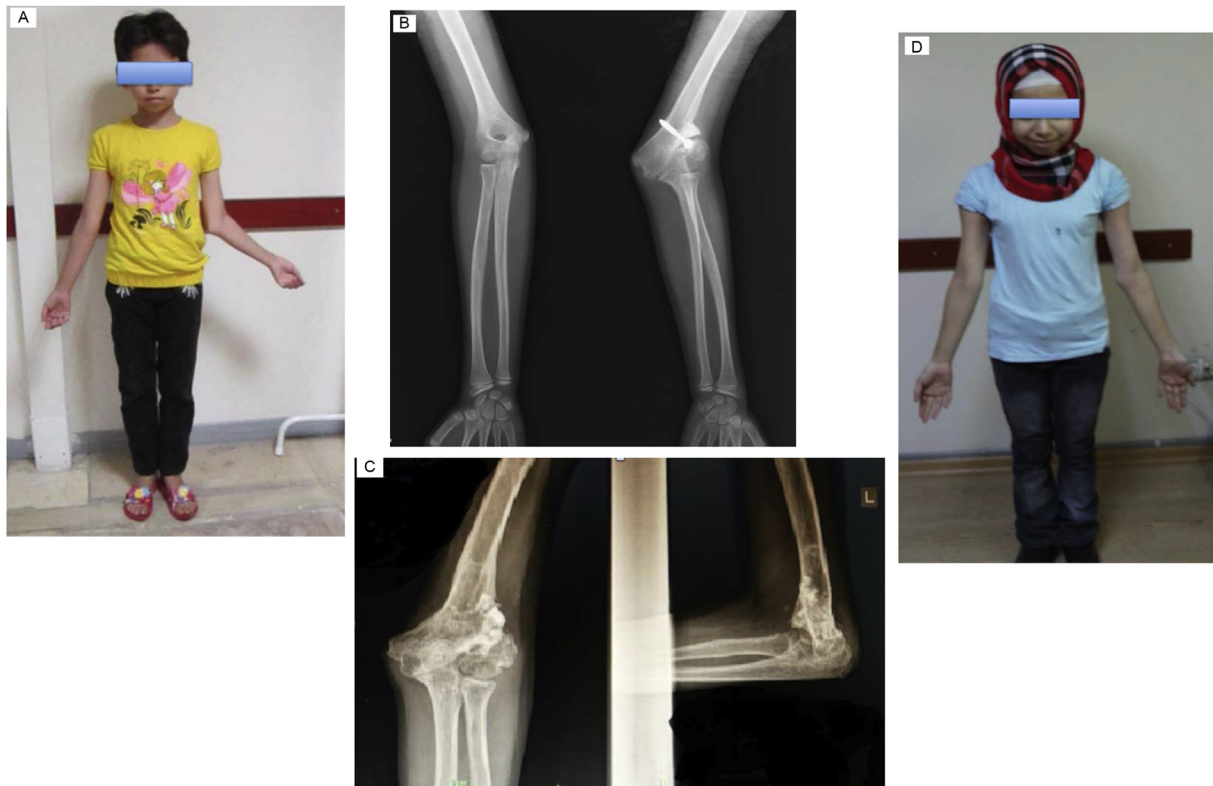


Fig. 3. Eleven-year-old girl with cubitus valgus deformity (patient #6). (a) Clinical appearance. (b) Anteroposterior radiography before correction. (c) Anteroposterior and lateral radiographs at last follow-up. (d) Clinical appearance at last follow-up.

gradual correction using distraction osteogenesis in 7 patients treated at an average age of 6 years.⁴ Pişkin et al reported good to excellent results in 23 patients treated for cubitus varus and valgus deformities.¹ Results obtained by gradual correction using a similar technique were excellent in 6 adult patients treated for cubitus varus deformity by the senior author.¹⁰ Taylor Spatial Frame has also been used with good results reported by Al Sayyad et al in treatment of both cubitus varus and valgus deformities.¹³ The surgical technique in the current study utilized hybrid system, where application of half-pins is easier at level of palpable epicondylar

area. Distal full ring is converted to half-ring after achieving full correction by cutting anterior portion of the ring to allow early full flexion of elbow.

The only major complication in the current study was a diaphyseal fracture of humerus at 2 weeks after removal of fixator that was treated with Ilizarov external fixator and had union in 1½ months. Ilizarov fixator was selected so as not to lose gained elbow ROM. No neurovascular complications were observed and there were only 2 grade 1 pin tract infections, which were treated with appropriate dressing and oral antibiotics. Song et al reported

refracture and radial nerve palsy in their series treated with acute correction.¹¹ Traction injuries may occur with acute corrections, while gradual distraction prevents occurrence of such injuries. Iatrogenic nerve injury may also occur. Ulnar nerve may snap anteriorly in patients with varus deformity or who have undergone previous surgery, and it is vulnerable to damage during insertion of K-wire or half-pin from medial side. It is important to protect ulnar nerve with mini-incision, and tracking of the nerve should be checked after placement of medial half-pin as it may cause entrapment of the nerve during elbow flexion. Kang et al recommended anterior transposition of ulnar nerve in adult patients with tardy ulnar nerve palsy combined with acute correction of cubitus valgus deformity.¹⁴ Pişkin et al also recommended anterior transposition of the nerve in preexisting tardy ulnar nerve palsy for better functional outcome in patients with cubitus valgus.¹ In the present study, none of our patients had existing tardy ulnar nerve lesion, and as we performed gradual correction with exposure of ulnar nerve through small incision and checked tracking of ulnar nerve during elbow ROM, we do not recommend routine anterior transposition of ulnar nerve in patients without ulnar nerve symptoms. Radial nerve may also be injured, as it turns to anterior surface of humerus at its distal third. Insertion of half-pins from anterolateral side should be avoided at distal third of humerus. It is safer to introduce half-pins to proximal humerus by offset connection pieces of current hybrid system. Minor pin tract infections are common problem, but they respond well to local wound care and oral antibiotics.^{1,4,10}

Unightly scars and poor cosmetic outcome are reported to occur in as many as 60% of cases following closing wedge osteotomy and internal fixation because of residual deformity, prominent lateral condyle, and postoperative scar formation.^{7,15} Minimally invasive surgery through stab incisions and open wedge corrective osteotomy seemed to eliminate such problems in the current study. Prominent lateral condyle was observed in 1 patient. This can be easily corrected with Ilizarov technique through medialization and rotation of distal fragment with translational-rotational hinges,¹ but patient did not recognize any cosmetic problem and therefore, we did not attempt to correct prominent lateral condyle.

In the literature, it is clear that after toddler age, children can tolerate external fixator treatment for many indications such as angular deformity, post-traumatic growth plate injuries, or tumor. Although prolonged use of external fixators may have negative psychological impact on children, adequate family counseling and psychological support helps child tolerate course of the treatment.¹⁶ In our study, mean fixator index was 13.25 weeks, which is relatively short compared to other Ilizarov indications. All patients tolerated the external fixator well.

There are some limitations in our study, such as its retrospective nature and small number of cases. Although the technique mentioned is neither a newly defined technique nor optimal, there

are few studies underlying the importance of gradual correction with good to excellent results in mid-term follow-up in the literature. Surgical technique is simplified through use of standard hybrid frame system and further studies are needed to verify the safety and efficacy of the method.

Ilizarov distraction osteogenesis is a valuable alternative for treatment of post-traumatic elbow deformities in children. Surgical technique is simple and correction is adjustable throughout fixator period. Gradual correction prevents possible neurovascular complications and minimally invasive surgery produces less scarring. Modified hybrid system provides safe and reliable fixation of distal fragment and minimizes risk of iatrogenic nerve injury. Compliance of the patient and the family is also a key factor in success of the outcome.

References

1. Pişkin A, Tomak Y, Sen C, Tomak L. The management of cubitus varus and valgus using ilizarov method. *J Bone Jt Surg Br.* 2007;89(12):1615–1619.
2. Gong HS, Chung MS, Oh JH, Cho HE, Baek GH. Oblique closing wedge osteotomy and lateral plating for cubitus varus in adults. *Clin Orthop Relat Res.* 2008;466(4):899–906.
3. Kalacı A, Ozkan C, Yanat AN, Öney T, Sever G, Dođramacı Y. Two different methods of supracondylar lateral wedge osteotomy in cubitus varus deformity in adults. *Eklem Hast Cerrahisi.* 2009;20(3):136–142.
4. Karatosun V, Alekberov C, Alici E, Ardiç CO, Aksu G. Treatment of cubitus varus using the Ilizarov technique of distraction osteogenesis. *J Bone Jt Surg Br.* 2000;82(7):1030–1033.
5. Barrett IR, Bellemore MC, Kwon YM. Cosmetic results of supracondylar osteotomy for correction of cubitus varus. *J Pediatr Orthop.* 1998;18:445–447.
6. Usui M, Ishii S, Miyano S, Narita H, Kura H. Three-dimensional osteotomy for cubitus varus after supracondylar fracture of the humerus in children. *J Pediatr Orthop.* 1991;11:327–331.
7. Wong HK, Lee EH, Balasubramaniam P. The lateral condylar prominence. A complication of supracondylar osteotomy for cubitus varus. *J Bone Jt Surg Br.* 1990;72:859–861.
8. Herzenberg JE, Waanders NA. Calculating rate and duration of distraction for deformity correction with the Ilizarov technique. *Orthop Clin North Am.* 1991;22:601–611.
9. Bellemore MC, Barrett IR, Middleton RWD, Scougall JS, Whiteway DW. Supracondylar osteotomy of the humerus for correction of cubitus varus. *J Bone Jt Surg Br.* 1984;66(4):566–572.
10. Ozkan C, Dođramacı Y, Kalacı A, Gülşen M, Bayram H. Results of using Ilizarov distraction osteogenesis technique for the treatment of cubitus varus deformities in adults. *Arch Orthop Trauma Surg.* 2010;130(4):489–495.
11. Song HR, Cho SH, Jeong ST, Park YJ, Koo KH. Supracondylar osteotomy with Ilizarov fixation for elbow deformities in adults. *J Bone Jt Surg Br.* 1997;79(5):748–752.
12. Hernandez 3rd MA, Roach JW. Corrective osteotomy for cubitus varus deformity. *J Pediatr Orthop.* 1994;14:487–491.
13. Al-Sayyad MJ. Taylor spatial frame in the treatment of upper extremity conditions. *J Pediatr Orthop.* 2012;32(2):169–178.
14. Kang HJ, Koh IH, Jeong YC, Yoon TH, Choi YR. Efficacy of combined osteotomy and ulnar nerve transposition for cubitus valgus with ulnar nerve palsy in adults. *Clin Orthop Rel Res.* 2013;471:3244–3250.
15. Ippolito E, Moneta MR, D'Arrigo C. Post-traumatic cubitus varus. Long-term follow-up of corrective supracondylar humeral osteotomy in children. *J Bone Jt Surg Am.* 1990;72:757–765.
16. Birch JG, Samchukov ML. Use of the Ilizarov method to correct lower limb deformities in children and adolescents. *J Am Acad Orthop Surg.* 2004;12:144–154.