

Two cases of disseminated tuberculosis after negative screening before adalimumab treatment for immune-mediated inflammatory diseases



Rita Fernanda Cortez de Almeida, MD,^a Ricardo Cortez Cardoso Penha, PhD,^b and Livia do Nascimento Barbosa, MD^a
Rio de Janeiro, Brazil

Key words: adalimumab; anergy; hidradenitis suppurativa; inflammatory immune-mediated diseases; psoriasis; tuberculosis.

INTRODUCTION

Adalimumab (Humira) is a fully human, monoclonal antibody against tumor necrosis factor (TNF)- α .¹ It is indicated for several immune-mediated inflammatory diseases, including psoriasis² and hidradenitis suppurativa (HS).³ Tuberculosis (TB) is the most prevalent infectious complication with an increase in the diagnosis among patients receiving anti-TNF- α therapy.⁴ Therefore, TB screening before biological therapy is extremely important to avoid this complication.

We report 2 cases of patients on adalimumab treatment for immune-mediated inflammatory diseases, who have complications with disseminated TB in mammary and intraocular regions, despite negative screening before anti-TNF- α therapy.

CASE REPORT

Case 1

A 69-year-old woman presented with a 1-year history of inflammatory joint pain and psoriasiform plaques involving the extremities, inframammary folds, glutes, face, and scalp. She denied a family history of psoriasis. Physical examination found well-demarcated erythematous, scaly plaques mostly on the extremities. There were asymmetric, tender, and swollen distal interphalangeal joints and pitting of the fingernails. Psoriatic arthritis and psoriasis were diagnosed (Psoriasis Area and Severity Index [PASI] score of 18). Methotrexate therapy was given

Abbreviations used:

CT:	computed tomography
HS:	hidradenitis suppurativa
IGRA:	interferon- γ release assay
IL:	interleukin
RIPE:	rifampicin, isoniazid, pyrazinamide, and ethambutol
TB:	tuberculosis
TNF:	tumor necrosis factor
TST:	tuberculin skin test

for six months, however, it was not effective and a biological treatment has been proposed. Chest radiograph and computed tomography (CT) scan did not show any evidence of TB infection. The tuberculin skin test (TST) was negative. Methotrexate therapy was discontinued, and subcutaneous injections of adalimumab (80 mg initial dose, 40 mg at week 1, 40 mg at week 3, and 40 mg every other week thereafter) were started. After 4 months on therapy, the psoriasis lesions improved, but the patient had a progressive painful swelling of the right breast with no history of trauma, contact with TB patients, or breast disease (Fig 1).

The mammogram was classified as Breast Imaging Reporting and Data System (BIRADS) 4, adalimumab therapy was suspended, and she was admitted to the hospital for further investigation. A biopsy of the breast abscess found multinucleated giant cells without evidence of malignancy. A new CT of the

From the Dermatology Department, Federal Hospital of Bonsucesso^a and the Molecular Carcinogenesis Program, Brazilian National Cancer Institute (INCA).^b

Funding sources: None.

Conflicts of interest: None disclosed.

Correspondence to: Rita Fernanda Cortez de Almeida, MD, Avenida Londres, 616, 21041-020, Rio de Janeiro, Brazil. E-mail: ritaacortez@hotmail.com.

JAAD Case Reports 2019;5:1002-5.
2352-5126

© 2019 by the American Academy of Dermatology, Inc. Published by Elsevier, Inc. This is an open access article under the CC BY-NC-ND license (<http://creativecommons.org/licenses/by-nc-nd/4.0/>).

<https://doi.org/10.1016/j.jidcr.2019.09.008>

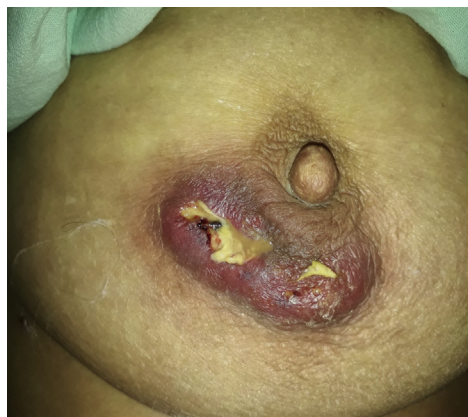

Fig 1. Clinical image from a 69-year-old patient with psoriasis and psoriatic arthritis after 4 months of adalimumab treatment. The image shows subareolar abscess with purulent drainage on the right breast.

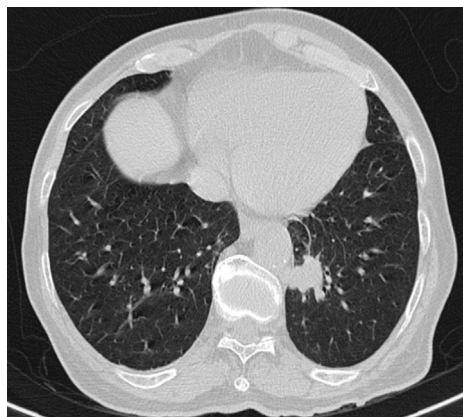


Fig 2. Chest CT image from a 69-year-old patient with psoriasis and psoriatic arthritis after 4 months of adalimumab treatment. CT image shows approximately 4.5-cm nodular opacity with soft tissue density in the basal anteromedial segment of the lower left lobe.

chest and abdomen showed nodular opacity with soft tissue density in the basal anteromedial segment of the lower left lobe (Fig 2), necrotic mediastinal and hilar lymphadenopathy, necrotic presternal lesion, and multiple tiny hypoechoic formations in the spleen. A second TST was recorded as 19 mm. Empirical treatment was started with rifampicin, isoniazid, pyrazinamide, and ethambutol (RIPE), and the therapy was extended for 9 months because of the poor response of the presternal lesion. Her psoriasis progressively worsened. However, the TB lesions regressed, and the patient improved significantly. The patient is currently under anti-interleukin (IL)12/IL-23 therapy (ustekinumab) with no signs of TB recurrence.

Case 2

A 22-year-old man presented with a 2-year history of multiple draining abscesses in intertriginous areas. Physical examination found inflammatory nodules and pus-secreting sinuses located predominantly in the axillary regions. Moderate-to-severe HS was diagnosed. There was no response with oral antibiotic therapy and anti-TNF- α was indicated for his HS. Chest radiograph did not show any evidence of TB infection, and TST was negative. The patient received subcutaneous injections of adalimumab (160 mg initial dose, 80 mg at week 2, 40 mg at week 4, and 40 mg weekly thereafter) with an improvement in his HS. After 3 months, the patient presented with a high-grade fever with no other systemic signs. Moreover, urinalysis showed leukocyturia and hematuria. The routine urine culture did not yield any bacteria. Adalimumab therapy was stopped, and empiric oral antibiotic therapy with levofloxacin was started for 10 days.

After urologic anomalies were excluded, adalimumab was reintroduced.

Two months later, the patient presented with dry eyes and blurred vision. Fluorescein angiography (Fig 3) and optical coherence CT showed images suggestive of bilateral subretinal granuloma, especially in the left eye. A chest CT showed diffuse micronodular opacities in both lungs with the absence of mediastinal lymph nodes. The patient was referred to the National Infectious Diseases Institute, and the interferon- γ release assay (IGRA) was positive. Anti-TNF- α therapy was promptly discontinued, and anti-TB treatment with RIPE was started.

After 2 months of treatment, the patient experienced night sweats, weight loss, productive cough, high-grade fever, and cervical lymphadenopathy. The CT scan of the neck found necrotic degeneration at the right supraclavicular lymph node (Fig 4). A new CT scan of the chest and abdomen showed centrilobular lung nodules with thickening of the interstitium, mediastinal lymph nodes, and splenomegaly with multiple hypoechoic nodules. The biopsy of the supraclavicular lymph node found a chronic granulomatous inflammatory response with the presence of necrosis and the presence of mycobacteria in Wade staining. Anti-TB treatment was extended for 9 months with an improvement of TB lesions. Oral antibiotic treatment for HS was reintroduced, and surgery was performed for the recurring lesions in the right axilla.

DISCUSSION

We report 2 cases of disseminated TB after adalimumab treatment. Adalimumab therapy has

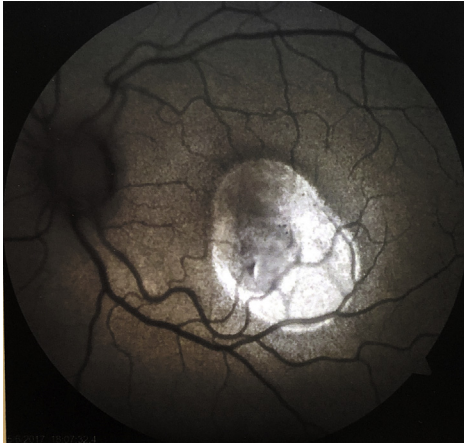

Fig 3. Subretinal granuloma images from a 22-year-old patient with HS after 5 months of adalimumab treatment. Fluorescein angiography of the left eye image shows progressive hypofluorescence areas in the macular region suggestive of granuloma with serous retinal detachment.

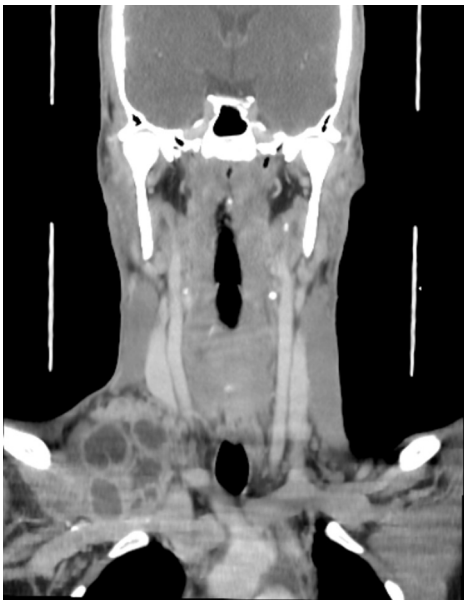

Fig 4. CT scan from a 22-year-old patient with HS after 2 months of antituberculosis treatment. CT image of the neck shows right level VI and bilateral level V lymphadenopathy, the largest confluent with a hypodense center, suggesting necrotic degeneration at the right supraclavicular fossa.

been associated with an increased risk of TB,⁴ which may be caused by (1) the lack of T cell and macrophage recruitments mediated by TNF- α to the site of infection and, therefore, the failure of granuloma formation⁵ or (2) blockage of TNF- α downregulating the inducible nitric oxide synthase in macrophages and its antimicrobial activity against infections such as TB.⁶

Interestingly, both patients had negative TST before adalimumab treatment. These findings indicate a T-cell anergy in the patients regardless of the TB. T-cell anergy is a tolerance mechanism in which the T cells are functionally unresponsive after an antigen encounter due to a lack of costimulatory signals.⁷ Indeed, around 15% of the TB cases have been reported as anergic.⁸ In case 1, the methotrexate therapy before the TST might have accounted for the false-negative result by negatively affecting the T-cell clonal expansion or inducing functional inactivation of T cells after tuberculin antigen exposure.⁹ In case 2, other mechanisms might be involved in T-cell anergy that, in turn, might also have contributed to the poor response to anti-TB treatment. A subset of V δ 2⁺ T cells has been implicated in both innate and adaptive immune responses against *Mycobacterium tuberculosis* infection.¹⁰ The authors found that anergic TB patients with negative TST displayed an enhanced V δ 2⁺ T-cell apoptosis and increased secretion of the inhibitory cytokines IL-4 and IL-10 than positive TST patients that, in turn, induce an impairment of V δ 2⁺ T-cell-mediated antituberculosis immunity.¹⁰ However, the levels of these cytokines were not evaluated in the reported cases.

Our limitation was the absence of resources to perform an IGRA to distinguish true negative responses from anergy before biologic therapy initiation. Even though TST remains the first-line tool to screen for TB, the use of IGRA before or on the same day as the TST could increase the accuracy of the latent TB diagnosis.

The relevance of this current work is to highlight the importance of TB screening before the administration of biological therapy, especially in countries with high TB burden such as Brazil.

We thank the patients for participating. We also thank the staff of Federal Hospital of Bonsucesso, especially Dr Carlos Figueiredo, for his kind assistance and valuable collaboration.

REFERENCES

1. Mitoma H, Horiuchi T, Tsukamoto H, et al. Molecular mechanisms of action of anti-TNF- α agents—comparison among therapeutic TNF- α antagonists. *Cytokine*. 2018;101:56-63.
2. Croom KF, McCormack PL. Adalimumab: in plaque psoriasis. *Am J Clin Dermatol*. 2009;10:43-50.
3. Kim ES, Garnock-Jones KP, Keam SJ. Adalimumab: a review in hidradenitis suppurative. *Am J Clin Dermatol*. 2016;17:545-552.
4. Zhang Z, Fan W, Yang G, et al. Risk of tuberculosis in patients treated with TNF- α antagonists: a systematic review and meta-analysis of randomized controlled trials. *BMJ Open*. 2017;7:e012567.
5. Roach DR, Bean AG, Demangel C, et al. TNF regulates chemokine induction essential for cell recruitment, granuloma

- formation, and clearance of mycobacterial infection. *J Immunol.* 2002;168:4620-4627.
6. Vila-Del Sol V, Diaz-Munoz MD, Fresno M. Requirement of tumor necrosis factor α and nuclear factor- κ B in the induction by IFN- γ of inducible nitric oxide synthase in macrophages. *J Leukoc Biol.* 2007;81:272-283.
 7. Schwartz RH. T cell anergy. *Annu Rev Immunol.* 2003;21:305-334.
 8. Szereday L, Baliko Z, Szekeres-Bartho J. The role of V δ 2+T-cells in patients with active Mycobacterium tuberculosis infection and tuberculin anergy. *Int J Tuberc Lung Dis.* 2008;12:262-268.
 9. Lina C, Conghua W, Nan L, et al. Combined treatment of etanercept and MTX reverses Th1/Th2, Th17/Treg imbalance in patients with rheumatoid arthritis. *J Clin Immunol.* 2011;31:596-605.
 10. Yan L, Cui H, Xiao H, et al. Anergic pulmonary tuberculosis is associated with contraction of the V δ 2+T cell population, apoptosis and enhanced inhibitory cytokine production. *PLoS One.* 2013;8:e71245.