

Pulmonary vein laceration during radiofrequency ablation for atrial fibrillation in a patient with previous robotic-assisted, minimally invasive mitral valve repair



Shawn H. Malan, MD, Ricardo A. Weis, MD, Frank X. Downey, MD, Komandoor Srivathsan, MD, Dan Sorajja, MD, FHRS

From Mayo Clinic Arizona, Phoenix, Arizona.

Introduction

Surgical procedures frequently result in a change to the normal anatomy of a patient. These changes must be considered in patients undergoing subsequent surgeries or procedures. Although endoscopic, robotic, and minimally invasive surgeries have decreased the morbidity associated with surgeries from many specialties,^{1–4} these surgeries lead to changes in natural anatomy, just like their more invasive predecessors. For example, minimally invasive mitral valve replacement surgeries traditionally utilize a right anterolateral minithoracotomy in the fourth intercostal space for exposure. Single-lung ventilation with peripheral cannulation and either transthoracic or endoaortic cross-clamping is used.⁵ After completion of the repair, the decision to close the pericardium is surgeon dependent, as there is currently no consensus regarding its closure.⁶ For those unfamiliar with the minimally invasive and robotic approach, a minithoracotomy scar may not elicit the same concerns as a sternotomy scar, although in both surgeries the heart, aorta, and pericardium were involved in and changed as a result of the procedure. We present a case in which anatomic changes, caused by a prior minimally invasive mitral valve repair, altered the early diagnosis and treatment of complications encountered during a radiofrequency atrial fibrillation (AF) ablation. To our knowledge, no similar complication has been described in literature.

Case report

A 76-year-old man with 2-month history of symptomatic paroxysmal AF refractory to rhythm control with amiodarone

KEYWORDS Atrial fibrillation; Cardiac surgery; Laceration; Minithoracotomy; Pericardial effusion
(Heart Rhythm Case Reports 2021;7:463–465)

Funding Sources: The authors have no funding sources to disclose. **Disclosures:** The authors have no conflicts to disclose. **Address reprint requests and correspondence:** Dr Dan Sorajja, Mayo Clinic Arizona, 5777 East Mayo Blvd, Phoenix, AZ 85054. E-mail address: sorajja.dan@mayo.edu.

KEY TEACHING POINTS

- Cardiac laceration is a known complication of electrophysiology procedures, with increased risk during transseptal puncture, catheter manipulation, or delivery of radiofrequency energy.
- Prior cardiac surgery, and prior manipulation of the pericardial space, should be considered when consenting patients for ablation and when creating a differential diagnosis for intra-procedural hemodynamic instability.
- If accumulation of pericardial fluid or blood cannot be stopped with aspiration, then sources of ongoing bleeding or drainage should be evaluated and treated. A multidisciplinary approach is recommended for the best interest of the patient.

presented for a pulmonary vein isolation for AF via radiofrequency ablation under general endotracheal anesthesia. His medical and surgical histories were significant for hypertension, coronary artery disease status post bare metal stent placement, and bileaflet mitral valve prolapse status post robotic mitral valve repair at an outside institution for which records were unavailable. At the time of the procedure, he had held his prescribed apixaban and aspirin for 2 doses. A myocardial perfusion imaging study performed 1 month prior to the procedure showed an ejection fraction of 61%. There was mild septal wall hypokinesis but no reversible ischemia seen. Transthoracic echocardiogram showed an ejection fraction of 55%–60% with no regional wall motion abnormalities seen. The mitral valve had no prolapse or stenosis and only trivial regurgitation.

The patient was brought to the electrophysiology suite with 2 20-gauge peripheral intravenous catheters placed by the preoperative nursing staff. He underwent a successful

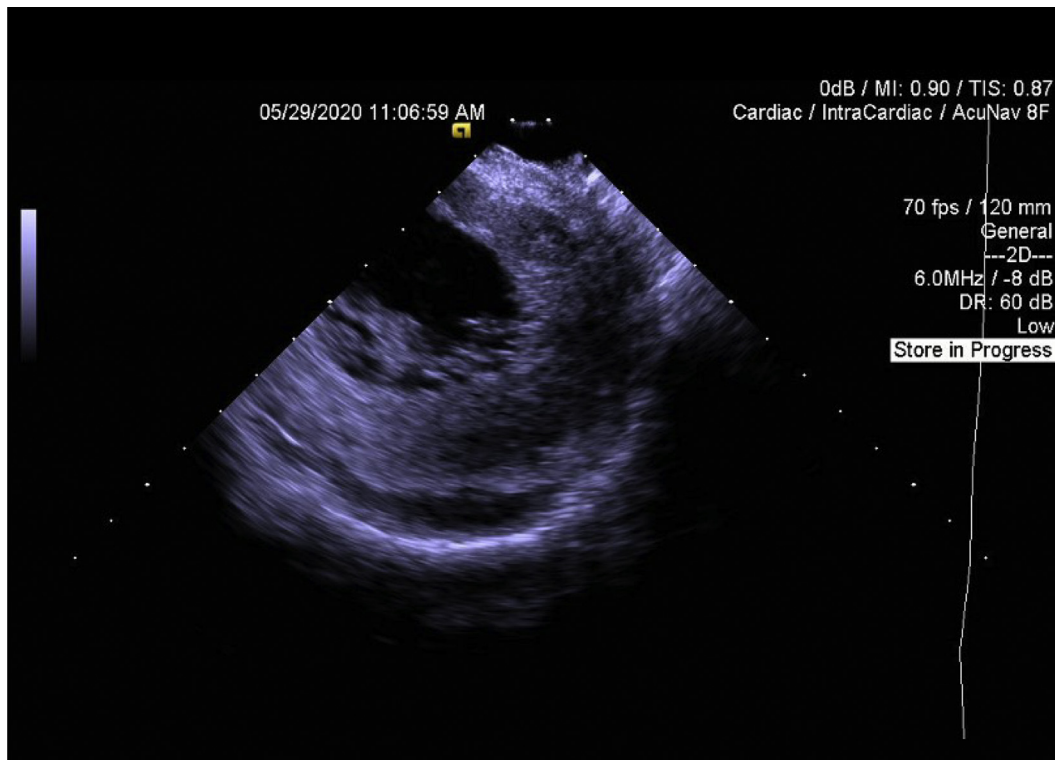


Figure 1 Intracardiac echocardiogram image of small posterior effusion.

intravenous induction with fentanyl, lidocaine, propofol, and rocuronium. A 7.5 endotracheal tube was placed via direct laryngoscopy. An arterial line was placed in the patient's right radial artery, after which the patient was turned over to the care of the electrophysiologist.

Vascular access obtained by the electrophysiologist included 2 separate 8F sheaths in the right femoral vein along with a 9F sheath and 7F sheath in the left femoral vein for placement of an intracardiac echocardiography (IC ECHO) and coronary sinus catheter, respectively. The 8F sheaths were later exchanged for SL0 and SL1 long sheaths for transseptal puncture and left atrial access. Transseptal puncture was successfully performed with fluoroscopic and IC ECHO guidance. Heparin was administered to achieve a target activated clotting time greater than 250 seconds.

The patient remained hemodynamically stable. Approximately 1 hour after the start of the wide circumferential ablation of the left pulmonary veins, the patient's systolic blood pressure quickly dropped from 100–105 mm Hg to 50–55 mm Hg. A phenylephrine infusion and multiple bolus doses were administered, and after approximately 15 minutes the systolic blood pressure returned to baseline and the phenylephrine infusion was stopped. IC ECHO showed a 1.1 cm effusion around the left ventricle, which remained stable in size and showed no evidence of pericardial tamponade (Figure 1). Hemoglobin measured from an arterial blood gas (ABG) was 10.5 g/dL, down from 13.6 g/dL at the beginning of the case. After a discussion between the anesthesiologist and electrophysiologist, it was deemed safe to continue

the procedure, given the stable effusion and decreased vasopressor requirements.

Approximately 1 hour later the patient's hemodynamics again worsened, requiring a pause in the procedure for resuscitation and discussion between providers. A pericardiocentesis was performed, with a pigtail catheter placement in the pericardial space confirmed by echocardiography and fluoroscopy. The effusion previously seen on the IC ECHO improved but did not resolve. A persistent pericardial effusion remained visible at the basal/posterior aspect of the left ventricle despite ongoing aspiration of blood from the pigtail catheter. A repeat ABG showed a decrease in hemoglobin to 7.1 g/dL, so blood products including packed red blood cells and fresh frozen plasma were ordered. Additional electrophysiology and anesthesiology staff were called to help with stabilizing the patient and achieving hemostasis. Over a guidewire, the pigtail catheter was exchanged for a long sheath, which was subsequently double-wired. The long sheath was removed, and 2 separate pigtail catheters were inserted in the pericardial space over the 2 guidewires. One of the pigtail catheters was positioned at the inferior-posterior left ventricle. Simultaneous aspiration of the pigtail catheters was unable to create a vacuum seal and stop additional blood from accumulating in the pericardial space, even with discontinuation of heparin. The estimated blood loss from the pericardial drains at this point was close to 1 L. Cardiovascular surgery was paged to the electrophysiology lab, and transfusion of blood products continued as needed. Despite previous transfusion, a repeat ABG was

sent and showed a hemoglobin level of <5.0 g/dL, so the institutional massive transfusion protocol was initiated. Resuscitative measures included the use of a Belmont rapid infusion machine and cell saver. The rapid infusion machine was hooked up to the 9F femoral vein sheath, which was already available for use.

All efforts to this point were unsuccessful at controlling the bleeding. Discussion was held between cardiovascular surgery, electrophysiology, and anesthesia, and then the patient was prepped and draped for emergent sternotomy. After completing the sternotomy, the surgeons immediately noticed a large amount of blood pooled in the right pleural space. There was very little blood in the pericardium, as it had drained into the pleural space through a defect in the pericardium anterior to the right phrenic nerve, most likely from his robotic mitral valve repair surgery 12 years prior. A laceration on the superior and anterior surface of the left superior pulmonary vein, adjacent to the left atrial appendage, was identified and repaired using 4-0 polypropylene sutures supported by a felt pledget, which resulted in adequate hemostasis. A transesophageal echocardiogram was then done and showed an ejection fraction of 55%–60% and a well-functioning mitral valve, with no other valvular pathology and no wall motion abnormalities. The chest was closed and the patient transferred to the intensive care unit on a low-dose epinephrine infusion.

On postoperative day 1, the patient was extubated and all infusions were discontinued. The remainder of his hospital stay was uneventful. He was discharged to a rehabilitation facility on postoperative day 5 in good condition. In follow-up, he has had no further AF, and has recovered from the sternotomy without problem.

Discussion

Cardiac laceration resulting in cardiac tamponade is a known complication of radiofrequency ablation procedures.⁷ This injury is most likely to occur during specific times of the procedure: (1) transseptal puncture, (2) catheter manipulation, or (3) delivery of radiofrequency energy.⁸ Hemodynamic compromise during these events should alert the treatment team to the potential of cardiac laceration and tamponade. The standard approach for management of this complication includes percutaneous drainage of the effusion, which was attempted via pigtail catheter placement in this case. In the

event of persistent hemodynamic compromise, surgical consultation is warranted.⁹

In this case, the effusion was identified quickly when the patient experienced hypotension. However, the prior pericardiectomy functioned as a persistent drain for blood from the pericardium.¹⁰ This aspect prevented the pericardium from sealing the perforation during aspiration of the pericardial drain. The patient's instability was a result not of tamponade physiology but of persistent hemorrhage into the right chest, resulting in depleted intravascular volume. When developing a differential diagnosis for any complication, it is important to consider patient-specific characteristics, including past surgical history. Consideration of the patient's prior pericardiectomy may have led to the true cause of his hypotension being identified earlier in the case. However, it likely would not have affected the overall outcome of need for sternotomy and repair of the laceration for our patient. In this case, the multidisciplinary approach in the management of our patient with closed-loop communication was essential to achieving a positive outcome.

References

1. Biere SSAY, van Berge Henegouwen MI, Maas KW, et al. Minimally invasive versus open oesophagectomy for patients with oesophageal cancer: a multicentre, open-label, randomised controlled trial. *Lancet* 2012;379:1887–1892.
2. Casarin J, Multinu F, Ubl DS, et al. Adoption of minimally invasive surgery and decrease in surgical morbidity for endometrial cancer treatment in the United States. *Obstet Gynecol* 2018;131:304–311.
3. Gandaglia G, Ghani KR, Sood A, et al. Effect of minimally invasive surgery on the risk for surgical site infections. *JAMA Surg* 2014;149:1039.
4. Lawrance CP, Henn MC, Miller JR, et al. A minimally invasive Cox maze IV procedure is as effective as sternotomy while decreasing major morbidity and hospital stay. *J Thorac Cardiovasc Surg* 2014;148:955–962.
5. Van Praet KM, Stamm C, Sündermann SH, et al. Minimally invasive surgical mitral valve repair: state of the art review. *Interventional Cardiology Review* 2017;13:14.
6. Boyd WD, Tyberg JV, Cox JL. A review of the current status of pericardial closure following cardiac surgery. *Expert Rev Cardiovasc Ther* 2012;10:1109–1118.
7. Deshmukh A, Patel NJ, Pant S, et al. In-hospital complications associated with catheter ablation of atrial fibrillation in the United States between 2000 and 2010. *Circulation* 2013;128:2104–2112.
8. Aldhoon B, Kautzner J. Complications of catheter ablation for atrial fibrillation. *Cor et Vasa* 2012;54:e414–e420.
9. Bunch TJ, Asirvatham SJ, Friedman PA, et al. Outcomes after cardiac perforation during radiofrequency ablation of the atrium. *J Cardiovasc Electrophysiol* 2005;16:1172–1179.
10. Rodriguez ER, Tan CD. Structure and anatomy of the human pericardium. *Prog Cardiovasc Dis* 2017;59:327–340.