

# Intracerebral hematoma after endoscopic fenestration of an arachnoid cyst

## A case report

Bing Qin, MD, Liansheng Gao, MD, Junwen Hu, MD, Lin Wang, MD\*, Gao Chen, MD, PhD\*

### Abstract

**Rationale:** An intracranial arachnoid cyst is a relatively common congenital benign lesion. A small number of patients present with neurological symptoms. Endoscopic fenestration has become a common treatment for arachnoid cysts in recent years, but intracerebral hematoma after surgery is rarely reported.

**Patient concerns:** A 60-year-old woman with an arachnoid cyst in the left parietal and occipital lobes showed obvious progressive neurological deficits. She had weakness in her right limbs for 2 years and a sudden convulsion in her left limbs.

**Diagnosis:** An arachnoid cyst in the left parietal and occipital lobes was detected on magnetic resonance imaging.

**Intervention:** Endoscopic fenestration was performed for the cyst. However, she developed an intracerebral hematoma after surgery, which was detected by computed tomography. Due to the exacerbation of the patient's condition in the early stage after surgery, reoperation was performed to remove the hematoma.

**Outcomes:** The patient was finally cured with no serious neurological deficits.

**Lessons:** The rare complication of intracerebral hematoma after surgery for an arachnoid cyst can lead to a rapid deterioration in the patient's condition. More-adequate preoperative examination and neuronavigation should be conducted during surgery. Appropriate enlargement of the bone hole may help protect against this complication. Moreover, prompt reoperation for the intracerebral hematoma may improve the prognosis.

**Abbreviations:** CT = computed tomography, DTI = diffusion tensor imaging, MRI = magnetic resonance imaging, MRV = magnetic resonance venography.

**Keywords:** arachnoid cyst, endoscopic fenestration, intracerebral hematoma

## 1. Introduction

Intracranial arachnoid cysts are relatively common congenital benign lesions occurring in up to 1.1% of the worldwide population.<sup>[1]</sup> It is more common in children than in adults.<sup>[2]</sup> Most of the cases are sporadic and asymptomatic. A very small number of patients present with neurological symptoms. There are 3 major surgical methods for the treatment of intracranial arachnoid cysts: craniotomy (opening or resection), neuro-

endoscopic fenestration, and shunt surgery. Endoscopic fenestration has been commonly performed in recent years, and endoscopy has been highly effective in most cases.<sup>[3,4]</sup> The main complication of endoscopic fenestration is recurrence of the intracranial arachnoid cyst, and intracerebral hematomas are rare.

We presented the case of a 60-year-old woman with an intracranial arachnoid cyst, who underwent endoscopic fenestration. An intracerebral hematoma and severe cerebral edema were detected after surgery. Therefore, she was reoperated to remove the hematoma and bone flap. The patient's prognosis was good.

## 2. Ethical review

This case report was approved by the clinical ethics committee of the Second Affiliated Hospital of Zhejiang University School of Medicine.

## 3. Patient consent statement

Informed written consent was obtained from the patient for publication of this case report and accompanying images.

## 4. Case report

A 60-year-old woman experienced weakness in her right limbs for 2 years and a sudden convulsion in her left limbs. Her cervical and lumbar vertebrae were examined in the local hospital, but no

Editor: N/A.

BQ, LG, and JH contributed equally to this work.

The authors have no conflicts of interest to declare.

Department of Neurosurgery, Second Affiliated Hospital, School of Medicine, Zhejiang University, Hangzhou, Zhejiang, China.

\* Correspondence: Gao Chen, Department of Neurosurgery, Second Affiliated Hospital, School of Medicine, Zhejiang University, 88 Jiefang Rd, Hangzhou, Zhejiang 310009, China (e-mail: d-chengao@zju.edu.cn); Lin Wang, Department of Neurosurgery, Second Affiliated Hospital, School of Medicine, Zhejiang University, 88 Jiefang Rd, Hangzhou, Zhejiang 310009, China (e-mail: wanglin\_77@hotmail.com).

Copyright © 2018 the Author(s). Published by Wolters Kluwer Health, Inc. This is an open access article distributed under the terms of the Creative Commons Attribution-Non Commercial-No Derivatives License 4.0 (CCBY-NC-ND), where it is permissible to download and share the work provided it is properly cited. The work cannot be changed in any way or used commercially without permission from the journal.

Medicine (2018) 97:44(e13106)

Received: 29 June 2018 / Accepted: 9 October 2018

<http://dx.doi.org/10.1097/MD.00000000000013106>

abnormality was detected. However, because her right limbs twitched 2 days earlier, she visited our hospital. Magnetic resonance imaging (MRI) revealed an arachnoid cyst in the left parietal and occipital lobes (Fig. 1). She had hypertension for >10 years and took amlodipine maleate tablets to control the blood pressure. Physical examination showed that the muscle strength of her right upper limb and right lower limb was grade 3 and 2, respectively, while the muscle strength of the left limbs was grade 5.

Neuroendoscopic fenestration of the arachnoid cyst was performed. A 3-cm scalp incision was made in the left occipital region to form a 2-cm (diameter) bone hole. After the dura mater was opened and a 0.5-cm deep incision was made in the cortical brain tissue, a colorless, clear fluid flowed out, following which, the lumen was visible. The brain tissue at the cystic bottom near the lateral ventricle was thin; fistulization was performed in this area by using neuroendoscopy, and the cortical fistula was opened. No active bleeding was observed.

The patient was transferred to the ward 1 hour later, and muscle strength of the right upper limb and right lower limb returned to grade 5 and 3, respectively. A decline in consciousness was observed at 7 hours after surgery. Two hours later, the patient fell into a coma. Computed tomography (CT) showed the presence of a left occipital parietal hematoma and cerebral hernia (Fig. 2). Therefore, she was immediately reoperated to remove the hematoma.

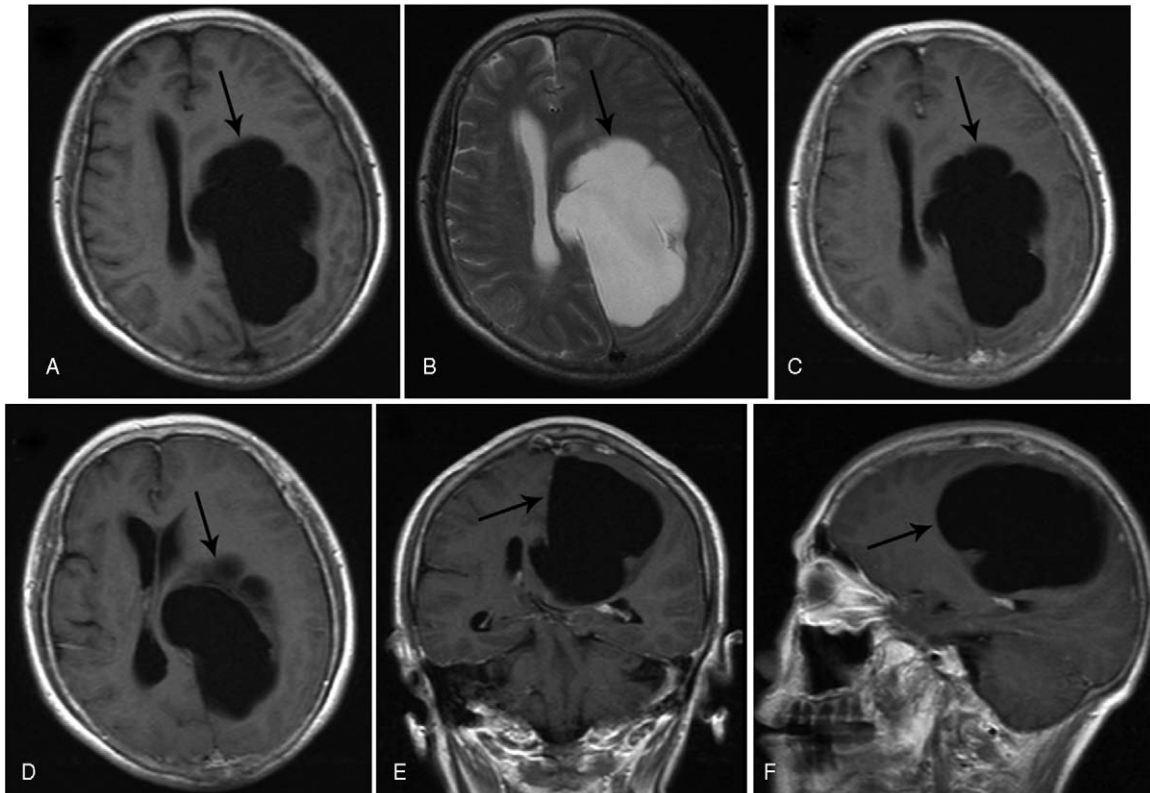
During the surgery, high dural tension, high brain pressure, local cerebral edema, and blood clots in the parietal occipital lobe were observed. The hematoma was removed, but we detected a big broken vein at the cortical fistula (Fig. 3). The vessel trunk was cut off at the former operation site, and the local drainage

vein was blocked. We enlarged the cortical fistula and released the cystic fluid, resulting in a decrease in brain pressure. We performed relaxation sutures of the dura and removed the bone flap at the same time. The patient regained consciousness and her muscle strength of the right limbs increased to grade 4 in the short time after surgery. On the second day, CT showed a reduced midline shift, but brain swelling and scattered cerebral hematoma persisted (Fig. 4).

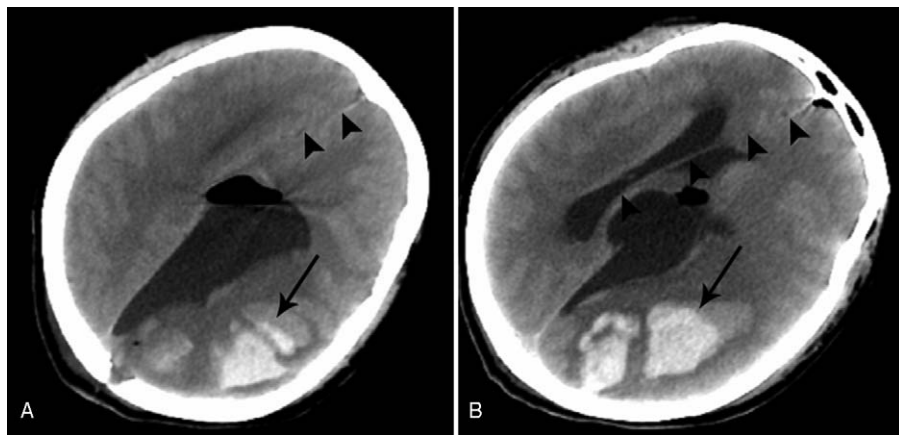
One week later, the muscle strength of her right lower limb and right upper limb increased to grade 5 and 4, respectively. Magnetic resonance venography (MRV) showed the absence of a big vein in the left occipital parietal region (Fig. 5). Three months later, when she returned for cranioplasty, her brain swelling had significantly reduced, cerebral hematoma disappeared (Fig. 6), and muscle strength of the right limbs returned to normal. The patient was followed up for 9 months until the present day and has recovered well.

## 5. Discussion

Most intracranial arachnoid cysts are congenital and do not require any specific treatments. In some cases, the cysts may be enlarged and cause secondary hydrocephalus, leading to the appearance of clinical symptoms, which mainly manifest as increased intracranial pressure and local brain tissue compression. Occasionally, acute symptoms may be caused by cyst rupture and bleeding. Patients with an increased intracranial pressure often benefit from surgery. However, for patients with only headache, epilepsy, cognitive impairment, and other symptoms, but not secondary hydrocephalus or an evident increase in intracranial pressure, the benefit of surgery is



**Figure 1.** Magnetic resonance image shows an arachnoid cyst in the left parietal and occipital lobes (arrow). Long T1 and T2 signals with clear edges and uniform signal intensity and without obvious enhancement under the left falx cerebri are seen. The adjacent brain tissue is compressed and displaced.

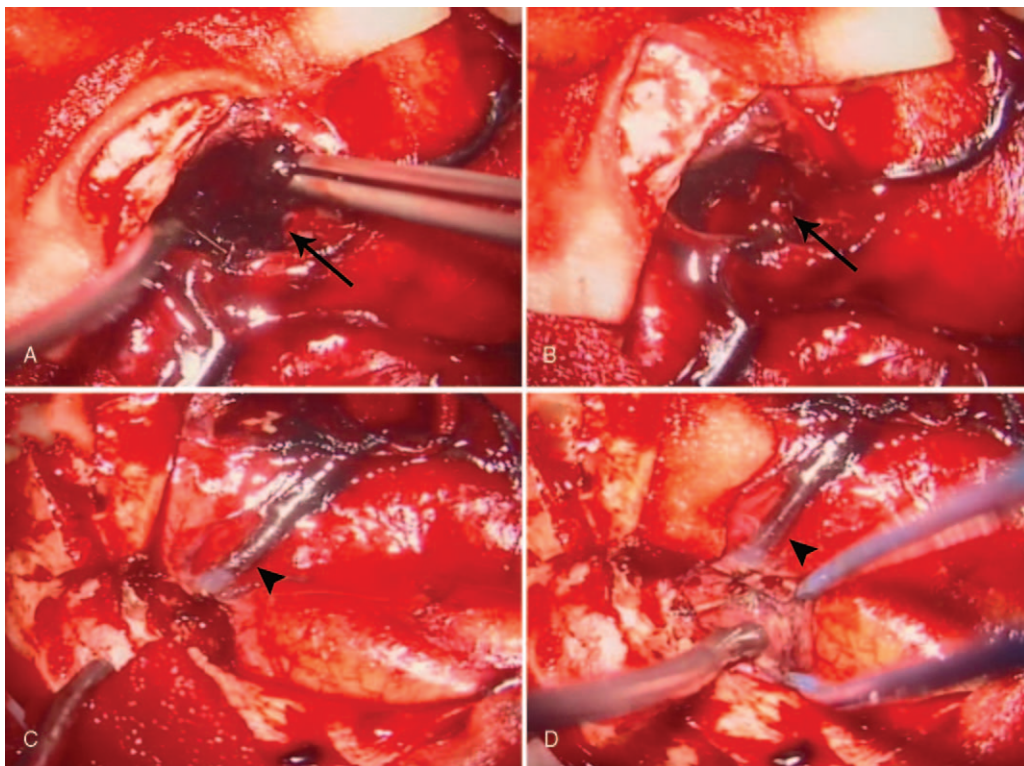


**Figure 2.** Computed tomography scan shows the left occipital parietal hematoma (arrow) and midline shift (dovetail arrows) after the first surgery. High-density signals are visible in the left occipital parietal lobe. The lateral ventricle and midline structures are compressed and moved to the right. The surrounding edema is evident.

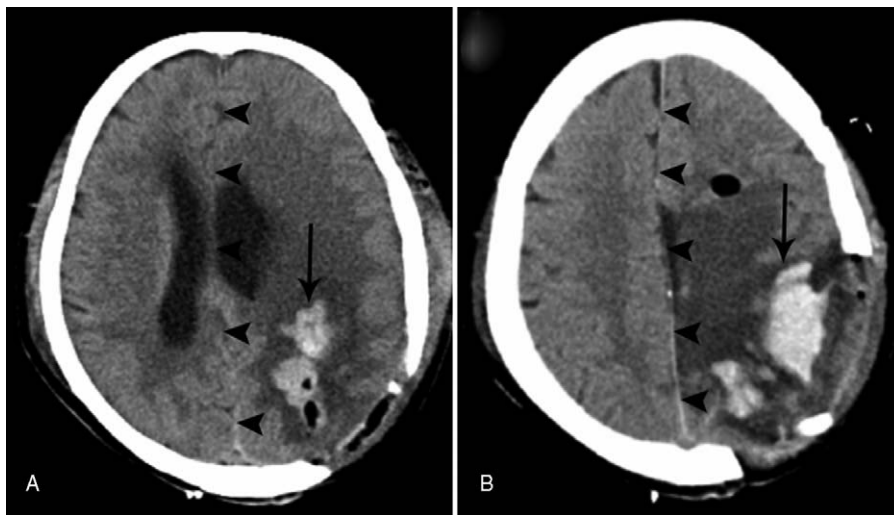
uncertain.<sup>[5,6]</sup> For supratentorial cysts, improvement in symptoms after surgery was significantly associated with a reduction in cyst volume after surgery. A prospective study concluded that fenestration/resection surgery is controversial in the absence of cerebrospinal fluid-pathway blockage and objective signs and symptoms.<sup>[6,7]</sup>

There are no significant differences in the rate of symptom remission and reoperation, change in cyst size after 6 months of surgery, and mortality and disability rates among different operative approaches.<sup>[8]</sup> The shunt operation is relatively simple

and involves slight injury; however, shunt-dependent and shunt-related complications may occur, such as infection, blockage, low intracranial pressure, and intracranial hemorrhage.<sup>[9]</sup> Cystectomy can quickly relieve symptoms, but the risk of surgery is higher, and the surgical incision is larger than that associated with fenestration and shunt surgery. In recent years, due to the improvement of endoscopic techniques, endoscopic cyst fenestration has been increasingly performed, especially for lesions in the skull base, midline, and middle cranial fossa, where direct craniotomy is difficult or may lead to extensive trauma. The



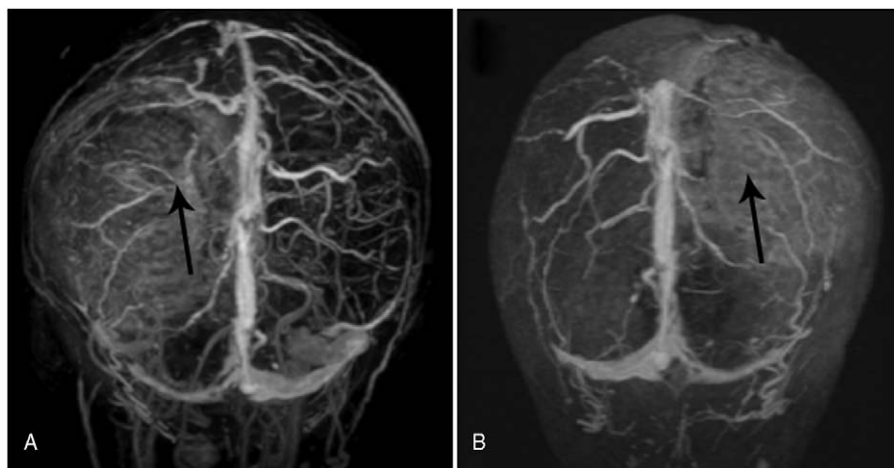
**Figure 3.** Intraoperative photos show the hematoma (arrow) and a big broken vein (dovetail arrows) at the cortical fistula.



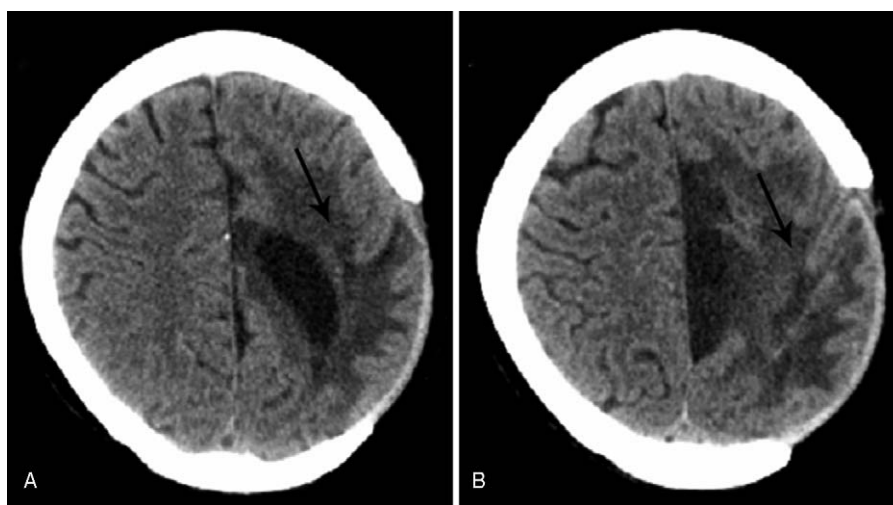
**Figure 4.** Computed tomography scan after the second surgery shows reduced cerebral hematoma (arrow) in the left parietal and occipital lobes and midline shift (dovetail arrows). Scattered high-density signals are observed in the left occipital parietal lobe. The lateral ventricle and midline structures are slightly compressed and moved to the right. The surrounding edema is persistent.

advantage of endoscopy is that it allows more-direct access to the cyst, is less invasive, and involves less-serious complications than other procedures.<sup>[10–12]</sup> The stoma of cysts should be large enough to reduce damage to the surrounding structure, and the cyst should be opened to the adjacent cistern and ventricle. The endoscope uses high-definition and stereovision systems to observe the arachnoid cyst and its adjacent structure and can provide a simple and minimally invasive method for cyst-brain fistulas. Although some researchers believed that the recurrence rate after endoscopic surgery was high, a series of studies on endoscopic fenestration for arachnoid cysts reported a complication rate of 18.8% to 20.0% and a reoperation rate of 3.7% to 12.5%.<sup>[13–15]</sup> These complications are mainly short-term and include cerebrospinal fluid leakage, meningitis, subdural effusion, and subdural hematoma.<sup>[4]</sup> However, there are some limitations to neuroendoscopic fenestration. First, the maximum depth of endoscopy is 20 mm, which limits the depth of the field,

and its transmission is through 2-dimensional images. Therefore, it is difficult to fully understand the entire spatial structure. For such large cysts, the wide, effective irradiation distance of the scope is not sufficient to fully realize the cyst wall and capsule structure in all directions due to the complex situation within the capsule; thus, it is difficult to define the specific anatomical position of the cyst. In such situations, stereotactic navigation systems may be helpful.<sup>[16]</sup> Second, the endoscopic field of vision is small, and there is a fish-eye-like distortion. In the absence of neuronavigation, it is necessary to repeatedly observe the cyst carefully from all angles in order to visualize the entire cyst and avoid vascular injury during operation, as high blood flow will quickly fill the cyst and cause unclear vision. It is difficult to control bleeding effectively and restore a clear view in a short time. Hence, it is very important to use 2 surgical instruments at the same time, which requires a large bone window and consequently reduces the advantage of endoscopy. Third, even



**Figure 5.** Magnetic resonance venography shows a lack of the big drainage vein in the left occipital parietal region (arrow). The superior sagittal sinus, sinus confluence, superficial cerebral vein, internal cerebral vein, great vein, straight sinus, and inferior sagittal sinus are present. No filling defect is seen.



**Figure 6.** Computed tomography scan shows that the cerebral hematoma has almost disappeared 3 months later in the left parietal and occipital lobes (arrow). A few high-density signals are seen in the left occipital parietal lobe. The surrounding edema is significantly reduced. Left meningoencephalocele is seen.

for neuronavigation, accurate positioning is difficult owing to the spontaneous cystic fluid release and brain tissue retraction in the process of surgery. In such situations, craniotomy is a better option than endoscopy for the entire lesion.

Postoperative subdural hematoma after surgery for arachnoid cysts has been reported occasionally, but the occurrence of intracerebral hematoma as a complication is very rare. In our literature review, only 1 case of such an occurrence was reported; the cause of the hematoma was reperfusion injury that occurred after reduction of the intracranial pressure and damage to the bridging vein caused by displacement of the cysts after their release.<sup>[17]</sup> In our case, the patient had clear symptoms, and the surgical indications were clear. However, this complication after surgery was serious and rare and should therefore be registered in the literature. We learned several lessons from this case. First, the choice of surgical method is important. Some researchers believed that craniotomy had a higher risk of subdural effusion and hematoma than endoscopy. However, according to previous studies, endoscopy did not show any significant advantage in this regard. In a study with an average follow-up of 6.9 years, Shim et al<sup>[9]</sup> reviewed 209 patients with cranial arachnoid cysts who underwent endoscopic or open surgery and found no significant differences in the postoperative complications. However, the success rate of neuroendoscopic fenestration is 75%, whereas that of microsurgical fenestration is 92%. Shim et al<sup>[9]</sup> recommend the use of microsurgical fenestration for the treatment of arachnoid cysts near the cortex of the temporal or occipital lobe. Second, the choice of the surgical position is crucial. To further clarify the direction and minimize structural damage, preoperative MRV and diffusion tensor imaging (DTI) are recommended and the routes should be planned accordingly to avoid important venous structures and nerve fibers. If these examinations cannot be completed, we suggest that the bone flap/bone hole be made far away from the midline and functional area to reduce the possibility of damage to the venous trunk and brain tissue. In our case, injury to the vein trunk during endoscopic advancement was the main reason for postoperative repeated bleeding and persistent edema. Third, cut-off of the big vein (postcentral sulcus vein) should be considered. Congestion of large veins is the main reason for repeated cerebral hemorrhage

and brain swelling. We suggest accurately enlarging the bone hole. If a big vein is blocked, a gelatin sponge should be placed over it to cover it and a new position should be selected for a new bone window, which may help reduce or even avoid postoperative complications. Fortunately, in our case, immediately after the hematoma was resolved and the bone flap was removed, the patient was finally cured with no serious neurological deficits.

## 6. Conclusion

Intracerebral hematomas are a rare complication after the surgery of arachnoid cysts. Our patient developed this complication as a result of a big broken vein during endoscopic fenestration, which led to rapid deterioration of her condition. We recommend more-adequate preoperative examinations such as MRV and DTI, which can provide a better understanding of the structure surrounding the lesion. Neuronavigation is recommended, especially for endoscopic fenestration, which would help choose a safe operative direction. Properly enlarging the bone hole during surgery is important for distinguishing the structure. Finally, rapid reoperation is the most-important salvage for intracerebral hematoma, which led to a good outcome in our patient.

## Author contributions

**Conceptualization:** Bing Qin, Lin Wang, Gao Chen.

**Resources:** Junwen Hu.

**Supervision:** Gao Chen.

**Validation:** Gao Chen.

**Writing – original draft:** Bing Qin, Liansheng Gao.

**Writing – review & editing:** Lin Wang.

## References

- [1] Vernooij MW, Ikram MA, Tanghe HL, et al. Incidental findings on brain MRI in the general population. *N Engl J Med* 2007;357:1821–8.
- [2] Al-Holou WN, Yew AY, Boomsaad ZE, et al. Prevalence and natural history of arachnoid cysts in children. *J Neurosurg Pediatr* 2010;5:578–85.
- [3] Karabatsou K, Hayhurst C, Buxton N, et al. Endoscopic management of arachnoid cysts: an advancing technique. *J Neurosurg* 2007; 106(6 suppl):455–62.

- [4] Xu S, Wang Y, Luo Q, et al. Endoscopic fenestration of twenty-six patients with middle fossa arachnoid cyst. *J Craniofac Surg* 2016;27:973–5.
- [5] Helland CA, Wester K. A population based study of intracranial arachnoid cysts: clinical and neuroimaging outcomes following surgical cyst decompression in adults. *J Neurol Neurosurg Psychiatry* 2007;78:1129–35.
- [6] Wang Y, Wang F, Yu M, et al. Clinical and radiological outcomes of surgical treatment for symptomatic arachnoid cysts in adults. *J Clin Neurosci* 2015;22:1456–61.
- [7] Rabiei K, Hogfeldt MJ, Doria-Medina R, et al. Surgery for intracranial arachnoid cysts in children—a prospective long-term study. *Childs Nerv Syst* 2016;32:1257–63.
- [8] Ali M, Bennardo M, Almenawer SA, et al. Exploring predictors of surgery and comparing operative treatment approaches for pediatric intracranial arachnoid cysts: a case series of 83 patients. *J Neurosurg Pediatr* 2015;16:275–82.
- [9] Shim KW, Lee YH, Park EK, et al. Treatment option for arachnoid cysts. *Childs Nerv Syst* 2009;25:1459–66.
- [10] Azab WA, Almanabri M, Yosef W. Endoscopic treatment of middle fossa arachnoid cysts. *Acta Neurochir (Wien)* 2017;159:2313–7.
- [11] Oertel JM, Wagner W, Mondorf Y, et al. Endoscopic treatment of arachnoid cysts: a detailed account of surgical techniques and results. *Neurosurgery* 2010;67:824–36.
- [12] Zhao P, Wang X, Li C, et al. The effectiveness of neuroendoscopic versus non-neuroendoscopic procedures in the treatment of lateral ventricular cysts: a retrospective medical record review study. *BMC Neurol* 2013;13:59.
- [13] Spacca B, Kandasamy J, Mallucci CL, et al. Endoscopic treatment of middle fossa arachnoid cysts: a series of 40 patients treated endoscopically in two centres. *Childs Nerv Syst* 2010;26:163–72.
- [14] Gui SB, Wang XS, Zong XY, et al. Assessment of endoscopic treatment for middle cranial fossa arachnoid cysts. *Childs Nerv Syst* 2011;27:1121–8.
- [15] Couvreur T, Hallaert G, Van Der Heggen T, et al. Endoscopic treatment of temporal arachnoid cysts in 34 patients. *World Neurosurg* 2015;84:734–40.
- [16] Turhan T, Ersahin Y, Akinturk N, et al. Fenestration methods for Sylvian arachnoid cysts: endoscopy or microsurgery. *Childs Nerv Syst* 2012;28:229–35.
- [17] Auschwitz T, DeCuypere M, Khan N, et al. Hemorrhagic infarction following open fenestration of a large intracranial arachnoid cyst in a pediatric patient. *J Neurosurg Pediatr* 2015;15:203–6.