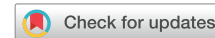

# Unusual case of late dislodgment of a superior vena cava coil



Taya V. Glotzer, MD, FACC, FHRS,\* Monali Shah, DO,<sup>†</sup> Shashank Jain, MD,<sup>†</sup>  
John M. Zimmerman, MD\*

From the \*Hackensack University Medical Center, Hackensack, New Jersey, and <sup>†</sup>Rutgers New Jersey Medical School, Newark, New Jersey.

## Introduction

Implantable cardioverter-defibrillators (ICDs) are routinely used for primary and secondary prevention of arrhythmia-related deaths in patients with heart failure and reduced left ventricular ejection fraction.<sup>1-3</sup> Complications that occur during transvenous ICD implantation have been well described in the literature and include early complications such as pocket hematoma, pocket or lead infection, lead dislodgment, myocardial perforation, postoperative arrhythmia, and pericardial effusion with or without tamponade.<sup>3,4</sup> Late complications include lead fracture and pocket or lead infection, but rarely lead dislodgment. This case report describes an unusual case of late superior vena cava (SVC) coil dislodgment.

## Case report

A 48-year-old man with a nonischemic cardiomyopathy underwent ICD implant at an outside institution for primary prevention of sudden cardiac death. The ICD was a Biotronik Inventra 7 VR-T DX with a single-coil VDD ICD lead. The maximum output of this device is 45 J. Defibrillation threshold (DFT) testing at implant showed the following results during 3 separate ventricular fibrillation (VF) inductions: failed 35 J, failed 40 J, failed 40 J with reversed polarity. In each case the patient was rescued with an external defibrillator. Because of the high DFT, implanting physicians chose to add an additional SVC coil, which was placed in the innominate vein. After the coil was added, successful defibrillation was achieved with 35 J reversed polarity. A postimplant chest radiograph is shown in [Figure 1](#). In the operative report from the outside institution, there was no mention of a requirement to reposition the SVC coil proximally to achieve adequate DFT.

---

**KEYWORDS** Defibrillation threshold testing; ICD implantation; ICD programming; Lead dislodgment; SVC coil  
(Heart Rhythm Case Reports 2018;4:405-407)

---

**Address reprint requests and correspondence:** Dr Taya V. Glotzer, Hackensack University Medical Center, 20 Prospect Ave, Suite 701, Hackensack, NJ 07601. E-mail address: [TayaVG@aol.com](mailto:TayaVG@aol.com).

The patient was discharged on the following day and had an uneventful postoperative course. Approximately 1 year after the ICD implant, the patient had a routine chest radiograph at our institution that showed stable position of the ICD leads ([Figure 2](#)). He continued to be treated for his heart failure with the addition of intravenous (IV) milrinone.

Six months later (18 months after the initial implant) the patient presented to our institution with another exacerbation of his congestive heart failure. A chest radiograph from the emergency room is shown in [Figure 3](#).

The patient had never required any ICD shocks to treat ventricular arrhythmias. He had no complaints other than shortness of breath and exercise intolerance. Specifically, there were no complaints in his left neck.

On physical examination his blood pressure was 135/86, pulse 96 beats/min. The patient had 2+ jugular vein distention bilaterally, bibasilar crackles, and 2+ pedal edema bilaterally. Heart sounds were regular, tachycardic, and distant. There were no visible abnormalities of the left neck other than jugular vein distention, but with deep palpation, the SVC coil lead could be felt under the subcutaneous tissues in the region of the left internal jugular vein. There was no decreased range of motion of the neck, or any pain with neck movement. The site of the ICD can in the left pectoral region was well healed.

Because the displaced SVC coil lead was not causing any symptoms for the patient, we elected to attempt DFT testing with the SVC coil OFF, using the right ventricular (RV) coil and can alone to potentially avoid a surgical procedure. Although that configuration had failed in the past, we thought it worth trying again after the prolonged therapy with IV milrinone, and after several days of diuresis in the hospital. We performed the DFT testing in the operating room on the fourth hospital day, so that in the event the DFT was not adequate, we could immediately move to reposition or replace the SVC coil.

The patient was placed on the operating table with R2 pads in optimal anteroposterior position. After the patient was sedated by anesthesia, VF was induced with a T-wave synchronized shock. VF was appropriately sensed and was successfully defibrillated to sinus rhythm with a 38 J biphasic

## KEY TEACHING POINTS

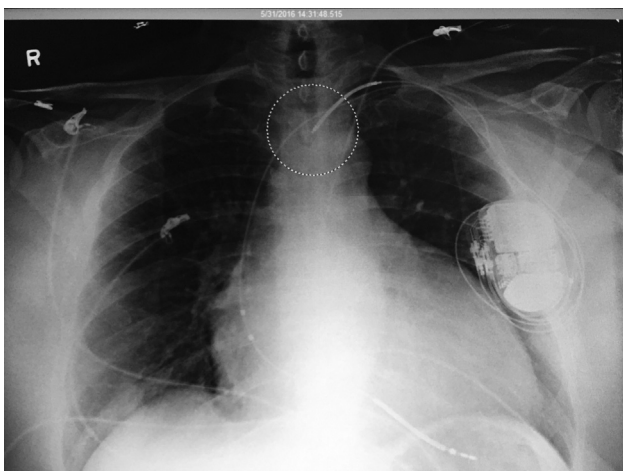
- When implantable cardioverter-defibrillator (ICD) system parameters are out of range, or failure to defibrillate is seen, search for ICD system reprogramming options before jumping to reoperation.
- Look carefully at all diagnostic testing obtained in patients with implanted devices, even when the indication for the diagnostic study had nothing to do with the device.
- Implant superior vena cava (SVC) coils somewhat distally, leaving part of the coil in the SVC to avoid proximal dislodgment.

shock reversed polarity. The shock impedance was 51 ohms. We elected to leave the ICD programmed with the SVC coil OFF and leave the electrically abandoned SVC coil in the dislodged location to avoid a surgical procedure with its risks of infection and bleeding. Final device programming was first shock at 38 J and all subsequent shocks at max output of 45 J. The pacemaker was programmed VVI lower rate at 40 beats/min to avoid RV pacing.

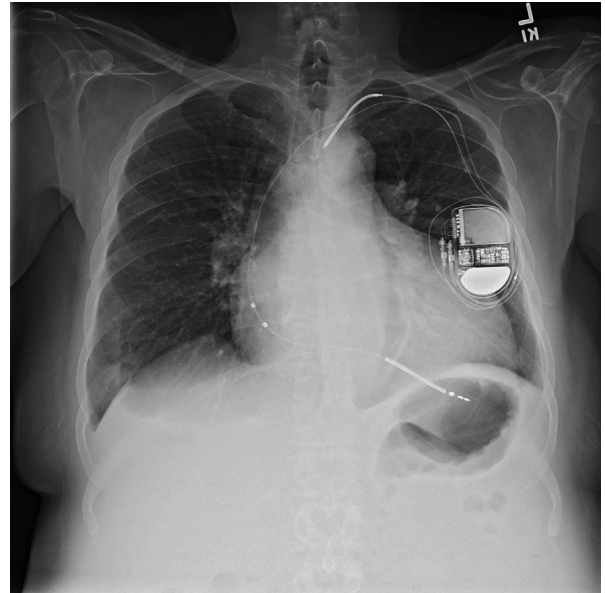
## Discussion

This is an unusual case of an SVC coil that dislodged from the innominate vein into the left internal jugular vein over a year after initial device implant, caused no symptoms, and was discovered only incidentally. As shown, the SVC coil was left quite proximally at initial implant; this case report can serve to caution implanters to position these coils more distally to avoid this rare complication.

Studies have reported the incidence of implanted lead dislodgment to be between 2% and 20.7%.<sup>5-8</sup> In 1995, 1



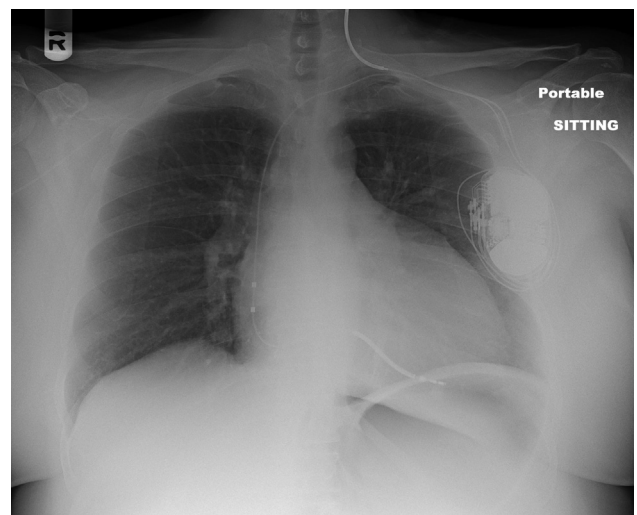
**Figure 1** Postimplant chest radiograph.



**Figure 2** Chest radiograph 1 year post implant showing stable position of the implantable cardioverter-defibrillator leads.

series described dislodgment of SVC coils migrating distally, with the SVC coils ending up in the right atrium despite being “adequately” sutured in the pectoral region. Both of those cases occurred approximately 3 months after implant and required reoperation to achieve adequate DFTs.<sup>7</sup> In a study of the incidence of venous obstruction after ICD implant, it was noted that patients with a dual-coil ICD lead had an increased incidence of venous obstruction, at 44%, over those with an RV coil ICD lead and a separate SVC coil lead, at 17%.<sup>9</sup>

Other studies have reported on dislodgments of leads other than the SVC coil. Lee and colleagues<sup>8</sup> conducted a



**Figure 3** Chest radiograph from the patient's visit to emergency room 18 months post implant.

prospective multicenter study evaluating early complications post ICD implantation in total of 3340 patients; 57 (1.7%) patients had lead dislodgements. Ghani and colleagues<sup>10</sup> reported a 4.4% (86/3903) incidence of reoperation for lead revision that was more common in younger and male patients; right atrial and ICD leads had the highest risk of dislodgment. Takahashi and colleagues<sup>6</sup> conducted a study comparing lead dislodgment in single-chamber vs dual-chamber ICDs in 178 consecutive patients. Of the 178 patients, 5 (3%) were found to have lead dislodgments. One occurred in the RV lead of the single-chamber ICD group, and the other 4 were atrial lead dislodgments in the dual-chamber ICD group; mean time to lead dislodgment was  $6 \pm 5$  months.

There is currently controversy about doing DFT testing during initial ICD implantation. The risks of performing DFT testing include inability to terminate ventricular tachycardia/VF, systemic shock leading to cardiac arrest, risk of hypoperfusion to the vital organs, stroke, and death.<sup>11</sup> Other factors that can impact DFT testing thresholds include procedural complications such as pneumothorax, medications such as amiodarone and anesthetic medicines that are administered during the implant procedure,<sup>12</sup> shock waveform (monophasic vs biphasic),<sup>13</sup> and cardiac mass. Patients with decreased left ventricular function have the highest risk of developing pump failure. One Canadian study showed that in over 19,000 ICD implants, the incidence of DFT testing–related death was 0.016%, DFT testing–related stroke was 0.026%, and DFT testing–related prolonged resuscitation was 0.14%.<sup>11</sup>

The recently published NORDIC<sup>14</sup> (1077 patients) and SIMPLE<sup>15</sup> trials (2500 patients) showed noninferiority of eliminating DFT testing for initial ICD implants in long-term follow-up. The studies showed that DFT testing is generally well tolerated but does not improve clinical shock efficacy or reduce arrhythmic death. However, the benefits of performing DFT testing include assessing the integrity of the entire system and detecting high DFTs that may require surgical modification. Each individual case should be assessed to determine the risks and possible benefits of DFT testing to determine if DFT should be performed. In the case presented here, we felt it prudent to assess the DFT because of the prior history of inadequate DFT and possible need for SVC coil repositioning. We were able to eliminate or “turn off” the SVC coil from the DFT circuit, and achieve an adequate DFT. We hypothesize that after therapy with IV milrinone for a period of time, the heart improved somewhat to achieve a lower DFT than was measured at initial implant.

## Conclusion

In the present case report, we describe a rare proximal migration of an SVC coil into the internal jugular vein that occurred more than a year after the initial implant, was discovered fortuitously, caused no symptoms, and was successfully managed with reprogramming of the device to exclude SVC coil.

## References

1. Yancy CW, Jessup M, Bozkurt B, et al. 2017 ACC/AHA/HFSA Focused Update of the 2013 ACCF/AHA Guideline for the Management of Heart Failure: A Report of the American College of Cardiology/American Heart Association Task Force on Clinical Practice Guidelines and the Heart Failure Society of America. *J Card Fail* 2017;23:628–651.
2. van Rees JB, de Bie MK, Thijssen J, Borleffs CJ, Schalij MJ, van Erven L. Implantation-related complications of implantable cardioverter-defibrillators and cardiac resynchronization therapy devices: a systematic review of randomized clinical trials. *J Am Coll Cardiol* 2011;58:995–1000.
3. Bardy GH, Lee KL, Mark DB, et al. Amiodarone or an implantable cardioverter-defibrillator for congestive heart failure. *N Engl J Med* 2005;352:225–237.
4. Moss AJ, Zareba W, Hall WJ, Klein H, Wilber DJ, Cannom DS, Daubert JP, Higgins SL, Brown MW, Andrews ML. Multicenter Automatic Defibrillator Implantation Trial III. Prophylactic implantation of a defibrillator in patients with myocardial infarction and reduced ejection fraction. *N Engl J Med* 2002;346:877–883.
5. Ascoeta MS, Marijon E, Defaye P, et al. Impact of early complications on outcomes in patients with implantable cardioverter-defibrillator for primary prevention. *Heart Rhythm* 2016;13:1045–1051.
6. Takahashi T, Bhandari AK, Watanuki M, Cannom DS, Sakurada H, Hiraoka M. High incidence of device-related and lead-related complications in the dual-chamber implantable cardioverter defibrillator compared with the single-chamber version. *Circ J* 2002;66:746–750.
7. Korte T, Jung W, Spehl S, Wolpert C, Moosdorf R, Manz M, Luderitz B. Incidence of ICD lead related complications during long-term follow-up: comparison of epicardial and endocardial electrode systems. *Pacing Clin Electrophysiol* 1995; 18:2053–2061.
8. Lee DS, Krahn AD, Healey JS, et al. Evaluation of early complications related to De Novo cardioverter defibrillator implantation insights from the Ontario ICD database. *J Am Coll Cardiol* 2010;55:774–782.
9. Lickfett L, Bitzen A, Arepally A, Nasir K, Wolpert C, Jeong KM, Krause U, Schimpf R, Lewalter T, Calkins H, Jung W, Luderitz B. Incidence of venous obstruction following insertion of an implantable cardioverter defibrillator. A study of systematic contrast venography on patients presenting for their first elective ICD generator replacement. *Europace* 2004;6:25–31.
10. Ghani A, Delnoy PP, Ramdat Misier AR, Smit JJ, Adiyaman A, Ottervanger JP, Elvan A. Incidence of lead dislodgement, malfunction and perforation during the first year following device implantation. *Neth Heart J* 2014;22:286–291.
11. Birnie D, Tung S, Simpson C, et al. Complications associated with defibrillation threshold testing: the Canadian experience. *Heart Rhythm* 2008;5:387–390.
12. Hohnloser SH, Dorian P, Roberts R, Gent M, Israel CW, Fain E, Champagne J, Connolly SJ. Effect of amiodarone and sotalol on ventricular defibrillation threshold: the optimal pharmacological therapy in cardioverter defibrillator patients (OPTIC) trial. *Circulation* 2006;114:104–109.
13. Feerer SA, Tang AS, Kavanagh KM, Rollins DL, Smith WM, Wolf PD, Ideker RE. Strength-duration and probability of success curves for defibrillation with biphasic waveforms. *Circulation* 1990;82:2128–2141.
14. Bansch D, Bonnemeier H, Brandt J, Bode F, Svendsen JH, Felk A, Hauser T, Wegscheider K, NORDIC ICD Trial Investigators. The NO Regular Defibrillation testing In Cardioverter Defibrillator Implantation (NORDIC ICD) trial: concept and design of a randomized, controlled trial of intra-operative defibrillation testing during de novo defibrillator implantation. *Europace* 2015;17:142–147.
15. Healey JS, Hohnloser SH, Glikson M, et al. Cardioverter defibrillator implantation without induction of ventricular fibrillation: a single-blind, non-inferiority, randomised controlled trial (SIMPLE). *Lancet* 2015;385:785–791.