

## Case Report



# Intraoperative Traction May Induce Acute Onset Dysphagia With Diffuse Idiopathic Skeletal Hyperostosis After Anterior Cervical Discectomy

Jung Hoon Sul , Joochul Yang , and Tae Wan Kim

Department of Neurosurgery, VHS Medical Center, Seoul, Korea



**Received:** Nov 10, 2021  
**Revised:** Jan 14, 2022  
**Accepted:** Jan 17, 2022  
**Published online:** Feb 17, 2022

### Address for correspondence:

**Tae Wan Kim**  
Department of Neurosurgery, VHS Medical Center, 53 Jinhwangdo-ro 61-gil, Gangdong-gu, Seoul 05368, Korea.  
Email: euro3399@naver.com

Copyright © 2022 Korean Neurotraumatology Society

This is an Open Access article distributed under the terms of the Creative Commons Attribution Non-Commercial License (<https://creativecommons.org/licenses/by-nc/4.0/>) which permits unrestricted non-commercial use, distribution, and reproduction in any medium, provided the original work is properly cited.

### ORCID iDs

Jung Hoon Sul   
<https://orcid.org/0000-0002-2036-7382>  
Joochul Yang   
<https://orcid.org/0000-0002-4496-937X>  
Tae Wan Kim   
<https://orcid.org/0000-0001-7650-3331>

### Conflict of Interest

The authors have no financial conflicts of interest.

## ABSTRACT

Diffuse idiopathic skeletal hyperostosis (DISH) is a systemic bone-forming disease, and its pathogenesis remains unknown. Moreover, the incidence of DISH increases with age. DISH may be an age-related disorder that occurs more frequently in degenerative spines than in healthy spines. Most patients with DISH of the cervical spine are asymptomatic; however, mechanical compression of the esophagus by the cervical spine can induce dysphagia, hoarseness, and dyspnea. In most cases, dysphagia progresses slowly. Most cases of postoperative dysphagia after anterior cervical spine surgery occurred within 1 month, and most patients recovered spontaneously. Severe dysphagia is relatively uncommon. Here, we report a case of acute-onset dysphagia with DISH that occurred immediately after anterior cervical discectomy. We should consider the possibility of dysphagia occurring immediately after anterior cervical discectomy in patients with DISH, even in those without dysphagia before surgery. Furthermore, surgical treatment for severe postoperative dysphagia associated with DISH may be a good option.

**Keywords:** Discectomy; Cervical spine; Dysphagia; Hyperostosis

## INTRODUCTION

Diffuse idiopathic skeletal hyperostosis (DISH) is a systemic bone-forming disease of ligaments and entheses, and its pathogenesis remains unknown. DISH commonly occurs in old age and is common in men,<sup>2,5,9)</sup> although the prevalence of DISH is quite variable. DISH can be diagnosed using radiography and computed tomography (CT). Moreover, DISH is radiologically diagnosed based on the presence of flowing calcification and ossification on the anterior aspects of the vertebral body for more than 4 continuous vertebrae and a relatively well-preserved disc height without disc degeneration on the involved segment.<sup>12)</sup> The thoracic spine is the most commonly body part involved.<sup>2)</sup> Fused vertebrae are most commonly found in the lower thoracic spine.<sup>17)</sup> However, complete bridging of the disc space in the cervical spine is not common.<sup>17)</sup> The most common symptoms of DISH in the spine are rigidity, motion limitation, axial pain, and dysphagia owing to direct compression of the esophagus. Symptomatic DISH of the cervical spine induces dysphagia, dysphonia, dyspnea, and reduced range of motion. Most patients with DISH of the cervical spine are asymptomatic, but mechanical compression of the esophagus induces dysphagia. The risk

factors associated with induction of DISH symptoms are unknown. The mean duration between symptoms such as dysphagia or airway obstruction owing to DISH and radiological diagnosis is approximately 500 days.<sup>19)</sup> In most cases, dysphagia progresses slowly. DISH-related dysphagia is commonly associated with osteophytes at the C3–C5 level.<sup>4)</sup> Therefore, surgical removal of DISH is an effective treatment option for dysphagia.<sup>3,4,7,8)</sup>

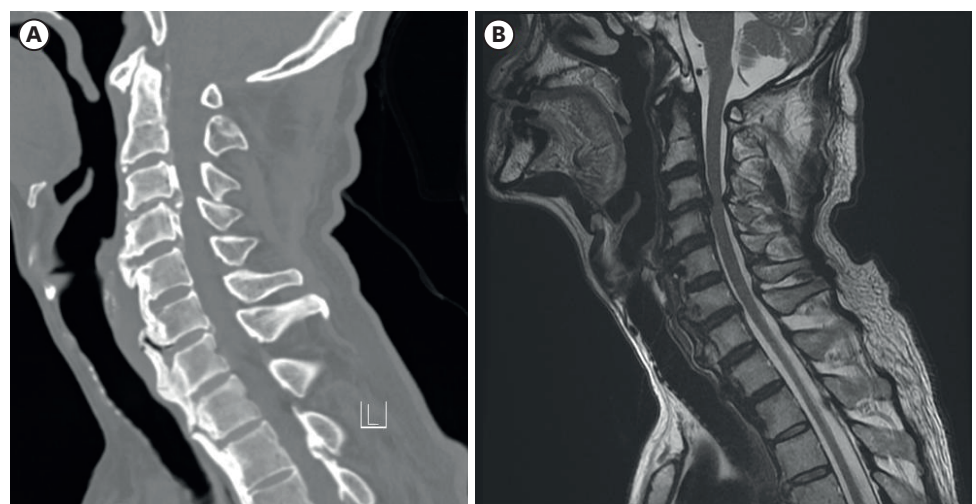
Most cases of postoperative dysphagia in anterior cervical spine surgery occurred within 1 month and most patients recovered spontaneously. Severe dysphagia is relatively less common in these cases.<sup>20)</sup>

In this study, we report a case of acute onset severe dysphagia with DISH occurring immediately after anterior cervical discectomy, although difficulty in swallowing was absent before surgery. Dysphagia may have occurred because of the repositioning of the tracheoesophageal complex after traction during the operation. During this process, osteophytes may directly compress the esophagus.

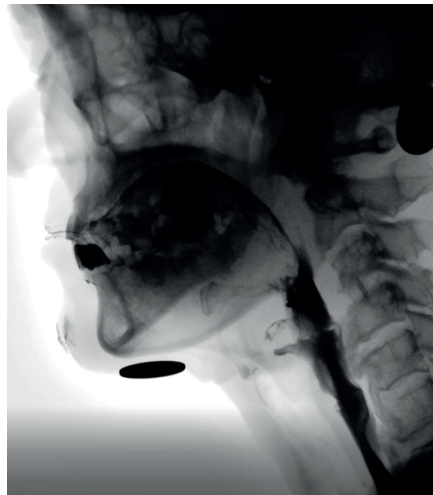
## CASE REPORT

A 69-year-old man was admitted to our department because of neck and left deltoid pain. CT and magnetic resonance imaging showed a protruding disc at the C3–C4 level and ossification and osteophytes along the anterior aspect of the cervical spine (**FIGURE 1**). He did not complain of dysphagia, hoarseness, or dyspnea.

Anterior cervical discectomy and fusion (ACDF) at the C3–C4 level was performed. Using the right-side approach, the longus coli muscle was retracted and anchored in the medial-to-lateral direction using a Caspar retractor. The rostrocaudal retractor system was placed in position. Then, Caspar pins were placed in the midline of the C3 and C4 bodies and retracted using a Caspar pin spreader. The degree of traction was as in the usual manner and not excessively pulled. After the operation, the pain was gradually relieved, but, dysphagia and hoarseness occurred immediately postoperatively. Laryngoscopic examination revealed no vocal cord paralysis. Endoscopic examination revealed no esophageal injuries. Hoarseness



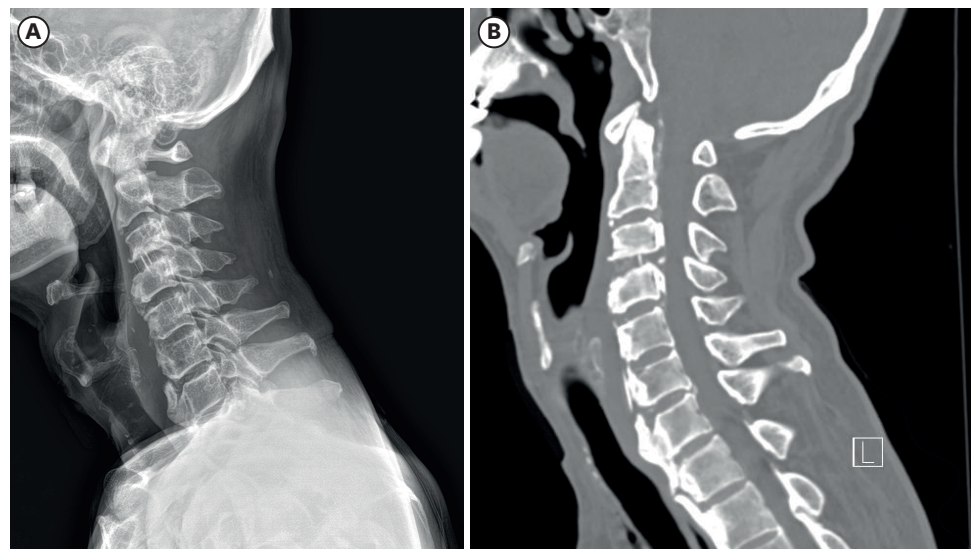
**FIGURE 1.** Computed tomography (A) and magnetic resonance imaging (B) showing protruding disc at the C3–C4 level and ossification and osteophytes along the anterior aspect of the cervical spine.



**FIGURE 2.** Video fluoroscopic swallowing test demonstrates mechanical compression effect by cervical spurs at both the C4–C5 and C6–C7 levels.

improved 2 weeks after surgery. Dysphagia was also slightly improved; however, the patient still had difficulty swallowing solid food, thus causing him to vomit. The video fluoroscopic swallowing (VFSS) test showed moderate amounts of vallecular residue and small-to-moderate amounts of pyriform sinus residue in the pharyngeal phase. It also showed a mechanical compression effect by cervical spurs at both the C4–C5 and C6–C7 levels (**FIGURE 2**). Reflux and esophageal deviation to the right side at the C6–C7 level were observed.

One month after ACDF, the patient still had difficulty swallowing solids. He lost weight (approximately 9 kg) after ACDF and complained of general weakness. We decided that conservative treatment was no longer the best option. Therefore, the DISH was removed from C4 to C6. Follow-up lateral radiographs and CT scans showed surgical removal of prominent ossification and osteophytes along the anterior aspect of the cervical vertebrae (**FIGURE 3**). Dysphagia gradually improved daily. Ten days after DISH removal, the follow-up VFSS test showed



**FIGURE 3.** Follow-up lateral view of a radiograph (A) and computed tomographic image (B) showing surgical removal of prominent ossification and osteophytes along the anterior aspect of the cervical vertebrae.

removal of the mechanical effect owing to cervical spur and aspiration improvement. One month after DISH removal, the patient was able to eat all foods without difficulty. We believed that our patient's postoperative dysphagia was related to DISH because of rapid onset, rapid disappearance of symptoms, and definite compression lesion by bony spurs on the VFSS test.

## DISCUSSION

In the case of DISH, hyperostosis of the cortex along the anterior surface of the vertebral body occurred initially. The bony structures gradually elongated across the disc space. During the process, a radiolucent space in front of the disc space was created, called an isolated triangular ossicle that occurred more frequently on the cervical spine.<sup>12)</sup> Bony excrescence on the cervical spine most frequently appears at the C5 and C6 levels.<sup>12)</sup> Among patients with DISH, ossification progressed more in younger patients during the 5-year follow-up periods.<sup>10)</sup> The causes of anterior cervical osteophyte-induced dysphagia include direct compression of the pharynx or esophagus and inflammatory changes in the prevertebral fascia, resulting in fibrosis and adhesion to the esophagus. Therefore, DISH may be a cause of dysphagia and airway obstruction.<sup>19)</sup>

DISH-related dysphagia is uncommon. Surgical treatment is not required for asymptomatic patients with DISH, except in cases of traumatic DISH.<sup>9)</sup> The risk of traumatic fracture in DISH depends on the severity of ossification.<sup>10)</sup> Dysphagia initially presents with difficulty in swallowing solid food, slowly progressing to soft food and liquids. Some authors<sup>3)</sup> have indicated that prevertebral soft tissue thickness (PVST) is more important than the thickness of osteophytes for the occurrence of dysphagia. Most symptomatic patients had problematic levels above C5. The importance of PVST is decreased below the C5 level because the esophagus does not adhere to the trachea below this level. Most cases of symptomatic DISH occur between the C3 and C5 levels because the normal epiglottic tilt lies over the laryngeal inlet at this level.<sup>4)</sup> DISH and spondylosis are the most common causes of anterior cervical hyperosteoophytosis-induced dysphagia.<sup>11)</sup> Conservative treatments include diet control, swallowing exercises, and anti-inflammatory drugs. If conservative treatment fails, direct removal of DISH with preservation of the annulus is recommended for symptomatic cases, and recurrence of DISH is rare. However, recurrence of DISH is also possible, and patients must be informed.<sup>15)</sup> Nevertheless, the prognosis of surgical removal of anterior osteophytes from DISH is good.<sup>18)</sup>

Postoperative dysphagia is a common complication of the anterior approach to the cervical spine. The prevalence of postoperative dysphagia varies and generally occurs within the first postoperative month and progressively disappears over time.<sup>14)</sup> Retraction of esophagus and prevertebral soft tissue during operation, they would be injured and result in severe swelling.<sup>6)</sup> Most postoperative dysphagia recovered within several weeks.<sup>16)</sup> Old age over 60 years, female sex, multilevel surgery, revision surgery, upper level lesions, and use of plates may be risk factors for postoperative dysphagia after anterior cervical spine.<sup>6,16,20)</sup>

The nearest distance between the esophagus and vertebral body is midline, and the larger space between the esophagus and vertebral body is at the medial edge of the longus coli muscles, which is greater than the left.<sup>13)</sup> The etiologies of postoperative dysphagia after the cervical spine via the anterior approach are hematoma formation, vocal cord paralysis, pharyngeal plexus denervation during intraoperative retraction, scar tissue formation

on plate, and mechanical effects of hardware on the posterior laryngopharynx and esophagus.<sup>13)</sup> Overcorrection of sagittal alignment of cervical spine may lead to bulging of the posterior pharyngeal wall, which may reduce pharyngeal space. During this process, normal pharyngeal squeeze and laryngeal elevation are influenced. Postoperative dysphagia is occurred by this mechanism.<sup>6)</sup> Overgrowth of the bone along several vertebrae and focal protruding bony spur of the anterior aspect of the vertebral body may compress the esophagus. Direct compression of the esophagus may impair the neuromuscular mechanism of swallowing, reduce luminal patency, and limit luminal motility and motion of soft tissue over focal area of direct compression may also induce inflammation and edema.<sup>1)</sup> In our case, repositioning of the tracheoesophageal complex may have occurred after traction during the operation. During this process, osteophytes may directly compress the esophagus.

## CONCLUSION

We should consider the possibility of dysphagia immediately after anterior cervical discectomy in patients with DISH, even in the absence of dysphagia before surgery. Furthermore, surgical treatment for severe postoperative dysphagia associated with DISH may be a good option.

## REFERENCES

- Butler AJ, Ghasem A, Al Maaieh M. Dysphagia following lumbar spine surgery in the setting of undiagnosed DISH of the cervical spine: a case report. *AME Case Rep* 3:13, 2019  
[PUBMED](#) | [CROSSREF](#)
- Cammisa M, De Serio A, Guglielmi G. Diffuse idiopathic skeletal hyperostosis. *Eur J Radiol* 27 Suppl 1:S7-S11, 1998  
[PUBMED](#) | [CROSSREF](#)
- Chung YS, Zhang HY, Ha Y, Park JY. Surgical outcomes of dysphagia provoked by diffuse idiopathic skeletal hyperostosis in the cervical spine. *Yonsei Med J* 61:341-348, 2020  
[PUBMED](#) | [CROSSREF](#)
- Egerter AC, Kim ES, Lee DJ, Liu JJ, Cadena G, Panchal RR, et al. Dysphagia secondary to anterior osteophytes of the cervical spine. *Global Spine J* 5:e78-e83, 2015  
[PUBMED](#) | [CROSSREF](#)
- Kuperus JS, Mohamed Hoessein FAA, de Jong PA, Verlaan JJ. Diffuse idiopathic skeletal hyperostosis: etiology and clinical relevance. *Best Pract Res Clin Rheumatol* 34:101527, 2020  
[PUBMED](#) | [CROSSREF](#)
- Lee JH, Paeng SH, Pyo SY, Kim ST, Lee WH. Swallowing difficulty in diffuse idiopathic skeletal hyperostosis with metabolic syndrome. *Korean J Neurotrauma* 16:90-98, 2020  
[PUBMED](#) | [CROSSREF](#)
- Liu J, Hai Y, Kang N, Chen X, Zhang Y. Risk factors and preventative measures of early and persistent dysphagia after anterior cervical spine surgery: a systematic review. *Eur Spine J* 27:1209-1218, 2018  
[PUBMED](#) | [CROSSREF](#)
- Lui Jonathan YC, Sayal P, Prezerakos G, Russo V, Choi D, Casey AT. The surgical management of dysphagia secondary to diffuse idiopathic skeletal hyperostosis. *Clin Neurol Neurosurg* 167:36-42, 2018  
[PUBMED](#) | [CROSSREF](#)
- Mader R, Verlaan JJ, Buskila D. Diffuse idiopathic skeletal hyperostosis: clinical features and pathogenic mechanisms. *Nat Rev Rheumatol* 9:741-750, 2013  
[PUBMED](#) | [CROSSREF](#)
- Murakami Y, Morino T, Hino M, Misaki H, Miura H. Progression of ossification of the anterior longitudinal ligament associated with diffuse idiopathic skeletal hyperostosis by age: a study of computed tomography findings over 5 years. *Global Spine J* 11:656-661, 2021  
[PUBMED](#) | [CROSSREF](#)



11. Oppenlander ME, Orringer DA, La Marca F, McGillicuddy JE, Sullivan SE, Chandler WF, et al. Dysphagia due to anterior cervical hyperosteoehyphosis. *Surg Neurol* 72:266-270, 2009  
[PUBMED](#) | [CROSSREF](#)
12. Resnick D, Niwayama G. Radiographic and pathologic features of spinal involvement in diffuse idiopathic skeletal hyperostosis (DISH). *Radiology* 119:559-568, 1976  
[PUBMED](#) | [CROSSREF](#)
13. Rhyne AL 3rd, Spector LR, Schmidt GL, Madigan L, Odum SM, Darden BV 2nd, et al. Anatomic mapping and evaluation of the esophagus in relation to the cervical vertebral body. *Eur Spine J* 16:1267-1272, 2007  
[PUBMED](#) | [CROSSREF](#)
14. Riley LH 3rd, Vaccaro AR, Dettori JR, Hashimoto R. Postoperative dysphagia in anterior cervical spine surgery. *Spine (Phila Pa 1976)* 35:S76-S85, 2010  
[PUBMED](#) | [CROSSREF](#)
15. Scholz C, Naseri Y, Hohenhaus M, Hubbe U, Klingler JH. Long-term results after surgical treatment of diffuse idiopathic skeletal hyperostosis (DISH) causing dysphagia. *J Clin Neurosci* 67:151-155, 2019  
[PUBMED](#) | [CROSSREF](#)
16. Smith-Hammond CA, New KC, Pietrobon R, Curtis DJ, Scharver CH, Turner DA. Prospective analysis of incidence and risk factors of dysphagia in spine surgery patients: comparison of anterior cervical, posterior cervical, and lumbar procedures. *Spine (Phila Pa 1976)* 29:1441-1446, 2004  
[PUBMED](#) | [CROSSREF](#)
17. Toyoda H, Terai H, Yamada K, Suzuki A, Dohzono S, Matsumoto T, et al. Prevalence of diffuse idiopathic skeletal hyperostosis in patients with spinal disorders. *Asian Spine J* 11:63-70, 2017  
[PUBMED](#) | [CROSSREF](#)
18. Urrutia J, Bono CM. Long-term results of surgical treatment of dysphagia secondary to cervical diffuse idiopathic skeletal hyperostosis. *Spine J* 9:e13-e17, 2009  
[PUBMED](#) | [CROSSREF](#)
19. Verlaan JJ, Boswijk PF, de Ru JA, Dhert WJ, Oner FC. Diffuse idiopathic skeletal hyperostosis of the cervical spine: an underestimated cause of dysphagia and airway obstruction. *Spine J* 11:1058-1067, 2011  
[PUBMED](#) | [CROSSREF](#)
20. Zeng JH, Zhong ZM, Chen JT. Early dysphagia complicating anterior cervical spine surgery: incidence and risk factors. *Arch Orthop Trauma Surg* 133:1067-1071, 2013  
[PUBMED](#) | [CROSSREF](#)