

# Clinical and radiographic outcomes with L4–S1 axial lumbar interbody fusion (AxiaLIF) and posterior instrumentation: a multicenter study

William D Tobler<sup>1</sup>  
Miguel A Melgar<sup>2</sup>  
Thomas J Raley<sup>3</sup>  
Neel Anand<sup>4</sup>  
Larry E Miller<sup>5</sup>  
Richard J Nasca<sup>6</sup>

<sup>1</sup>Department of Neurosurgery, University of Cincinnati College of Medicine, Mayfield Clinic, and The Christ Hospital, Cincinnati, OH, USA;

<sup>2</sup>Department of Neurosurgery, Tulane University, New Orleans, LA, USA;

<sup>3</sup>Advanced Spine and Pain, Arlington, VA, USA; <sup>4</sup>Spine Trauma, Minimally Invasive Spine Surgery Spine Center, Cedars-Sinai Medical Center, Los Angeles, CA, USA; <sup>5</sup>Miller Scientific Consulting, Inc, Arden, NC, USA;

<sup>6</sup>Orthopaedic and Spine Surgery, Wilmington, NC, USA

**Introduction:** Previous studies have confirmed the benefits and limitations of the presacral retroperitoneal approach for L5–S1 interbody fusion. The purpose of this study was to determine the safety and effectiveness of the minimally invasive axial lumbar interbody approach (AxiaLIF) for L4–S1 fusion.

**Methods:** In this retrospective series, 52 patients from four clinical sites underwent L4–S1 interbody fusion with the AxiaLIF two-level system with minimum 2-year clinical and radiographic follow-up (range: 24–51 months). Outcomes included back pain severity (on a 10-point scale), the Oswestry Disability Index (ODI), and Odom's criteria. Flexion and extension radiographs, as well as computed tomography scans, were evaluated to determine fusion status. Longitudinal outcomes were assessed with repeated measures analysis of variance.

**Results:** Mean subject age was  $52 \pm 11$  years and the male:female ratio was 1:1. Patients sustained no intraoperative bowel or vascular injury, deep infection, or neurologic complication. Median procedural blood loss was 220 cc and median length of hospital stay was 3 days. At 2-year follow-up, mean back pain had improved 56%, from  $7.7 \pm 1.6$  at baseline to  $3.4 \pm 2.7$  ( $P < 0.001$ ). Back pain clinical success (ie,  $\geq 30\%$  improvement from baseline) was achieved in 39 (75%) patients at 2 years. Mean ODI scores improved 42%, from  $60\% \pm 16\%$  at baseline to  $35\% \pm 27\%$  at 2 years ( $P < 0.001$ ). ODI clinical success (ie,  $\geq 30\%$  improvement from baseline) was achieved in 26 (50%) patients. At final follow-up, 45 (87%) patients were rated as good or excellent, five as fair, and two as poor by Odom's criteria. Interbody fusion observed on imaging was achieved in 97 (93%) of 104 treated interspaces. During follow-up, five patients underwent reoperation on the lumbar spine, including facet screw removal (two), laminectomy (two), and transforaminal lumbar interbody fusion (one).

**Conclusion:** The AxiaLIF two-level device is a safe, effective treatment adjunct for patients with L4–S1 disc pathology resistant to conservative treatments.

**Keywords:** AxiaLIF, axial presacral fusion, interbody, outcomes, two-level fusion

## Introduction

Patients with disabling back pain, caused by degenerative disc disease or spondylolisthesis, whose symptoms persist for 6 months or longer have a poor prognosis for improvement with conservative management alone.<sup>1–3</sup> Lumbar interbody fusion or disc arthroplasty are therapeutic options for patients with persistent back pain and dysfunction refractory to conservative care; these options can avoid the need to live with disability and potential reliance on chronic analgesics.<sup>4–6</sup> The most commonly performed interbody fusion procedures, including posterior lumbar interbody fusion, transforaminal lumbar interbody fusion, anterior lumbar interbody fusion, and extreme lateral interbody fusion, necessitate the removal of bone and connective tissue support

Correspondence: Larry E Miller  
Miller Scientific Consulting, Inc,  
26 Portobello Road, Arden,  
NC 28704, USA  
Tel +1 928 607 9657  
Fax +1 928 268 3563  
Email larry@millerscientific.com

structures and/or exposure of major neural, vascular, and organ systems. Risks associated with these operations include iatrogenic nerve or organ injury and chronic spinal instability.<sup>7-9</sup>

Fusion procedures via the presacral axial route use the avascular tissue plane of the presacral space to directly access the sacrum and lumbosacral discs, obviating the need to dissect the paraspinous muscles, remove laminae and facet joints, or expose and retract major nerves and vascular structures. Previous studies have confirmed the benefits and limitations of the presacral retroperitoneal approach for L5–S1 interbody fusion.<sup>10-14</sup> However, long-term clinical and radiographic outcomes with L4–S1 axial lumbar interbody fusion (AxiaLIF) are limited. The purpose of this study was to determine the safety and effectiveness of the minimally invasive axial lumbar interbody approach for L4–S1 fusion through 2 years of follow-up.

## Methods

### Patients

In this retrospective series, 52 consecutive patients from four clinical sites underwent L4–L5 and L5–S1 interbody fusion with the AxiaLIF 2L or 2L plus system (TranS1, Inc, Wilmington, NC, USA) from 2008 to 2011, and patients were followed for a minimum of 2 years (mean: 29 months; range: 24–51 months). This research received approval by an institutional review board and the requirement for patient informed consent was waived due to the retrospective nature of the study. Patients underwent at least 6 months of unsuccessful nonoperative treatment before surgical intervention. They presented with varying degrees of back pain and back dysfunction, with 90% self-reporting concomitant radicular symptoms (Table 1). Preoperative imaging confirmed disc

pathology in all patients; degenerative disc disease was reported as the primary diagnosis in 36 (69%) patients, and nine (17%) patients had grade 1 or 2 spondylolisthesis. The presacral approach is contraindicated in patients with previous pelvic surgery, infection, radiation, inflammatory bowel disease, or rectal disease.

### Pretreatment evaluations

Before surgery, all patients underwent physical and neurologic examinations and completed a detailed medical and medication history. Preoperative imaging studies included magnetic resonance imaging, as well as contrast- and noncontrast-enhanced computed tomography (CT) scans in all patients. Discography and/or electromyography were used in some patients. Surgeons followed the Milliman Care Guidelines for lumbar fusion during all procedures.

### Surgical procedure

Patients underwent a two-level interbody fusion procedure with the AxiaLIF system, using an AxiaLIF 2L or 2L plus implant supplemented with facet and pedicle screws. The Food and Drug Administration approved the 2L device in 2008 and the 2L plus in 2010; the four-component AxiaLIF 2L plus rod is designed to provide improved fixation and resistance to subsidence compared with the 2L implant.

The patient was positioned on a radiolucent extension frame (Jackson table) so the hips and knees were extended to maximize lordosis. The presacral plane was entered through an incision at the level of the paracoccygeal notch. Blunt finger dissection to the sacrum provided access for placement of a blunt guide pin on the posterior third of the inferior endplate of the sacrum. Using a preplanned trajectory with templates and anterior–posterior and lateral C-arm images, the surgeon then navigated toward the central portion of the L5 vertebra and the anterior part of the L4 vertebral body (Figure 1A–C).

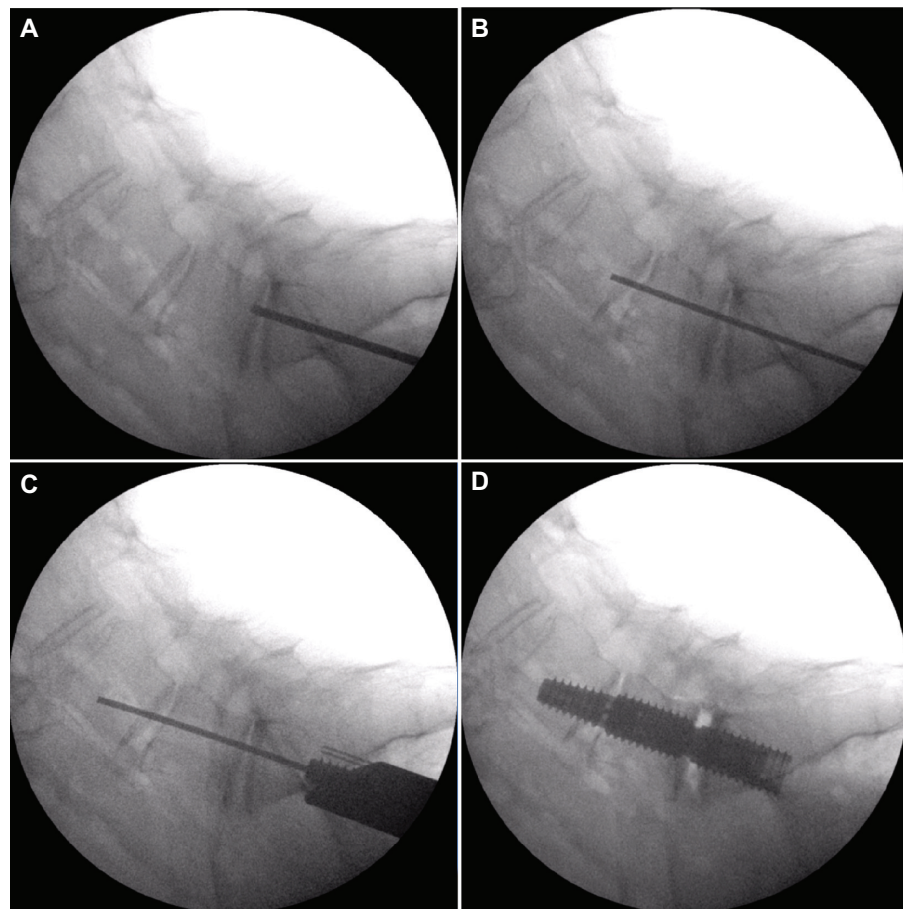
After preparation of a 12 mm bony channel in the sacrum, the L5–S1 disc space was entered. Nitinol cutters were then used to debulk the nucleus pulposus and denude the superior and inferior endplates to bleeding bone. The L4–L5 interspace was similarly prepared and the L4 vertebral body was reamed, taking care not to penetrate the superior endplate of L4. A combination of autogenous bone and bone marrow aspirate from the iliac crest and vertebral bodies was used. Bone graft extenders and allograft bone provided the material for fusion; recombinant human (rh) bone morphogenetic protein (BMP)-2 was used in 34 (65%) patients.

**Table 1** Patient demographics for 52 patients from four clinical sites who underwent two-level fusion with AxiaLIF system

Characteristic	Value
Age (years)	52 ± 11
Male sex	26 (50)
Back pain severity (10-point scale)	7.7 ± 1.6
ODI (%) <sup>*</sup>	60 ± 16
Primary diagnosis	
Degenerative disc disease	36 (69.2)
Spondylolisthesis	9 (17.3)
Spinal stenosis	4 (7.7)
Radiculopathy	2 (3.8)
Revision surgery	1 (1.9)

**Notes:** Values are mean ± SD or n (%). <sup>\*</sup>ODI collected on 33 of 52 patients.

**Abbreviations:** AxiaLIF, axial lumbar interbody fusion; SD, standard deviation; n, number; ODI, Oswestry Disability Index.



**Figure 1** Fluoroscopic views demonstrating the trajectory of the guide pin.

**Notes:** Lateral views show (A) sacral entry point, (B) guide pin across the lumbosacral joint, (C) guide pin advanced into L4, and (D) the final implant position of the two-level AxiaLIF rod.

**Abbreviation:** AxiaLIF, axial lumbar interbody fusion.

A 2L or 2L plus AxiaLIF rod was inserted in the prepared channel (Figure 1D). The rod system can be placed with or without distraction. Distraction of the L5 and L4 pedicle screws was performed against fixed S1 screws to open the resected interspaces and improve sagittal and coronal alignment of the L4 to sacral segments. Posterior instrumentation included pedicle screws and rods in 28 patients, facet screws in 15 patients, and combinations of pedicle and facet screws in nine patients; most of the posterior devices were placed percutaneously.

## Outcomes

Clinical and radiographic outcomes were collected during regularly scheduled office visits 3 months, 6 months, 12 months, and 24 months after surgery. Patient characteristics, procedural blood loss, and hospital stay were recorded. Postoperatively, fusion mass quality and implant stability were assessed with anterior–posterior and lateral radiographs taken in flexion and extension in all patients

and with CT scan in 46 (88%) patients. Two patients who were completely asymptomatic opted not to undergo CT scanning. We defined fusion as the presence of bridging bone from vertebral endplate to endplate that occupied more than 50% of the interspace on CT scan and no motion on flexion–extension films.<sup>12,13</sup> Imaging was evaluated independent of the operating surgeon by neuroradiologists and an orthopedic spine surgeon. At each visit, axial back pain severity was assessed by the patient using a 10-point numeric scale. At two of the four sites, back function was evaluated with the Oswestry Disability Index (ODI).<sup>15</sup> Clinical success for back pain severity and ODI was defined as a 30% or more improvement relative to baseline values.<sup>16</sup> Odom's criteria was used to rate clinical outcomes at 2 years.<sup>17</sup>

## Statistical analyses

Data were analyzed using Predictive Analytics Software (version 18; IBM Corporation, Armonk, NY, USA). Continuous data were reported as the mean  $\pm$  standard

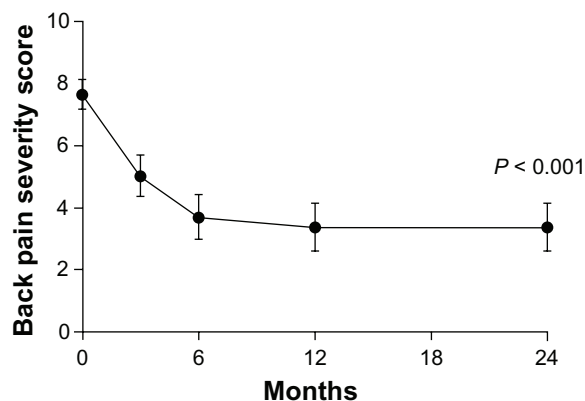
deviation or median (min-max), depending on normality assumptions. Categorical data were reported as frequencies and percentages. Data on back pain severity were available for 48 of 52 patients and ODI data, which were collected at two of the four study sites, are reported for 33 of 52 patients. Longitudinal changes in back pain severity and ODI at each follow-up visit during the 2-year follow-up period were assessed using repeated measures analysis of variance. The threshold for statistical significance was set at  $P < 0.05$ .

## Results

Mean subject age was  $52 \pm 11$  years and the male:female ratio was 1:1. For the 52 patients consecutively treated at four sites (2008–2011), interbody fusion was observed in 97 (93.3%) of 104 treated interspaces at follow-up (range: 24–51 months; mean: 29 months). There were no bowel or vascular injuries, deep infection, neurologic complication, or implant failure.

Complications included bone graft extravasation into the spinal canal in one patient that was successfully removed with laminectomy, resulting in no permanent neurologic deficit. After a L4–L5 nonunion was observed in one patient, reoperation with placement of a transforaminal lumbar interbody fusion cage without removal of the AxiaLIF rod resulted in a solid fusion. Two patients underwent removal of misplaced facet screws. One patient had a laminectomy at 6 months for removal of a BMP-induced cyst, which resulted in relief of radicular symptoms. There were no deep infections. In two patients who developed superficial infections and delayed healing of the presacral incision, local wound care and antibiotics provided resolution. One patient had a retroperitoneal hematoma that resolved without treatment but delayed hospital discharge. Two patients had nonunion at both levels and three patients had nonunion at a single level. To date, only one of the five patients with nonunions, described above, has had additional surgery; none of these patients have had signs of radiographic failure of the AxiaLIF device or posterior instrumentation.

Procedural blood loss ranged from 50 cc to 1,000 cc (median 220 cc) and the length of hospital stay ranged from 0 days to 9 days (median 3 days). During the 2-year follow-up period, the two-level interbody fusion procedure resulted in clinically meaningful improvements in back pain and function. Mean back pain decreased from  $7.7 \pm 1.6$  at baseline to  $3.4 \pm 2.7$  at the 2-year follow-up visit ( $P < 0.001$ ), representing an average improvement of 56% (Figure 2); 75% of patients achieved clinical success. Mean ODI scores improved 42% from  $60\% \pm 16\%$  at baseline to  $35\% \pm 27\%$  at 2 years ( $P < 0.001$ ) (Figure 3). ODI clinical success was realized in



**Figure 2** Back pain severity through 2 years after AxiaLIF surgery.

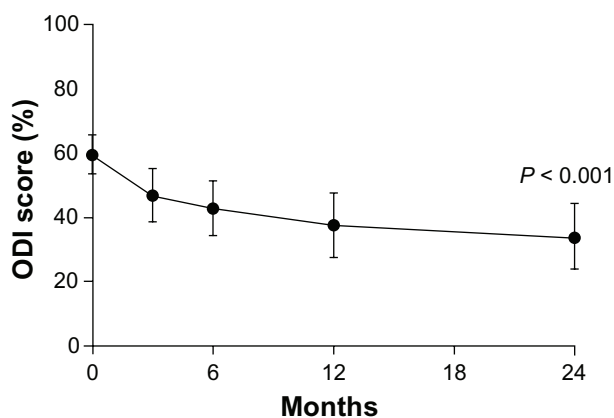
**Note:** Mean  $\pm$  95% confidence interval.

**Abbreviation:** AxiaLIF, axial lumbar interbody fusion.

50% of patients at 2 years. At final follow-up using Odom's criteria, 45 (87%) patients had ratings of good or excellent, five as fair, and two as poor. Typical radiographic and CT images of a solid interbody fusion construct achieved with the two-level AxiaLIF implant are shown in Figures 4 and 5.

## Discussion

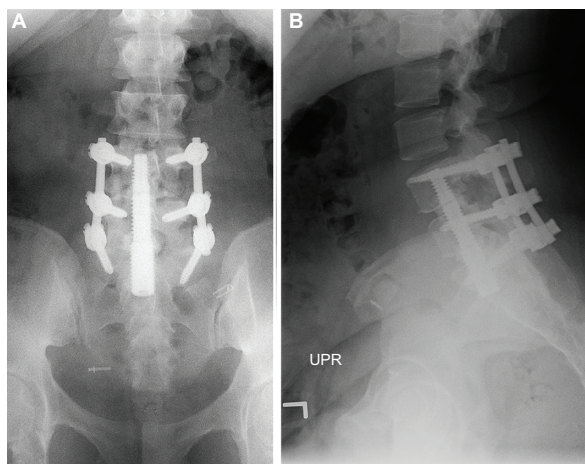
Our retrospective study of 52 patients who underwent a two-level lumbar fusion using AxiaLIF demonstrated high fusion rates (93%), relief of back pain, and improved back function through a minimum of 2 years follow-up. Our data corroborate the 94% fusion rate and few complications observed with the single-level AxiaLIF procedure.<sup>13</sup> Via this presacral route, the clinical evidence to date suggests that the AxiaLIF device can provide safe and effective treatment in select patients with one- or two-level disc pathology who are resistant to conservative treatments.



**Figure 3** ODI through 2 years after AxiaLIF surgery.

**Note:** Mean  $\pm$  95% confidence interval.

**Abbreviations:** ODI, Oswestry Disability Index; AxiaLIF, axial lumbar interbody fusion.



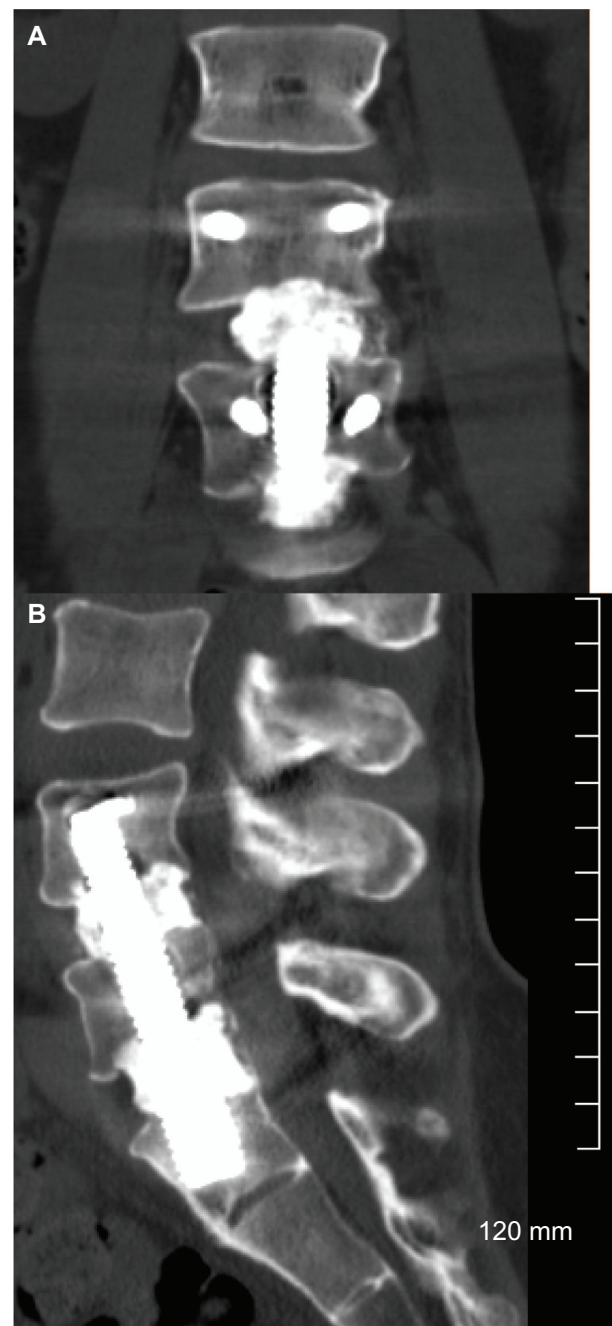
**Figure 4** Anteroposterior and lateral radiographs demonstrating two-level interbody fusion with AxiaLIF implant with bilateral pedicle screw fixation.

**Notes:** (A) Anteroposterior and (B) lateral radiographs.

**Abbreviation:** AxiaLIF, axial lumbar interbody fusion; UPR, upright.

The 56% mean improvement in pain relief and 42% mean improvement in function observed in this study compare favorably with findings of two systematic reviews that assessed standard surgical approaches for lumbar fusion surgery for degenerative disc disease. In a systematic review of 33 studies, Andersson et al<sup>18</sup> reported a median 50% improvement in pain severity and 42% improvement in ODI after fusion surgery. Similarly, in a meta-analysis of 25 studies, Geisler et al<sup>19</sup> reported a mean 49% decrease in pain severity after fusion surgery for degenerative disc disease. Our group previously reported excellent outcomes in 155 patients who underwent a one-level axial presacral fusion, including a 63% decrease in pain, a 54% improvement in function, and a 94% fusion rate at 2 years.<sup>13</sup> Clinical outcomes from our study are also comparable with control group results from three published randomized controlled trials that compared lumbar spinal fusion with disc arthroplasty.<sup>20–22</sup> Blumenthal et al,<sup>21</sup> Zigler et al,<sup>22</sup> and Berg et al<sup>20</sup> demonstrated a 48%, 43%, and 50% improvement in back pain severity, respectively, for fusion-treated patients after 2 years of follow-up and ODI improvement of 41%, 36%, and 44%, respectively.

In a study of 68 patients who underwent two-level AxiaLIF fusions at the University of Colorado Spine Center during a 4-year period, Lindley et al<sup>23</sup> noted that 16 (23.5%) patients developed a total of 18 complications, including pseudarthrosis (8.8%), superficial infection (5.9%), sacral fracture (2.9%), pelvic hematoma (2.9%), failure of wound closure (1.5%), transient nerve root irritation (1.5%), and rectal perforation (2.9%). Most concerning were two rectal perforations; these occurred in one patient who had had previous pelvic inflammatory disease, which is a



**Figure 5** Anteroposterior and lateral computed tomography scan images of two-level AxiaLIF fusion supplemented with bilateral pedicle screw fixation at 1 year posttreatment.

**Notes:** (A) Anteroposterior and (B) lateral CT scan images.

**Abbreviation:** AxiaLIF, axial lumbar interbody fusion.

contraindication to the presacral approach, and in another whose perforation occurred during a cannula exchange, which was recognized by the surgeon and repaired. Proper surgical technique, including the use of retractors and shielding pads that protect the bowel, have reduced the incidence of perforations. The presacral space is not a safe portal for this operation in patients who have adhesions and

scar tissue from previous pelvic surgery, infection, radiation, inflammatory bowel disease, or rectal disease.

In a report of 9,152 patients who underwent one- and two-level axial presacral fusions (2005–2010), Gundanna et al<sup>24</sup> noted a 1.3% complication rate, with a 0.6% incidence of bowel injury. Our case-matched series of 99 patients examined outcomes after fusion with or without rhBMP-2; among 54 without rhBMP-2 and 45 who received rhBMP-2, we found no effect for this BMP material on fusion rates or clinical outcomes for a one-level interbody fusion with AxiaLIF instrumentation.<sup>13</sup>

In a recent report of the two-level AxiaLIF technique, Marchi et al<sup>25</sup> noted a 50% improvement in back pain severity and 40% improvement in ODI during 2 years in 27 patients who underwent fusion surgery with a prototype AxiaLIF implant. The authors reported several complications that included radiolucencies, failure of posterior instrumentation, and migration of the prototype axial rod, and a 22% fusion rate. Of significance, they used only bone marrow aspirate and calcium phosphate and no autogenous graft. These outcomes might best be interpreted as related to a less-than-ideal graft substrate. Historical outcomes of posterior or lateral mass fusions without interbody grafting would predict fusion rates of at least 70%. Although they used posterior fixation, the authors did not specify if bone grafting material was used posteriorly. In our series, we have not seen instrumentation failures but have observed 1 mm to 2 mm radiolucencies around portions of the implant in CT imaging studies in the setting of documented fusion. The clinical improvements reported by Marchi et al<sup>25</sup> at 2 years in Visual Analog Scale and ODI scores would appear to be consistent with good fusion outcomes and not a 22% fusion rate.

Important prerequisites for favorable patient outcomes include precise and thorough preoperative planning and procedural techniques. A proper trajectory for placement of the AxiaLIF rod should be predetermined preoperatively by standing lateral radiographs. If an adequate trajectory cannot be templated for a two-level implant, an alternate approach should be used. Other important considerations are thorough debridement of remaining disc contents, and proper end plate preparation with the nitinol loop cutters and recently introduced flat cutters. Adequate amounts of graft to fill the disc space are necessary. Other requirements include placement of posterior instrumentation at L4, L5, and S1; decortication of the facets and transverse processes; and placement of adequate amounts of bone graft for fusion.<sup>26</sup> Over distraction of the AxiaLIF device and breaching the superior end plate of L4 must be avoided.

Although the results from our study are encouraging and corroborate data from previously published systematic reviews and clinical trials, these findings must be interpreted cautiously. Given that this was a retrospective case series, the data are subject to potential bias associated with this study design. The fact that ODI was only collected at two of four study sites also limits the robustness of these back function data.

## Conclusion

In findings from our retrospective series of 52 consecutive patients who underwent an L4–S1 interbody fusion for two-level disc pathology resistant to conservative treatment, AxiaLIF implantation appeared to be a safe and effective adjunct. At 2-year follow up, our patient-reported improvements of 56% for pain relief and 42% for function are encouraging and should continue with studies of larger populations and with longer follow-up periods.

## Disclosure

WDT, TJR, NA, LEM, and RJN are consultants to TranS1, Inc, Wilmington, NC, USA. The authors report no other conflicts of interest in this work.

## References

- Carey TS, Garrett JM, Jackman AM. Beyond the good prognosis. Examination of an inception cohort of patients with chronic low back pain. *Spine (Phila Pa 1976)*. 2000;25(1):115–120.
- Von Korff M. Studying the natural history of back pain. *Spine (Phila Pa 1976)*. 1994;19(Suppl 18):2041S–2046S.
- Smith SE, Darden BV, Rhyne AL, Wood KE. Outcome of unoperated discogram-positive low back pain. *Spine (Phila Pa 1976)*. 1995;20(18):1997–2000; discussion 2000–2001.
- Boswell MV, Trescot AM, Datta S, et al; American Society of Interventional Pain Physicians. Interventional techniques: evidence-based practice guidelines in the management of chronic spinal pain. *Pain Physician*. 2007;10(1):7–111.
- Brodke DS, Ritter SM. Nonoperative management of low back pain and lumbar disc degeneration. *J Bone Joint Surg Am*. 2004;86-A:1810–1818.
- Turk DC. Understanding pain sufferers: the role of cognitive processes. *Spine J*. 2004;4(1):1–7.
- Humphreys SC, Hodges SD, Patwardhan AG, Eck JC, Murphy RB, Covington LA. Comparison of posterior and transforaminal approaches to lumbar interbody fusion. *Spine (Phila Pa 1976)*. 2001;26(5):567–571.
- Kawaguchi Y, Matsui H, Tsuji H. Back muscle injury after posterior lumbar spine surgery. A histologic and enzymatic analysis. *Spine (Phila Pa 1976)*. 1996;21(8):941–944.
- Motosuneya T, Asazuma T, Tsuji T, Watanabe H, Nakayama Y, Nemoto K. Postoperative change of the cross-sectional area of back musculature after 5 surgical procedures as assessed by magnetic resonance imaging. *J Spinal Disord Tech*. 2006;19(5):318–322.
- Cragg A, Carl A, Casteneda F, Dickman C, Guterman L, Oliveira C. New percutaneous access method for minimally invasive anterior lumbar surgery. *J Spinal Disord Tech*. 2004;17(1):21–28.
- Stippler M, Turka M, Gerszten PC. Outcomes after percutaneous TranS1 AxiaLIF® L5-S1 interbody fusion for intractable lower back pain. *The Internet Journal of Spine Surgery*. 2009;5(1):1–12.

12. Tobler WD, Ferrara LA. The presacral retroperitoneal approach for axial lumbar interbody fusion: a prospective study of clinical outcomes, complications and fusion rates at a follow-up of two years in 26 patients. *J Bone Joint Surg Br.* 2011;93(7):955–960.
13. Tobler WD, Gerszten PC, Bradley WD, Raley TJ, Nasca RJ, Block JE. Minimally invasive axial presacral L5-S1 interbody fusion: two-year clinical and radiographic outcomes. *Spine (Phila Pa 1976).* 2011;36(20):E1296–E1301.
14. Gerszten PC, Tobler WD, Nasca RJ. Retrospective analysis of L5-S1 axial lumbar interbody fusion (AxiaLIF): a comparison with and without the use of recombinant human bone morphogenetic protein-2. *Spine J.* 2011;11(11):1027–1032.
15. Fairbank JC, Pynsent PB. The Oswestry Disability Index. *Spine (Phila Pa 1976).* 2000;25(22):2940–2952; discussion 2952.
16. Ostelo RW, Deyo RA, Stratford P, et al. Interpreting change scores for pain and functional status in low back pain: towards international consensus regarding minimal important change. *Spine (Phila Pa 1976).* 2008;33(1):90–94.
17. Odom GL, Finney W, Woodhall B. Cervical disk lesions. *J Am Med Assoc.* 1958;166(1):23–28.
18. Andersson GB, Mekhail NA, Block JE. Treatment of intractable discogenic low back pain. A systematic review of spinal fusion and intradiscal electrothermal therapy (IDET). *Pain Physician.* 2006;9(3):237–248.
19. Geisler FH, Blumenthal SL, Guyer RD, et al. Neurological complications of lumbar artificial disc replacement and comparison of clinical results with those related to lumbar arthrodesis in the literature: results of a multicenter, prospective, randomized investigational device exemption study of Charité intervertebral disc. Invited submission from the Joint Section Meeting on Disorders of the Spine and Peripheral Nerves, Mar 2004. *J Neurosurg Spine.* 2004;1(2):143–154.
20. Berg S, Tullberg T, Branth B, Olerud C, Tropp H. Total disc replacement compared to lumbar fusion: a randomised controlled trial with 2-year follow-up. *Eur Spine J.* 2009;18(10):1512–1519.
21. Blumenthal S, McAfee PC, Guyer RD, et al. A prospective, randomized, multicenter Food and Drug Administration investigational device exemptions study of lumbar total disc replacement with the CHARITE artificial disc versus lumbar fusion: part I: evaluation of clinical outcomes. *Spine (Phila Pa 1976).* 2005;30(14):1565–1575; discussion E387–E391.
22. Zigler J, Delamarter R, Spivak JM, et al. Results of the prospective, randomized, multicenter Food and Drug Administration investigational device exemption study of the ProDisc-L total disc replacement versus circumferential fusion for the treatment of 1-level degenerative disc disease. *Spine (Phila Pa 1976).* 2007;32(11):1155–1162; discussion 1163.
23. Lindley EM, McCullough MA, Burger EL, Brown CW, Patel VV. Complications of axial lumbar interbody fusion. *J Neurosurg Spine.* 2011;15(3):273–279.
24. Gundanna MI, Miller LE, Block JE. Complications with axial presacral lumbar interbody fusion: a five-year postmarket surveillance experience. *SAS J.* 2011;5(3):90–94.
25. Marchi L, Oliveira L, Coutinho E, Pimenta L. Results and complications after 2-level axial lumbar interbody fusion with a minimum 2-year follow-up. *J Neurosurg Spine.* 2012;17(3):187–192.
26. Fleischer GD, Kim YJ, Ferrara LA, Freeman AL, Boachie-Adjei O. Biomechanical analysis of sacral screw strain and range of motion in long posterior spinal fixation constructs: effects of lumbosacral fixation strategies in reducing sacral screw strains. *Spine (Phila Pa 1976).* 2012;37(3):E163–E169.

## Medical Devices: Evidence and Research

### Publish your work in this journal

Medical Devices: Evidence and Research is an international, peer-reviewed, open access journal that focuses on the evidence, technology, research, and expert opinion supporting the use and application of medical devices in the diagnosis, treatment and management of clinical conditions and physiological processes. The identification of novel

Submit your manuscript here: <http://www.dovepress.com/medical-devices-evidence-and-research-journal>

devices and optimal use of existing devices which will lead to improved clinical outcomes and more effective patient management and safety is a key feature. The manuscript management system is completely online and includes a quick and fair peer-review system. Visit <http://www.dovepress.com/testimonials.php> to read real quotes from authors.