

# Gray Matter Alterations in Panic Disorder: A Voxel-Wise Meta-Analysis

Anguang Pan<sup>1\*</sup>, Shaojie Liu<sup>2\*</sup>, Shijun Hu<sup>1</sup>, Jin Dai<sup>3</sup>, Juan Yi<sup>4</sup>

<sup>1</sup>Department of Radiology, Xishan Hospital, the Seventh People's Hospital of Wenzhou, Wenzhou, Zhejiang, China; <sup>2</sup>Hainan Province's Capital City Compulsory Isolation Drug Rehabilitation Center Hospital, Haikou, Hainan, China; <sup>3</sup>Nuclear Magnetic Resonance, Wulanchabu Central Hospital, Wulanchabu, Inner Mongolia, China; <sup>4</sup>Department of Neurology, General Hospital of Central Theater Command, Wuhan, Hubei, China

## ABSTRACT

**Background:** Gray matter alterations play a role in the panic disorder's pathophysiology origin. However, the current literature seemed inadequate to reach a consistent conclusion. Therefore, we conducted this gray matter meta-analysis on panic disorder.

**Methods:** A systematic review and a voxel-wise meta-analysis based on voxel-based morphometry were conducted for the gray matter studies in patients with panic disorder. The Seed-based d Mapping toolbox was applied for the voxel-wise meta-analysis. Fourteen gray matter studies (954 subjects) were enrolled in the current meta-analysis. The subgroup analysis of typical-onset versus late-onset patients was also performed. At last, the clinical severity was meta-regressed with gray matter alterations.

**Results:** Significant gray matter alterations were found in the left para-cingulate gyrus and the right amygdala of panic disorder patients. The subgroup analysis of typical-onset panic disorder patients showed a similar pattern. However, gray matter alterations were demonstrated in the bilateral opercular cortex of late-onset panic disorder patients. A significant association between the clinical severity and the gray matter alterations was found in the fronto-cingulate regions of panic disorder patients.

**Conclusion:** Gray matter alterations might represent a significant pillar of panic disorder's neurobiology, especially for the amygdala, cingulate, and frontal regions. Future gray matter studies in panic disorder should be needed to reconfirm this pattern of gray matter alterations.

## ARTICLE HISTORY

Received: March 28, 2023

Accepted: June 07, 2023

Publication Date: August 25, 2023

## INTRODUCTION

Panic disorder (PD), a mental illness with the dysfunctions of autonomic nervous system, usually is manifested with the unexpected and anticipatory worry of panic attacks.<sup>1</sup> The mixtures of symptom dimensions, such as cognition, affect, physiology, and behaviors,<sup>2</sup> are usually comprehensive, sudden, intense, and unexpected. The typical symptoms would prevail and cause the dysfunction of social and occupational domains. However, it is usually under-evaluated in clinical practice.<sup>3</sup> The significant impacts on the different domains of patients should be paid attention.<sup>1</sup> Panic disorder will also lead to impairments in occupational and social functions.<sup>1,4,5</sup> In addition, the link between PD, negative clinical outcomes, and dysfunctional immune response has been reported in several studies, although the causation has not been confirmed. Importantly, PD frequently associated with depressive symptoms may be related to relevant neurobiological

dysfunctions, in particular immune-inflammatory abnormalities, which might be associated with suicidal behaviors.<sup>6</sup> Panic disorder and depressive symptoms may be frequently related to unsuccessful therapeutic response, which meant that PD might be with a limited response to antidepressant treatment and are at higher risk to develop suicidal behavior. A recent study showed that low-dose buprenorphine is a treatment option in reducing addictive behaviors. In addition, the depression with suicidal ideation related to immune-inflammatory dysfunctions might be decreased.<sup>7</sup> Therefore, it is important for clinicians and scientists to delineate the pathophysiology of PD.

The brain plays a crucial role in the cognitive, affective, and behavioral symptoms of PD. Among the various methods to explore the brain, magnetic resonance imaging (MRI) is a crucial tool. A method, voxel-based morphometry (VBM) in MRI, has been used to calculate the gray matter (GM) using

\*Anguang Pan and Shaojie Liu are co-first authors, they contributed equally to this work.

**Corresponding author:** Juan Yi, e-mail: yijuan678@sina.com

**Cite this article as:** Pan A, Liu S, Hu S, Dai J, Yi J. Gray matter alterations in panic disorder: A voxel-wise meta-analysis. *Psychiatry Clin Psychopharmacol.* 2023;33(3):229-237.



the segmentation step. In addition, the non-parametric independent 2-sample test was applied to compare between groups to identify the significant GM alterations for PD.<sup>8</sup> Gray matter is an important structure for the cognitive function, attention, and executive function<sup>9</sup> due to the rich distribution of neurons within the GM of the cerebral cortex.<sup>10</sup> Therefore, we can understand the pathophysiology of PD via the VBM analysis of GM alterations. A voxel-wise meta-analysis of PD's VBM results might provide a comprehensive viewpoint of GM alterations of PD.

The Gorman's hypothesis of "fear network" established the framework for the neurobiology of PD,<sup>11</sup> which consisted of the fronto-limbic regions, such as the anterior cingulate, frontal gyrus, thalamus, insula, hippocampus, and amygdala, which have been found with GM alterations in previous VBM studies.<sup>12-17</sup> A previous pilot meta-analysis mentioned the possible pattern of GM alterations in the striato-limbic regions.<sup>18</sup> In these years, controversies of GM alterations in PD were still debated. Therefore, a meta-analysis of recent VBM studies in PD might be an intriguing study to give clinicians and scientists a more comprehensive viewpoint to understand the pathophysiology of PD. In this project, we planned to include all VBM studies in patients with PD. According to the earlier literature, we suggested that GM alterations might be significant over the fronto-limbic regions. The current meta-analysis might elucidate the detailed and specific regions for GM alterations in PD.

## MATERIAL AND METHODS

### Search Strategy and Information Sources

The following keywords "panic disorder" plus "voxel-based" or "morphometry" or "voxel-wise" or "gray matter" were conducted to collect the related articles in the PubMed, Embase, Scopus, Web of Science, ScienceDirect, and Cochrane database. The related reports in the English language before February 2023 were included.

### Exclusion Criteria for Studies

(i) The comorbidity of significant medical illness due to the possible impacts on the brain structures. (ii) The adolescent/children studies due to the possible biases from the adolescent/children group. (iii) The studies without healthy controls. (iv) The studies without brain coordinate outcomes.

#### MAIN POINTS

- Gray matter alterations in the left para-cingulate gyrus and the right amygdala of panic disorder patients.
- Gray matter alterations in the bilateral opercular cortex of late-onset panic disorder patients.
- A significant association between the clinical severity and the gray matter alterations was found in the fronto-cingulate regions of panic disorder patients.

### The Meta-Analysis of Gray Matter Alterations

Pooled GM alterations in PD were analyzed by the Seed-based d Mapping (SDM) (<http://www.sdmproject.com>). The SDM has been reported in various previous studies of mental illness, such as depression, substance use disorder, mild cognitive impairment, internet addiction disorder, and Tourette syndrome.<sup>19-24</sup> The SDM used activation likelihood estimate<sup>25</sup> and multilevel kernel density analysis<sup>26</sup> in the calculation algorithms. A better control of the selection criterion of SDM can include the most significant peak clusters in the meta-analysis, which might decrease the biases originating from the liberal threshold and regions of interest method in the neuroimaging studies. The SDM can also reconstruct the regions with higher GM and lower GM on the same map. At first, a Talairach space map of GM differences<sup>27</sup> was established while reported clusters were enrolled and calculated via the algorithms of SDM. Then, an un-normalized Gaussian kernel was used to smooth the reported coordinates' proximity, which can control false positives.<sup>28</sup> The SDM can create both positive (higher GM) and negative (lower GM) concurrently, which could obtain the maximal voxel values to decrease the biases. The meta-analytic value of a voxel was defined as the mean of studies mentioning the voxel in their reporting results. The values would be weighted by each study sample size's square root. It can weigh more on the studies of a larger sample size.

An null distribution was created in the whole brain for assessing the meta-analytic values. The reporting coordinates were permuted using Monte-Carlo randomizations to produce the null distribution and reached statistical stability with less computing duration.<sup>29</sup> The preprocessing and mean test was performed at first. Then, the family-wise error correction step was performed with 1000 randomization permutations, which produced the threshold-free cluster enhancement (TFCE)-corrected *P* image files. The TFCE-corrected *P* image files was thresholded as *P*-value < .025 and cluster size > 10 voxels.<sup>29,30</sup> The subgroup analysis of typical-onset vs. late-onset PD patients was also performed. The subgroup analysis also followed the preprocessing, mean test, family-wise error correction, and threshold setting. At last, we also performed the meta-regression step to determine the existence of a significant association between the clinical severity [Panic Disorder Severity Scale (PDSS) scores] and GM alterations. The preprocessing, linear model, family-wise error correction, and threshold setting steps were also performed to find the significant clusters for the meta-regression between PDSS scores and GM alterations. The significant clusters or local peaks were overlaid and presented using the fslview function of FSL (FMRIB Software Library). The significant peak coordinates (Montreal Neurological Institute [MNI] space) would be used to create the mask and extract the mask values. Then, the extracted values of the created mask were used to assess the bias of publication by the funnel plot and Egger test.

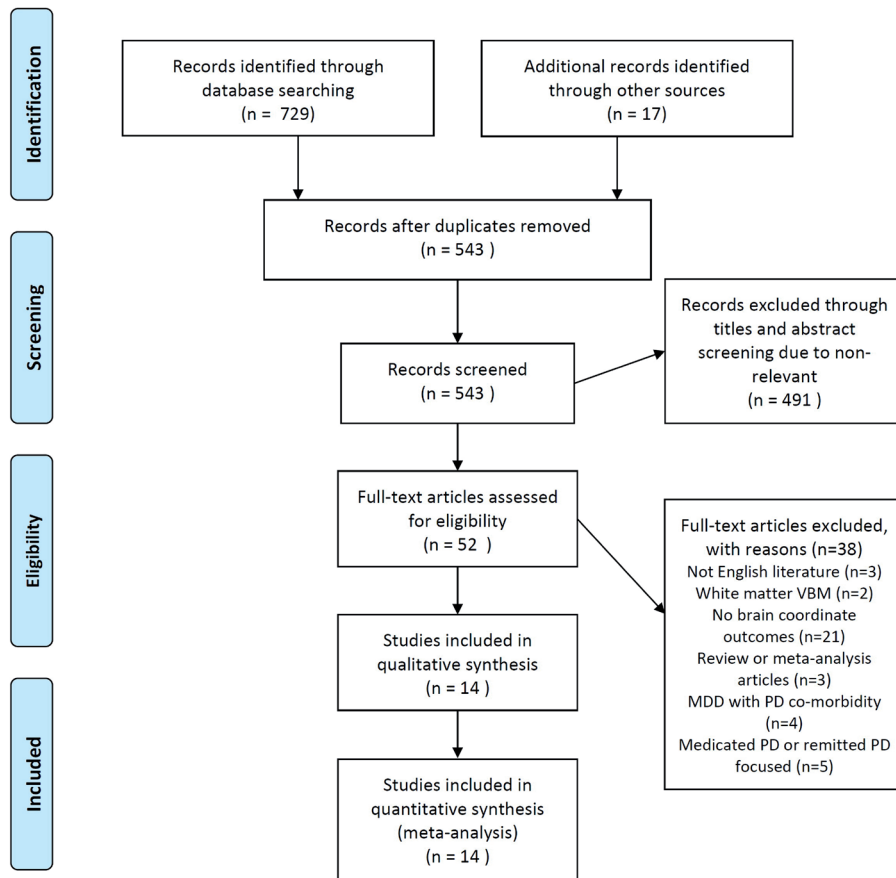


Figure 1. PRISMA flow chart for the selection of enrolled studies. The flow chart for the collection, screening, exclusion, and selection of enrolled studies.

**RESULTS**

**Study Selection and Study Characteristics**

We followed the Preferred Reporting Items for Systematic Reviews and Meta-Analyses (PRISMA) flow diagram (Figure 1) to select relevant articles. Initially, 543 articles were identified, but after removing duplicates, 491 were excluded due to non-relevant titles and abstracts. After this initial screening process, 52 studies were assessed, and 38 articles were

discarded during the full-text evaluation for various reasons (Figure 1). We then performed qualitative and quantitative analyses of the remaining 14 studies (Table 1).<sup>12-17,31-38</sup> Finally, 455 patients with PD and 499 controls were enrolled.

**Reporting Bias in Studies**

The funnel plot of included studies was shown in Figure 2. Metabias test results were Bias=0.15, z=0.17, df=12, P=.865. Excess significance test P=.962.

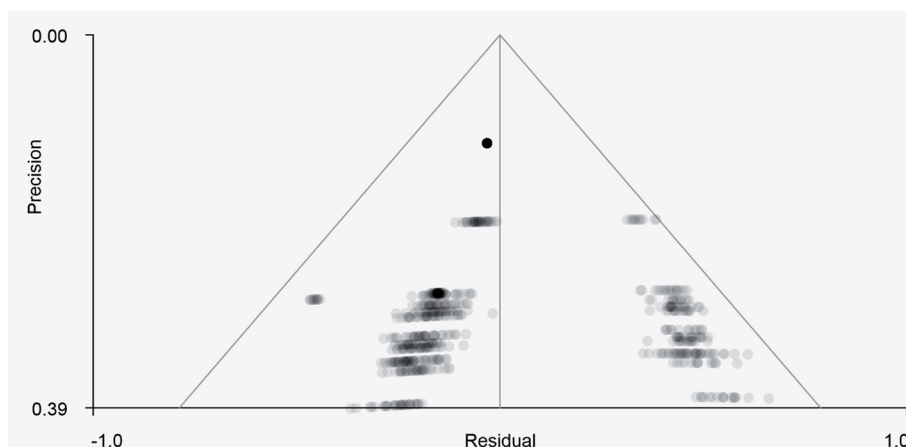


Figure 2. The funnel plot of the included studies. The funnel plot showed a non-symmetric distribution.

### Gray Matter Alterations in Panic Disorder Patients Versus Controls

Gray matter decreases in the right amygdala [MNI coordinates (24, 0, -22), SDM-Z: -4.523,  $P = .029$ , cluster voxels: 26] and left paracingulate gyri (part of Anterior Cingulate Cortex [ACC]) [MNI coordinates (-2, 28, 34), SDM-Z: -3.985,  $P = .045$ , cluster voxels: 15] were found. The clusters of right amygdala (Figure 3A) and left paracingulate gyri (Figure 3B) were demonstrated. The metabias test and excess significance test did not show the existence of bias of publication in the right amygdala and left paracingulate gyri for the GM alterations in PD patients.

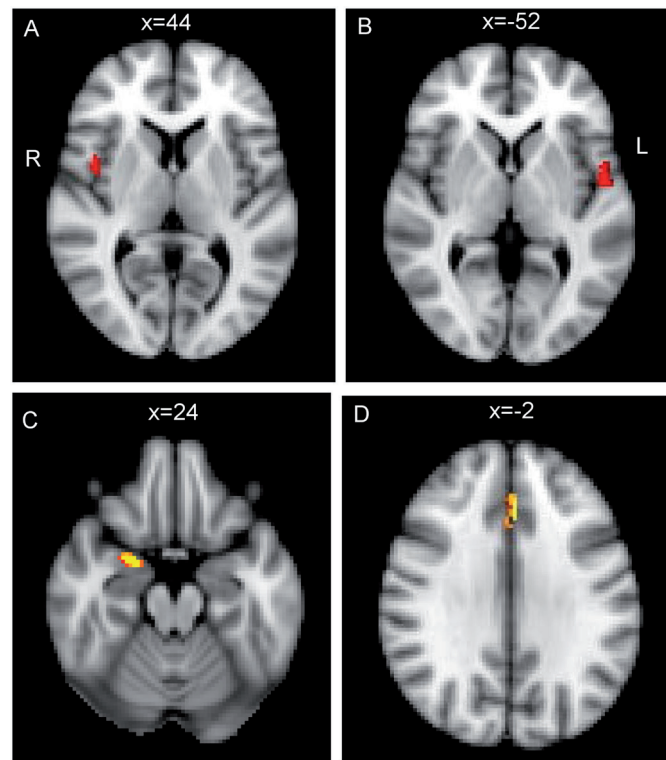
### Subgroup Analysis in Panic Disorder Patients: Typical-Onset Versus Late-Onset

The mean test of the studies of typical-onset PD patients showed GM decreases in right amygdala [MNI coordinates (24, 0, -20)] and left paracingulate gyri (part of ACC) [MNI coordinates (-2, 32, 30)]. The clusters of right amygdala and left paracingulate gyri are shown in Figure 4A.

The mean test of the studies of late-onset PD patients showed GM decreases in bilateral central opercular cortex [left, MNI coordinates (44, 0, 6); right, MNI coordinates (-52, -2, 2)]. The clusters of the bilateral central opercular cortex are shown in Figure 4B.

### META-REGRESSION RESULTS OF CLINICAL SEVERITY

The PDSS scores were significantly associated with GM alterations in the following regions: right superior frontal gyrus (SFG) [MNI coordinates (6, 26, 42), SDM-Z: 3.436,  $P < .001$ , cluster voxels: 54], left SFG [MNI coordinates (2, 26, 38), SDM-Z: 3.248,  $P < .001$ , cluster voxels: 72], right paracingulate gyri, BA 24 [MNI coordinates (4, 22, 34), SDM-Z: 3.285,  $P < .001$ , cluster voxels: 76], and right paracingulate gyri, BA 32 [MNI coordinates (8, 30, 34),

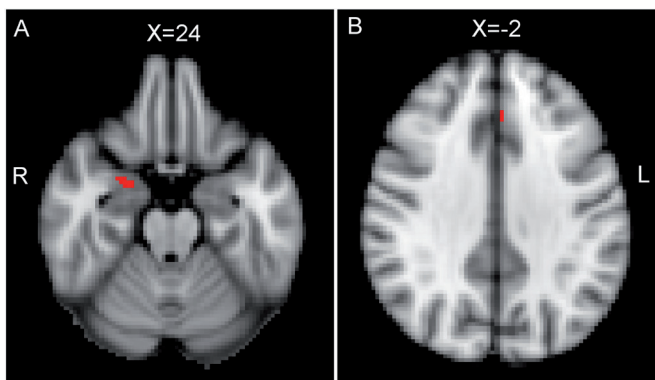


**Figure 4.** Late-onset subgroup analysis showed the GM alterations in the bilateral central opercular cortex (A and B). Typical-onset subgroup analysis demonstrated the GM alterations in the right amygdala and left para-cingulate gyri (C and D). GM, gray matter; PD, panic disorder.

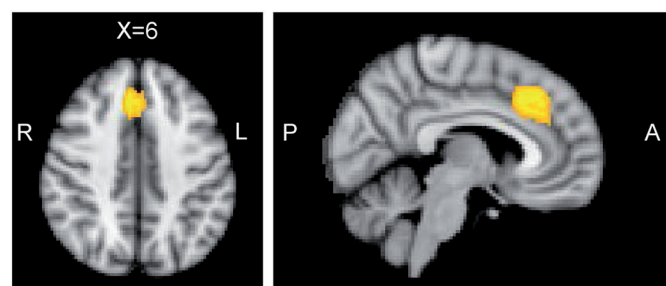
SDM-Z: 3.276,  $P < .001$ , cluster voxels: 160]. The significant local peaks are shown in Figure 5.

### DISCUSSION

The recent meta-analysis of PD studies in VBM methodology showed that PD was more specifically associated with frontal lobe GM alterations.<sup>39</sup> In addition, an earlier meta-analysis of VBM studies demonstrated limbic-region



**Figure 3.** The pooled GM alterations in the right amygdala and left paracingulate gyri. The pooled meta-analysis showed GM alterations in the right amygdala (A) and left paracingulate gyri (median cingulate gyri) (B). GM, gray matter.



**Figure 5.** The clinical severity was significantly associated with GM alterations in the bilateral SFG and right paracingulate gyri. The clinical severity (PDSS scores) showed a significant association with GM alterations in the bilateral SFG and right paracingulate gyri (BA24 and 32). GM, gray matter; PDSS, Panic Disorder Severity Scale; SFG, superior frontal gyrus.

Table 1. Summary of Enrolled Studies

	Subjects (PD vs. Healthy Controls)	Comorbidity	Method	Findings
Asami 2008 (Japan)	26 (38.5% M, 37 ± 10 years old) vs. 26 (38.5% M, 37 ± 8.7 years old)	11 Agoraphobia	Whole-brain VBM (SPM2)	GM reductions in anterior cingulate cortex
Asami 2009 (Japan)	24 (37.5% M, 35.8 ± 10 years old) vs. 24 (37.5% M, 37.2 ± 8.7 years old)	13 Agoraphobia	Whole-brain VBM (SPM2)	Multiple regions of GM alterations in frontal lobe; temporal lobe; cerebellum
Hayano 2009 (Japan)	27 (37% M, 38.2 ± 9.9 years old) vs. 30 (30% M, 35.3 ± 10.5 years old)	Not mentioned	Whole-brain VBM (SPM2)	GM reductions in the amygdala and hippocampus
Kunas 2020 (Germany)	143 (37.8% M, 34.13 ± 10.7 years old) vs. 178 (43.3% M, 31.23 ± 10.5 years old)	72 Smoking	Whole-brain VBM (SPM12)	GM reductions in the right amygdala
Lai 2012 (Taiwan, China)	30 (36.7% M, 47.03 ± 10.63 years old) vs. 21 (47.6% M, 47.14 ± 11.81 years old)	None	VBM function of FSL	Left orbito-frontal cortex left inferior frontal cortex right insula left superior temporal gyrus GM reductions
Lai 2015 (Taiwan, China)	53 (47.2% M, 43.28 ± 10.11 years old) vs. 54 (46.3% M, 40.38 ± 10.51 years old)	None	VBM function of FSL	Right inferior frontal gyrus right insula GM reductions
Massana 2003 (Spain)	18 (38.9% M, 36.8 ± 11.3 years old) vs. 18 (44.4% M, 36.7 ± 8.8 years old)	15 Agoraphobia	Whole-brain VBM (SPM99)	GM reductions in the left parahippocampal gyrus
Na 2013 (South Korea)	22 (59.1% M, 40.2 ± 10.6 years old) vs. 22 (50% M 40.2 ± 12.4 years old)	12 Agoraphobia	Whole-brain VBM (SPM2)	GM reductions in the left medial orbito-frontal gyrus
Picado 2015 (Spain)	20 (25% M, 30.9 ± 6.639 years old) vs. 20 (60% M, 33.2 ± 6.613 years old)	Agoraphobia	Whole-brain VBM (SPM5)	GM reductions in the left middle frontal gyrus
Protopopescu 2006 (USA)	10 (40% M, 35.5 years old) vs. 23 (52.2% M, 28.7 years old)	2 Agoraphobia; 1 alcohol dependence	Whole-brain VBM (SPM99)	GM increase in the brainstem
Roppongi 2010 (Japan)	28 (35.7% M, 38.4 ± 9.8 years old) vs. 28 (35.7% M, 37.8 ± 9.8 years old)	15; 1 current major depression; 1 previous dysthymia; 6 previous major depression	Whole-brain VBM (SPM2)	GM reduction in the right posterior-medial orbitofrontal region
Sobanski 2010 (Germany)	17 (47.1% M, 34.9 ± 6.7 years old) vs. 17 (47.1% M, 33.1 ± 6.2 years old)	16 agoraphobia social phobia (6%) generalized anxiety disorder (6%) adjustment disorder (12%) paranoid personality disorder (12%)	Whole-brain VBM (SPM5)	GM reductions in right middle temporal lobe and orbitofrontal cortex
Uchida 2008 (Brazil)	19 (15.8% M, 37.1 ± 9.8 years old) vs. 20 (20% M, 36.5 ± 9.9 years old)	14 Agoraphobia; 3 major depressive disorder; 2 dysthymia	Whole-brain VBM (SPM2)	GM reductions in the right anterior cingulate cortex GM increases in the left insula, midbrain, pons
Yoo 2005 (South Korea)	18 (50% M, 33.3 ± 7.1 years old) vs. 18 (61.1% M, 32 ± 5.8 years old)	None	Whole-brain VBM (SPM2)	GM reductions in the bilateral putamen

FSL, FMRIB Software Library; GM, gray matter; VBM, voxel-based morphometry

alterations of PD's GM.<sup>18</sup> In the current SDM meta-analysis, we found significant GM alterations in the left paracingulate gyri and right amygdala of patients with PD. In addition, the subgroup analysis of typical-onset PD patients demonstrated a similar pattern of GM alterations over the left paracingulate gyri and right amygdala. However, the subgroup analysis of late-onset PD patients showed a distinct pattern of GM alterations, which would be focused on the bilateral central opercular cortex, which had overlapping regions of the bilateral insular cortex. At last, the meta-regression of clinical severity demonstrated

the possible association of GM alterations in the bilateral SFG and right paracingulate gyri. Our meta-analysis is more updated than the previous meta-analysis<sup>18</sup> with an enrollment of the VBM reports published before 2011, which showed the GM alterations in the striato-limbic regions. However, our meta-analysis supported the possibility of the extended fear network model hypothesis proposed by Lai et al.<sup>40</sup> In the extended fear network model, anterior and middle cingulate cortex, sensory regions of occipital and parietal cortex, medial and posterior parts of the frontal cortex, and insula might be involved. Our meta-analysis

results also found the GM alterations in the paracingulate gyri (median cingulate), which might be nearby the middle cingulate cortex. Our findings of the bilateral central opercular cortex in the late-onset PD subgroup analysis seemed to be within the regions of the extended fear network. The meta-regression results of clinical severity in the SFG might also be within the regions of the extended fear network. Therefore, our meta-analysis results supported the latest hypothesis of the extended fear network model from the perspective of GM alterations in PD. Another previous meta-analysis using the older version of SDM showed the GM alterations in the prefrontal, limbic, and temporo-parieto-occipital regions.<sup>39</sup> Our meta-analysis used the latest version of SDM to decrease the possible biases from the individual studies. In addition, our funnel plot, metabias test result, and excess significance test showed no significant bias from the created mask of significant clusters and publication bias. Our results failed to find such significant and widespread areas of the results from the previous meta-analysis, which might suggest the potential influences from the latest included study<sup>32</sup> and less potential bias in our meta-analysis. Another previous meta-analysis using the activation likelihood estimation meta-analysis showed significant GM alterations in the frontal, temporal, and insula.<sup>41</sup> Since our meta-analysis used SDM with a combined feature of activation likelihood estimate and multilevel kernel density analysis, it is predictable that our results might be different. It suggested that the different algorithms might derive different results in the meta-analysis. An optimal and standard algorithm might be warranted in the future to obtain more consistent results.

The amygdala is the center of the fear network. The processing and modulation of fearful response and memory might be related to the connection between the amygdala, hippocampus, and medial frontal cortex.<sup>42</sup> The connection between the amygdala and hypothalamus or brainstem might be associated with symptomatic presentations of PD. The psychosocial interventions might also enhance the inhibitory control of the frontal cortex for the excessive signals from the hippocampus and amygdala.<sup>11</sup> The amygdala might also be responsible for the defense action toward the different threats.<sup>43</sup> In addition, antidepressant treatment might alleviate the excessive activation of the amygdala regions.<sup>44</sup> Our meta-analysis results of the right amygdala might represent the potential endophenotype of GM alterations of PD.

The cingulate cortex is also a major component of the fear network model. The midcingulate cortex is even a crucial component of the extended fear network model.<sup>42</sup> Disrupted in schizophrenia 1 gene sequence variation has been reported to be associated with panic and cingulate cortex, which is affiliated with memory and executive function.<sup>45</sup> In addition, the explorative functional connectivity analysis of PD demonstrated that the middle

cingulate gyri might represent a node to connect with the limbic regions.<sup>46</sup> Our meta-analysis results of GM alterations in the left paracingulate gyri (median cingulate gyri) might represent another pillar of GM alterations in patients with PD.

Our subgroup analysis results of the typical-onset group suggested that amygdala and cingulate GM alterations might represent the specific pattern of GM alterations for typical-onset PD, which might have significant contributions to our pooled meta-analysis results of GM alterations. However, the late-onset PD group might demonstrate another pattern of GM alterations, which would be focused on the bilateral central opercular cortex. The central opercular cortex is overlapping with the insula, which is a crucial component of GM alterations in PD.<sup>13,17,33,47</sup> Insula integrates multimodal sensory information with frontal and temporal regions via dense connections, which can modulate panic responses.<sup>33,48,49</sup> The insula might process the sensory information filtered by the thalamus. In addition, it might cooperate with the frontal lobe to control panic symptoms.<sup>11</sup> Therefore, late-onset PD might have more significant GM alterations in the insula regions. However, further studies might be needed to confirm the potentially distinct patterns of GM alterations in typical-onset and late-onset PD.

The GM alterations of bilateral SFG and right paracingulate gyri might be associated with clinical severity in PD according to our meta-analysis results. It suggested that fronto-cingulate regions might be responsible for the inhibitor control of excessive limbic responses in PD. In addition, the clusters seemed to be relatively huge in the meta-regression results of PDSS scores. Therefore, the potential contribution of fronto-cingulate regions for the control of panic symptoms seemed to be an intriguing research topic for the future direction of PD studies.

In summary, the amygdala and cingulate GM alterations in PD might represent the alterations of the fear response and response inhibition of PD patients. This type of GM alterations might be just specific to typical-onset PD patients. For late-onset PD patients, the GM alterations of insula-related regions might represent the possible alterations of integration of sensory information, which might contribute to panic attacks in late-onset PD patients. The clinical severity might be modulated by the frontal regions (such as SFG) and cingulate regions (such as paracingulate gyri) in PD patients according to our meta-analysis results. The medications targeted at the frontal, cingulate, and amygdala regions (such as antidepressants) might be helpful to relieve panic attacks. However, more functional studies will be needed to confirm this type of structural alteration. In addition, the future meta-analysis of functional studies in PD might be useful to confirm this pattern of alterations.

Several limitations in the current meta-analysis should be disclosed. First, the inadequate sample size should be noted

even though the MRI studies of PD patients were relatively low in the sample size. The variations in the reference standard and threshold setting of the included studies may be another limitation, altering the interpretation of the meta-analysis results and causing biases to influence the results. Second, the variable content of MRI, such as machine brands, technology, operator abilities, screening timing, pulse sequence setting parameters, and operator training, as well as the lack of precise definitions with the same standard procedures across the included studies, should not be ignored. These variables might interfere with the strength of evidence for GM alterations in patients with PD. Although the subgroup analysis of typical-onset and late-onset PD showed significant impacts on the distinct patterns of GM alterations, a more clearly defined onset range of age in future studies might be necessary to clarify this issue. Third, the clinical severity of PD and the subjects' demographic data might also influence the interpretation. Our meta-analysis included case-control studies of patients with the diverse severities and demographic characteristics of included subjects might lead to cautious interpretation. In addition, the effects of medicated and remitted PD are impossible to exclude. The statistical and clinical heterogeneity should not be ignored while interpreting the results. The various kinds of antidepressants, anxiolytics, and remission characteristics should play a role in the variables. Fourth, the patient-level data were lacking, which would influence the interpretation of our results. A possible patient-level subgroup could not be confirmed. The impact and specific pattern of the GM alterations on the benefit of detecting PD under patient-level data would be difficult to explore. Fifth, different kinds of VBM algorithms might be another limitation. The FSL and Statistical Parametric Mapping (SPM) VBM algorithms' differences might influence our meta-analytic results. Sixth, our meta-analysis only surveyed the summarized GM alterations in PD. Further analysis is required to determine the best methods for predicting PD using the specific pattern of GM alterations or combined multimodal alterations of neuroimaging. Finally, the inclusion of the covariates of demographic data and other potential variables in the future meta-analysis can be improved to enroll more covariates in the meta-analysis model and more sophistication of the multivariate model might be warranted in the future to optimize the meta-analysis results.

**Peer-review:** Externally peer-reviewed.

**Author Contributions:** Concept - P.A., L.S.; Design - P.A., L.S.; Supervision - Y.J.; Resources - Y.J.; Materials - H.S., D.J.; Data Collection and/or Processing - P.A., L.S.; Analysis and/or Interpretation - P.A., L.S.; Literature Search - P.A., L.S.; Writing - P.A., L.S.; Critical Review - H.S., D.J., Y.J.

**Declaration of Interests:** The authors have no conflict of interest to declare.

**Funding:** The authors declared that this study has received no financial support.

## REFERENCES

1. Culpepper L. Identifying and treating panic disorder in primary care. *J Clin Psychiatry*. 2004;65(Suppl 5):19-23.
2. Ludewig S, Geyer MA, Ramseier M, Vollenweider FX, Rechsteiner E, Cattapan-Ludewig K. Information-processing deficits and cognitive dysfunction in panic disorder. *J Psychiatry Neurosci*. 2005;30(1):37-43.
3. Wood WG. The diagnosis and management of panic disorder. *Psychiatr Med*. 1990;8(3):197-209.
4. Rubin HC, Rapaport MH, Levine B, et al. Quality of well being in panic disorder: The assessment of psychiatric and general disability. *J Affect Disord*. 2000;57(1-3):217-221. [\[CrossRef\]](#)
5. Barrera TL, Hiatt EL, Dunn NJ, Teng EJ. Impact of panic disorder on quality of life among veterans in a primary care pilot study. *Compr Psychiatry*. 2013;54(3):256-261. [\[CrossRef\]](#)
6. Serafini G, Parisi VM, Aguglia A, et al. A specific inflammatory profile underlying suicide risk? Systematic review of the main literature findings. *Int J Environ Res Public Health*. 2020;17(7). [\[CrossRef\]](#)
7. Serafini G, Adavastro G, Canepa G, et al. The efficacy of buprenorphine in major depression, treatment-resistant depression and suicidal behavior: A systematic review. *Int J Mol Sci*. 2018;19(8). [\[CrossRef\]](#)
8. Bigler ED. Structural image analysis of the brain in neuropsychology using magnetic resonance imaging (MRI) techniques. *Neuropsychol Rev*. 2015;25(3):224-249. [\[CrossRef\]](#)
9. Zheng D, Sun H, Dong X, et al. Executive dysfunction and gray matter atrophy in amnesic mild cognitive impairment. *Neurobiol Aging*. 2014;35(3):548-555. [\[CrossRef\]](#)
10. Schmidt-Wilcke T, Poljansky S, Hierlmeier S, Hausner J, Ibach B. Memory performance correlates with gray matter density in the ento-/perirhinal cortex and posterior hippocampus in patients with mild cognitive impairment and healthy controls--a voxel based morphometry study. *NeuroImage*. 2009;47(4):1914-1920. [\[CrossRef\]](#)
11. Gorman JM, Kent JM, Sullivan GM, Coplan JD. Neuroanatomical hypothesis of panic disorder, revised. *Am J Psychiatry*. 2000;157(4):493-505. [\[CrossRef\]](#)
12. Asami T, Hayano F, Nakamura M, et al. Anterior cingulate cortex volume reduction in patients with panic disorder. *Psychiatry Clin Neurosci*. 2008;62(3):322-330. [\[CrossRef\]](#)
13. Asami T, Yamasue H, Hayano F, et al. Sexually dimorphic gray matter volume reduction in patients with panic disorder. *Psychiatry Res*. 2009;173(2):128-134. [\[CrossRef\]](#)
14. Massana G, Serra-Grabulosa JM, Salgado-Pineda P, et al. Parahippocampal gray matter density in panic disorder: A voxel-based morphometric study. *Am J Psychiatry*. 2003;160(3):566-568. [\[CrossRef\]](#)
15. Protopopescu X, Pan H, Tuescher O, et al. Increased brainstem volume in panic disorder: A voxel-based morphometric study. *Neuroreport*. 2006;17(4):361-363. [\[CrossRef\]](#)

16. Sobanski T, Wagner G, Peikert G, et al. Temporal and right frontal lobe alterations in panic disorder: A quantitative volumetric and voxel-based morphometric MRI study. *Psychol Med*. 2010;40(11):1879-1886. [\[CrossRef\]](#)
17. Uchida RR, Del-Ben CM, Busatto GF, et al. Regional gray matter abnormalities in panic disorder: A voxel-based morphometry study. *Psychiatry Res*. 2008;163(1):21-29. [\[CrossRef\]](#)
18. Lai CH. Gray matter deficits in panic disorder: A pilot study of meta-analysis. *J Clin Psychopharmacol*. 2011;31(3):287-293. [\[CrossRef\]](#)
19. Sun JT, Hu B, Chen TQ, et al. Internet addiction-induced brain structure and function alterations: A systematic review and meta-analysis of voxel-based morphometry and resting-state functional connectivity studies. *Brain Imaging Behav*. 2023;17(3):329-342. [\[CrossRef\]](#)
20. Wan X, Zhang S, Wang W, et al. Gray matter abnormalities in Tourette syndrome: A meta-analysis of voxel-based morphometry studies. *Transl Psychiatry*. 2021;11(1):287. [\[CrossRef\]](#)
21. Xiao S, Yang Z, Su T, Gong J, Huang L, Wang Y. Functional and structural brain abnormalities in posttraumatic stress disorder: A multimodal meta-analysis of neuroimaging studies. *J Psychiatr Res*. 2022;155:153-162. [\[CrossRef\]](#)
22. Yan H, Xiao S, Fu S, et al. Functional and structural brain abnormalities in substance use disorder: A multimodal meta-analysis of neuroimaging studies. *Acta Psychiatr Scand*. 2023;147(4):345-359. [\[CrossRef\]](#)
23. Zhang J, Liu Y, Lan K, et al. Gray matter atrophy in amnesic mild cognitive impairment: A voxel-based meta-analysis. *Front Aging Neurosci*. 2021;13:627919. [\[CrossRef\]](#)
24. Zheng R, Zhang Y, Yang Z, Han S, Cheng J. Reduced brain gray matter volume in patients with first-episode major depressive disorder: A quantitative meta-analysis. *Front Psychiatry*. 2021;12:671348. [\[CrossRef\]](#)
25. Turkeltaub PE, Eden GF, Jones KM, Zeffiro TA. Meta-analysis of the functional neuroanatomy of single-word reading: Method and validation. *Neuroimage*. 2002;16(3 Pt 1):765-780. [\[CrossRef\]](#)
26. Wager TD, Lindquist M, Kaplan L. Meta-analysis of functional neuroimaging data: Current and future directions. *Soc Cogn Affect Neurosci*. 2007;2(2):150-158. [\[CrossRef\]](#)
27. Lancaster JL, Woldorff MG, Parsons LM, et al. Automated Talairach atlas labels for functional brain mapping. *Hum Brain Mapp*. 2000;10(3):120-131. [\[CrossRef\]](#)
28. Salimi-Khorshidi G, Smith SM, Keltner JR, Wager TD, Nichols TE. Meta-analysis of neuroimaging data: A comparison of image-based and coordinate-based pooling of studies. *Neuroimage*. 2009;45(3):810-823. [\[CrossRef\]](#)
29. Radua J, Mataix-Cols D. Voxel-wise meta-analysis of grey matter changes in obsessive-compulsive disorder. *Br J Psychiatry*. 2009;195(5):393-402. [\[CrossRef\]](#)
30. Genovese CR, Lazar NA, Nichols T. Thresholding of statistical maps in functional neuroimaging using the false discovery rate. *Neuroimage*. 2002;15(4):870-878. [\[CrossRef\]](#)
31. Hayano F, Nakamura M, Asami T, et al. Smaller amygdala is associated with anxiety in patients with panic disorder. *Psychiatry Clin Neurosci*. 2009;63(3):266-276. [\[CrossRef\]](#)
32. Kunas SL, Hilbert K, Yang Y, et al. The modulating impact of cigarette smoking on brain structure in panic disorder: A voxel-based morphometry study. *Soc Cogn Affect Neurosci*. 2020;15(8):849-859. [\[CrossRef\]](#)
33. Lai CH, Wu YT. Fronto-temporo-insula gray matter alterations of first-episode, drug-naive and very late-onset panic disorder patients. *J Affect Disord*. 2012;140(3):285-291. [\[CrossRef\]](#)
34. Lai CH, Wu YT. The gray matter alterations in major depressive disorder and panic disorder: Putative differences in the pathogenesis. *J Affect Disord*. 2015;186:1-6. [\[CrossRef\]](#)
35. Na KS, Ham BJ, Lee MS, et al. Decreased gray matter volume of the medial orbitofrontal cortex in panic disorder with agoraphobia: A preliminary study. *Prog Neuropsychopharmacol Biol Psychiatry*. 2013;45:195-200. [\[CrossRef\]](#)
36. Picado M, Carmona S, Hoekzema E, et al. The neuroanatomical basis of panic disorder and social phobia in schizophrenia: A voxel based morphometric study. *PLoS One*. 2015;10(3):e0119847. [\[CrossRef\]](#)
37. Roppongi T, Nakamura M, Asami T, et al. Posterior orbitofrontal sulcogyral pattern associated with orbitofrontal cortex volume reduction and anxiety trait in panic disorder. *Psychiatry Clin Neurosci*. 2010;64(3):318-326. [\[CrossRef\]](#)
38. Yoo HK, Kim MJ, Kim SJ, et al. Putaminal gray matter volume decrease in panic disorder: An optimized voxel-based morphometry study. *Eur J Neurosci*. 2005;22(8):2089-2094. [\[CrossRef\]](#)
39. Wang X, Cheng B, Wang S, et al. Distinct grey matter volume alterations in adult patients with panic disorder and social anxiety disorder: A systematic review and voxel-based morphometry meta-analysis. *J Affect Disord*. 2021;281:805-823. [\[CrossRef\]](#)
40. Lai CH. Fear network model in panic disorder: The past and the future. *Psychiatry Investig*. 2019;16(1):16-26. [\[CrossRef\]](#)
41. Wu Y, Zhong Y, Ma Z, et al. Gray matter changes in panic disorder: A voxel-based meta-analysis and meta-analytic connectivity modeling. *Psychiatry Res Neuroimaging*. 2018;282:82-89. [\[CrossRef\]](#)
42. Sobanski T, Wagner G. Functional neuroanatomy in panic disorder: Status quo of the research. *World J Psychiatry*. 2017;7(1):12-33. [\[CrossRef\]](#)
43. Canteras NS, Graeff FG. Executive and modulatory neural circuits of defensive reactions: Implications for panic disorder. *Neurosci Biobehav Rev*. 2014;46(3):352-364. [\[CrossRef\]](#)
44. Graeff FG, Zangrossi H, Jr. The dual role of serotonin in defense and the mode of action of antidepressants on generalized anxiety and panic disorders. *Cent Nerv Syst Agents Med Chem*. 2010;10(3):207-217. [\[CrossRef\]](#)
45. Carless MA, Glahn DC, Johnson MP, et al. Impact of DISC1 variation on neuroanatomical and neurocognitive phenotypes. *Mol Psychiatry*. 2011;16(11):1096-1104, 1063. [\[CrossRef\]](#)



46. Lai CH, Wu YT. The explorative analysis to revise fear network model for panic disorder: Functional connectome Statistics. *Stat Med*. 2016;95(18):e3597. [\[CrossRef\]](#)
47. Graeff FG, Del-Ben CM. Neurobiology of panic disorder: From animal models to brain neuroimaging. *Neurosci Biobehav Rev*. 2008;32(7):1326-1335. [\[CrossRef\]](#)
48. Nagai M, Kishi K, Kato S. Insular cortex and neuropsychiatric disorders: A review of recent literature. *Eur Psychiatry*. 2007;22(6):387-394. [\[CrossRef\]](#)
49. Dresler T, Hahn T, Plichta MM, et al. Neural correlates of spontaneous panic attacks. *J Neural Transm (Vienna)*. 2011;118(2):263-269. [\[CrossRef\]](#)