

# A Patient-Centered Integrative Approach Improves Visual Field Defect: A Case Report

Global Advances in Health and Medicine

Volume 10: 1–8

© The Author(s) 2021

Article reuse guidelines:

sagepub.com/journals-permissions

DOI: 10.1177/21649561211021081

journals.sagepub.com/home/gam



Lan Kao, DACM, LAc, Dipl OM<sup>1</sup>, Ka-Kit Hui, MD, FACP<sup>1,2</sup> , and Edward Hui, MD, FACP<sup>1,2</sup> 

## Abstract

We present a case involving a patient with a complicated visual field defect preventing her from renewing her driver license. It highlights the underappreciated role of chronic stress in the genesis and perpetuation of ill health and the potential of Chinese medicine (CM) to complement biomedicine in the treatment of an intractable visual disorder. The patient experienced impaired vision from age 15, and ophthalmologists considered various diagnoses including optic neuritis and acute zonal occult outer retinopathy (AZOOR)-complex disorder with acute macular neuroretinopathy. She was treated with an integrative East-West medical approach incorporating acupuncture, cupping, trigger point injections, guidance on self-care and lifestyle modification. Although the eye disorder was not cured, there was visual improvement as demonstrated by various objective ophthalmologic tests, and the patient was able to renew her driver license. Visual improvement remained stable upon follow-up examination three years after the treatment intervention. Other concomitant health issues reported by the patient also improved including amelioration of neck pain, a more regular menstrual cycle, and decreased anxiety. This case demonstrates how a patient with an intractable complex eye disorder can have objective visual improvement when treated with an integrative patient-centered approach.

## Keywords

visual field defect, acupuncture, chronic stress, patient-centered, integrative medicine

Received September 3, 2020; Revised May 4, 2021. Accepted for publication May 7, 2021

## Introduction

Visual functioning is an important measure of physiological functioning, health and quality of life.<sup>1</sup> A study of 67,500 adults found visual impairment can adversely affect activities of daily living in older and younger adults, and for some the physical disability can stop them from driving altogether.<sup>2,3</sup> A 2014 public poll found Americans are more concerned about losing their eyesight and the impact it would have on everyday life than other conditions such as loss of hearing, memory or speech.<sup>4</sup> According to the Centers for Disease Control and Prevention, vision loss ranks among the top ten causes of disability and will continue to increase in the future as the population gets older and diseases such as diabetes also increase. Despite advances in modern ophthalmology, no proven treatment or management options exist in biomedicine for certain eye

disorders including optic neuritis, acute zonal occult outer retinopathy (AZOOR)-complex disorder, or acute macular neuroretinopathy.

Integrative medicine and health, with its greater appreciation of stress-related symptoms and conditions, is facilitating the shift from identification of disease to intervention in pathogenetic biological trajectories even before they develop into specific disease patterns.<sup>5</sup>

<sup>1</sup>UCLA Department of Medicine, UCLA Center for East-West Medicine, University of California Los Angeles, Los Angeles, California

<sup>2</sup>UCLA Department of Medicine, David Geffen School of Medicine, University of California Los Angeles, Los Angeles, California

### Corresponding Author:

Edward Hui, UCLA Department of Medicine, UCLA Center for East-West Medicine, University of California Los Angeles, 1015 Gayley Avenue, Suite 301, Los Angeles, CA 90024, USA.

Email: ehui@mednet.ucla.edu



There is strong evidence that chronic stress can lead to adverse effects on physiology and childhood exposure to stress can lead to adverse effects on health in adulthood.<sup>6</sup> When stress is sustained, primary mediators including catecholamines, cortisol, and proinflammatory cytokines, engender a series of physiological effects

leading to subclinical changes in various secondary outcomes: neurobiological, metabolic, cardiovascular, and immune. The impact of stress on health and function is well recognized in Chinese medicine (CM), as its inherent mind-body-spirit approach considers the whole person and their environment. In CM, the eyes (as can

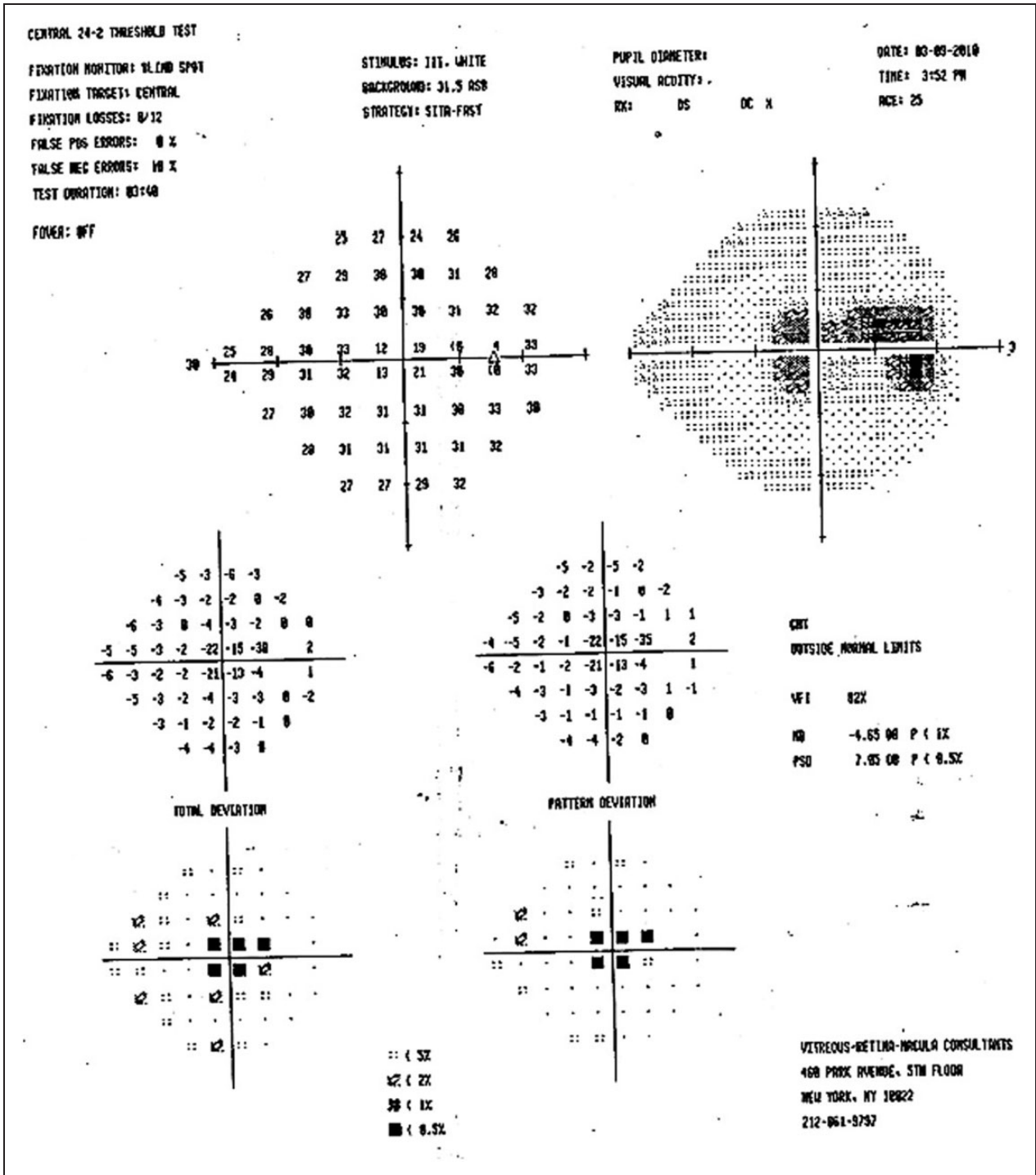


Figure 1. Single Field Analysis of the Right Eye From Vitreous-Retina-Macula Consultants on March 9, 2010 (Prior to Treatments at CEWM).

other sense organs) reflect the physiological functioning of the viscera, homeostasis of the body, psychological and emotional state of the whole person.

We present a patient who experienced sustained stress for half of her life, and this may have negatively impacted her vision. Although she compensated initially for the visual deficit, over time it affected her quality of life and functioning, and she was diagnosed with conditions ranging from optic neuritis to AZOOR-complex disorder with acute macular neuroretinopathy and central serous retinopathy. An integrative approach was utilized with the CM principle that eye disease does not exist in isolation but is rather a manifestation of imbalances and dysfunction in other parts of the body.<sup>7</sup> Aside from her visual disorder, other physiological dysfunctions and the totality of stressors (psychosocial, mechanical and metabolic) also needed to be addressed in the intervention. Her vision improved through this approach to eye health blending diagnostic principles and therapeutics of CM with biomedicine.

## Case

### Patient Information

A 29-year-old woman was referred to the clinical program at the Center for East-West Medicine (CEWM) within University of California Los Angeles (UCLA) Health for evaluation and management of visual field

defect (VFD) in both eyes but worse in the right eye. She had recently relocated to California and worked as a project manager in the entertainment industry. Her visual deficit began to impede her daily functioning, and she was not able to renew her driver license after failing the vision test at the California Department of Motor Vehicles in 2014.

Her ophthalmologic history started with visual distortions in the periphery of her right eye at age 15 in 2000. An ophthalmologist diagnosed optic neuritis, but she was not treated. There was a blind spot in the inferotemporal visual field of the right eye. In 2008, she underwent photorefractive keratectomy. In 2009, a significant decrease in central vision of the right eye with subsequent evaluation by several retinal specialists led to diagnoses of acute macular neuroretinopathy and central serous retinopathy. Magnetic resonance imaging of the neuraxis and lumbar puncture were unremarkable, and an infectious workup proved unrevealing. A neurologist treated her with corticosteroids without improvement in her vision. The visual distortion could not be improved with corrective lenses either. In October of 2009, a retinal specialist in New York City documented no evidence of retinal vascular occlusion. Choroidal thickness measurements in the normal range argued against central serous chorioretinopathy, and scans over the right optic nerve revealed debris consistent with vitreous cells indicative of an inflammatory or possibly infectious process. Based on the physical examination findings of

**Table 1.** Timeline of Interventions and Outcomes.

	Trigger Point Injections	Acupuncture 30 min	Cupping	Lifestyle and Nutritional Counseling	Response to Treatment
October 27, 2014					
Consultation Only					
November 14, 2014	Splenius, capitis, trapezius	LI4, LR3, ST36, SP6, LI10, GB20, GB34, SP9, SPI0			Reduced tension in the neck, shoulder
November 19, 2014	Trapezius	PC6, SP6, SP9, GV20, MS14, SI3, SI13, BL23, BL65		x	Improvement with visual field defect (VFD)
December 10, 2014	Trapezius, infraspinatus	GV20, BL10, BL18, BL20, BL22, MS14	Neck, shoulder	x	Symptoms recurred due to lapse in treatment, L-eye worse than R-eye
December 22, 2014	Splenius, trapezius	GV14, GB21, BL18, BL20, BL22, PC7, MS14	Neck	x	Patient noted visual improvement
January 14, 2015	Trapezius, splenius capitis (right), levator	GV14, GV20, BL10, BL18, BL20, BL23, PC7, SP3, HT8	Neck (left)	x	Self-reported 15% visual improvement
February 23, 2015	Trapezius, splenius cervicis, multifidus (right)	GV20, PC7, SP3, HT8, SI3, BL10, BL18, BL20, BL23, MS14		x	L-eye is clear, no blind spots; and R-eye has a blind spot but smaller than what it was prior to treatment
July 1, 2015	Trapezius, levator scapulae	GV20, BL18, BL20, PC7, SP3, MS14,	Neck	x	Sustaining visual improvement; R-eye has an opaque blind spot, L-eye is clear but fluctuates

outer retinal thinning, she was diagnosed with AZOOR-complex disorder with acute macular neuroretinopathy. Confirmatory diagnostic testing and ophthalmologic evaluation at Mount Sinai Hospital supported this diagnosis and concluded a prior misdiagnosis of optic neuritis. In 2011, peripheral VFD had arisen in the left eye. From 2009 to 2014, her visual disorder went untreated. The only records available from the preceding discussion is a single field analysis from March 2010 mapping the visual field in her right eye, which showed a blind spot in the central vision (Figure 1).

### Clinical Findings

Her first visit to CEWM was in October 2014. Our evaluation and assessment demonstrated a woman presenting with VFD along with myofascial neck pain, irregular menstrual cycles, loose stools, and anxiety. Stress at work was ongoing, and her diet consisted of convenient on-the-go foods such as salads and sandwiches. She had quit smoking less than a year prior. The patient related a turbulent childhood, especially during early adolescence, coinciding with the development of her visual problem. The shock and distress of having to witness her younger

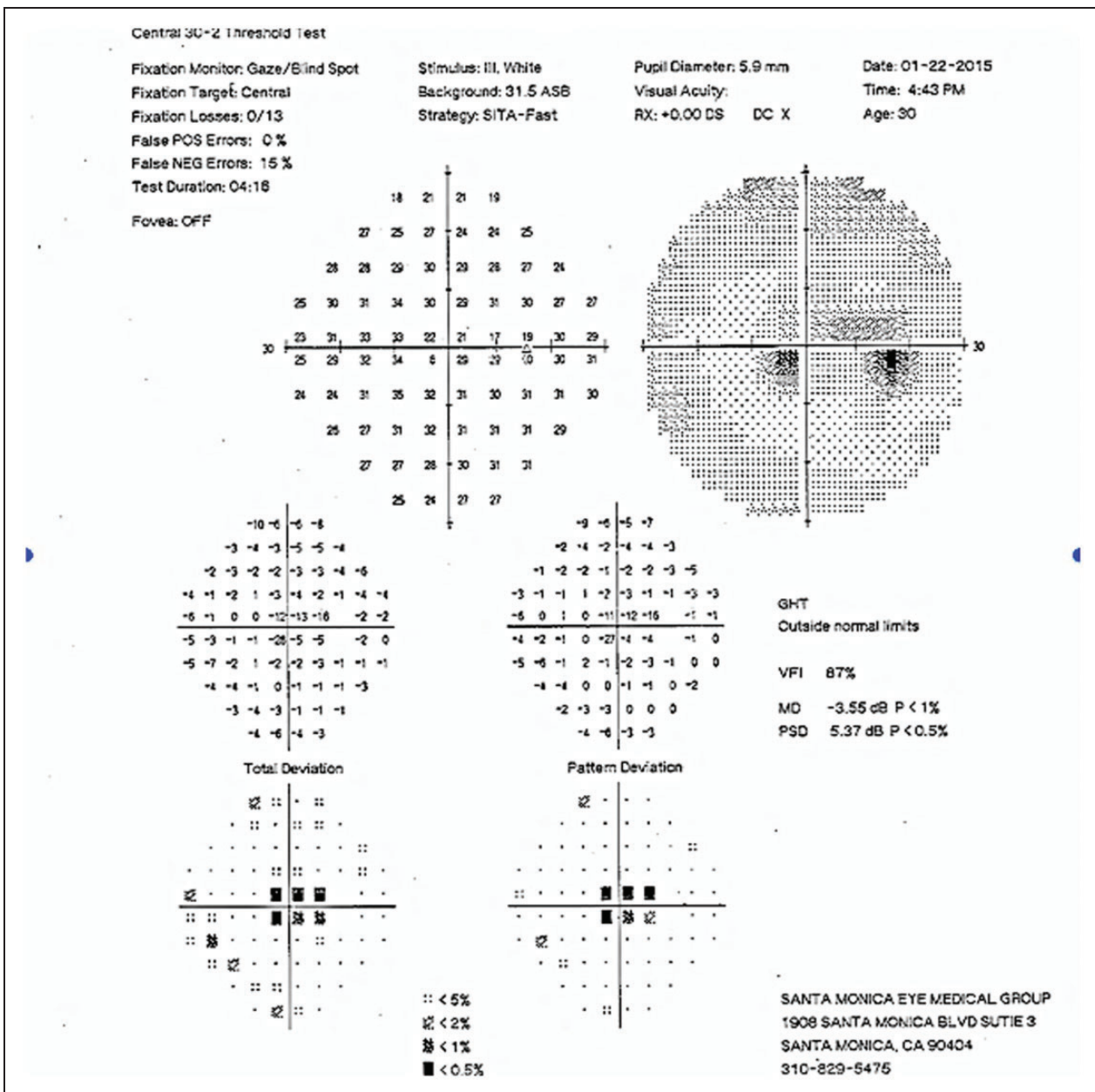


Figure 2. A Single Field Analysis of the Right Eye on January 22, 2015 Showing Improvement With the Decreased Size of the Dark Spot in the Central Vision.

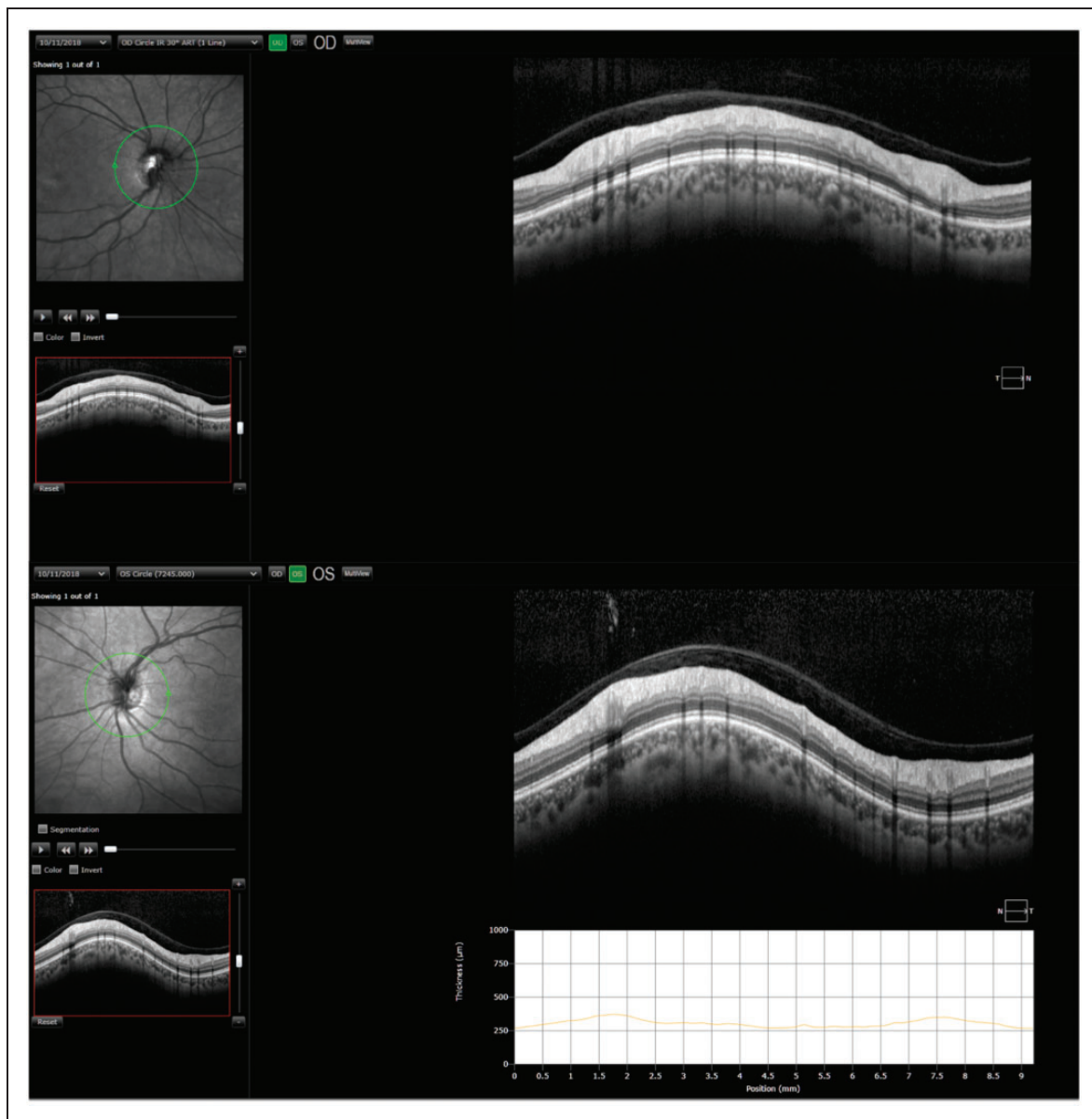

sister, with bipolar and borderline personality disorder, uncontrollably physically beat her mother remained fresh in her mind. Her father had what she described as a “scary temper”, and she felt emotionally and verbally abused by him. This home situation persisted for many years until she was able to move out as a young adult.

## Methods

CM differential diagnosis in this case was Stagnation of Liver Qi and Blood with Spleen and Stomach Qi Deficiency. The patient’s history of emotional stress and trauma over time (i.e. Liver Qi Stagnation) led to other bodily dysfunctions manifesting as myofascial

neck pain, irregular menstrual cycles, loose stools, and anxiety (i.e. all manifestations of Spleen and Stomach Qi Deficiency). A comprehensive treatment regimen for each clinical visit including acupuncture with needle retention at specific acupoints on the body and head for 30 minutes, cupping, trigger point injections (TPIs), lifestyle and nutritional counseling, and self-care guidance was delivered every one to two weeks and totaling six treatments over a period of four months (Table 1). Primary acupoints administered in various combinations for each session included GV14, GV20, GB20, BL10, BL18, BL20, BL23, PC6, PC7, SP3, SP6, HT8, and MS14 (Table 1). Cupping is a CM modality for myofascial release commonly



**Figure 3.** OCT Heidelberg Spectralis on October 11, 2018 from Jules Stein Eye Institute.

administered after acupuncture. Lifestyle counseling entailed providing the patient with tools to optimize stress management, regulation of emotions, physical activity and exercise, and sleep hygiene. Nutritional counseling was personalized for the patient, involving recommendations to limit alcohol consumption, to eat regularly, and increase consumption of cooked foods in preference to raw foods.

### Results

The patient tolerated the interventions without adverse effects, and occasionally experienced emotional cathartic release during and after acupuncture. By the fifth visit on 1/14/2015, the patient reported her vision as the clearest it had been in six years. Improvements were seen on

the single field analysis when she was reevaluated by an ophthalmologist at Santa Monica Eye Medical Group (SMEMG) on 1/22/2015 showing the dark spot in the central vision in the right eye had reduced in size and visual field index (VFI) improvement from 82% on 3/9/2010 (Figure 1) to 87% (Figure 2) which allowed for renewal of eye prescription necessary for the patient to retake the driving test. She successfully renewed her driver license in April 2015. At five months follow up visit on 7/1/15, she reported sustaining visual improvement. Reevaluation three years later by a neuro-ophthalmologist at Jules Stein Eye Institute on 10/11/2018 revealed unchanged decreased visual acuity in the right eye, trace afferent pupillary defect in the right eye, mild temporal pallor in the right optic nerve and mildly thin macula with dull reflex (Figure 3). The left optic

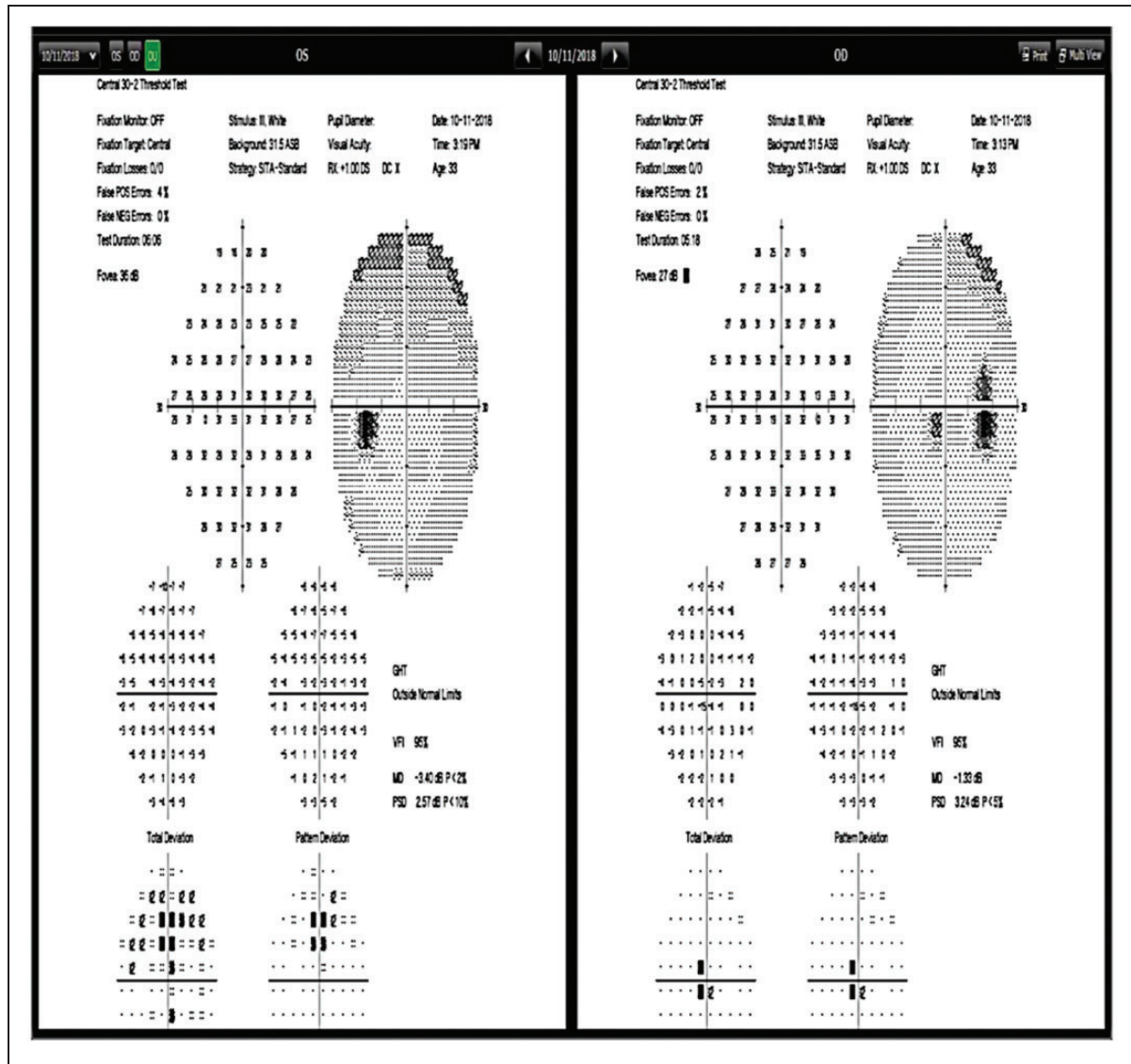


Figure 4. Humphrey Visual Field Administered on October 11, 2018.

nerve and maculae appeared normal on dilated fundus exam. These findings were unchanged compared to visual field test performed at SMEMG on 1/22/15. The Humphrey visual field performed on 10/11/2018 (Figure 4) also showed improvement in VFI at 95% in the right eye, higher than what it was on 1/22/15.

## Discussion

Here we have illustrated the importance of recognizing chronic stress in the genesis and perpetuation of ill health and disease as well as the potential of CM to complement biomedicine in the treatment of intractable visual problems. An integrative approach to eye health that blends diagnostic principles and therapeutics of CM with biomedicine allows for a comprehensive treatment strategy encompassing psychosocial, personalized, and holistic care that treats the whole person. This case further highlights the relevance of studying the “effectiveness of complex, personalized clinical interventions”<sup>8,9</sup> and the importance of whole systems research in complementary and integrative medicine.

There is accumulating evidence that suggests the clinical efficacy of acupuncture for a wide variety of conditions<sup>10–13</sup> by modulating the limbic system,<sup>14</sup> lowering blood pressure,<sup>15</sup> improving sleep quality,<sup>16,17</sup> decreasing cortisol levels,<sup>18</sup> facilitating release of endogenous opioids,<sup>19</sup> decreasing inflammation,<sup>20</sup> and regulating neurotransmitters.<sup>21</sup> One of the earliest clinical studies in biomedicine evaluating the utility of acupuncture in ophthalmology conducted by Wong and Ching (1979) detailed 500 cases treated with acupuncture and reported symptomatic relief for retinitis pigmentosa, high myopia, cataracts, surgical aphakia, controlled glaucoma, and detached retina.<sup>22</sup> In 2003, Li et al. reported the effects of acupuncture on visual cortices in the brain and on vision.<sup>23</sup> The World Health Organization included potential indications for acupuncture for eye disorders such as Sjogren’s syndrome, central serous choroidopathy, and color blindness in their 2003 official report on the effectiveness of acupuncture based on data from clinical trials.<sup>24</sup>

An integrative East-West patient-centered approach, which has been successfully used in other chronic conditions,<sup>25</sup> can be considered for its potential application to eye disorders. Though the patient’s visual disorder was not cured, her vision improved enabling renewal of her driver license, and there was concurrent improvement in well-being with decreased burnout and increased resilience. From the patient’s perspective, knowing that something could be done to improve her vision was a tremendous relief given the fear and specter of total vision loss. We hope this case will draw further interest in the potential utility of integrating CM with biomedicine for the management of intractable eye disorders.

## Availability of Data and Material

The data used and analyzed during the current study are available from the corresponding author upon reasonable request.

## Consent for Publication

A written consent from the patient was obtained and stored on file for this case presentation.

## Acknowledgments

The authors would like to thank Dr. Brad Straatsma, professor emeritus in the Department of Ophthalmology at the UCLA Stein Eye Institute (formerly known as the Jules Stein Eye Institute), and Dr. Carolina Ortube for their feedback of the manuscript. The authors would also like to acknowledge Alex Wang for his contribution with literature retrieval.

## Authors’ Contributions

LK contributed to the conceptualization and writing of the manuscript. EH contributed to the conceptualization and writing of the manuscript. KKH edited the manuscript. All authors have read and approved the final manuscript.

## Declaration of Conflicting Interests


The author(s) declared no potential conflicts of interest with respect to the research, authorship, and/or publication of this article.

## Funding

The author(s) disclosed receipt of the following financial support for the research, authorship, and/or publication of this article: This clinical case report was financially supported by the Long Family Foundation, Gerald Oppenheimer Family Foundation, and Panda Charitable Foundation in providing salary support for the authors’ time in reviewing the medical literature and writing the manuscript.

## ORCID iDs

Ka-Kit Hui  <https://orcid.org/0000-0001-6490-1148>

Edward Hui  <https://orcid.org/0000-0002-9744-9706>

## References

1. Taipale J, Mikhailova A, Ojamo M et al. Low vision status and declining vision decrease health-related quality of life: results from a nationwide 11-year follow-up study. *Qual Life Res.* 2019;28(12):3225–3236.
2. Swanson M, McGwin G. Visual impairment and functional status from the 1995 National Health Interview Survey on Disability. *Ophthalmol Epidemiol.* 2004;11 (3): 227–239.
3. Vitale S, Cotch MF, Sperduto RD. Prevalence of visual impairment in the United States. *JAMA.* 2006;295(18): 2158–2163.
4. Scott AW, Bressler NM, Ffolkes S, Wittenborn JS, Jorkasky J. Public attitudes about eye and vision health. *JAMA Ophthalmol.* 2016;134(10):1111–1118.

5. McEwen BS, Getz L. Lifetime experiences, the brain and personalized medicine: an integrative perspective. *Metabolism*. 2013;62(1):S20–S26.
6. Hill MN, Eiland L, Lee TT, Hillard CJ, McEwen BS. Early life stress alters the developmental trajectory of corticolimbic endocannabinoid signaling in male rats. *Neuropharmacology*. 2019;146:154–162.
7. Wei Q, Rosenfarb A, Liang L. *Ophthalmology in Chinese Medicine* (Vol. 13). New Haven, CT: PMPH-USA; 2011.
8. Ijaz N, Rioux J, Elder C, Weeks J. Whole systems research methods in health care: a scoping review. *J Alternat Complement Med*. 2019;25(S1):S21–S51.
9. Elder C, Ijaz N, Weeks J, Rioux J, Ritenbaugh C. convergent points for conventional medicine and whole systems research: a user's guide. *J Alternat Complement Med*. 2019;25(S1): S12–S16.
10. Macpherson H, Tilbrook HJ, Bland JM et al. Acupuncture for irritable bowel syndrome: primary care based pragmatic randomized controlled trial. *BMC Gastroenterol*. 2012;12:150.
11. MacPherson H, Richmond S, Bland M et al. Acupuncture and counseling for depression in primary care: a randomized controlled trial. *PLOS Med*. 2013;10(9):e1001518. Emmons SL, Otto L. Acupuncture for overactive bladder: a randomized controlled trial. *Obstet Gynecol*. 2005;106(1):138–143.
12. Lomuscio A, Belletti S, Battezzati PM, Lombardi F. Efficacy of acupuncture in preventing atrial fibrillation recurrences after electrical cardioversion. *J Cardiovasc Electrophysiol*. 2011;22(3):241–247.
13. Berman BM, Langevin HM, Witt CM, Dubner R. Acupuncture for chronic low back pain. *N Engl J Med*. 2010;363(5):454–461.
14. Hui KK, Marina O, Liu J, Rosen BR, Kwong KK. Acupuncture, the limbic system, and the anticorrelated networks of the brain. *Auton Neurosci*. 2010;157(1–2):81–90.
15. Li P, Longhurst JC. Neural mechanism of electroacupuncture's hypotensive effects. *Auton Neurosci*. 2010;157(1–2):24–30.
16. Frisk J, Kallstrom AC, Wall N, Fredrikson M, Hammar M. Acupuncture improves health-related quality-of-life (HRQoL) and sleep in women with breast cancer and hot flushes. *Support Care Cancer*. 2012;20(4):715–724.
17. Sarris J, Byrne GJ. A systematic review of insomnia and complementary medicine. *Sleep Med Rev*. 2011; 15(2):99–106.
18. Harbach H, Moll B, Boedeker RH et al. Minimal immunoreactive plasma beta-endorphin and decrease of cortisol at standard analgesia or different acupuncture techniques. *Eur J Anaesthesiol*. 2007;24(4):370–376.
19. Lin JG, Cjen WL. Acupuncture analgesia: a review of its mechanisms of actions. *AM J Chin Med*. 2008; 36(4):635–645.
20. Choi DC, Lee JY, Moon YJ, Kim SW, Oh TH, Yune TY. Acupuncture-mediated inhibition of inflammation facilitates significant functional recovery after spinal cord injury. *Neurobiol Dis*. 2010; 39(3): 272–282.
21. Wen G, He X, Lu Y, Xia Y. *Effect of Acupuncture on Neurotransmitters/Modulators*. Berlin, Germany: Springer; 2010:120–142.
22. Wong S., Ching R. The use of acupuncture in ophthalmology. *Am J Chin Med*. 1980;8(2):104–153.
23. Li G, Cheung RTF, Ma Q, Yang E. Visual cortical activations on fMRI upon stimulation of the vision-implicated acupoints. *Brain Imaging*. 2003;14(5):669–673.
24. WHO Acupuncture. Review and analysis of reports on controlled clinical trials, 2003. *Report (Rapport)*. 2016. <http://digicollection.org/hss/en/d/Js4926e/>
25. Pritzker S, Katz M, Hui K. Person-centered medicine at the intersection of East and West. *Eur J Person Center Healthc*. 2012;3(1):209–215.