

The management of hidradenitis suppurativa degenerating into squamous cell carcinoma: About three case reports

Souhaib Atri^{a,c}, Ahmed Ben Mahmoud^{a,c,*}, Alia Zehani^{b,c}, Amine Chammakhi^{a,c},
Wael Rebai^{a,c}, Montasser Jameleddine Kacem^{a,c}

^a Department of Surgery A, Rabta Hospital, Tunis, Tunisia

^b Department of Pathology, Rabta Hospital, Tunis, Tunisia

^c Faculty of Medicine of Tunis, Tunis El Manar University, Tunis, Tunisia

ARTICLE INFO

Keywords:

Hidradenitis suppurativa
Squamous cell carcinoma
Verneuil's disease

ABSTRACT

Introduction and importance: Hidradenitis suppurativa (HS) is a chronic inflammatory and suppurative disease of the apocrine sweat glands. Its transformation into squamous cell carcinoma (SCC) is very rare.

Case presentation: We describe 3 cases of males aged 57, 58 and 55-years-old. The diagnoses were confirmed by pathology examination in all cases. Two of our patients underwent extended and complete surgery. The first two patients died during the year after the diagnosis was established, the third one is still alive with no recurrence after one year of surgery.

Clinical discussion: Hidradenitis suppurativa mostly concerns perianal location and it targets mainly male patients with a multifactorial development. Surgical treatment consists of large excision. The SCC is associated with a high mortality rate.

Conclusion: Hidradenitis suppurativa needs early diagnosis and effective surgery. The transformation into squamous cell carcinoma is rare and its management is challenging. Extended and complete excision is required with rigorous postoperative follow-up.

1. Introduction

Verneuil's disease (VD) or Hidradenitis suppurativa (HS) is a chronic, recurrent, inflammatory and suppurative skin disorder of the apocrine sweat glands [1], firstly described by Alfred Velpeau in 1839 [2] and it's only in 1854 that the French surgeon Aristide Verneuil described the disease and its association with sweat glands [3].

The evolution is chronic, recurrent and extensive, with a very rare rate of comorbidity, although the long progression of the disease can lead to a various complications, and one of them is degeneration in a cell squamous carcinoma reported for the first time by Anderson in 1958 [4]. It occurs in approximately 4–6% of perineal HS [5] with very high morbidity and rarely efficient treatment.

We report in this article the challenging management from pathology confirmation to postoperative follow-up in three patients with a surgical history of perineal surgery for benign condition, presenting with transformation into squamous cell carcinoma (SCC).

The work has been reported in line with the SCARE 2020 criteria [6].

2. Case reports

2.1. First case

A 57 years Old man, a heavy smoker, followed for 20 years in our department for recurrent anal fistulas. A biopsy with pathology examination showed Hidradenitis suppurativa. The evolution was marked by recurrence and extension of the lesions, despite iterative excisions. Magnetic resonance imaging (MRI) of the perineum had objectified multiple inter- and extra-sphincter fistulous paths reaching the soft parts of the buttock and the inner surface of the right thigh associated with multiple collections (Fig. 1). On sight of these data, the patient underwent an extensive surgical excision with a lateral diverting colostomy (Fig. 2).

After five-years-lost, he returned with a voluminous tumor mass extended from the anal region to the upper third of the thigh. On abdominopelvic CT-scan, we found a large tumor invading the prostate, seminal vesicles, gluteal soft tissue of the right thigh associated with

* Corresponding author. Department of Surgery "A", La Rabta Hospital, La Rabta Jebbari, 1007, Tunis, Tunisia.

E-mail address: ahmed.benmahmoud92@gmail.com (A. Ben Mahmoud).

<https://doi.org/10.1016/j.amsu.2021.102239>

Received 20 February 2021; Received in revised form 14 March 2021; Accepted 18 March 2021

Available online 24 March 2021

2049-0801/© 2021 The Authors. Published by Elsevier Ltd on behalf of IJS Publishing Group Ltd. This is an open access article under the CC BY-NC-ND license

(<http://creativecommons.org/licenses/by-nc-nd/4.0/>).

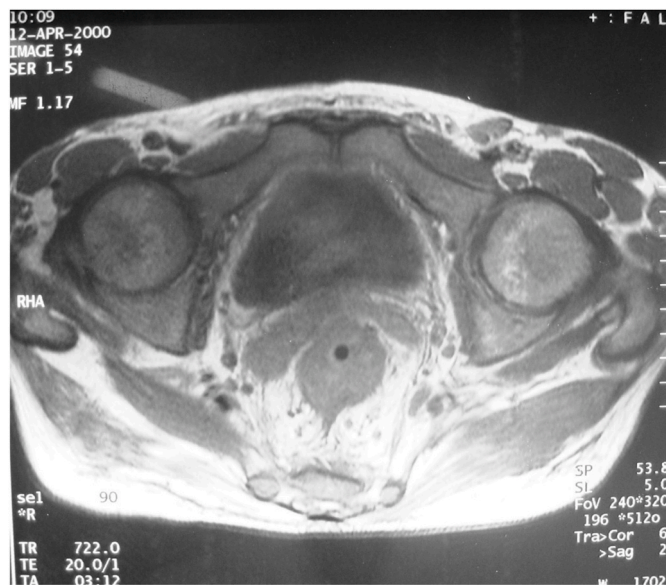


Fig. 1. Magnetic resonance imaging of the perineum: presence of multiple non-communicating fistulous paths with the rectum.

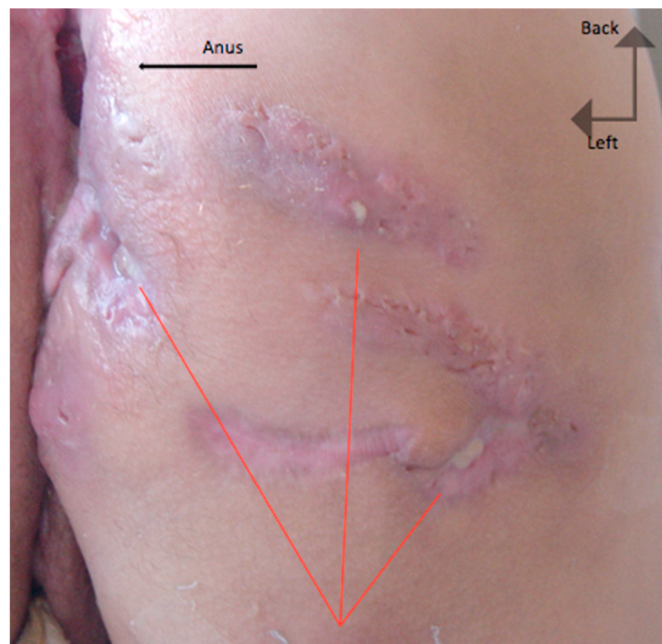


Fig. 2. Genupectoral position: presence of multiple suppurative lesions (red arrow) associated with complete destruction of the sphincter apparatus (black arrow). (For interpretation of the references to colour in this figure legend, the reader is referred to the Web version of this article.)

bilateral iliac lymph nodes and secondary bone lesions of the right femur. A surgical biopsy was performed on the tumor mass, and the pathology findings revealed an infiltrating well-differentiated squamous cell carcinoma. The patient underwent palliative radio-chemotherapy. He died six months after the start of treatment.

2.2. Second case

A 58-year-old patient with 15 years history of hidradenitis suppurativa, operated repeatedly for perianal and buttock's abscess who has been lost to follow-up for the last three years.

He presented to our emergency department with a purulent and painful drainage. Physical examination showed an altered general state, a very important weight loss, and a large loss of substance, in the aspect of an erythematous crater, extending over the entire buttock with dilapidated perineum and purulent, sanguineous drainage (Fig. 3).

The CT scan showed a voluminous tissular process of the anal region extended to the adjacent organs with lysis of the coccyx, sacrum, ischium and, left acetabulum (Fig. 4).

Perineal and gluteal biopsies concluded on poorly differentiated squamous cell carcinoma.

Onsight of the high progression of the disease and the very bad general state, the patient had a diverting colostomy and was discharged to hospice. The patient died after 3 weeks.

2.3. Third case

A 55-year-old man who underwent surgery several times in the last 10 years for gluteal abscesses. He presented to our surgery department for painful perianal region. Verneuil's disease was suspected on physical examination but also a crohn's disease with perianal lesions was also discussed. The diagnosis of hidradenitis suppurativa was confirmed on biopsies of the buttock. He underwent a surgical excision 2 years ago.

Currently, the patient complaint of a recurrence of lesions in the 2 buttocks with the aspect of several scar indurations with some localized vegetations. Biopsies were performed, and histopathology examination revealed malignant tumor infiltration, spreading in irregular islands through the dermis. Tumor cells were pleomorphic, having eosinophilic cytoplasm and vesicular nuclei. There were keratin pearls and individual keratinization. The diagnosis of moderately differentiated squamous cell carcinoma was set (Fig. 5). The patient is resumed for extensive and complete resection of all the lesions. The postoperative course was eventless and a 6-month follow-up showed no recurrence.

3. Discussion

Hidradenitis suppurativa is a recurrent, debilitating skin disease characterized by its long-term evolution. In the cases of our patients they had 10–20 years of evolution, it can be associated with Crohn's disease or conglobate acne [7,8] which makes the diagnosis challenging, as shown with our first patient.

With the long-term evolution, many serious complications can occur such as cellulitis or abscess and even lymphatic obstruction [9]. However, degeneration to squamous cell carcinoma still the most dreadful complication. Since its first description by Anderson in 1958 [10], and Jackman in 1959 [8], there were a few reported cases in the literature.

In 2018 Chapman et al. [11] reviewed 85 patients, the majority was summarized in case reports. While HS appears to be significantly more common among women [12], the degeneration into SCC is predominant in men [13], this difference may be due to the fact that the malignant degeneration is seen mainly in the buttocks and perianal region, which is the most commonly affected site in men [12]. In our 3 cases, all the patients were men and the disease was located in the buttock region.

To date, data are not so clear about pathophysiology of hidradenitis suppurativa and the malignant transformation to SCC, beside the chronic states of inflammation, that procure a favorable environment for oncogenesis through the dysregulation of tumor suppressor genes and self-sufficient growth, leading to genetic mutations and cell DNA. There are many other factors involved such as obesity and smoking that contribute to the incidence and severity of the disease, and are associated with malignant transformation [5]. Moreover, Lavogiez et al. [14] reported the involvement of HPV-16 infection in the degeneracy. In our review, 2 of our patient was heavy smokers and the HPV infection was not sought.

The diagnosis of SCC can be particularly challenging. That's why it is recommended to perform a biopsy with a histopathologic examination at the slightest suspicion and repeat deep biopsies in any atypical non-

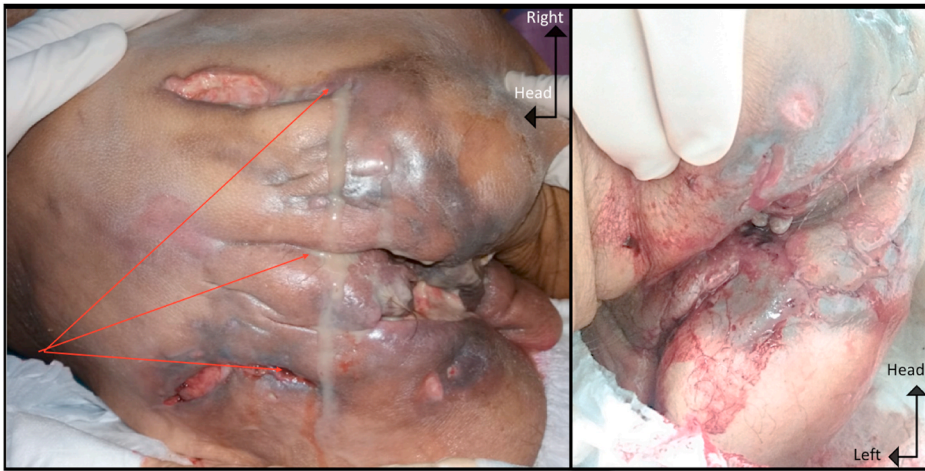


Fig. 3. Large loss of substance, in the aspect of an erythematous crater, extending over the entire buttock with dilapidated perineum and purulent, sanguinous drainage.

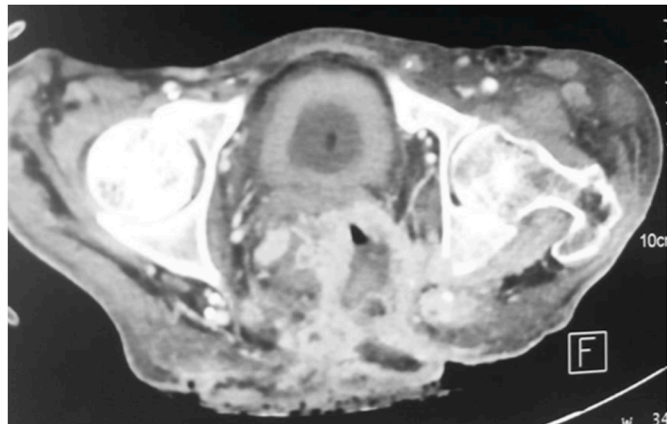


Fig. 4. Voluminous tissue process of the anal region extended to the surrounding organs with lysis of the coccyx, sacrum, ischium and, left acetabulum.

healing lesions.

CT-scan and Magnetic resonance imaging may help establish the true extent of the disease, lymph node evaluation, and surveillance after surgery.

The treatment of hidradenitis suppurativa is not very well established. In 1989, Hurley suggested a preliminary clinical staging [15]. This classification can be useful in the therapeutic choice (Table 1)

According to this staging, medical treatment is recommended in the early stage. However, surgical excision should be considered in stages II and III.

In case of degeneration into squamous cell carcinoma, an aggressive approach is critical in preventing significant morbidity and mortality. Jourabchi et al. [5] recommend large and deep surgical excision, with a minimum margin of 2 cm when possible.

At this stage, disease-free survival is 33% in one year. In case of recurrence, half of the patients die with metastases [13,16].

Radiation therapy is only recommended in those patients who do not undergo surgery. Chemotherapy has not been shown to be effective. It is followed by high morbidity with frequent chemoresistance.

4. Conclusion

The transformation of hidradenitis suppurativa into squamous cell carcinoma is a scarce complication with an unfortunate prognosis. We insist on the need for early diagnosis, and a radical surgical approach, with rigorous long-term surveillance to avoid any fatal evolution.

Ethical approval

There is no ethical committee in our country (Not applicable for this Manuscript).

Table 1
Hurley's classification.

| | |
|------------|---|
| Grade I: | Abscess formation, single or multiple without sinus tracts and cicatrization |
| Grade II: | Recurrent abscess with tract formation and cicatrization. Single or multiple, widely separated lesions |
| Grade III: | Diffuse or near-diffuse involvement, or multiple interconnected tracts and Abscesses across entire area |

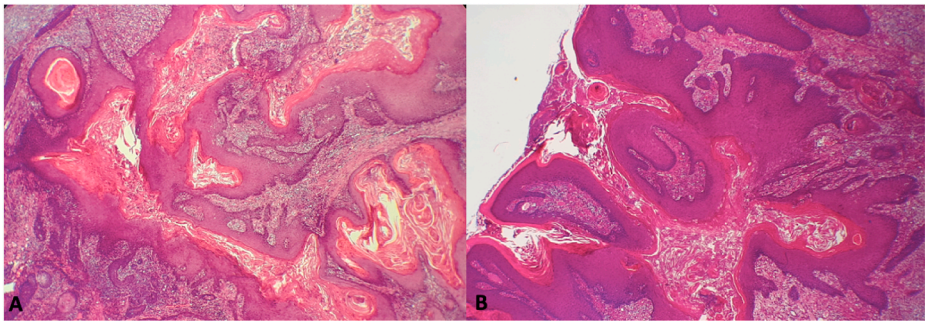


Fig. 5. A-Cystic dilated structures in the dermis, surrounded by a dense inflammatory infiltrate (HEx10). B- Acanthotic, papillomatous and hyperkeratotic epidermis invading deep into the dermis (Hex4).

Sources of funding

No sources of funding.

Trial registry number

It's a cases report.

Consent for publication

Written informed consent was obtained from the patients for publication of this case series and any accompanying images. A copy of the written consents is available for review by the Editor-in-Chief of this journal on request.

Provenance and peer review

Not commissioned, externally peer reviewed.

Guarantor

Ahmed Ben Mahmoud.

Author contribution

Souhaib Atri: Article Writing and literature review.
 Ahmed Ben Mahmoud: Article Writing.
 Alia Zehani: Analyzed and interpreted pathology data.
 Amine Chammakhi: Analyzed and interpreted patient's data.
 Wael Rebai: Performed surgery.
 Montasser Jameleddine Kacem: Article concept and review.

Declaration of competing interest

All authors declare that they have no conflicts of interest.

References

- [1] J. Arnous, La maladie de Verneuil, *Ann. Gastroenterol. Hepatol.* 12 (1976).

- [2] Velpeau A. Dictionnaire de médecine, un repertoire générale des Sciences Medicales sous le rapport theorique et prat ». .
- [3] A. Verneuil, *Etudes sur les tumeurs de la peau; de quelques maladies des glandes sudoripares*, *Arch Gen Med* 4 (1854) 447.
- [4] H.J. Donsky, et C.G. Mendelson, Squamous cell carcinoma as a complication of hidradenitis suppurativa, *Arch. Dermatol.* 90 (1964), <https://doi.org/10.1001/archderm.1964.01600050036008>.
- [5] N. Jourabchi, A.H. Fischer, A. Cimino-Mathews, K.M. Waters, et G.A. Okoye, Squamous cell carcinoma complicating a chronic lesion of hidradenitis suppurativa: a case report and review of the literature: squamous cell carcinoma complicating a chronic lesion of hidradenitis suppurativa, *Int. Wound J.* 14 (2017) 435–438, <https://doi.org/10.1111/iwj.12671>.
- [6] R.A. Agha, T. Franchi, C. Sohrabi, G. Mathew, for the SCARE Group, The SCARE 2020 guideline: updating consensus surgical CAse REport (SCARE) guidelines, *Int. J. Surg.* 84 (2020) 226–230.
- [7] R. Mouly et, C. Dufonrmentel, La maladie de Verneuil, *Chir. Mém. L'Académie* 10 (1977).
- [8] R.J. Jackman, Hidradenitis suppurative: diagnosis and surgical management of perianal manifestations, *Proc. Roy. Soc. Med.* 52 (1959).
- [9] O. Faye, et al., Lymphœdème compliquant une hidradénite suppurée : trois observations, *Ann. Dermatol. Vénéréologie*, 134 (6–7) (2007) 567–569, [https://doi.org/10.1016/S0151-9638\(07\)89271-4](https://doi.org/10.1016/S0151-9638(07)89271-4).
- [10] B.B. Anderson, C.A. Cadogan, et D. Gangadharam, Hidradenitis suppurativa of the perineum, scrotum, and gluteal area: presentation, complications, and treatment, *J. Natl. Med. Assoc.* 74 (10) (1982) 999–1003.
- [11] S. Chapman, D. Delgadillo III, C. Barber, et A. Khachemoune, Cutaneous squamous cell carcinoma complicating hidradenitis suppurativa: a review of the prevalence, pathogenesis, and treatment of this dreaded complication, *Acta Dermatovenerol. Alpina Pannonica Adriatica* 27 (1) (2018), <https://doi.org/10.15570/actaapa.2018.5>.
- [12] G.B.E. Jemec, M. Heidenheim, et N.H. Nielsen, The prevalence of hidradenitis suppurativa and its potential precursor lesions, *J. Am. Acad. Dermatol.* 35 (2) (1996) 191–194, [https://doi.org/10.1016/S0190-9622\(96\)90321-7](https://doi.org/10.1016/S0190-9622(96)90321-7).
- [13] D. Pérez-Díaz, et al., Squamous cell carcinoma complicating perianal hidradenitis suppurativa, *Int. J. Colorectal Dis.* 10 (4) (1995) 225–228, <https://doi.org/10.1007/BF00346224>.
- [14] C. Lavogiez, E. Delaporte, et S. Darras-Vercambre, Clinicopathological study of 13 cases of squamous cell carcinoma complicating hidradenitis suppurativa, *Dermatology* 220 (2010), <https://doi.org/10.1159/000269836>.
- [15] B.B. Dhaoui, F. Boussema, Z. Aydi, L. Baili, et L. Rokbani, Hidradenitis suppurativa (Verneuil's disease), *J. Saudi Soc. Dermatol. Surg.* 17 (1) (2013) 1–5, <https://doi.org/10.1016/j.jssdds.2012.06.003>.
- [16] L. Montaglini, O. Monneuse, F. Braye, X. Barth, A. Claudy, et E. Tissot, Maladie de Verneuil et cancer, *J. Chir. (Paris)* 142 (6) (2005) 381–382, [https://doi.org/10.1016/S0021-7697\(05\)80960-3](https://doi.org/10.1016/S0021-7697(05)80960-3).