

Reversible pulmonary artery perfusion abnormalities in the postpartum period as a precursor to the development of pulmonary arterial hypertension

Devaki O'Riordan¹, David G. Kiely² and B. Ronan O'Driscoll¹

¹Manchester Academic Health Sciences Centre, Department of Respiratory Medicine, Salford Royal Foundation NHS Trust, Salford, Manchester, UK; ²Sheffield Pulmonary Vascular Disease Unit, Royal Hallamshire Hospital, Sheffield Teaching Hospitals NHS Foundation Trust, Sheffield, South Yorkshire, UK

Abstract

Deterioration, or a new presentation, of pulmonary arterial hypertension (PAH), are recognized complications of pregnancy. In this report, we describe a patient with a family history of PAH who developed peripartum breathlessness and hypoxemia with ventilation-perfusion mismatch but no evidence of thromboembolism or PAH. Significantly reduced perfusion at both lung bases was noted on perfusion scintigraphy and three-dimensional magnetic resonance (3D-MR) perfusion maps in the immediate postpartum period. These abnormalities spontaneously resolved by 16 weeks postpartum, consistent with reversible pulmonary abnormalities of pulmonary perfusion. However, she developed new breathlessness four years later and was found to have developed PAH. This case provides a mechanism which may contribute to the high mortality seen in pregnant patients with PAH in the peripartum period.

Keywords

peripartum, scintigraphy, vasoconstriction, VQ scan in pregnancy

Date received: 19 August 2017; accepted: 14 April 2018

Pulmonary Circulation 2018; 8(3) 1–6

DOI: 10.1177/2045894018775190

This case report describes a patient with no known pulmonary vascular disease, but with a family history of pulmonary arterial hypertension (PAH), who developed hypoxemia during late pregnancy and the puerperium. Abnormalities of pulmonary artery perfusion in the immediate postpartum period were noted on perfusion scintigraphy and three-dimensional magnetic resonance (3D-MR) perfusion maps which have not been previously described and which resolved at follow-up. She developed PAH four years later.

Case report

Due to a family history of PAH, a 27-year-old asymptomatic, non-smoking Singaporean woman with no previous medical history was referred to the cardiology clinic seven weeks into her first pregnancy to screen for pulmonary

hypertension (PH). Her father died of PAH at the age of 46 years and her sister (her only sibling) had been on treatment for PAH for five years. To our knowledge, the family had not had any genetic testing.

At presentation, the patient was asymptomatic at World Health Organization Functional Class (WHO FC) I, with oxygen saturations of 96% on air at rest. She underwent a transthoracic echocardiogram which showed normal right ventricular function and an estimated systolic pulmonary artery pressure (PAP) of 16 mmHg plus right atrial pressure based on the tricuspid gradient.

Corresponding author:

Devaki O'Riordan, Fairfield General Hospital, Rochdale Old Road, Bury, Lancashire BL9 7TD, UK.

Email: devakignan@yahoo.co.uk



Creative Commons Non Commercial CC BY-NC: This article is distributed under the terms of the Creative Commons Attribution-NonCommercial 4.0 License (<http://www.creativecommons.org/licenses/by-nc/4.0/>)

which permits non-commercial use, reproduction and distribution of the work without further permission provided the original work is attributed as specified on the SAGE and Open Access pages (<https://us.sagepub.com/en-us/nam/open-access-at-sage>).

© The Author(s) 2018.

Reprints and permissions:
sagepub.co.uk/journalsPermissions.nav
journals.sagepub.com/home/pul



She was referred again at 34 weeks’ gestation with breathlessness on walking up hills (WHO FC II), with an oxygen saturation of 93% on air at rest. Echocardiogram again showed no evidence of PH with systolic PAP estimated at 21 mmHg, and her dyspnea was felt to be due to her gravid uterus and diaphragmatic splinting. Lung function tests were not performed at this time.

At full term, she delivered a healthy baby girl by normal vaginal delivery with a moderate postpartum hemorrhage (dropping her hemoglobin from 153 g/L to 98 g/L). Of interest, her platelet count also dropped modestly from 166 to $137 \times 10^9/L$ (normal range = 150–400), but her clotting studies were normal (prothrombin time, APTT, and fibrinogen). After delivery, her oxygen saturation fell from 93% pre-delivery to 86–88% breathing air and she reported increasing breathlessness on minimal exertion in WHO FC III. Her chest was clear, her blood pressure and heart sounds were normal, and she had no clinical evidence of right or left heart strain. The electrocardiogram and plain chest radiograph were normal.

She walked 75 m slowly breathing air (over 80 s) and her oxygen saturation dropped from 90% to 78%. There was no positional variability in saturation. Spirometry revealed normal volumes and flow (FEV1/FVC = 2.98 L [85% predicted]/3.69 L [91% predicted]) but transfer factor (DLCO) was reduced at 47% predicted. Other than her hemoglobin and platelet counts as above, all blood tests including HIV test, eosinophils, vasculitis, and autoimmune screens were normal. Echocardiography showed an estimated systolic PAP of 20 mmHg plus right atrial pressure and good right ventricular function.

A ventilation perfusion (VQ) scan performed one day postpartum showed normal ventilation throughout, but grossly reduced perfusion in both mid to lower zones, with normal perfusion at the apices (Fig. 1). Computed tomography pulmonary angiogram (CTPA) on the same day showed no evidence of emboli or abnormal structural vasculature to correspond with the changes seen on VQ scan (Figs. 2 and 3). She was treated with 2 L/min oxygen therapy and prophylactic low molecular weight heparin, and after a

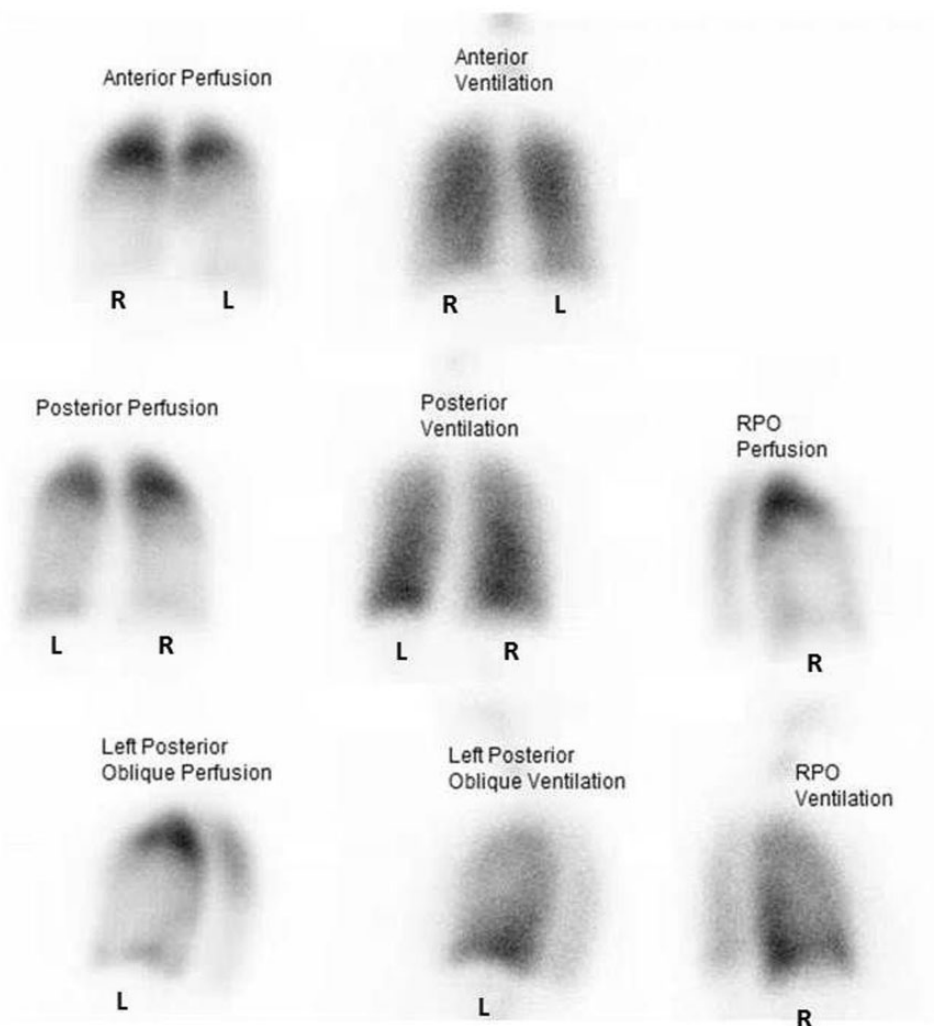


Fig. 1. VQ scan performed on day 1 postpartum showing ventilation-perfusion mismatches in both mid to lower zones during period of hypoxia.

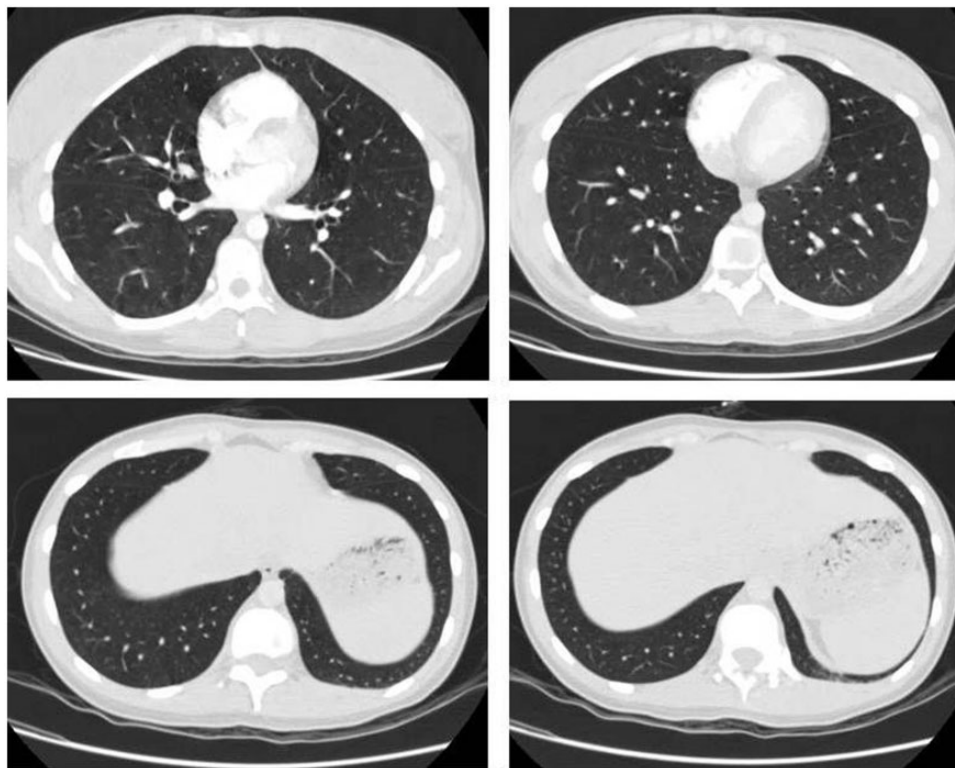

Fig. 2. CTPA on day 1 showing no evidence of pulmonary thromboemboli or structural vascular abnormalities in the areas corresponding to changes on the VQ scan.

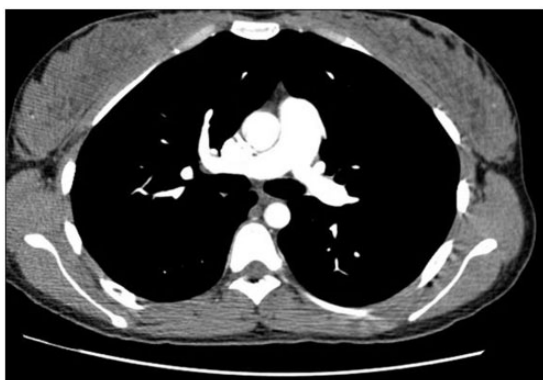

Fig. 3. CTPA on day 1 showing no evidence of proximal pulmonary artery obstruction.

further 48 h was able to maintain her oxygen saturation at 92% on air, although her desaturation on exercise remained the same.

Given concerns regarding an uncharacterized pulmonary vascular disorder she was referred to the regional PH referral center. Here, she underwent right heart catheterization (RHC) 13 days after delivery, (right atrial pressure = 7 mmHg, pulmonary capillary wedge pressure [PCWP] = 9 mmHg, cardiac output = 5.17 L/min, mean PAP [mPAP] = 24 mmHg [systolic PAP = 34 mmHg/diastolic PAP = 13 mmHg], cardiac index = 3.68 L/min/m²,

and pulmonary vascular resistance [PVR] = 232 dynes/s/cm²). Following exercise on the catheter table, the heart rate increased from 85 bpm to 120 bpm, with increases in mPAP to 29 mmHg, in PCWP to 12 mmHg, and in cardiac output to 8.2 L/min, with a fall in PVR of 166 dynes/s/cm². 3D-MR perfusion maps 14 days postpartum showed a similar picture to the perfusion scan, with less filling of the vessels inferiorly compared to apically (Fig. 4). MR also demonstrated normal right and left ventricular function. CTPA demonstrated no evidence of thromboembolic disease and no evidence of a right to left shunt. Overnight oximetry on air showed a mean oxygen saturation of 87% with frequent small desaturations, but no significant apneas.

The patient was reviewed as an outpatient six weeks postpartum, at which time she had become asymptomatic with unlimited exercise tolerance. She climbed 90 18-cm steps in 3 min without breathlessness and retained oxygen saturations of 96% breathing air throughout. Fourteen weeks after childbirth, she was reassessed at the regional referral center. RHC demonstrated no change in mPAP at 23 mmHg. A repeat isotope perfusion scan was now within normal limits apart from very minimal patchy perfusion defects at the lung bases (Fig. 5). 3D-MR perfusion mapping was also normal, with no evidence of significant desaturation on maximal exercise testing (Fig. 6). Six months after delivery, her transthoracic echocardiogram showed an estimated systolic PAP of 23 mmHg and she was asymptomatic in WHO FC I.

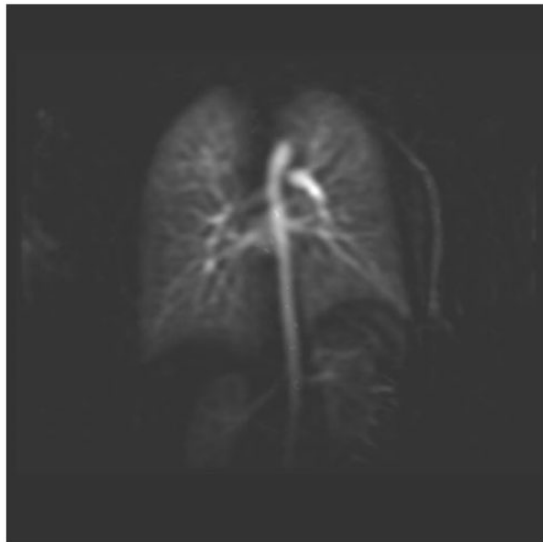
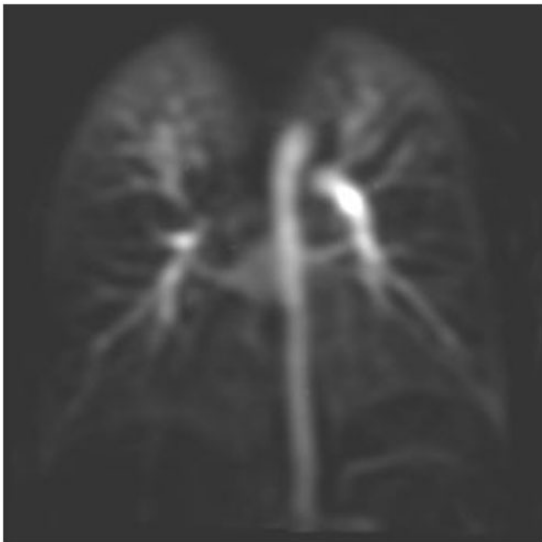


Fig. 4. MR perfusion map 14 days postpartum showing reduced filling of vessels inferiorly compared to apically.

Fig. 6. MR image showing normal perfusion 14 weeks postpartum.

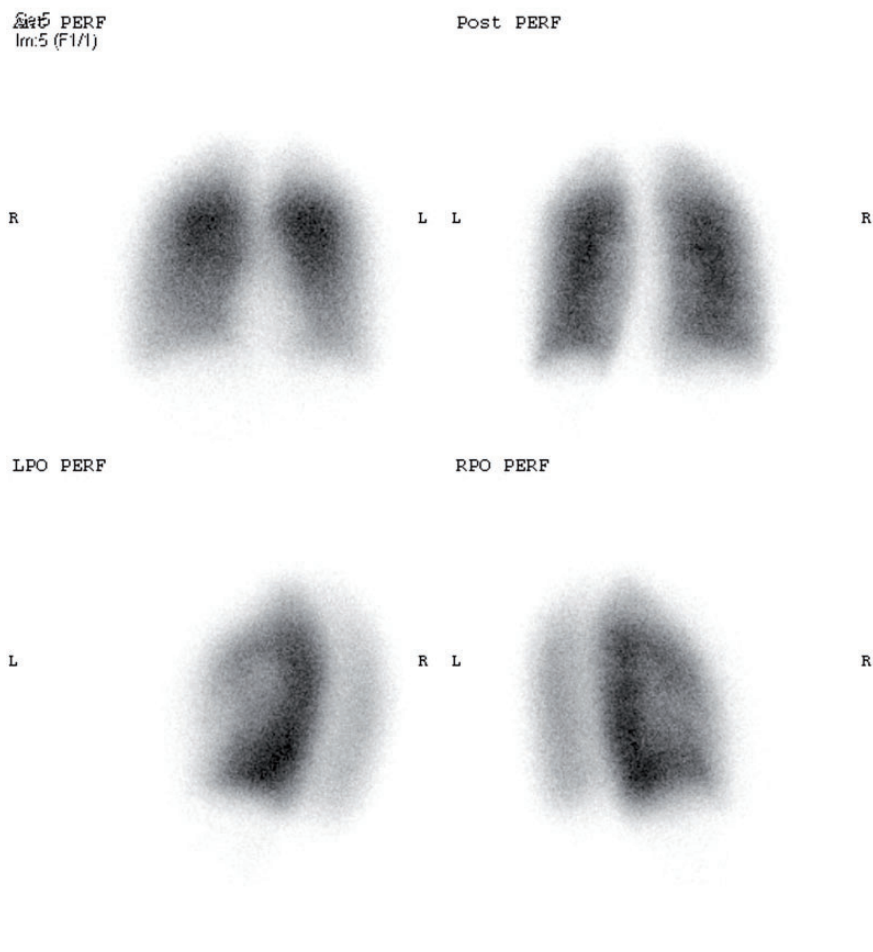


Fig. 5. Repeat VQ scan performed eight weeks after childbirth when patient was asymptomatic, showing complete resolution of previous mismatched changes.

She remained well for almost four years but then presented with exertional breathlessness in WHO FC II. Her spirometry was normal but transfer factor (DLCO) was 61% predicted. An echocardiogram showed new dilation of the right ventricle with estimated systolic PAP of 75 mmHg. RHC confirmed the presence of significant PAH with PAP of 90/35 (mean = 56 mmHg), a mean PAWP of 12 mmHg, reduced cardiac output at 1.97 L/min/m², and an elevated PVR of 1200 dynes/s/cm². Cardiac MR scan demonstrated right ventricular impairment with a right ventricular ejection fraction of 44%. A repeat perfusion scan of the lungs remained normal (identical to Fig. 2) and did not show recurrence of the previous abnormalities shown in Fig. 1.

Discussion

This case illustrates an unusual pulmonary vascular response during the postpartum period, which has not been previously described. It demonstrates reversible changes in pulmonary perfusion occurring in a woman with a family history of PAH but in the absence of PH. It suggests an abnormal pulmonary vascular response which may be one of a number of mechanisms responsible for the high mortality seen in women with PAH in the immediate postpartum period. In addition, this case describes the development of PAH several years following the initial presentation in pregnancy with complete resolution of symptoms in interim period.

PH has many causes which include idiopathic PAH, a rare condition with a relentlessly progressive course and if untreated has a median survival of <3 years.¹ Studies have suggested that 11–40% of patients with idiopathic disease and 70% of patients with a family history of PAH have a mutation in the *BMPR2* gene.² Similar rates of this gene mutation are seen in PAH cohort studies in East Asian populations.³ Importantly, so far there is no intervention that will prevent the development of PAH in patients who carry the genetic mutation.

Echocardiography studies of asymptomatic relatives of patients with PAH have shown that although pulmonary vascular pressures may be normal at rest, they can behave abnormally in response to exercise or hypoxia.⁴ However, current guidelines do not recommend the use of stress echocardiography as a means of identifying early PAH due to the lack of validated criteria and prospective data.⁵

The occurrence of PAH during pregnancy has been postulated to represent an unmasking of pre-existing disease due to the increased cardiovascular demands of pregnancy, or one of “multiple hits” that are thought to be required for the development of PAH in patients who are predisposed to develop the condition chronically, such as those with a family history of PAH.

Pregnancy in PAH is associated with a high rate of maternal death. Compared to previous decades, there has been an overall improvement in mortality in PAH at 25%

versus 38% for all patients.⁶ More recent studies have suggested improved outcomes when patients receive care in specialist centers with an overall mortality in the region of 10%.^{7,8} Mortality is particularly high in the immediate postpartum period with the majority of deaths occurring in the first seven days postpartum.⁶ Pregnancy is a “vasodilatory” state with major changes occurring in the postpartum period resulting in reversal of this state. During pregnancy, fluctuating levels of estradiol and progesterone affect both physiology and pathology in the lung.⁹ Hormonal mechanisms may also be responsible for the well-recognized phenomenon of worsening PH in pregnancy in women with established PAH.¹⁰ The fact that this patient’s condition worsened temporarily in the postpartum period with regards to oxygenation and pulmonary perfusion to the lung bases raises the possibility that reversible pulmonary vasoconstriction may play a part in postpartum pathophysiology.

Amniotic fluid embolism should be considered as a differential diagnosis here. However, this patient had breathlessness and mild hypoxemia from the 34th week of pregnancy and she had no traumatic risk factors during labor and she had an uneventful delivery. With no evidence of cardiogenic shock or disseminated intravascular coagulopathy (instead a finding of isolated thrombocytopenia alone), a clinical diagnosis of amniotic fluid embolism was ruled out.¹¹ Indeed, mother and baby had no neurological sequelae consistent with this diagnosis.

It is interesting to note that this patient’s platelet count dropped peripartum. The authors postulate that the development of pulmonary microthrombi composed of platelets and fibrin may have been responsible for the transient reduction in perfusion in the postpartum period, as seen in PH in newborns.¹² In patients with severe PAH, where there is less vascular reserve, such an insult could potentially explain why patients can decompensate rapidly in the immediate postpartum period with an acute worsening of PH and with severe hypoxemia that may not respond to vasodilator therapy.

Generally, the physiological changes occurring in pregnancy return to normal within 3–6 months of delivery, and indeed this patient became asymptomatic with a normal oxygen saturation and normal pulmonary perfusion and hemodynamics within this time. However, we note that her mPAP remained at the high end of the normal range (with a mPAP in the range of 20–24 mmHg, albeit with a fall in PVR on exercise) and with a persistently reduced transfer factor (DLCO). The two CTPA scans were of sufficiently high quality to rule out chronic thromboembolic PH.^{13,14}

The nature of this patient’s pulmonary vascular changes was still indeterminate and prognosis unclear. Consequently, she was counseled against pursuing another pregnancy, and also in avoidance of estrogen-containing contraception as intimal proliferation has been reported in association with female reproductive steroids.¹⁵ The genetic status of the patient and her family are not known and ideally should be studied.

There are often debates regarding the investigation of choice for suspected pulmonary embolism occurring during pregnancy, which is an important differential in a breathless hypoxemic patient in pregnancy or the postpartum period. In this patient, there was no evidence of pulmonary thromboembolism, and if a VQ scan had not been performed, the finding of reduced perfusion in the lower lobes and VQ mismatch as a cause of the hypoxemia would have been missed. It is notable that multiple studies in breathless pregnant patients have shown > 80% to have normal VQ scans in pregnancy, the remainder being diagnostic of pulmonary emboli.^{16,17} Subsequent investigation with MR imaging with 3D-MR perfusion maps and MR angiography confirmed reduced perfusion in the lower lobes in the absence of structural obstruction and no evidence of a right to left shunt. Vasculitis can also lead to reversible perfusion defects with a normal CT scan,¹⁸ but her clinical presentation did not fit this diagnosis and her autoimmune screen was normal. To our knowledge, such reversible pulmonary perfusion abnormalities have not been described previously in the postpartum period.

In conclusion, we identify a mechanism (transiently abnormal perfusion of unknown pathophysiology) that may in part explain the high mortality seen in the postpartum period in patients with PAH. In addition, the fact that this patient has gone on to develop established PAH four years later, emphasizes the significance of an increase in PAP over time, even if it remains within the normal range. This should prompt consideration of continued follow-up in patients with a family history of PAH who have borderline elevated PAP.

Acknowledgments

The authors thank JM Wild and AJ Swift (University of Sheffield) for the MR images.

Conflict of interest

The author(s) declare that there is no conflict of interest.

Funding

This research received no specific grant from any funding agency in the public, commercial, or not-for-profit sectors.

References

- Kiely DG, Elliot CA, Sabroe I, et al. Pulmonary hypertension: diagnosis and management. *BMJ* 2013; 346: f2028.
- Newman JH, Wheeler L, Lane KB, et al. Mutation in the gene for bone morphogenetic protein receptor II as a cause of primary pulmonary hypertension in a large kindred. *N Engl J Med* 2001; 345: 319–324.
- Liu D, Eyries M, Wu W-H, et al. Molecular genetics and clinical features of Chinese idiopathic and heritable pulmonary arterial hypertension patients. *ERJ* 2012; 39: 597–603.
- Grünig E, Weissmann S, Ehlken N, et al. Stress Doppler echocardiography in relatives of patients with idiopathic and familial pulmonary arterial hypertension: results of a multicenter European analysis of pulmonary artery pressure response to exercise and hypoxia. *Circulation* 2009; 119(13): 1747–1757.
- Galiè N, Humbert M, Vachiery JL, et al. 2015 ESC/ERS Guidelines for the diagnosis and treatment of pulmonary hypertension. The joint task force for ESC and ERS. *Eur Heart J* 2016; 37(1): 67–119.
- Bedard E, Dimopoulos K and Gatzoulis MA. Has there been any progress made on pregnancy outcomes among women with pulmonary arterial hypertension? *Eur Heart J* 2009; 30: 256–265.
- Kiely DG, Condliffe R, Webster V, et al. Improved survival in pregnancy and pulmonary hypertension using a multiprofessional approach. *BJOG* 2010; 117: 565–574.
- Jaïs X, Olsson KM, Barbera JA, et al. Pregnancy outcomes in pulmonary arterial hypertension in the modern management era. *Eur Respir J* 2012; 40(4): 881–885.
- Gonzalez-Arena A and Agramonte-Hevia J. Sex steroid hormone effects in normal and pathologic conditions in lung physiology. *Mini Rev Med Chem* 2012; 12(11): 1055–1062.
- Hemnes AR, Kiely DG, Cockrill BA, et al. Statement on pregnancy in pulmonary hypertension from the Pulmonary Vascular Research Institute. *Pulm Circ* 2015; 5(3): 435–465.
- Kobayashi H, Akasaka J, Naruse K, et al. Comparison of the different definition criteria for the diagnosis of amniotic fluid embolism. *J Clin Diagn Res* 2017; 11(7): QC18–QC21.
- Levin DL, Weinberg AG and Perkin RM. Pulmonary microthrombi syndrome in newborn infants with unresponsive persistent pulmonary hypertension. *J Pediatr* 1983; 102(2): 299–303.
- Castaner E, Gallardo X, Ballesteros E, et al. CT diagnosis of chronic pulmonary thromboembolism. *Radiographics* 2009; 29(1): 31–50.
- Bergin CJ, Sirlin CB, Hauschildt JP, et al. Chronic thromboembolism: Diagnosis with helical CT and MRI imaging with angiographic and surgical correlation. *Radiology* 1997; 204(3): 695–702.
- Godsland IF, Winkler U, Lidegaard O, et al. Occlusive vascular diseases in oral contraceptive users. Epidemiology, pathology and mechanisms. *Drugs* 2000; 60: 721–869.
- Curtis BR, Cox M, Poplawski M, et al. Low yield of ventilation and perfusion imaging for the evaluation of pulmonary emboli after indeterminate CT pulmonary angiography. *Emerg Radiol* 2017; 24(5): 525–530.
- Gruning T, Mingo RE and Gosling MG. Diagnosing venous thromboembolism in pregnancy. *Br J Radiol* 2016; 89: 1062.
- Bateman NT and Croft DN. False positive lung scans and radiotherapy. *BMJ* 1976; 1: 807–808.