



A Case of Vesicular Mycosis Fungoides

Rosa Kim, Bo Ram Kwon, Ji Yeon Byun, You Won Choi, Hae Young Choi, Sanghui Park¹, Min Young Lee

Departments of Dermatology and ¹Pathology, Ewha Womans University College of Medicine, Seoul, Korea

Received May 7, 2020
Revised September 3, 2020
Accepted September 22, 2020

Corresponding Author

Min Young Lee
Department of Dermatology, Ewha
Womans University College of Medicine,
260 Gonghang-daero, Gangseo-gu, Seoul
07804, Korea
Tel: +82-2-2650-5159
Fax: +82-2-2652-6925
E-mail: pure412@hanmail.net
<https://orcid.org/0000-0001-8436-1505>

A 44-year-old male presented with 7 months history of nonpruritic round oozing plaques on the extremities and red papules on the trunk. The lesions were resistant to topical and oral steroid prescribed at the other local clinics. Histopathological examination showed parakeratosis with acanthosis and rete ridge elongation as well as spongiotic intraepidermal blisters and dense dermal infiltration of small to medium sized atypical lymphoid cells. Immunohistochemical analysis revealed the lymphocyte infiltrate to be predominantly CD4⁺ T cells, with CD4/CD8 ratio to be greater than 10:1. Infiltration of large cells that were CD30⁺ were also noted. This histopathologic findings are consistent with vesicular mycosis fungoides (MF). He was prescribed with narrow-band ultraviolet B twice per week and topical steroid, combined with interferon- α injection for 5 weeks, and his skin lesions significantly faded and were flattened. Vesicular MF is associated with poor prognosis, but our patient was able to show benign course of disease thanks to timely diagnosis. One must consider vesicular MF as a differential for recalcitrant eczematous lesions.

Keywords: Mycosis fungoides, Vesicular mycosis fungoides

INTRODUCTION

Mycosis fungoides (MF) is a type of cutaneous lymphoma caused by post-thymic T cell migration under the influence of chronic antigen stimulation¹. The histopathology of MF is characterized by passive infiltration of hyperchromatic cerebriform lymphocytes into the epidermis². Of the various clinical and histological subtypes of MF, types that accompany an epidermal response, including lichenoid or vesicular MF, can pose a challenge to dermatologists when making a diagnosis. The purpose of this article is to discuss a rare case of vesicular MF.

CASE REPORT

A 44-year-old male presented with a 7-month history of non-pruritic, variably sized, round oozing plaques on the extremities along with asymptomatic red-to-brownish papules and patches on the trunk (Fig. 1). Local clinics had previously prescribed topical and oral steroids to treat discrete coin-shaped erythematous vesicular patches that they had diagnosed as contact dermatitis or nummular eczema. The lesions were re-

calcitrant to the therapy, and they did not show any spontaneous regression. Therefore, he was referred to our clinic. He had no history of fever, weight loss, malaise, or lymphadenopathy.

For further evaluation, a skin biopsy of an oozing plaque lesion on the calf was performed. Histopathological examination showed parakeratosis with acanthosis and rete ridge elongation as well as spongiotic intraepidermal blisters and dense dermal infiltration of small to medium sized atypical lymphoid cells (Fig. 2). Immunohistochemical analysis revealed that the lymphocyte infiltrate comprised predominantly CD4⁺ T cells, with a CD4:CD8 ratio greater than 10:1 (Fig. 3A, B). Large cells that are at least four times larger than regular lymphocytes with round-to-oval nuclei were observed in the epidermis and dermis. Some of the large cells expressed CD30⁺ antigen while anaplastic lymphoma kinase (ALK) staining was negative (Fig. 3C). Because intraepidermal blisters and spongiosis were seen along with band-like dermal infiltrate of small to medium sized atypical lymphocytes that were predominantly CD4⁺, the patient was diagnosed with vesicular MF.

No definitive abnormal finding was seen on blood cell morphology or bone marrow chromosome tests, indicating an ab-



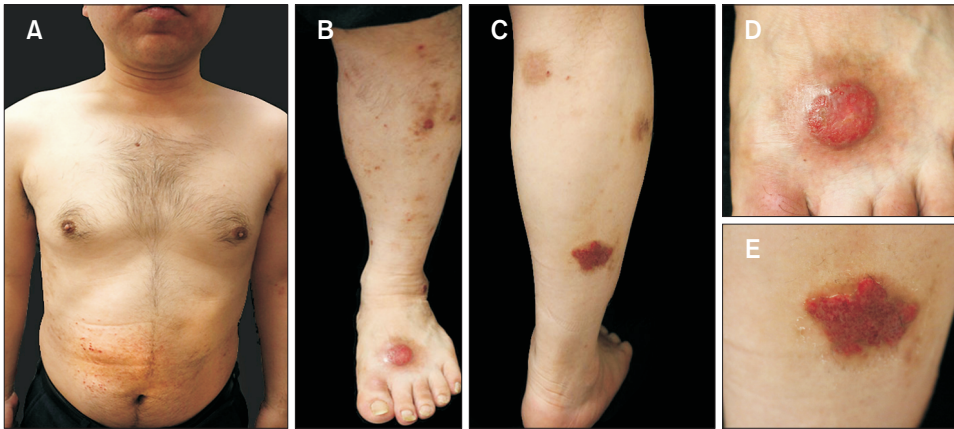

Fig. 1. Oozing red to brownish papules and plaques on trunk (A), legs (B, C), dorsum of foot (D), and biopsy site on the leg (E).

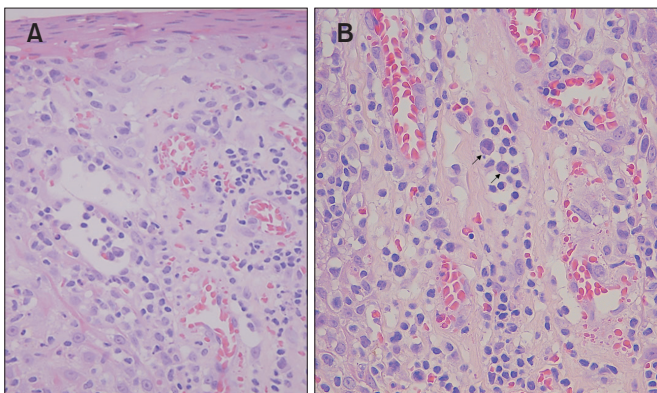


Fig. 2. Spongiotic intraepidermal blisters and (A) epidermal and (B) dermal infiltration of small to medium sized atypical lymphoid cells with large cells (arrows) (H&E, $\times 400$).

sense of significant peripheral blood involvement. Chest computed tomography (CT), neck CT, abdominal CT, and whole-body positron emission tomography–CT demonstrated no lymph node involvement or solid organ involvement. Such staging studies revealed the patient to be T3, N0, M0, B0 (stage IIB)³. He was prescribed narrow-band ultraviolet B phototherapy twice per week and adjuvant topical steroids as skin-directed therapy, combined with interferon- α subcutaneous injections as a systemic biologic modifier. After 5 weeks, the skin lesions had significantly receded and flattened (Fig. 4). The patient did not develop any new lesions for another 5 months. We received the patient's consent form about publishing all photographic materials.

DISCUSSION

MF is the most common form of primary cutaneous lymphoma; it constitutes 60% of cutaneous T-cell lymphomas and almost 50% of primary cutaneous lymphomas^{4,5}. MF

can present with many diverse cutaneous manifestations, but MF typically shows poorly defined areas of erythema arising spontaneously on non-sun-exposed areas such as the buttocks, medial thighs, and breasts⁶.

Of the numerous variants, vesicular MF manifests histopathologic features that are also seen in reactive eczematous dermatitis; therefore, misdiagnosis or a delayed diagnosis is possible. However, it is important to recognize this variant because it is associated with the prognosis of the disease⁷. In addition to histopathologic features that are commonly seen in classic MF, including epidermal infiltration by small to medium sized lymphocytes predominantly CD4⁺ with cerebriform hyperchromatic nuclei, blisters and spongiosis may develop in vesicular MF. Reactive dermatoses are associated with similar features, exocytosis with Langerhans cell microgranulomas. However, reactive dermatoses are characterized by the infiltration of CD4⁺ and CD8⁺ lymphocytes along with macrophages, eosinophils, mast cells and plasma cells⁸. Therefore, presence of atypical epitheliotropic predominantly CD4⁺ lymphocytes demonstrates vesicular MF.

Many hypotheses regarding the mechanism of vesiculation have been proposed. The confluence of Pautrier's microabscesses in MF may lead to bullae formation. Proliferation and accumulation of neoplastic lymphocytes in the epidermis may result in a loss of coherence between basal keratinocytes and the basal lamina, forming vesicles. Momtahan et al.¹ reported four cases of vesicular MF and proposed that vesiculation indicates a Th2-dominant cytokine microenvironment. Conversion of a Th1-dominant microenvironment to Th2 is thought to be associated with a more aggressive clinical course because interleukin (IL)-10 in a Th2-dominant environment suppresses natural killer and dendritic cells. The production of Th2-

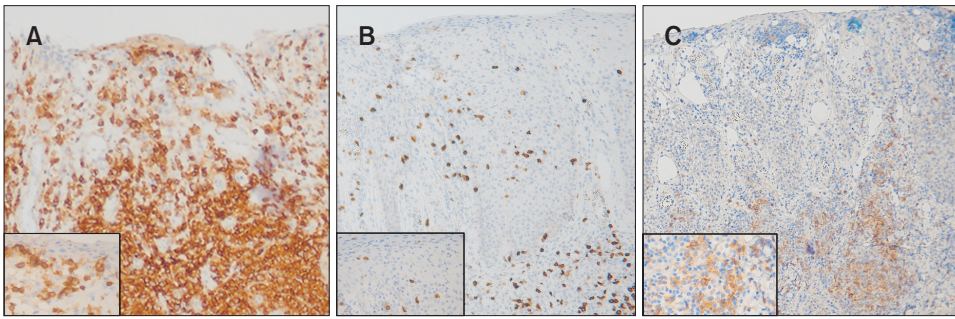


Fig. 3. Immunohistochemical phenotypic studies showing atypical lymphocytes. The lymphocytes exhibit a very high CD4 to CD8 ratio in excess of 10:1 (A) CD4 ($\times 100$, inset $\times 400$), (B) CD8 ($\times 100$, inset $\times 400$), (C) CD30 ($\times 100$, inset $\times 400$).

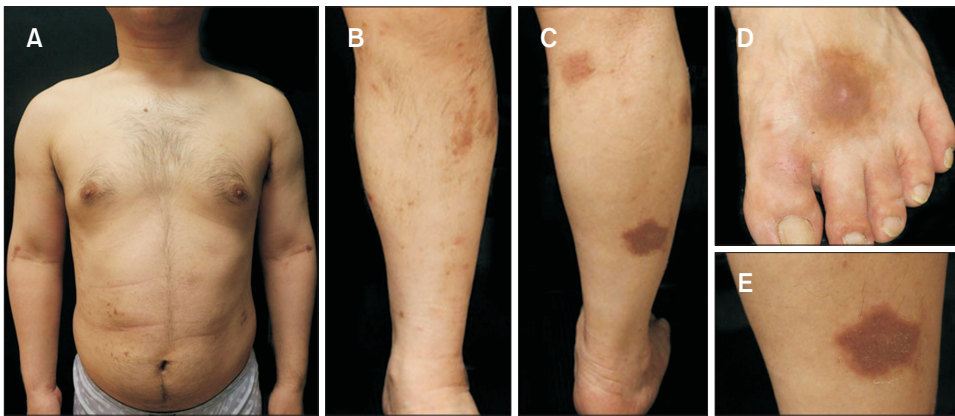


Fig. 4. Post-narrow-band ultraviolet B phototherapy and interferon- α treatment for five weeks. Skin lesions had significantly receded and flattened on trunk (A), legs (B, C), dorsum of foot (D), and biopsy site on the leg (E).

specific cytokines such as IL-4, IL-5, and IL-10 outweighs Th1 cytokine production, leading to increases in immunoglobulin (Ig) E, IgA, and serum eosinophils. This cytokine milieu mimics a relative state of immunosuppression, leading to a poor prognosis.

Vesicular MF can also mimic autoimmune blistering diseases. Several cases of concomitant MF and pemphigus foliaceus or bullous pemphigoid have been reported². In our case, immunofluorescence evaluation was not performed because clear vesicles and bullae were not present at the initial physical examination. However, it would have been more helpful to rule out simultaneous autoimmune bullous diseases.

Our case showed epidermal and dermal infiltration of large cells (\geq four times the size of a small lymphocyte)⁹, and some of them were CD30⁺. The CD30 antigen is a marker of “activation,” shared by primary cutaneous anaplastic large lymphoma (C-ALCL) and lymphomatoid papulosis (LyP), which comprise the second most common group of cutaneous T-cell lymphomas. A distinction between MF and C-ALCL or LyP is essential in making diagnosis. In C-ALCL, $\geq 75\%$ of the tumor cells express the CD30 antigen³ while CD30⁺ large cells in our case comprised less than 25%. Our case patient was negative

for ALK expression, which is often seen in C-ALCL but never in MF¹⁰. In addition, LyP is clinically characterized by the appearance of widely dispersed crops of papules, nodules and large plaques that spontaneously regress after several weeks or months¹¹. Of the five subtypes of LyP, types A, C, D, and E exhibit tumor cells predominantly composed of CD30⁺ atypical lymphocytes¹¹. LyP type D shows marked epidermotropism of CD8⁺ atypical lymphocyte that morphologically similar to localized pagetoid reticulosis¹², thus causing a diagnostic dilemma. However, the skin lesions of the case patient had never undergone spontaneous involution or recurrence. Immunohistochemistry showed marked expression of CD4 in atypical lymphoid cell with striking reduction in CD8, such is consistent finding with MF.

Vesicular MF is associated with a poor prognosis. Although our case presented with skin lesions that are not typically seen in classic MF, he was diagnosed at an early stage and then followed a benign course. The diagnosis of vesicular MF is demanding, but dermatologists must consider vesicular MF as a differential diagnosis if eczematous skin lesions resistant to therapy are present. If spongiosis and intraepidermal blisters are seen along with colonization by cerebriform lymphocytes

on histopathological evaluation, vesicular MF must be considered to prevent a delayed diagnosis or misdiagnosis.

CONFLICTS OF INTEREST

The authors have nothing to disclose.

FUNDING SOURCE

None.

ORCID

Rosa Kim, <https://orcid.org/0000-0002-0873-7643>
Bo Ram Kwon, <https://orcid.org/0000-0002-8887-9667>
Ji Yeon Byun, <https://orcid.org/0000-0003-4519-9474>
You Won Choi, <https://orcid.org/0000-0001-6315-3889>
Hae Young Choi, <https://orcid.org/0000-0003-3460-2539>
Sanghui Park, <https://orcid.org/0000-0003-3837-8677>
Min Young Lee, <https://orcid.org/0000-0001-8436-1505>

REFERENCES

1. Momtahn S, Nuovo GJ, Magro CM. Vesicular mycosis fungoides. *Am J Dermatopathol* 2015;37:724-729.
2. Hoppe RT, Wood GS, Abel EA. Mycosis fungoides and the Sézary syndrome: pathology, staging, and treatment. *Curr Probl Cancer* 1990;14:293-371.
3. Olsen E, Vonderheid E, Pimpinelli N, Willemze R, Kim Y, Knobler R, et al. Revisions to the staging and classification of mycosis fungoides and Sezary syndrome: a proposal of the International Society for Cutaneous Lymphomas (ISCL) and the cutaneous lymphoma task force of the European Organization of Research and Treatment of Cancer (EORTC). *Blood* 2007;110:1713-1722.
4. Willemze R, Jaffe ES, Burg G, Cerroni L, Berti E, Swerdlow SH, et al. WHO-EORTC classification for cutaneous lymphomas. *Blood* 2005;105:3768-3785.
5. Willemze R, Cerroni L, Kempf W, Berti E, Facchetti F, Swerdlow SH, et al. The 2018 update of the WHO-EORTC classification for primary cutaneous lymphomas. *Blood* 2019;133:1703-1714. Erratum in: *Blood* 2019;134:1112.
6. Girardi M, Heald PW, Wilson LD. The pathogenesis of mycosis fungoides. *N Engl J Med* 2004;350:1978-1988.
7. Bowman PH, Hogan DJ, Sanusi ID. Mycosis fungoides bullosa: report of a case and review of the literature. *J Am Acad Dermatol* 2001;45:934-939.
8. Elder DE. *Lever's histopathology of the skin*. 11th ed. Philadelphia: Lippincott William & Wilkins, 2015. p. 1135-1145.
9. Porntharukcharoen S, Rutnin S, Rajatanavin N. Large-cell transformed mycosis fungoides coexisting with mycosis fungoides bullosa: a case report and review of the literature. *Case Rep Dermatol* 2017;9:243-248.
10. Vergier B, de Muret A, Beylot-Barry M, Vaillant L, Ekouevi D, Chene G, et al. Transformation of mycosis fungoides: clinicopathological and prognostic features of 45 cases. French Study Group of Cutaneous Lymphomas. *Blood* 2000;95:2212-2218.
11. Patterson JW. *Weedon's skin pathology*. 4th ed. Edinburgh: Elsevier, 2016:1186-1188.
12. Kempf W, Kerl K, Mitteldorf C. Cutaneous CD30-positive T-cell lymphoproliferative disorders-clinical and histopathologic features, differential diagnosis, and treatment. *Semin Cutan Med Surg* 2018;37:24-29.