



CLINICAL PRACTICE ARTICLE

**REVISED** Metachronous or synchronous male breast and prostate cancers a duality to lookout for. [version 2; peer review: 2 approved, 1 approved with reservations]

Alain Mwamba Mukendi <sup>1</sup>, Eunice Van Den Berg<sup>2</sup>, Sugeshnee Pather<sup>2</sup>, Rushen Siva Padayachee<sup>2</sup>

<sup>1</sup>Department of Urology, Chris Hani Baragwanath Academic Hospital / University of the Witwatersrand, Johannesburg, South Africa  
<sup>2</sup>Division of Anatomical Pathology, National Health Laboratory Service/Chris Hani Baragwanath Academic Hospital, Faculty of Health Sciences, University of the Witwatersrand., Johannesburg, South Africa

**v2** First published: 20 Nov 2018, 7:1825  
<https://doi.org/10.12688/f1000research.16997.1>  
 Latest published: 26 Feb 2019, 7:1825  
<https://doi.org/10.12688/f1000research.16997.2>

**Abstract**

**Introduction:** Breast cancer is well known as the stereotypical women’s cancer, and prostate cancer represents the well-known stereotypical male counterpart. While prostate cancer carries the potential to metastasize to the breast, the synchronous or metachronous co-occurrence of primary breast and primary prostate cancers is quite unusual. Prostate cancer in men of African descent may have its own behaviour with regards to its relationship with male breast cancer.

**Case presentation:**



Case 1: A 64 year old male presented to Chris Hani Baragwanath Hospital (CHBAH) with a 2 years history of a painless left breast lump. A core biopsy was done and confirmed breast carcinoma. Tamoxifen was started but, due to disease progression, he underwent left modified radical mastectomy followed by chemotherapy. Prostate biopsy was done for raised Prostate Specific Antigen (PSA) and suspicious prostate on digital rectal examination. A prostatic adenocarcinoma was subsequently diagnosed with bone metastases on bone scan. He was started on Androgen deprivation therapy and followed up every 3 months.

Case 2: A 68 year old male presented to CHBAH with a 1 year history of a painless right breast lump. A core biopsy confirmed breast cancer. Tamoxifen was started, followed by right modified radical mastectomy and chemotherapy for disease progression. A raised PSA and suspicious prostate on digital rectal examination prompted a prostate biopsy revealing a prostatic adenocarcinoma. Bone scan was negative for metastasis. He is currently on 3 monthly Androgen

**Open Peer Review**

Reviewer Status

	Invited Reviewers		
	1	2	3
<b>version 2</b>			
(revision)			
26 Feb 2019	report	report	report
	↑	↑	
<b>version 1</b>			
20 Nov 2018			
	report	report	

- Pankaj Joshi** , Centre for Reconstructive Urology, Pune, Maharashtra, India  
**Sandeep Bafna**, Centre for Reconstructive Urology, Pune, India
- Bannakij Lojanapiwat**, Chiang Mai University, Chiang Mai, Thailand
- Celestin Nzanu Mudogo** , University of Hamburg, Hamburg, Germany

Any reports and responses or comments on the article can be found at the end of the article.

deprivation therapy and awaiting radiation.

**Conclusion:** This clinical practice article not only presents this exceptionally rare duality but highlights that both cancers can coexist either as sporadic conditions, or as a result of genetic mutations. Thus, we suggest that men with prostate cancer be screened clinically, biochemically and genetically for breast cancer and vice versa.

**Keywords**

Male breast cancer; prostate cancer; duality; metachronous; synchronous; men of African descent.

**Corresponding author:** Alain Mwamba Mukendi ([alainmwamba2006@yahoo.fr](mailto:alainmwamba2006@yahoo.fr))

**Author roles:** **Mukendi AM:** Conceptualization, Data Curation, Investigation, Project Administration, Resources, Visualization, Writing – Original Draft Preparation, Writing – Review & Editing; **Van Den Berg E:** Resources, Visualization, Writing – Original Draft Preparation; **Pather S:** Resources, Visualization, Writing – Original Draft Preparation; **Padayachee RS:** Resources, Visualization, Writing – Original Draft Preparation

**Competing interests:** No competing interests were disclosed.

**Grant information:** The author(s) declared that no grants were involved in supporting this work.

**Copyright:** © 2019 Mukendi AM *et al.* This is an open access article distributed under the terms of the [Creative Commons Attribution License](#), which permits unrestricted use, distribution, and reproduction in any medium, provided the original work is properly cited.

**How to cite this article:** Mukendi AM, Van Den Berg E, Pather S and Padayachee RS. **Metachronous or synchronous male breast and prostate cancers a duality to lookout for. [version 2; peer review: 2 approved, 1 approved with reservations]** F1000Research 2019, 7:1825 <https://doi.org/10.12688/f1000research.16997.2>

**First published:** 20 Nov 2018, 7:1825 <https://doi.org/10.12688/f1000research.16997.1>

**REVISED** Amendments from Version 1

With regards to the **Pankaj Joshi's** last response as below:

- "Please specify the changes in Case 1"- this was the only outstanding correction in relation with the histology type of breast cancer. It was added in the new version. Also added combination of ADT and EBRT for the second patient who is a high risk Ca prostate with no bone metastases.

With regards to **Bannakij Lojanapiwat**:

- I added in the text reasons why we could not get genetic testing on those patients. We hope that with our interest in research and publications we may one day have funding for future research and testing costs if required.
- The conclusion has been shortened. However, we humbly feel that the sentence "suggest that men with prostate cancer be screened clinically, biochemically and genetically for breast cancer and vice versa." should stay as it is. Prostate cancer is common, male breast cancer is rare therefore, it is less likely to find breast cancer in prostate cancer patients. However, the chances are higher to detect prostate cancer from a breast cancer patients not only because prostate cancer is most frequent but also because of the possibility of sharing the same genetic etiology.

See referee reports

## Introduction

Prostate cancer is one of the leading causes of male cancer death<sup>1</sup>. It is the most common conditions seen in patients in our outpatient department. It represents about one third of conditions encountered on a daily basis, out of about 200 consultations.

Male breast cancer is very rare, and comprises only about 1% of all breast cancers<sup>1,2</sup>. Prostate cancer and breast cancer synchronous or metachronous duality is quite unusual<sup>3</sup>. Most of the reported cases of this dual pathology were prostate cancer patients on estrogen therapy who later on developed breast cancer<sup>4,5</sup>.

Men with a family history of breast or prostate cancer have elevated prostate cancer risks, including risk of very aggressive disease<sup>6</sup>. Sporadic cases are exceptionally rare<sup>1</sup>.

We present 2 cases of primary prostate and primary breast cancers in patients of African descent, who were diagnosed first with breast cancer without any family history of breast cancer, and then with prostate cancer. This is the first such case series from Africa.

## Case presentation

### Case 1

A 64 year old black male, retired forensic pathology auditor, was referred to urology clinic at CHBAH from medical oncology at the end of June 2018 with a prostate specific antigen (PSA) of 43.82 ng/dL. His hospital attendance had begun in October

2016 when he presented to the breast unit with a 2 years history of a painless progressively enlarging left breast lump with further investigations revealing carcinoma of the left breast. He was diabetic, hypertensive on treatment, and HIV negative. There was no known family history of breast, prostate or any other cancers. There was no history of undescended testes, testicular injury or mumps orchitis. A left modified radical mastectomy was performed in April 2017. He was previously a smoker, smoking 6 cigarettes per day for 40 years (12 pack-year), and quit in May 2017.

On physical examination, performed in June 2018, scars from left mastectomy and axillary lymph nodes dissection were noted. He had a normal right breast with no palpable lumps. Digital rectal examination revealed an approximately 30 g firm prostate with a nodule on the left lobe. The rest of the examination was unremarkable.

## Investigations and results

**Mammography (October 2016).** Mammograms showed the left breast was Breast Imaging Reporting and Data System (BIRADS) category 6 and BIRADS category 1 for the right breast.

**Core biopsy of the left breast (October 2016).** Pathological diagnosis: An invasive carcinoma of no special type.

Immunohistochemistry: Estrogen receptors: Strong positivity in 67–100% of cells.

Progesterone receptors: Strong positivity in 34–66% of cells. HER2neu: Score 1+ Negative. Ki-67: 20%

**Left breast and axillary dissection histopathology assessment (April 2017).** Pathological diagnosis: Infiltrating duct carcinoma. On macroscopic examination the left breast nipple and skin were unremarkable. On section a tumour was noted in the lower outer and inner quadrants. It measured 40mm in maximal diameter. Microscopically, the tumour comprised infiltrating epithelioid cells in a nested growth pattern, with some tubule formation. There was marked nuclear pleomorphism, and eight mitotic figures were noted in ten high power fields. The modified Bloom and Richardson classification was Grade 2. Five lymph nodes were identified, and all of these contained tumour metastases.

Immunohistochemical stains were positive for estrogen receptors, negative for progesterone receptors, and equivocal for HER2. FISH testing was negative for HER2 amplification. Ki67 staining showed a proliferation index of 20% (Figure 1). The PSA immunochemistry staining was negative confirming primary breast carcinoma.

## Bloods tests.

-Prostate specific antigen: 43.82ng/dL (normal range=0–4.5)

-Lactate dehydrogenase: 254 U/L (normal range=48–115)

-Calcium: 2.63 mmol/L (normal range=2.15–2.50)

-Alkaline phosphatase (ALP): 49 U/L (normal range=53–128)

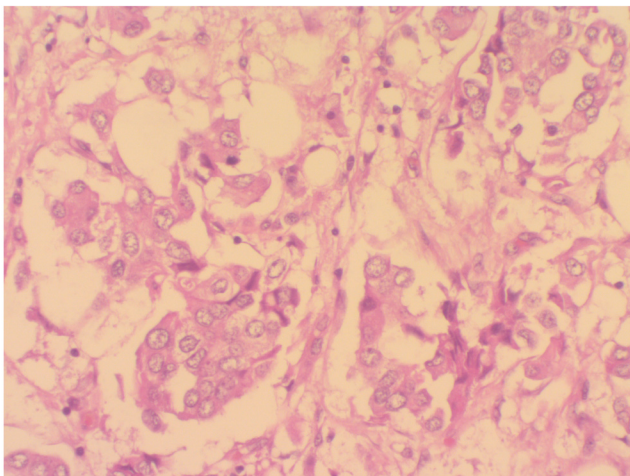
**Prostate biopsy.** Microscopic examination of the prostate core biopsies demonstrated an invasive prostatic adenocarcinoma. The tumour comprised predominately infiltrative, poorly formed, fused glands, and a minor component of more well differentiated glandular areas that splayed muscle fibres. The poorly formed fused glands were compatible with a Gleason pattern of 4 and the well-formed glands were compatible with a Gleason pattern of 3 (Gleason score = 7; WHO grade group 3). The tumour cells had large nuclei, conspicuous nucleoli and abundant pale eosinophilic cytoplasm (Figure 2). The immunohistochemical profile of the tumour (CK 7 and CK20 negative; PSA monoclonal positive) confirmed primary prostatic origin.

**Computerised tomography (CT) scan of the brain, chest and abdomen.** Global cerebral involutinal changes, postsurgical changes in the left chest wall and axilla, and sclerotic lesions at L3 and right iliac bone were found on the CT scans.

**Bone scan.** Active pathology at L3 and right iliac bone were found on Bone scan.

### Management

Initially assessed as T2N0M0 in October 2016, he was put on tamoxifen 20 mg per os daily. 6 months later (April 2017) in view of disease progression to T4bN1Mx, a left mastectomy and left axillary lymph nodes dissection was done. Tamoxifen was replaced by anastrozole 1 mg daily and He was then referred for chemo-radiation. He received 4 cycles of chemotherapy AC-T (Adriamycin, cyclophosphamide and taxol) completed in January 2018. A second primary cancer, a prostatic adenocarcinoma was diagnosed in July 2018, almost 2 years after the initial one, for which he is currently on Goserelin 10.8 mg subcutaneously every 3 months. He has so far received 2 injections (July and October of 2018) and will follow up in 3 months for the next injection, and PSA/testosterone monitoring will be done at 6 months as per the hospital policies (funds restrictions). He is unlikely to be given radiation therapy for curative intent as the disease was found to be metastatic.



**Figure 1. Breast carcinoma showing an adenocarcinoma with marked nuclear pleomorphism.** (H&E stain, X400 magnification).

### Case 2

A 68 year old black male, retired teacher, was referred to urology clinic at CHBAH in May 2018 from medical oncology with a PSA of 113 ng/dL. He first presented in December 2016 to CHBAH breast unit with a 1 year history of a painless right breast lump with further investigations revealing carcinoma of the right breast. He reported that his father died of cancer, but does not know which cancer it was. He had no medical history, was HIV negative, and had no history of undescended testes, mumps orchitis or testicular injury. He was a heavy smoker who smoked 20 cigarettes per day for 40 years (40 pack-year) and quit in July 2016. Right mastectomy and axillary lymph nodes dissection was performed in April 2017.

On physical examination, scars from right mastectomy and axillary lymph nodes dissection were observed. He had a normal left breast with no palpable lumps. Digital rectal examination revealed an approximately 40 g hard nodular prostate. The rest of the examination was unremarkable.

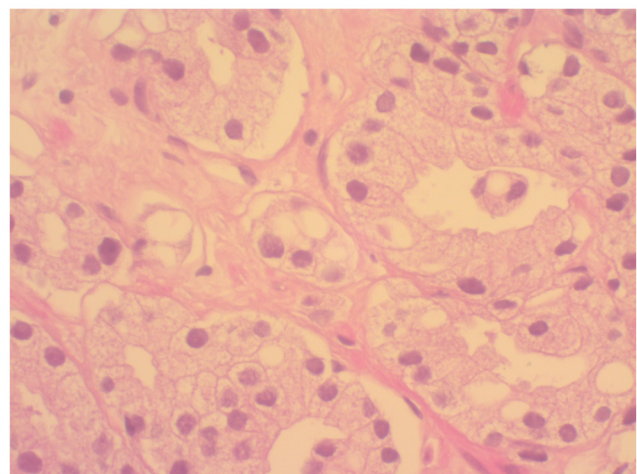
### Investigations and results

**Mammography (December 2016).** Mammograms showed the left breast was BIRADS category 1 and BIRADS category 5 for the right breast.

**Core biopsy of the right breast (December 2016).** Pathological diagnosis: Infiltrating duct carcinoma displaying cribriform features.

Immunohistochemistry: Estrogen receptor positive; strong 3+ intensity staining in >91% of tumour cells. Progesterone Receptor positive; strong 3+ intensity staining in 70% of tumour cells. HER2 negative score 1+ in approximately 10% of tumour cells. Ki-67 the tumour proliferation index approaches 30%.

**The right breast histopathological assessment.** Histopathological examination showed an infiltrating duct carcinoma (Figure 3), with a Nottingham combined histopathological



**Figure 2. Prostatic adenocarcinoma.** (H&E stain, X400 magnification).

grade of 1/3 (tubules 1, pleomorphism 2 and mitoses 1). Estrogen and progesterone receptors were expressed diffusely within the tumour cells (Figure 4). Foci of low-grade cribriform ductal carcinoma *in situ* were also evident (Figure 5). The PSA immunohistochemistry staining was negative confirming primary breast carcinoma.

**Bloods tests.**

- Prostate specific antigen: 113ng/dL (normal range=0–4.5)
- Lactate dehydrogenase: 289 U/L (normal range=48–115)
- Calcium: 2.56 mmol/L (normal range=2.15–2.50)
- ALP: 73 U/L (normal range=53–128)

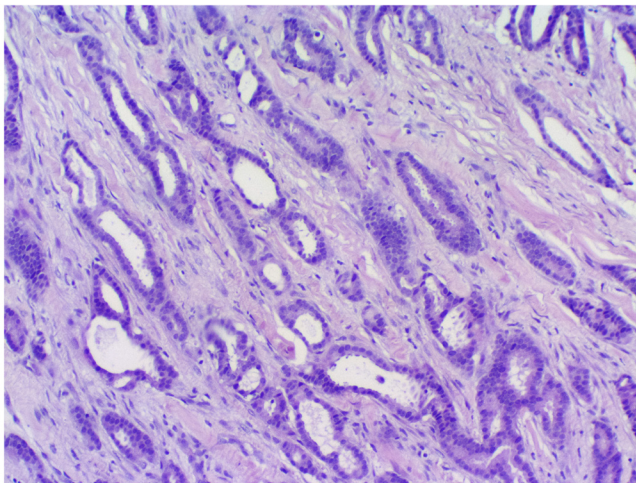
**Prostate biopsy.** Biopsy results showed an invasive prostatic adenocarcinoma (Figure 6), with a modified Gleason score of

9, and grade group 5, which was infiltrating into skeletal muscle (Figure 7). The proportion of tumour infiltration was >90% within the cores. There were areas of lymphatic invasion and perineural invasion.

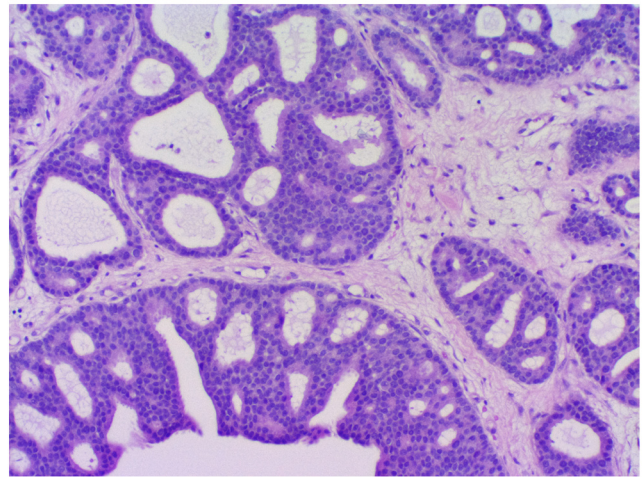
**Bone scan.** No evidence of osteoblastic metastases was found.

**Management**

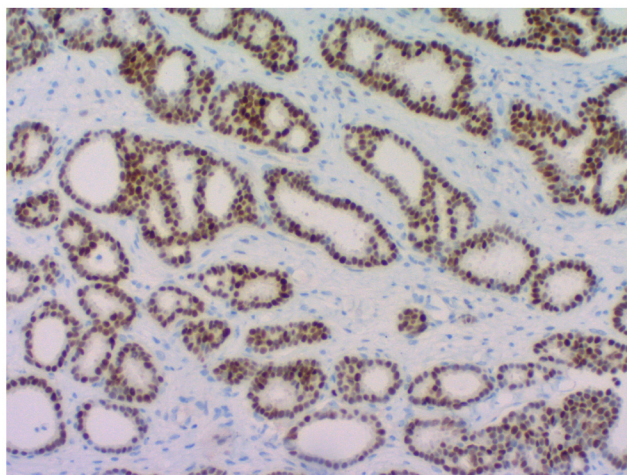
He was assessed from the beginning in December 2016 as T4bN0Mx, he was put on tamoxifen 20 mg per os daily. 4 months later (April 2017), due to disease progression on tamoxifen from T4bN0Mx to T4bN1Mx, a right mastectomy and right axillary lymph nodes dissection was done prior to referring him for chemo-radiation. He received 6 cycles of chemotherapy FAC, (Fluorouracil, Adriamycin and cyclophosphamide) completed in January 2018; he is still on tamoxifen. A second



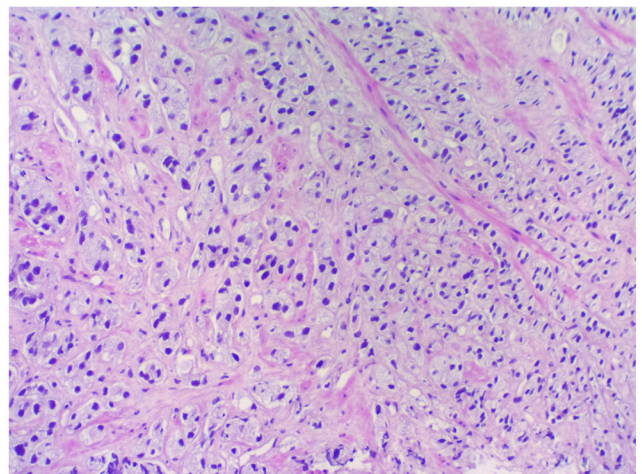
**Figure 3.** Breast infiltrating duct carcinoma (H&E stain, X200 magnification).



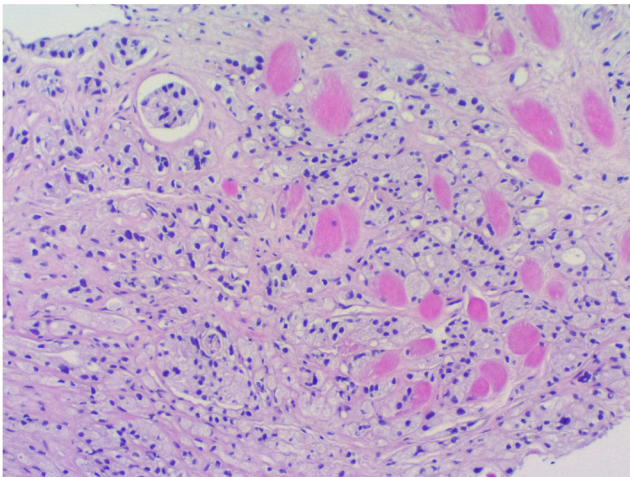
**Figure 5.** Breast cribriform ductal carcinoma *in situ* (DCIS) (H&E stain, X200 magnification).



**Figure 4.** Oestrogen receptors diffusely expressed in the breast carcinoma (estrogen receptor (ER) immunohistochemistry, X200 magnification).



**Figure 6.** Invasive prostatic adenocarcinoma (H&E stain, X200 magnification).



**Figure 7.** Invasive prostatic adenocarcinoma infiltrating into skeletal muscle (H&E stain, X200 magnification).

primary non metastatic cancer arising from the prostate, a prostatic adenocarcinoma, was diagnosed in May 2018, 17 months after the first primary. He is currently on Goserelin 10.8 mg subcutaneously every 3 months and has already received 2 doses. He is awaiting radiation therapy to the right chest. PSA/testosterone monitoring will be performed at 6 months as per the hospital policies (funds restrictions). Radiation oncologist will consider external beam radiotherapy at the time of radiation for right chest.

## Discussion

Prostate cancer is the most common male cancer in the U.S. and second leading cause of cancer death. Male breast cancer is very rare, and comprises only about 1% of all breast cancers<sup>1,2</sup>. Prostate cancer and breast cancer, as synchronous or metachronous dual primary cancer, is quite infrequent<sup>3</sup>. They are both part of the hereditary breast and ovarian cancer (HBOC) syndrome which is associated with gene mutations in *BRCA1* and *BRCA2*<sup>7</sup>. The *BRCA* alteration can be inherited from either of the parents and be responsible for a familial type of breast and prostate cancers which has also been previously reported<sup>6,8</sup>.

*BRCA2* and *BRCA1* mutation carriers have respectively 40% and 20% lifetime risk of prostate cancer, whereas the lifetime risk of male breast cancer is approximately 5% to 10%, and 1% to 5% for *BRCA2* and *BRCA1* mutation carriers, respectively<sup>9</sup>. Mutations in *BRCA2*, in particular, have been associated with more aggressive clinicopathologic characteristics of prostate cancer and worse outcomes<sup>7</sup>. The *BRCA* germline mutations in male cancers are found in only 1% – 2 % of sporadic prostate cancer<sup>10</sup>. However, prostate and male breast cancers have some similarities with regards to etiology and therapeutic approaches<sup>2,9,11</sup>.

Prostate cancer carries the potential to metastasize to the breast<sup>3</sup>. Male primary breast cancer and breast metastases from prostatic carcinoma may have similar histological features<sup>12</sup>. Therefore it

is crucial to exclude breast metastases from prostatic adenocarcinoma through a thorough histopathological assessment. PSA immunohistochemistry may help to distinguish between primary and metastatic disease within the breast specimen. This step is very important because of its therapeutic and prognostic implications<sup>12</sup>. Breast specimens from our 2 cases were evaluated for possible prostatic metastases using PSA immunohistochemistry staining and were both negative.

Androgen deficiency or excess estrogen increases the risk of male breast cancer in men with a history of testicular injury, mumps orchitis, or undescended testes<sup>3</sup>. Klinefelter's syndrome also increases the risk of male breast cancer. Estrogen treatment for prostate cancer was reported as another risk factor for the development of male breast cancer<sup>3,4</sup>. The latter risk factor is associated with most of the reported cases of this dual pathology<sup>4,5</sup>. None of these risk factors were found in our 2 cases.

Metachronous or synchronous occurrences of both breast and prostate cancer are scarce in the current literature. Lee *et al.* evaluated 161 male breast cancer patients for prostate cancer between 1977 and 2000, and found that only 10 patients were also diagnosed with prostate cancer. Breast cancer was the first primary tumour in 8 of these 10 patients<sup>3</sup>. The association of a sporadic male breast cancer with any other primary tumours, including prostate cancer, is exceptionally uncommon<sup>1,9</sup>. As with our 2 patients, just a few cases of this combination without any family history of breast cancer or any genetic mutations have been reported<sup>13–16</sup>. Treatment for each cancer includes hormone manipulation, which may increase the risk for subsequent cancers<sup>17</sup>. There is no available guideline for treatment of this association, hence further research is necessary.

This is in our knowledge the first reported cases from patients of African descent living in Africa. Unfortunately, we could not evaluate our patients in terms of genetics because of the lack of some technical facilities and funds restrictions. Prostate cancer from men of African descent may have its own behaviour with regards to its relationship with male breast cancer as seen in our 2 cases, both are high risk for metastases but one seems to be more aggressive than the other one.

Prostate cancer is in general a slow growing cancer and on that account many years have to pass before developing any symptomatology<sup>8</sup>. We strongly believe that in those 2 patients even though prostate cancer was the second diagnosed primary they both coexisted undiagnosed at some point in time. Therefore it is absolutely difficult to say which one started first. Most likely if prostate cancer screening was done when they were in their 50s, prostate cancer would have been detected first.

## Conclusion

Breast and prostate cancer as synchronous or metachronous primary cancers are very rare and can be either sporadic or as a result of genetic mutations. When either a breast or prostate cancer is diagnosed in a male patient, clinicians should be alert for the other, however, because such a co-occurrence is rarely

diagnosed or reported this rarely happens. More studies and research may be helpful to understand the behaviour of these synchronous or metachronous breast and prostate cancers particularly in an African setting.

A suggestion is therefore made that men with prostate cancer be screened clinically, biochemically and genetically for breast cancer, or vice versa, in view of possible common genetic factors contributing to the pathogenesis of both cancers.

### Take-away lessons

- Synchronous or metachronous Breast and prostate cancer are rarely reported, and sporadic cases are extremely rare.
- BRCA mutation is found to be a common genetic pathway in both cancers.
- Because of the possible link between the 2, clinicians should lookout for this duality regardless of which one is diagnosed, being investigated or worked up first.
- It is crucial to do PSA staining on both specimens (breast and prostate) to exclude metastases.

### Consent

Written informed consents were obtained from both patients for publication of this manuscript and accompanying results.

### Data availability

All data underlying the results are available as part of the article and no additional source data are required.

### Grant information

The author(s) declared that no grants were involved in supporting this work.

### Acknowledgements

Mrs. Joelle Bukumbabu Mukendi (Registered Nurse at Chris Hani Baragwanath Academic Hospital /paediatric oncology department) for helping with referencing and uploading files.

Mrs. Mosase Lehloka-Mashabane (Registered Nurse/ Oncology trained at Chris Hani Baragwanath Academic Hospital/ Urology department) for helping with obtaining consent from the patients and providing feedback from the patients during routine follow ups.

### References

- Ozet A, Yavuz AA, Kömürçü S, *et al.*: **Bilateral male breast cancer and prostate cancer: a case report.** *Jpn J Clin Oncol.* 2000; **30**(4): 188–190.  
[PubMed Abstract](#) | [Publisher Full Text](#)
- Cutuli BF, Lacroze M, Dilhuydy JM, *et al.*: **[Breast cancer in men: incidence and types of associated previous synchronous and metachronous cancers].** *Bull Cancer.* 1992; **79**(7): 689–96.  
[PubMed Abstract](#)
- Lee UJ, Jones JS: **Incidence of prostate cancer in male breast cancer patients: a risk factor for prostate cancer screening.** *Prostate Cancer Prostatic Dis.* 2009; **12**(1): 52–56.  
[PubMed Abstract](#) | [Publisher Full Text](#)
- Karlsson CT, Malmer B, Wiklund F, *et al.*: **Breast cancer as a second primary in patients with prostate cancer—estrogen treatment or association with family history of cancer?** *J Urol.* 2006; **176**(2): 538–543.  
[PubMed Abstract](#) | [Publisher Full Text](#)
- Tajiki M, Tuchiya T, Yasuda M, *et al.*: **A male case of synchronous double cancers of the breast and prostate.** *Intern Med.* 1994; **33**(1): 31–35.  
[PubMed Abstract](#) | [Publisher Full Text](#)
- Barber L, Gerke T, Markt SC, *et al.*: **Family History of Breast or Prostate Cancer and Prostate Cancer Risk.** *Clin Cancer Res.* 2018. **24**(23): 5910–5917  
[PubMed Abstract](#) | [Publisher Full Text](#)
- Giri VN, Hyatt C, Kelly WK, *et al.*: **Current BRCA1/2 Genetic Testing Guidelines for Prostate Cancer and the Implications for Oncologists.** 2017.  
[Reference Source](#)
- Esserman L, Shieh Y, Thompson I: **Rethinking screening for breast cancer and prostate cancer.** *JAMA.* 2009; **302**(15): 1685–1692.  
[PubMed Abstract](#) | [Publisher Full Text](#)
- Lecarpentier J, Silvestri V, Kuchenbaecker KB, *et al.*: **Prediction of breast and prostate cancer risks in male BRCA1 and BRCA2 mutation carriers using polygenic risk scores.** *J Clin Oncol.* 2017; **35**(20): 2240–2250.  
[PubMed Abstract](#) | [Publisher Full Text](#) | [Free Full Text](#)
- Song WH, Kim SH, Joung JY, *et al.*: **Prostate Cancer in a Patient with a Family History of BRCA Mutation: a Case Report and Literature Review.** *J Korean Med Sci.* 2017; **32**(2): 377–381.  
[PubMed Abstract](#) | [Publisher Full Text](#) | [Free Full Text](#)
- Pienta KJ, Goodson JA, Esper PS: **Epidemiology of prostate cancer: molecular and environmental clues.** *Urology.* 1996; **48**(5): 676–83.  
[PubMed Abstract](#) | [Publisher Full Text](#)
- Carder PJ, Speirs V, Ramsdale J, *et al.*: **Expression of prostate specific antigen in male breast cancer.** *J Clin Pathol.* 2005; **58**(1): 69–71.  
[PubMed Abstract](#) | [Publisher Full Text](#) | [Free Full Text](#)
- Carter BS, Bova GS, Beaty TH, *et al.*: **Hereditary prostate cancer: epidemiologic and clinical features.** *J Urol.* 1993; **150**(3): 797–802.  
[PubMed Abstract](#) | [Publisher Full Text](#)
- Akashi-Tanaka S, Fukutomi T, Fukami A, *et al.*: **Male breast cancer in patients with a familial history of breast cancer.** *Surg Today.* 1996; **26**(12): 975–9.  
[PubMed Abstract](#) | [Publisher Full Text](#)
- Tulinus H, Olafsdottir GH, Sigvaldason H, *et al.*: **Neoplastic diseases in families of breast cancer patients.** *J Med Genet.* 1994; **31**(8): 618–21.  
[PubMed Abstract](#) | [Publisher Full Text](#) | [Free Full Text](#)
- Anderson DE, Badzioch MD: **Familial effects of prostate and other cancers on lifetime breast cancer risk.** *Breast Cancer Res Treat.* 1993; **28**(2): 107–13.  
[PubMed Abstract](#) | [Publisher Full Text](#)
- Abhyankar N, Hoskins KF, Abern MR, *et al.*: **Descriptive characteristics of prostate cancer in patients with a history of primary male breast cancer - a SEER analysis.** *BMC Cancer.* 2017; **17**(1): 659.  
[PubMed Abstract](#) | [Publisher Full Text](#) | [Free Full Text](#)

# Open Peer Review

Current Peer Review Status:   

---

## Version 2

Reviewer Report 16 June 2021

<https://doi.org/10.5256/f1000research.20122.r44973>

© 2021 Joshi P et al. This is an open access peer review report distributed under the terms of the [Creative Commons Attribution License](#), which permits unrestricted use, distribution, and reproduction in any medium, provided the original work is properly cited.



**Pankaj Joshi** 

Centre for Reconstructive Urology, Pune, Maharashtra, India

**Sandeep Bafna**

Centre for Reconstructive Urology, Pune, Maharashtra, India

I do not have any issue with the final edited version. Have gone through all the changes requested earlier.

**Competing Interests:** No competing interests were disclosed.

**Reviewer Expertise:** Reconstructive Urology

**We confirm that we have read this submission and believe that we have an appropriate level of expertise to confirm that it is of an acceptable scientific standard.**

Reviewer Report 08 July 2019

<https://doi.org/10.5256/f1000research.20122.r50324>

© 2019 Mudogo C. This is an open access peer review report distributed under the terms of the [Creative Commons Attribution License](#), which permits unrestricted use, distribution, and reproduction in any medium, provided the original work is properly cited.



**Celestin Nzanzu Mudogo** 

Institute for Biochemistry and Molecular Biology, University of Hamburg, Hamburg, Germany

Strength of the paper

- First case reported on duality between breast and prostate cancer in male. This finding may suggest a specific prostate surveillance or genetic screening for men prostatism symptoms or asymptomatic rise in PSA.



**Weakness of the research work**

- Lack of genetic testing outcomes correlation to the clinical cases presented still a limitation of this study.
- Some studies suggest an evidence correlation between Hormone and symptomatic or asymptomatic prostate cancer! Unfortunately, the authors could not follow up and present the Hormones profiles before and after the Tamoxifen treatment and Prostate cancer diagnosis because of funding issues! This could be very informative to be discussed and need to be consider in their future work.

In sum, these rare cases reported is an initial presentation of the duality between prostate to breast cancer in men! I recommend the paper for indexing as a clinical case report and I'm looking forward to reading the next paper based on future work discussed in this paper.

**Is the background of the cases' history and progression described in sufficient detail?**

Yes

**Are enough details provided of any physical examination and diagnostic tests, treatment given and outcomes?**

Partly

**Is sufficient discussion included of the importance of the findings and their relevance to future understanding of disease processes, diagnosis or treatment?**

Partly

**Is the conclusion balanced and justified on the basis of the findings?**

Yes

**Competing Interests:** No competing interests were disclosed.

**Reviewer Expertise:** Biochemistry and Molecular Parasitology

**I confirm that I have read this submission and believe that I have an appropriate level of expertise to confirm that it is of an acceptable scientific standard, however I have significant reservations, as outlined above.**

Reviewer Report 18 March 2019

<https://doi.org/10.5256/f1000research.20122.r44974>

© 2019 Lojanapiwat B. This is an open access peer review report distributed under the terms of the [Creative Commons Attribution License](#), which permits unrestricted use, distribution, and reproduction in any medium, provided the original work is properly cited.



**Bannakij Lojanapiwat**

Department of Surgery, Chiang Mai University, Chiang Mai, Thailand

I do not have changes to the final version that it is ok for indexing.

**Is the background of the cases' history and progression described in sufficient detail?**

Yes

**Are enough details provided of any physical examination and diagnostic tests, treatment given and outcomes?**

Yes

**Is sufficient discussion included of the importance of the findings and their relevance to future understanding of disease processes, diagnosis or treatment?**

Yes

**Is the conclusion balanced and justified on the basis of the findings?**

Yes

**Competing Interests:** No competing interests were disclosed.

**I confirm that I have read this submission and believe that I have an appropriate level of expertise to confirm that it is of an acceptable scientific standard.**

---

### Version 1

Reviewer Report 15 January 2019

<https://doi.org/10.5256/f1000research.18583.r41758>

© 2019 Lojanapiwat B. This is an open access peer review report distributed under the terms of the [Creative Commons Attribution License](#), which permits unrestricted use, distribution, and reproduction in any medium, provided the original work is properly cited.



**Bannakij Lojanapiwat**

Department of Surgery, Chiang Mai University, Chiang Mai, Thailand

Both breast cancer and prostate cancer are hormonal dependent and have genetic alteration in recent studies, This article is not perfect due to lack of genetic testing that is difficult to explain the co-incident of both cancer.

Conclusion is quite long, author should rewrite. Conclusion has this sentence 'suggest that men with prostate cancer be screened clinically, biochemically and genetically for breast cancer and vice versa.' Maybe write 'only suggests that men with prostate cancer can be screened for breast cancer.'

If possible summary of the case report in Table maybe more understand the natural history and treatment of this rare condition.

**Is the background of the cases' history and progression described in sufficient detail?**

Yes

**Are enough details provided of any physical examination and diagnostic tests, treatment given and outcomes?**

Yes

**Is sufficient discussion included of the importance of the findings and their relevance to future understanding of disease processes, diagnosis or treatment?**

Partly

**Is the conclusion balanced and justified on the basis of the findings?**

No

**Competing Interests:** No competing interests were disclosed.

**Reviewer Expertise:** Urooncology, endourology

**I confirm that I have read this submission and believe that I have an appropriate level of expertise to confirm that it is of an acceptable scientific standard, however I have significant reservations, as outlined above.**

Reviewer Report 04 December 2018

<https://doi.org/10.5256/f1000research.18583.r40909>

© 2018 Joshi P. This is an open access peer review report distributed under the terms of the [Creative Commons Attribution License](#), which permits unrestricted use, distribution, and reproduction in any medium, provided the original work is properly cited.



**Pankaj Joshi**

Centre for Reconstructive Urology, Pune, Maharashtra, India

It's an interesting observation.

I think authors should mention BRCA Gene mutation's role in breast and prostate cancer.

Why is the second patient on ADT if bone scan was negative?

Details are important when discussing cancer:

What was the breast pathology? Ductal or lobular? What were the patients' Gleason scores and PSAs?

Which men would you screen for breast cancer since it is so rare - less than 1/100? Which genetic tests? Be clear with screening goals because you are talking about screening parameters because prostate cancer affects a massive population.

Those are my thoughts to the author(s). It is an idea which needs refinements and more details regarding how and why we should carry their message into practice.

**Is the background of the cases' history and progression described in sufficient detail?**

No

**Are enough details provided of any physical examination and diagnostic tests, treatment given and outcomes?**

Yes

**Is sufficient discussion included of the importance of the findings and their relevance to future understanding of disease processes, diagnosis or treatment?**

No

**Is the conclusion balanced and justified on the basis of the findings?**

No

**Competing Interests:** No competing interests were disclosed.

**Reviewer Expertise:** Reconstructive Urology

**I confirm that I have read this submission and believe that I have an appropriate level of expertise to confirm that it is of an acceptable scientific standard, however I have significant reservations, as outlined above.**

Author Response 04 Dec 2018

**Alain Mwamba Mukendi**, Chris Hani Baragwanath Academic Hospital / University of the Witwatersrand, Johannesburg, South Africa

Thank you for your review. I am not sure if you could access the entire article most of the points raised have their answers in the article. All the PSA, Gleason scores etc. Are under case presentation. The role of BRCA was also highlighted under the discussion. Both breast malignancies were ductal as shown in figures 3 and 5. We will on the next version specify that for the first case.

**Competing Interests:** None

---

## Comments on this article

Version 1

Author Response 18 Dec 2018

**Alain Mwamba Mukendi**, Chris Hani Baragwanath Academic Hospital / University of the Witwatersrand, Johannesburg, South Africa

Thank you for your input. Once I get the second referee review I will specify the breast histopath for case 1 and wait for your final review.

**Competing Interests:** None

Reviewer Response ( ) 17 Dec 2018

**Pankaj Joshi**, Centre for Reconstructive Urology, Pune, Maharashtra, India

Your comments are appreciated.

Good correlation

Nice histopath slides

Please specify the changes in Case 1

**Competing Interests:** No competing interests were disclosed.

---

The benefits of publishing with F1000Research:

- Your article is published within days, with no editorial bias
- You can publish traditional articles, null/negative results, case reports, data notes and more
- The peer review process is transparent and collaborative
- Your article is indexed in PubMed after passing peer review
- Dedicated customer support at every stage

For pre-submission enquiries, contact [research@f1000.com](mailto:research@f1000.com)

**F1000Research**