



OPEN Investigation of postmortem change in the human corneal epithelium via impression cytology

Ting Deng¹, Kaori Shintani-Ishida^{1✉}, Hidetoshi Tanioka², Chie Sotozono² & Hiroshi Ikegaya¹

The corneal epithelium, which consists of superficial, intermediate, and basal layers, demonstrates layer-by-layer shedding with the prolongation of postmortem interval (PMI). This study aimed to evaluate postmortem changes in the corneal epithelium via impression cytology. Specimens were obtained from 134 cases of postmortem CT and/or autopsy, which were divided into 6 groups by PMI (6 h–14 days). The cells collected from the corneal surface using membrane filters were double-stained with antibodies against ZO-1 (expressing on superficial cells) and occludin (expressing on either superficial or intermediate cells) to identify them. With the prolongation of PMI, the percentage of ZO-1 (+)/occludin (+) cells decreased, whereas that of ZO-1 (–)/occludin (–) cells increased, demonstrating the shedding of the corneal epithelium. Meanwhile, ZO-1 (–)/occludin (+) cells initially exhibited an increase in percentage until 48 h and then became undetectable, suggesting a decline in stainability. Age, gender, and wet conditions did not have a significant effect on the number of ZO-1 (+)/occludin (+) or ZO-1 (–)/occludin (–) cells. The effects of ambient temperature and whether the eyelids were open or closed remain unclear due to a lack of data. A simple and noninvasive impression cytology may be applicable for diagnosis in forensic practice.

Keywords Corneal epithelium, Postmortem interval, Impression cytology, Tight junctions, ZO-1, Occludin

In the field of forensic medicine, postmortem interval (PMI) estimation is crucial. The postmortem changes in the body, including body temperature, rigor mortis, lividity, and corneal opacity, are useful to estimate PMI until approximately 72 h postmortem¹. However, body temperature, rigor mortis, and lividity are strongly influenced by external factors. Corneal opacity determination with the naked eye is subjective. Therefore, objective evaluation criteria that are not significantly influenced by the external environment are worthy of further exploration.

Because the eyeball is protected by the orbital cavity and the closed eyelid, postmortem changes in the eyeball are not significantly influenced by the external environment. In recent years, an increasing number of studies have been conducted on the correlation between PMI and postmortem eyeball changes, particularly in corneal opacity², corneal thickness³, iris and pupil⁴, lens⁵, retina⁶, intraocular pressure⁷, eye temperature^{8,9}, and vitreous electrolyte concentrations⁶. However, these examinations require invasive procedures or expensive instruments. To address this problem, the development of more convenient and noninvasive methods is urgently needed.

The corneal epithelial cells are divided into three layers from the anterior to the posterior, namely, superficial, intermediate, and basal cells. A previous study on the maximum time limit postmortem for harvesting donor cornea reported that the epithelial cells shed layer-by-layer with the prolongation of PMI^{10,11}. Observation of postmortem changes in the epithelial layers may be useful for the estimation of PMI in forensic medicine. However, in forensic practice, as the cornea of a cadaver cannot be collected before the autopsy, histological examination of corneal tissue sections is not feasible.

In ophthalmology, impression cytology is mainly employed in the screening of dry eye, keratoconjunctivitis and in the noninvasive detection of ocular surface tumors¹². This method was developed by Egbert in 1977¹³. It involves harvesting epithelial cells by applying a membrane filter to the cornea or conjunctiva for a few seconds under eye-point anesthesia. Impression cytology is simple and causes minimal damage to the cornea and conjunctiva. The corneal epithelium serves as a barrier, protecting the eye from the external environment, and this barrier function is maintained by tight junctions, which are cell–cell adhesive structures. The tight junctions of the corneal epithelium are composed of tight junction proteins, including ZO-1 and occludin. In the immunocytochemistry of intact human cornea, ZO-1 was restricted to the most superficial cells and was not

¹Department of Forensic Medicine, Graduate School of Medical Science, Kyoto Prefectural University of Medicine, 465 Kajii-cho, Kamigyo-ku, Kyoto 602-8566, Japan. ²Department of Ophthalmology, Graduate School of Medical Science, Kyoto Prefectural University of Medicine, Kyoto, Japan. ✉email: kaori@koto.kpu-m.ac.jp

observed in the intermediate or basal epithelial cells¹⁴. In the immunohistochemistry of the transverse sections of the human cornea, ZO-1 was stained at most apical superficial cells, as well as the border between the basal and intermediate cells¹⁵. Meanwhile, occludin was apparent in the superficial and intermediate cell layers of the epithelium in the transverse sections of the rat cornea¹⁶. Ban et al. demonstrated that occludin was concentrated at the cell–cell borders only in the superficial layer and that it appeared to be expressed in the superficial and intermediate cell layers in the human cornea¹⁵. Immunofluorescence staining with anti-ZO-1 and anti-occludin antibodies may be able to identify the epithelial cells harvested via impression cytology. This study aimed to determine whether corneal epithelial cells collected from the eyes of a cadaver via impression cytology are useful for the observation of postmortem changes in the corneal epithelium.

Results

Immunofluorescence staining of corneal epithelial cells collected from cadavers with different PMIs

The representative images of double-staining with anti-ZO-1 and anti-occludin antibodies are presented in Fig. 1a. Most of the cells in group 1 exhibited a pentagonal or hexagonal shape and were close to each other. Either ZO-1 or occludin was stained on the edge of each cell, and the stain was concentrated on the regions of contact between the cells (Fig. 1b). The cells shrank and scattered with the prolongation of the PMI.

ZO-1 (+)/occludin (+) cells accounted for 98.8% (median) of the total number of cells in group 1 (Fig. 2a). This value did not statistically change in group 2 but gradually decreased with the prolongation of the PMI to 78.4% in group 6. Spearman's rank correlation coefficient was -0.69 , indicating a negative correlation. Contrarily, the percentage of ZO-1 (–)/occludin (–) cells was only 0.39% in group 1, which increased with the prolongation of the PMI in group 4 and reached 19.3% in group 6 (Fig. 2c). A strong positive correlation was observed between the percentage of ZO-1 (–)/occludin (–) cells and PMI (Spearman's rank correlation coefficient = 0.70). Meanwhile, the percentage of ZO-1 (–)/occludin (+) cells initially increased in group 3 but subsequently decreased (Fig. 2b). Spearman's rank correlation coefficient was 0.20 .

The influence of other factors on the ZO-1/occludin-positive rate of postmortem corneal epithelial cells

To evaluate the simultaneous effect of PMI and another independent variable, including age, gender, and wet condition, on postmortem ZO-1/occludin-positive cell rate, two-way ANOVA analyses were conducted on the percentages of ZO-1 (+)/occludin (+) and ZO-1 (–)/occludin (–) cells, which statistically correlated with PMI. First, 114 cases, including those in their 50 s (50–59 years old, $n = 23$), 60 s (60–69 years old, $n = 22$), 70 s (70–79 years old, $n = 36$), and 80 s (80–89 years old, $n = 33$) were analyzed for the interaction between PMI and age on each cell type (Table 1). The effect of PMI was statistically significant, but that of age was not in both cell types. No significant interaction was observed between PMI and age.

Second, 134 cases, including 89 men and 45 women, were analyzed for the main effect of gender (Table 2). No significant effect of gender was observed in both cell types. However, there was a significant interaction between PMI and gender in ZO-1 (–)/occludin (–) cells but not in ZO-1 (+)/occludin (+) cells.

Wet and dry conditions may influence postmortem changes in the corneal epithelium. Cases until 48 h postmortem were divided into three groups based on the situation in which the cadaver was found: with the face submerged in the water in the bathroom ($n = 12$), with the face not submerged in the water in the bathroom ($n = 8$), and somewhere other than the bathroom or the waterside ($n = 61$). No significant effect of wet conditions and no significant interaction between PMI and wet conditions were observed in both cell types (Table 3).

Discussion

The majority of the cells collected from cadavers 6–12 h postmortem via impression cytology were identified as superficial cells based on the shapes and immunofluorescence staining patterns. Examination of 51 human donor corneas by scanning electron microscopy or light microscopy revealed intact epithelium within 48 h postmortem when the body was placed in a cold storage room at 4°C within a few hours after the death¹¹. After 48 h, superficial and deep epithelial layer separation, as well as epithelial cell loss, increased. Consistent with these findings, the present study demonstrated that the percentage of ZO-1 (+)/occludin (+) cells decreased at 25 h postmortem and that of ZO-1 (–)/occludin (–) cells increased at 49 h postmortem.

Meanwhile, the percentages of ZO-1 (–)/occludin (+) cells initially increased at 25–48 h postmortem and then subsequently decreased. In forensic pathology, a decline in immunohistochemistry reaction is frequently observed in tissue samples obtained from decomposed bodies. In a tissue microarray with 120 forensic autopsy samples, including liver, lung, and brain tissues, samples from cadavers collected 1–3 days postmortem exhibited positive staining with all antibodies, whereas samples with a longer PMI showed decreased staining rates¹⁷. In immunocytochemical staining of human, guinea pig, and rat colon and urinary bladder samples left for 48 h at 20°C until fixation, the quantity of positive staining substantially decreased owing to the autolysis of the tissue¹⁸. Immunohistochemistry in human surgical tissues revealed that the variation in staining intensity was mainly affected by the time interval prior to tissue fixation, and the staining intensity loss became evident at 48 h¹⁹. The number of ZO-1/occludin negative cells was likely to be partially affected by the decline in stainability with the antibodies.

Regarding age-related changes in the corneal epithelium, there have been several reports on corneal epithelial thickness (CET)^{20,21}, corneal epithelial cell density, and corneal epithelial cell area²². In the present study, among the 50–89-year-old groups, the changes in the corneal epithelium were mainly affected by PMI but not by age. These inconsistent findings could be attributed to different measurements. Furthermore, the age range in the present study was narrower than those in the other studies and did not include cases below 50 years old.



Fig. 1. Panel (a) shows representative images of the immunofluorescence staining of corneal epithelial cells collected from cadavers with different postmortem intervals. NC, negative control; scale bar = 50 μ m. Panel (b) shows magnified images of the cells in group 2.

Although the prevalence of dry eye increases with age²³, it could not be determined whether every cadaver has some eye disease.

No statistically significant difference was observed between men and women in the CET²⁴. Meanwhile, other studies reported that men had thicker corneas than women^{21,25}. In the present study, gender had no effect on the postmortem changes in the corneal epithelium, whereas an association was observed between gender and

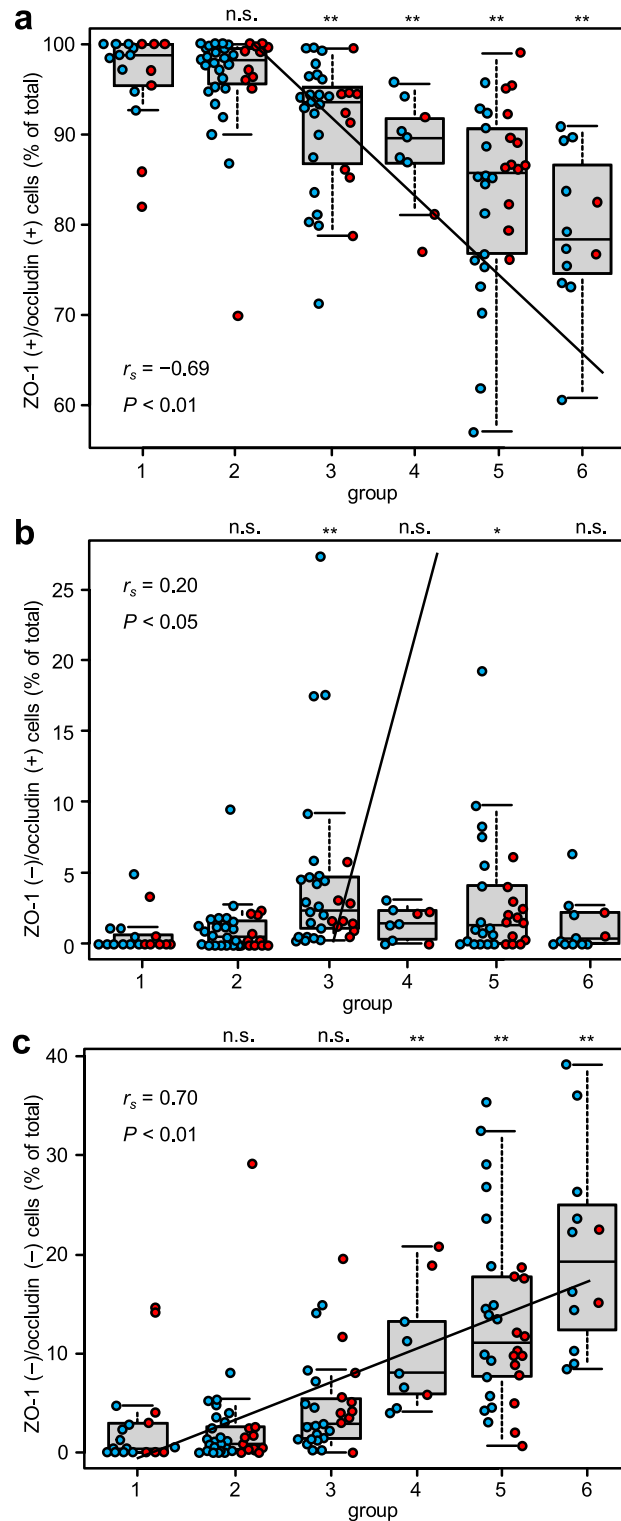


Fig. 2. Relationship between the postmortem interval and the percentages of ZO-1 (+)/occludin (+) cells (**a**), ZO-1 (-)/occludin (+) cells (**b**), and ZO-1 (-)/occludin (-) cells (**c**). Blue and red dots denote the male and female cases, respectively. Box plots show the minimum, first quartile, median, third quartile, and maximum values. r_s , Spearman's rank correlation coefficient. Steel's multiple comparisons test was employed to compare the 6–12 h postmortem group with the other groups; the analytical results are presented at the top of the graph. n.s., not significant; ** $P < 0.01$; * $P < 0.05$.

Cell types	PMI	Age	Interaction
ZO-1 (+)/occludin (+)	<0.001	0.83	0.81
ZO-1 (-)/occludin (-)	<0.001	0.73	0.49

Table 1. *P*-value in two-way ANOVA between the postmortem interval (PMI) and age on the ZO-1/occludin-positive cell rate. 114 cases, including those in their 50 s (50–59 years old, *n* = 23), 60 s (60–69 years old, *n* = 22), 70 s (70–79 years old, *n* = 36), and 80 s (80–89 years old, *n* = 33), were analyzed.

Cell types	PMI	Gender	Interaction
ZO-1 (+)/occludin (+)	<0.001	0.59	0.06
ZO-1 (-)/occludin (-)	<0.001	0.29	0.045

Table 2. *P*-value in two-way ANOVA between postmortem interval (PMI) and gender on the ZO-1/occludin-positive cell rate. 134 cases, including 89 men and 45 women, were analyzed.

Cell types	PMI	Situation	Interaction
ZO-1 (+)/occludin (+)	<0.001	0.87	0.12
ZO-1 (-)/occludin (-)	<0.01	0.80	0.051

Table 3. *P*-value in two-way ANOVA between postmortem interval (PMI) and wet condition on the ZO-1/occludin-positive cell rate. Cases until 48 h postmortem were divided into three groups based on the situation where the cadaver was found: with the face submerged in the water in the bathroom (*n* = 12), with the face not submerged in the water in the bathroom (*n* = 8), and somewhere other than the bathroom or the waterside (*n* = 61).

PMI in ZO-1 (-)/occludin (-) cells. This could be attributed to the significant difference in the number of cases between men and women as well as the small number of cases in general.

In mice exposed to a low-humidity environment, corneal barrier dysfunction was induced, which resulted in corneal epithelial shedding²⁶. However, it is unclear whether the effect of low humidity on corneal barrier function is extended to postmortem eyes. In the present study, the postmortem change in the corneal epithelium seemed to be unrelated to the situation in which the cadaver was found: in the bathroom or somewhere other than the bathroom or the waterside. However, as the present study was conducted during the high-humidity season in Kyoto, no significant difference was observed. Furthermore, although the eyelids of the cadaver were kept closed at least while being transported to our department, we could not obtain information on whether the eyelids were opened when the body was found.

To our knowledge, impression cytology has never been employed in forensic practices. It is suitable for forensic examination as it is noninvasive and fast method and does not affect the subsequent examination or autopsy. The immunofluorescence technique of impression cytology was successfully adapted by Pflugfelder et al. in 1990²⁷. In the present study, the membrane filter was dissolved with acetone before immunofluorescence staining according to Krenzer and Freddo's protocol²⁸ to eliminate background fluorescence and obtain better fluorescence images.

This study has several limitations that need to be acknowledged. The first is the possible contamination of conjunctival epithelial cells and blood cells in the impression cytology. Either ZO-1 or occludin was positively stained in conjunctival apical superficial cells and corneal epithelial cells²⁹. Thus, we excluded cases with blood on the cornea and in the conjunctival sac from the analysis. When we performed impression cytology, we opened the eyelid as gently as we could and placed the membrane filter on the center of the cornea. In addition, washing the bulbus with saline or other aqueous sterile solution before impression cytology may have prevented contamination of the sample with other cell types. The second limitation was that we could not fully obtain information on the situation when the body was found. In particular, ambient temperature and whether the eyelids are open or closed can have a big impact on corneal epithelial condition. The subject's history of eye disease was also unknown. In an injured corneal epithelium, ZO-1 expression was induced in the intermediate^{30,31} and basal³¹ cells to reform tight junctions during recovery. Finally, in this method, 3 h may be required to dissolve the membrane for immunofluorescence staining. Forensic applications may also require methods that do not necessitate the dissolution of the membrane for faster processing^{32–34}.

In conclusion, the present study demonstrated that it is possible to observe PMI-dependent changes in the corneal epithelium through immunofluorescence staining of tight junction proteins on corneal epithelial cells collected from the eyes of cadavers via impression cytology. A simple and noninvasive impression cytology may be applicable for diagnosis in forensic practice.

Group	Postmortem interval	Number of cases
1	6–12 h	17
2	13–24 h	35
3	25–48 h	31
4	49–72 h	9
5	4–7 days	30
6	8–14 days	12

Table 4. Number of cases in each group divided according to the postmortem interval.

Methods

The Ethical approval

This study was approved by the Institutional Review Board of the Kyoto Prefectural University of Medicine (ERB-C-3107). All experiments were performed in accordance with the Declaration of Helsinki. Sources of cadavers were medico-legal autopsies commissioned by the Kyoto Prefectural Police. Moreover, this study was conducted using autopsy records from the past. However, we could not obtain informed consent from the bereaved family for the use of these records. Therefore, we conducted this study in accordance with the Ethical Guidelines for Medical Research Involving Human Subjects, Chapter 5, Part 12-1, (b), (ii) (enacted by the Ministry of Health, Labor, and Welfare in Japan). We posted information about our research on our website (<https://square.umin.ac.jp/kpum-hoi/research.html>), allowing for the exclusion of individuals whose relatives did not agree to the study participation. The Institutional Review Board of the Kyoto Prefectural University of Medicine approved this method and waived the need for informed consent.

Study subjects

The subjects for the impression cytology were selected among cadavers taken to our department for postmortem computed tomography (CT) and/or autopsy from March 15 to August 31, 2024, based on the inclusion/exclusion criteria. The cadaver was transported to our department at room temperature with closed eyelids. Impression cytology was performed within approximately 15 min after the arrival of the cadaver. The inclusion criteria were PMI < 2 weeks and age > 18 years. The exclusion criteria were a high degree of decomposition, burning, eyeball atrophy, corneal dryness, eyeball injury, palpebral fissure stenosis, conjunctival healing, and blood or mucus on the cornea and in the conjunctival sac. The interval from the estimated time of death to the start time of CT examination or autopsy was defined as PMI. Impression cytology was performed in 134 cases that met the inclusion and exclusion criteria. The number of male and female cases were 89 and 45, respectively. The age range was 21–97 years, with a median age of 71 years. The PMI ranged from 6 h to 14 days. These cases were divided into six groups based on their PMIs (Table 4).

Impression cytology

Cellulose membrane filter (GSPW03700, Merck Millipore, Tokyo, Japan) was cut into a right trapezoid (2-mm long at the top, 4-mm long at the bottom, and 5-mm high). The membrane filter was placed on the central surface of the cornea using forceps and lightly pressed for 5 s using a small stick¹³. Subsequently, the picked membrane filter was sprayed with Cytosetter (J20000, Matsunami glass, Osaka, Japan) for fixation and was put the cell-attachment side down on a poly L-lysine-coated glass slide (Muto Pure Chemical, Tokyo, Japan). After drying the membrane filter, a drop of acetone was applied to facilitate the adhesion of cells to the glass slide, and the membrane filter was dried again to ensure complete adhesion. Then, to dissolve the membrane filter, the slide was soaked in acetone solution with agitation at 30 rpm for 1 h. After washing the slide with tap water for 5 min, the membrane filter residue was digested with 10-U/mL cellulase (Nacalai Tesque, Kyoto, Japan) solution (0.1 M acetate buffer pH 5) for 2 h at 37 °C²⁸. After washing with tap water followed by phosphate-buffered saline (PBS), the specimen was blocked with 5% donkey serum (D9663, Sigma-Aldrich, Tokyo, Japan) in PBS for 30 min and then incubated with anti-ZO-1 (1:1000, 21773-1-AP, Proteintech, Tokyo, Japan) and anti-occludin (1:2000, 66378-1-Ig, Proteintech) antibodies for 1 h at room temperature. Next, after washing with 1% BSA with PBS three times, the specimen was incubated with ZO-1 (1:500, Goat Anti-Rabbit IgG H&L Alexa Fluor® 488, ab150081, Abcam, Tokyo, Japan) and occludin (1:1000, Goat Anti-Mouse IgG H&L Alexa Fluor® 568, ab175701, Abcam) antibodies for 1 h at room temperature. Afterward, the specimen was mounted with medium with DAPI (VECTASHIELD #H-1800, Vector Laboratories, Newark, CA). A total of 12 fluorescence images were obtained from each slide using a fluorescence microscope (BZ-X710 All-in-One Fluorescence Microscope, Keyence, Osaka, Japan) at a magnification of 40x. The specimen not stained with the primary antibody was used as the negative control. The DAPI-stained cells were classified into ZO-1 (+)/occludin (+), ZO-1 (-)/occludin (+), and ZO-1 (-)/occludin (-). The number of cells was counted using an imaging software (cellSens 1.16, Evident, Tokyo, Japan, <https://evidentscientific.com/en/products/software/cellsens>).

Statistical analysis

Quantitative data were expressed as median (interquartile range [IQR]) and analyzed using EZR³⁵. Spearman's rank correlation coefficient was used to determine the correlation between PMI and the number of immunostained cells. Steel's multiple comparisons test was employed to compare the 6–12 h postmortem group with the other groups. The influence of the other factors on the correlation was investigated via two-way analysis of variance (ANOVA) within the different PMI groups. *P*-values of 0.05 or less were considered to be statistically significant.

Conference presentation

This study was presented at a regional congress of Japanese Society of Legal Medicine in Nara, Japan (11/9/2024). The short abstract will be published on the website of Japanese Society of Legal Medicine.

Data availability

The datasets generated or analyzed during the current study are available from the corresponding author on reasonable request.

Received: 29 November 2024; Accepted: 27 May 2025

Published online: 06 June 2025

References

- Shrestha, R., Kanchan, T. & Krishan, K. *Methods of Estimation of Time Since Death* (StatPearls Publishing, Treasure Island (FL), 2024). <https://www.ncbi.nlm.nih.gov/books/NBK549867>.
- Nath, A. et al. A cross-sectional study of time since death from image analysis of corneal opacity. *Cureus* **13**, e14975. <https://doi.org/10.7759/cureus.14975> (2021).
- Napoli, P. E. et al. Repeatability and reproducibility of post-mortem central corneal thickness measurements using a portable optical coherence tomography system in humans: a prospective multicenter study. *Sci. Rep.* **10**, 14508. <https://doi.org/10.1038/s41598-020-71546-1> (2020).
- Englisch, C. N., Alrefai, R., Lesan, C. M., Seitz, B. & Tschernig, T. Postmortem sympathomimetic iris excitability. *Ann. Anat.* **254**, 152240. <https://doi.org/10.1016/j.aanat.2024> (2024).
- Prieto-Bonete, G., Perez-Carceles, M. D. & Luna, A. Morphological and histological changes in eye lens: Possible application for estimating postmortem interval. *Leg. Med. (Tokyo)* **17**, 437–442 (2015).
- Palić, M., Šoštarić-Zuckermann, I. C., Džaja, P., Ljubić, B. B. & Severin, K. A biochemical and histological assessment of postmortem changes to the eyes of domestic pigs: a preliminary study. *Animals (Basel)* **14**, 1190. <https://doi.org/10.3390/ani14081190> (2024).
- Balci, Y., Basmak, H., Kocaturk, B. K., Sahin, A. & Ozdamar, K. The importance of measuring intraocular pressure using a tonometer in order to estimate the post-mortem interval. *Am. J. Forensic Med. Pathol.* **31**, 151–155 (2010).
- Kaliszan, M. Studies on time of death estimation in the early post mortem period: application of a method based on eyeball temperature measurement to human bodies. *Leg. Med. (Tokyo)* **15**, 278–282 (2013).
- Kaliszan, M. & Wujewicz, M. Eye temperature measured after death in human bodies as an alternative method of time of death estimation in the early post mortem period: a successive study on new series of cases with exactly known time of death. *Leg. Med. (Tokyo)* **38**, 10–13 (2019).
- Slettedal, J. K., Lyberg, T., Ramstad, H., Beraki, K. & Nicolaissen, B. Regeneration of the epithelium in organ-cultured donor corneas with extended post-mortem time. *Acta Ophthalmol. Scand.* **85**, 371–376 (2007).
- Slettedal, J. K., Lyberg, T., Ramstad, H. & Nicolaissen, B. Donor corneas for transplantation: a scanning electron microscopic study of the epithelium. *Acta Ophthalmol. Scand.* **84**, 516–521 (2006).
- Moshaghian, S. M., Abolhosseini, M., Rezaei Kanavi, M. & Hosseini, S. B. Impression cytology for detection of clinically suspected ocular surface disorders: a cross-sectional study. *Eur. J. Ophthalmol.* **31**, 943–950 (2021).
- Egbert, P. R., Lauber, S. & Maurice, D. M. A simple conjunctival biopsy. *Am. J. Ophthalmol.* **84**, 798–801 (1977).
- Crewe, J. M. & Armitage, W. J. Integrity of epithelium and endothelium in organ-cultured human corneas. *Invest. Ophthalmol. Vis. Sci.* **42**, 1757–1761 (2001).
- Ban, Y. et al. Tight junction-related protein expression and distribution in human corneal epithelium. *Exp. Eye Res.* **76**, 663–669 (2003).
- Suzuki, K., Tanaka, T., Enoki, M. & Nishida, T. Coordinated reassembly of the basement membrane and junctional proteins during corneal epithelial wound healing. *Invest. Ophthalmol. Vis. Sci.* **41**, 2495–2500 (2000).
- Lesnikova, I., Schreckenbach, M. N., Kristensen, M. P., Papanikolaou, L. L. & Hamilton-Dutoit, S. Usability of immunohistochemistry in forensic samples with varying decomposition. *Am. J. Forensic Med. Pathol.* **39**, 185–191 (2018).
- Gu, J., Huang, W. M. & Polak, J. M. Stability of immunocytochemical reactivity of neuronal substances following delayed fixation. *J. Neurosci. Methods* **12**, 297–302 (1985).
- Maleszewski, J., Lu, J., Fox-Talbot, K. & Halushka, M. K. Robust immunohistochemical staining of several classes of proteins in tissues subjected to autolysis. *J. Histochem. Cytochem.* **55**, 597–606 (2007).
- Colakoglu, A. & Cosar, C. B. Age-related changes in corneal epithelial thickness measured with an ultrasound pachymeter. *Clin. Interv. Aging* **17**, 1461–1470 (2022).
- Kim, B. J., Ryu, I. H. & Kim, S. W. Age-related differences in corneal epithelial thickness measurements with anterior segment optical coherence tomography. *Jpn. J. Ophthalmol.* **60**, 357–364 (2016).
- Chin, J. Y. et al. Impact of age on the characteristics of corneal nerves and corneal epithelial cells in healthy adults. *Cornea* **43**, 409–418 (2024).
- Cui, X. et al. Assessment of corneal epithelial thickness in dry eye patients. *Optom. Vis. Sci.* **91**, 1446–1454 (2014).
- Samy, M. M., Shaaban, Y. M. & Badran, T. A. F. Age- and sex-related differences in corneal epithelial thickness measured with spectral domain anterior segment optical coherence tomography among Egyptians. *Medicine (Baltimore)* **96**, e8314. <https://doi.org/10.1097/md.0000000000008314> (2017).
- Abusamak, M. Corneal epithelial mapping characteristics in normal eyes using anterior segment spectral domain optical coherence tomography. *Trans. Vis. Sci. Technol.* **11**, 6. <https://doi.org/10.1167/tvst.11.3.6> (2022).
- Pelegriño, F. S., Pflugfelder, S. C. & De Paiva, C. S. Low humidity environmental challenge causes barrier disruption and cornification of the mouse corneal epithelium via a c-jun N-terminal kinase 2 (JNK2) pathway. *Exp. Eye Res.* **94**, 150–156 (2012).
- Pflugfelder, S. C. et al. Conjunctival cytologic features of primary Sjögren's syndrome. *Ophthalmology* **97**, 985–991 (1990).
- Krenzer, K. L. & Fredro, T. F. Cytokeratin expression in normal human bulbar conjunctiva obtained by impression cytology. *Invest. Ophthalmol. Vis. Sci.* **38**, 142–152 (1997).
- Yoshida, Y., Ban, Y. & Kinoshita, S. Tight junction transmembrane protein claudin subtype expression and distribution in human corneal and conjunctival epithelium. *Invest. Ophthalmol. Vis. Sci.* **50**, 2103–2108 (2009).
- Wang, Y., Chen, M. & Wolosin, J. M. ZO-1 in corneal epithelium; stratal distribution and synthesis induction by outer cell removal. *Exp. Eye Res.* **57**, 283–292 (1993).
- Jongkhajornpong, P., Nakamura, T., Sotozono, C., Inatomi, T. & Kinoshita, S. Phenotypic investigation of regenerated epithelial cells after gonococcal corneal perforation: a clinical, histological, and immunohistochemical study. *Cornea* **34**, 1508–1512 (2015).
- Chao, C. et al. Conjunctival MUC5AC+ goblet cell index: relationship with corneal nerves and dry eye. *Graefes Arch. Clin. Exp. Ophthalmol.* **256**, 2249–2257 (2018).
- Jirsova, K. et al. Aberrant HLA-DR expression in the conjunctival epithelium after autologous serum treatment in patients with graft-versus-host disease or Sjögren's syndrome. *PLoS ONE* **15**, e0231473 (2020).
- Santos, A. et al. Increased inflammatory mediators in the ocular surface tissue in keratoconus. *Mol. Vis.* **30**, 279–288 (2024).

35. Kanda, Y. Investigation of the freely available easy-to-use software “EZR” for medical statistics. *Bone Marrow Transp.* **48**, 452–458 (2013).

Acknowledgements

We thank Enago for the English language review.

Author contributions

Conceptualization: T. D.; methodology: T. D., K. S.-I., and H. T; formal analysis and investigation: T. D.; writing—original draft preparation: T. D. and K. S.-I.; writing—review and editing: C. S. and H. I. All authors have read and agreed to the published version of the manuscript.

Funding

No funding was received to assist with the preparation of this manuscript.

Declarations

Competing interests

The authors declare no competing interests.

Additional information

Correspondence and requests for materials should be addressed to K.S.-I.

Reprints and permissions information is available at www.nature.com/reprints.

Publisher’s note Springer Nature remains neutral with regard to jurisdictional claims in published maps and institutional affiliations.

Open Access This article is licensed under a Creative Commons Attribution-NonCommercial-NoDerivatives 4.0 International License, which permits any non-commercial use, sharing, distribution and reproduction in any medium or format, as long as you give appropriate credit to the original author(s) and the source, provide a link to the Creative Commons licence, and indicate if you modified the licensed material. You do not have permission under this licence to share adapted material derived from this article or parts of it. The images or other third party material in this article are included in the article’s Creative Commons licence, unless indicated otherwise in a credit line to the material. If material is not included in the article’s Creative Commons licence and your intended use is not permitted by statutory regulation or exceeds the permitted use, you will need to obtain permission directly from the copyright holder. To view a copy of this licence, visit <http://creativecommons.org/licenses/by-nc-nd/4.0/>.

© The Author(s) 2025