

Contents lists available at [ScienceDirect](#)

## International Journal of Surgery Case Reports

journal homepage: [www.casereports.com](http://www.casereports.com)

# Agnesis of gall bladder in laparoscopic cholecystectomy—A case report



Samer Makki Mohamed Al-Hakkak

Department of Surgery, Faculty of Medicine, Jabir Ibn Hayyan Medical University, Najaf city, Iraq

## ARTICLE INFO

### Article history:

Received 7 February 2017

Received in revised form 21 June 2017

Accepted 22 June 2017

Available online 3 August 2017

### Keywords:

Agnesis of gall bladder

Gallbladder diseases

Laparoscopic cholecystectomy

Ultrasound diagnosis

Unnecessary surgery

Conversion to open

## ABSTRACT

**INTRODUCTION:** Agnesis of gallbladder is a rare congenital anomaly of biliary tree that may be associated with other biliary and extra biliary congenital anomalies.

**CASE PRESENTATION:** A 43-year-old female presented with a 4 months history of upper abdominal pain associated with nausea and vomiting. It was associated with dyspeptic symptoms and become worse following ingestion of high-fat meal contents. Clinically, a differential of gall stone disease was considered. Ultrasonography of abdomen revealed a contracted gallbladder with multiple stones with normal wall thickness, so the fact of clinical diagnosis considering finding cholithiasis. She was submitted to laparoscopic exploration which revealed that the gall bladder was absent within gall bladder fossa.

**DISCUSSION:** In this case, the differential of cholithiasis symptoms considered support by ultrasonography, symptomatic gall stones presented more than half of cases of gall bladder agnesis. Diagnosis of gall bladder disease usually done by ultrasound modality, it must be done by expert one. Awareness of this entity by clinicians, surgeons and radiologists are essential because many of these patients present with biliary symptoms and have unnecessary operations.

**CONCLUSION:** Agnesis of gallbladder should be kept in mind whenever the gall bladder was improperly visualized in routine imaging methods. Ultrasonography operated dependent we must not depend on single one or even multiple done by the same person. Avoid a needless surgical exploration, which might be risky. Non-visualized gall bladder during laparoscopic cholecystectomy is challenging should not convert to open unless sure that the gall bladder was present.

© 2017 The Author(s). Published by Elsevier Ltd on behalf of IJS Publishing Group Ltd. This is an open access article under the CC BY-NC-ND license (<http://creativecommons.org/licenses/by-nc-nd/4.0/>).

## 1. Introduction

Agnesis of gall bladder without extrahepatic biliary atresia is a well-recognized but extremely rare congenital anomaly in which the GB fails to develop, and subsequently it is not found at the usual or at the most common atypical sites [1–3]. Agnesis of gall bladder (AGB) if it is not associated with other anatomical alterations, it is mainly discovered in adults. Although agnesis gall bladder is a rare anomaly, the surgeon and radiologists should be aware of it when interpreting questionable ultrasound (US) findings, so that they can arrange for other investigations to avoid unnecessary operations or to minimize confusion during attempted cholecystectomy [16,17]. After more than 300 years since the initial description, this rare condition is still presenting a dilemma to the radiologists and surgeons (since the first case was described by Lemery in 1701). Agnesis gallbladder is an extremely rare embryological aberration with a reported incidence ranging between 0.01% and 0.075% (10–75 per 100 000 population).[1–5,18]. The reported inci-

dence based on autopsy findings is approximately one case in 6334 live births or approximately 0.035–0.3% [1,6,19,20]. The etiology of GBA is unknown, but generally it is accepted to be a congenital malformation [7]. Gallbladder agnesis is most often a sporadic occurrence with no clear cause.

## 2. Clinical presentations

A 43 year old female was investigated for right upper quadrant pain of 4 months duration associated with nausea and vomiting. The pain was aching in nature, was dull, it was not radiated to other region. It was associated with dyspeptic symptoms and become worse following ingestion of high fat meal contents. There was no biliary colic, no symptom of obstructed jaundice, no constipation. On examination there was no organomegaly, no palpable masses detected. Her liver function test were normal.

Ultrasonography of abdomen revealed a contracted gall bladder with multiple stones with normal wall thickness, so the fact of clinical diagnosis considering the above finding cholithiasis. She was prepared and scheduled for elective laparoscopic cholecystectomy due to persistent symptoms. She submitted to laparoscopic exploration which revealed that the gall bladder was absent within

E-mail addresses: [sammerhakak1971@yahoo.com](mailto:sammerhakak1971@yahoo.com), [sammerhakak1971@gmail.com](mailto:sammerhakak1971@gmail.com)

<http://dx.doi.org/10.1016/j.ijscr.2017.06.054>

2210-2612/© 2017 The Author(s). Published by Elsevier Ltd on behalf of IJS Publishing Group Ltd. This is an open access article under the CC BY-NC-ND license (<http://creativecommons.org/licenses/by-nc-nd/4.0/>).

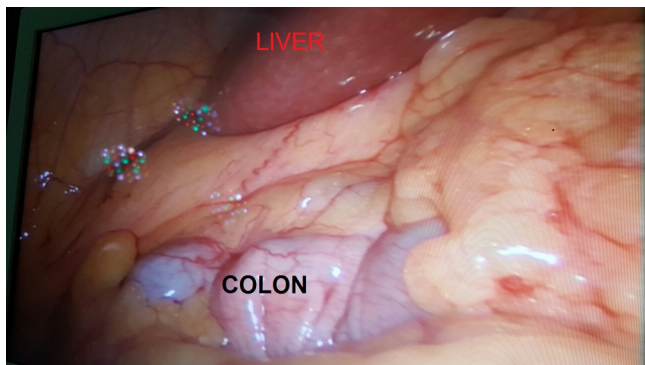


Fig. 1. a) Surgical view of laparoscopic cholecystectomy, First po. b) Lifting the right lobe of liver to visualize the anatomy o.

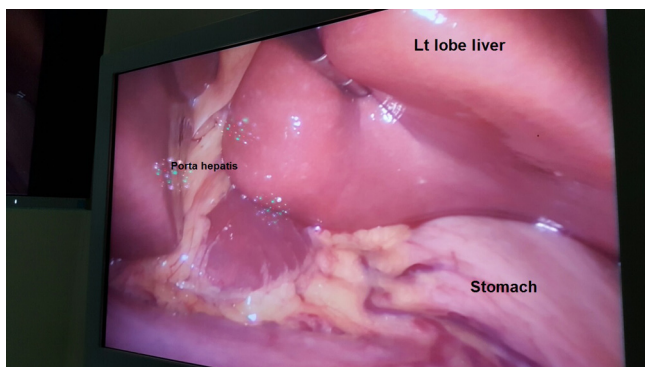


Fig. 2. Surgical view, lift the left the lobe of the liver to se.

gall bladder fossa as shown in (Figs. 1 and 2). We call more experience laparoscopic surgeon ask for help say non visualized GB then call radiologist to the theater to do intra-operative ultrasonography was also revealed that the gall bladder not visualized. May be not present this were strange unpredictable events. The decision was

the operation ended. Postoperative reassessment and evaluation by MRCP and CT scan as shown in (Figs. 3 and 4). The gall bladder was absent with normal biliary tree.

### 3. Discussion

Gallbladder(GB) agenesis diagnosed during surgery has a female predominance of 3:1, while cases found in autopsies have an equal sex ratio [21]. Most of the adult patients with (AGB)are between 36 and 46 years of age at presentation [2,21]. Three groups have been identified:

- 1 Symptomatic cases,
- 2 Asymptomatic cases, and those with
- 3 Multiple fetal anomalies [1,4,26].

Agenesis of gallbladder occurs alone in 70–87.2% of cases (31.6% asymptomatic cases, and 55.6% symptomatic cases). It occurs in association with additional malformations in the remaining 12.8–30% of cases. Asymptomatic cases are found incidentally during autopsy or during operations for non-biliary disorders or during screening of the patient’s family [20,22–25]. Most of the reported operated cases of agenesis of gall bladder(AGB) were symptomatic and complained of abdominal symptoms (biliary symptoms) suggestive of biliary tract disease, and they have undergone either laparotomy or laparoscopic exploration with preoperative diagnosis of symptomatic GB disease [1,16,28]. Aggenesis gallbladder has no characteristic symptoms. It has been postulated that approximately 23% of the patients with AGB will develop symptoms suggestive of bile tract disease at some time in their lives, and bile duct stones will be found in 25–60% of them [2,4,18,21,25,27]. The symptoms may be secondary to concomitant biliary pathologies such as primary duct stones and biliary dyskinesia (patients may have a congenital abnormality of function in the form of a significant higher sphincter of Oddi resting pressure and an increase in the proportion of retrograde propagation of phasic muscular contraction with regurgitation of pancreatic or duodenal contents), or it may be related to non-biliary causes such

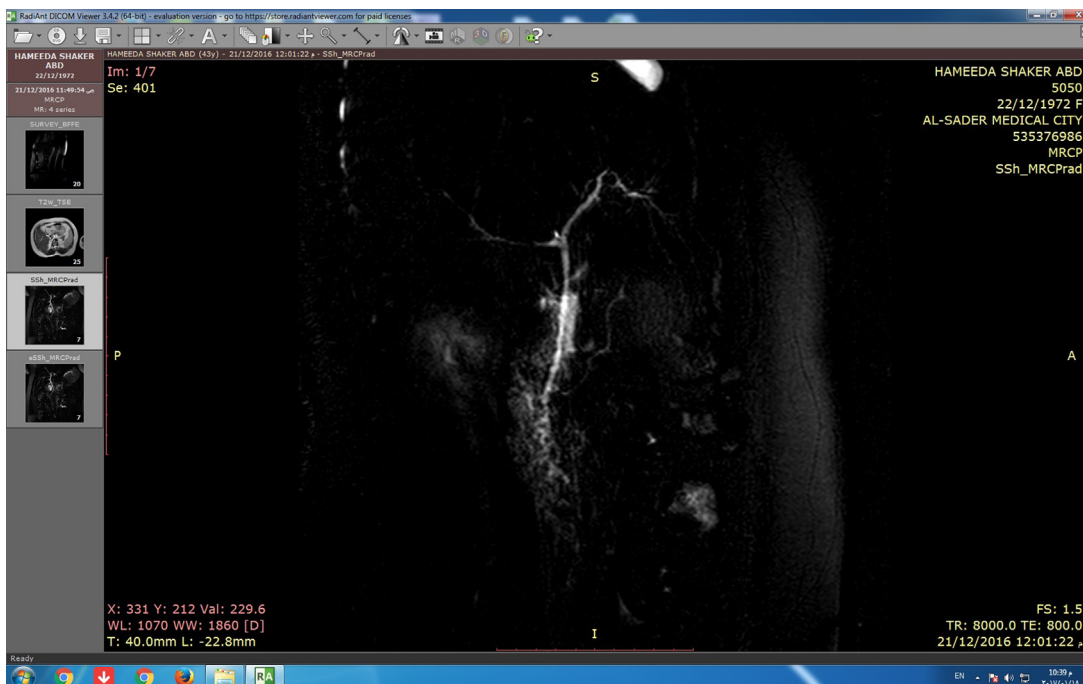


Fig. 3. Magnatic resonance cholangiopancreatography (MRCP), view.

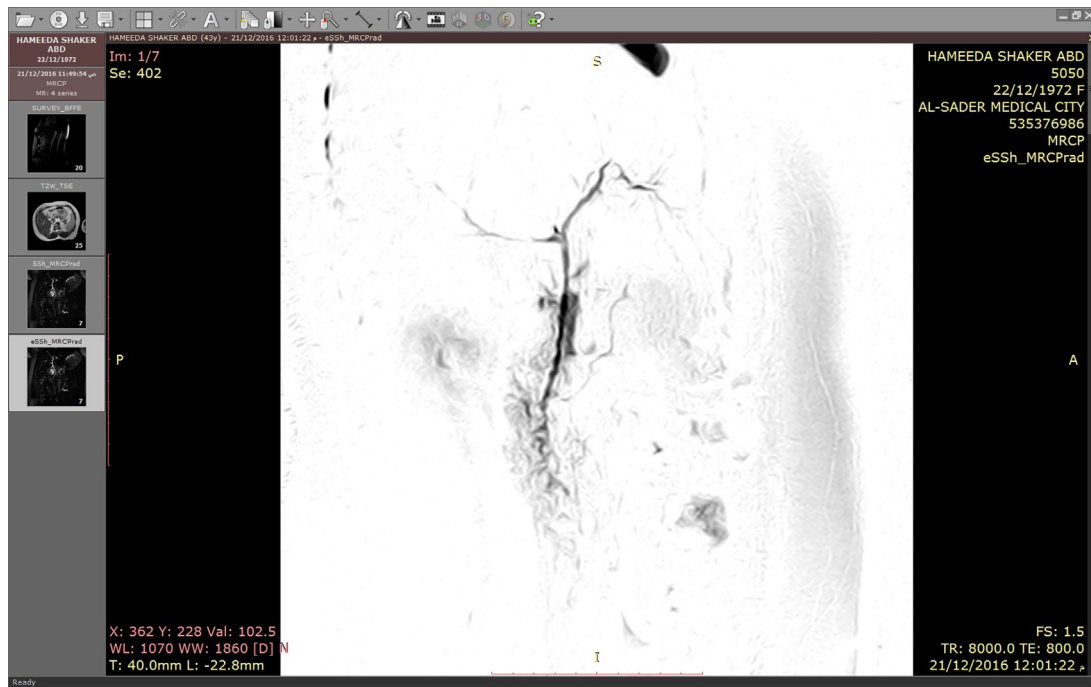


Fig. 4. MRCP negative view the anatomy of biliary tree, absent o.

as duodenitis, esophagitis, gastritis and irritable bowel disease [1,2,4,16,20,26,29,31]. A pathophysiological similarity between AGB and post-cholecystectomy bile duct dilatation has been suggested [2,21]. Despite the high accuracy of the modern US and other diagnostic imaging techniques, the preoperative diagnosis of AGB has been considered extremely difficult and nearly all diagnoses on symptomatic patients are made at laparotomy or during attempted laparoscopic cholecystectomy [27]. Although ideally AGB should be diagnosed before surgery, this has been documented in only few reports [6–15]. This is mainly because the radiological investigative methods for GB diseases present sensitivity of <100% for the identification of the GB, and US is highly operator-dependent [24,26].

The standard investigative modalities, which are used for investigation of biliary symptoms, US might be fallacious and baffling [30]. In which case it is virtually impossible to diagnose AGB by such conventional modalities. Additionally, due to the rarity of gall bladder agenesis, surgeon and radiologists are unfamiliar with and hesitate to document it despite failure to find the GB on US [20]. The indication for surgery in patients with agenesis of gall bladder is usually a complaint of biliary symptoms along with a false positive US study [1]. The preoperative US or cholangiography may suggest a small contracted (shrunken, scarred, sclerotic, or atrophied) GB with cholelithiasis with or without dilatation of the common bile duct in most of the patients [16,21]. The periportal tissue and subhepatic peritoneal folds may be incorrectly interpreted as shrunken GB [1,16,26], or the highly reflective gas-filled duodenum may mimic a GB filled with stones [16].

Patients might be misdiagnosed as having acute cholelithiasis cholecystitis (incorrectly diagnosed as cholelithiasis) and referred for cholecystectomy [32]. Alternatively the GB may not be visualized by US and the preoperative diagnosis of non-functioning symptomatic GB secondary to acute or chronic cholecystitis is made and again the patients are referred for cholecystectomy.

Although US has 95% sensitivity for the diagnosis of cholelithiasis, occasionally a small contracted GB associated with stones and chronic cholecystitis will be difficult to visualize, and can lead to

erroneous interpretation because US examination not visualizing the GB in a patient with suggestive symptoms.

During the planned open or laparoscopic cholecystectomy for the presumed GB disease the surgeon can fail to locate the GB, which can be very challenging. A high index of suspicion is mandatory for diagnosis of AGB [33].

Preoperative diagnosis based on a CT scan, N-2,6-dimethylphenylcarbamoyl methyl iminodiacetic acid scan (HIDA scan) and cautious US had been reported in twins [14]. Magnetic resonance cholangiography is an ideal complementary investigation to inconclusive US studies. A few studies reported that AGB was diagnosed during attempted laparoscopic cholecystectomy for presumed gallstones, and ERCP and CT scan confirmed the diagnosis of AGB and thus laparotomy was avoided [10–13]. If the diagnosis of AGB is made during operation as in our case, the surgeon must prove AGB by thoroughly examining the most common sites for ectopic GB, which are intrahepatic, retrohepatic, on the left side, or within the leaves of the lesser omentum or within the falciform ligament, retroduodenal, retropancreatic and retroperitoneal [4–6]. Intraoperative US has a good tool must not forgotten in absent of GB intraoperative. Meticulous operative exploration and dissection of the entire extrahepatic biliary tree to established the diagnosis are not necessary [34], and it was risky.

Fischella et al. discourage an extensive routine diagnostic work up, and suggest a careful clinical and diagnostic evaluation of the patient who has symptoms suggestive of biliary tract disease [32].

If the diagnosis is made during surgery, the operative strategy is to seek of aberrant GB, but not do excessive dissection, it will harm the patient, better to end surgery and the diagnosis should be reconfirmed postoperatively by careful US or done by more expert radiologist, use highly sophisticated investigation like MRCP, CT and even ERCP. If symptoms continue postoperatively, then treatment with smooth muscle relaxants and analgesics is effective [1]. otherwise no treatment or definitive procedure is required if no symptoms occur, because the person with isolated AGB is healthy and the prognosis is excellent.



#### 4. Conclusion

Patients with AGB often are symptomatic and present with biliary-type pain. Agenesis of gallbladder should be kept in mind whenever the GB is improperly visualized in routine imaging methods. US operated dependent we must not depend on single US or even multiple done by same person. The awareness of physician, radiologist and the surgeons of the possibility of this condition and of the problems posed by it, may allow the surgeon to attempt confirmation of diagnosis, when suspected, by nonoperative methods, avoiding unnecessary surgical exploration and minimizing the risk of complications. Agenesis of gallbladder is a rarely encountered condition for a surgeon, but extensive diagnostic work-ups including MRCP, abdominal CT even ERCP should be performed in all situations when gall bladder agenesis is suspected. We underline the inaccuracy of currently used diagnostic tests and the importance of making a correct preoperative diagnosis to avoid a needless surgical exploration, which might be risky. non visualized GB during laparoscopic cholecystectomy, is challenging should not to convert to open unless sure that the GB is present.

#### Conflicts of interest

No any conflict of interest.

#### Funding

The article receive no funding.

#### Ethical approval

Ethically, we did not do excessive risky surgery, further assessment of patient done post operatively, for safe of patient.

#### Consent

Written informed consent was obtained from patient and his relative to participate in this case report.

#### Author contribution

No author contributor other than me.

#### Registration of research studies

Researchregistry.com 2666.

#### Guarantor

I accept full responsibility for the work and/or the conduct of the study, had access to the data, and controlled the decision to publish.

#### Appendix A. Supplementary data

Supplementary data associated with this article can be found, in the online version, at <http://dx.doi.org/10.1016/j.ijscr.2017.06.054>.

#### References

- [1] R.S. Bennion, J.E. Thompson Jr., R.K. Tompkins, Agenesis of the gallbladder without extrahepatic biliary atresia, *Arch. Surg.* 123 (1988) 1257–1260.
- [2] R.J. Jackson, D. McClellan, Agenesis of the gallbladder: a cause of false-positive ultrasonography, *Am. Surg.* 55 (1989) 36–40.
- [3] V. Houghton, A.W. Lewicki, Agenesis of the gallbladder. Is preoperative diagnosis possible? *Radiology* 106 (1973) 305–306.
- [4] U. Baltazar, J. Dunn, S. Gonzalez-Diaz, W. Browder, Agenesis of the gallbladder, *South Med. J.* 93 (2000) 914–915.
- [5] B. Singh, K.S. Satyapal, J. Moodley, A.A. Haffjee, Congenital absence of the gall bladder, *Surg. Radiol. Anat.* 21 (1999) 221–224.
- [6] N. Azmat, K.R. Francis, N. Mandava, W.F. Pizzi, Agenesis of the gallbladder revisited laparoscopically, *Am. J. Gastroenterol.* 88 (1993) 1269–1270.
- [7] M.A. Cabajo Caballero, J.C. Martin del Olmo, J.I. Blanco Alvarez, R. Atienza Sanchez, Gallbladder and cystic duct absence: an infrequent malformation in laparoscopic surgery, *Surg. Endosc.* 11 (1997) 483–484.
- [8] J.F. Amaral, R. Ferland, Agenesis of the gallbladder: laparoscopic diagnosis, *Surg. Laparosc. Endosc.* 3 (1993) 337–341.
- [9] M.J. Hershman, S.J. Southern, R.D. Rosin, Gallbladder agenesis diagnosed at laparoscopy, *J. R. Soc. Med.* 85 (1992) 702–703.
- [10] L. Sarli, V. Violi, S. Gobbi, Laparoscopic diagnosis of gallbladderagenesis, *Surg. Endosc.* 14 (2000) 373.
- [11] B. Singh, J. Moodley, A.A. Haffjee, P. Rajaruthnam, Laparoscopic diagnosis of gallbladder agenesis, *Surg. Laparosc. Endosc.* 7 (1997) 129–132.
- [12] P.B. Kestenholz, M. von Flue, F. Harder, Agenesis of the gallbladder in adults: a laparoscopic diagnosis, *Chirurg* 68 (1997) 643–645.
- [13] N. Gotohda, S. Itano, S. Horiki, et al., Gallbladder agenesis with no other biliary tract abnormality: report of a case and review of the literature, *J. Hepatobiliary Pancreat. Surg.* 7 (2000) 327–330.
- [14] M. Sugrue, J. Gani, R. Sarre, J. Watts, Ectopia and agenesis of the gall-bladder: a report of two sets of twins and review of the literature, *Aust. N.Z. J. Surg.* 61 (1991) 816–818.
- [15] R. Orlando, F. Candiani, F. Lirussi, Agenesis of the gallbladder associated with Gilbert's syndrome, *Surg. Endosc.* 15 (2001) 757.
- [16] B.K. Jain, D.N. Das, R.K. Singh, R. Kukreti, P. Dargan, Agenesis of gallbladder in symptomatic patients, *Trop. Gastroenterol.* 22 (2001) 80–82.
- [17] Q. Scott Jr., Preoperative ultrasound examination interpreted to represent a small contracted gallbladder with stones, *J. Am. Osteopath. Assoc.* 99 (1999) 530–532.
- [18] R.J. Richards, H. Taubin, D. Wasson, Agenesis of the gallbladder in symptomatic adults: a case and review of the literature, *J. Clin. Gastroenterol.* 16 (1993) 231–233.
- [19] S.E. Monroe, Congenital absence of the gallbladder: a statistical study, *J. Int. Coll. Surg.* 32 (1959) 369–373.
- [20] C.H. Cho, K.W. Suh, J.S. Min, C.K. Kim, Congenital absence of gallbladder, *Yonsei Med. J.* 33 (1992) 364–367.
- [21] J. Waisberg, P.E. Pinto Jr., P.R. Gusson, P.R. Fasano, A.C. Godoy, Agenesis of the gallbladder and cystic duct, *Sao Paulo Med. J.* 120 (2002) 192–194.
- [22] J.L. Kobacker, Congenital absence of the gallbladder: a possible hereditary defect, *Ann. Intern. Med.* 33 (1950) 1008–1021.
- [23] L.A. Nadeau, W.A. Cloutier, J.T. Konecki, G. Morin, R.W. Taylor, Hereditary gallbladder agenesis: twelve cases in the same family, *J. Maine Med. Assoc.* 63 (1972) 1–4.
- [24] J.M. Sterchi, R.W. Baine, R.T. Myers, Agenesis of the gallbladder: an inherited defect? *South Med. J.* 70 (1977) 498–499.
- [25] J.E. Wilson, J.E. Deitrick, Agenesis of the gallbladder: case report and familial investigation, *Surgery* 99 (1986) 106–109.
- [26] K.T. Vijay, H.H. Kocher, R.S. Koti, R.D. Bapat, Agenesis of gall bladder: a diagnostic dilemma, *J. Postgrad. Med.* 42 (1996) 80–82.
- [27] G. Belli, A. D'Agostino, A. Iannelli, G. Rotondano, P. Ceccarelli, Isolated agenesis of the gallbladder: an intraoperative problem, *Minerva Chir.* 52 (1997) 1119–1121.
- [28] R.K. Aspevik, B. Hjelseth, O. Irtun, Agenesis of the gallbladder, *Tidsskr. Nor. Laegeforen.* 122 (2002) 2774–2776.
- [29] M. Ibrarullah, S.S. Sikora, V.K. Kapoor, S. Awasthi, L.K. Kacker, Agenesis of the gallbladder: a case report, *Jpn. J. Surg.* 21 (1991) 580–582.
- [30] K.T. Vijay, H.H. Kocher, R.S. Koti, R.D. Bapat, Agenesis of gall bladder: a diagnostic dilemma, *J. Postgrad. Med.* 42 (1996) 80–82.
- [31] Z. Bekele, Congenital absence of the gallbladder and the cystic duct, *Ethiop. Med. J.* 40 (2002) 171–178.
- [32] P.M. Fisichella, A. Di Stefano, I. Di Carlo, G. La Greca, D. Russello, F. Latteri, Isolated agenesis of the gallbladder: report of a case, *Surg. Today* 32 (2002) 78–80.
- [33] N. Peloponissios, M. Gillet, N. Halkic, Isolated agenesis of the gallbladder, *Swiss Surg.* 9 (2003) 315–319.
- [34] P.J. Chopra, S.S. Hussein, Isolated agenesis of the gallbladder, *Saudi Med. J.* 24 (2003) 409–410.

#### Open Access

This article is published Open Access at [sciendo.com](http://sciendo.com). It is distributed under the [IJSCR Supplementary terms and conditions](http://www.ijscr.com/terms-conditions), which permits unrestricted non commercial use, distribution, and reproduction in any medium, provided the original authors and source are credited.