

Craniosynostosis: Esthetic protocol in open technique

Access this article online

Website:

www.amsjournal.com

DOI:

10.4103/2231-0746.110086

Quick Response Code:



Ghali E. Ghali, George Zakhary

Department of Oral and Maxillofacial Surgery, Louisiana State University School of Medicine,
1501 King Highway, Shreveport, LA 71130, USA

Address for correspondence:

Dr. Ghali E. Ghali, Department of Oral and Maxillofacial Surgery,
Louisiana State University School of Medicine,
1501 King Highway, PO Box 33932, Shreveport, LA 71130, USA.

E-mail: gghali@lsuhsc.edu

ABSTRACT

Introduction: The past two decades have seen advances relative to the treatment of patients with craniosynostosis in the areas of resorbable fixation, imaging, and both intraoperative and perioperative management. The purpose of this study is to present open cranial vault reshaping techniques and anesthetic protocol used at Louisiana State University Health - Shreveport, USA. **Materials and Methods:** The surgical procedure of choice was single-stage open cranial vault reshaping with barrel-staving and orbital bandeau advancement as needed for supra-orbital rim deficiencies. **Results:** The outcomes of single-stage cranial vault reshaping with selective postoperative dynamic orthotics yielded symmetrical and consistent clinical results with only three children out of over 100 cases requiring later surgical correction. **Discussion:** Our review of techniques provides a safe protocol for management of craniosynostosis with symmetrical clinical head shape. The techniques presented here are aimed at improving the multidisciplinary management of these patients.

Keywords: Cranial vault, craniosynostosis, plagiocephaly, scaphocephaly

INTRODUCTION

Craniosynostosis, the premature fusion of cranial sutures, can affect one or multiple sutures, occur as an isolated defect or be associated with a craniofacial syndrome.^[1] Non-syndromic craniosynostosis presents more commonly than syndromic craniosynostosis. Single suture craniosynostosis results in head shape deformities with classic presentations, depending on which suture is involved. Sagittal suture fusion results in scaphocephaly, unilateral coronal or lambdoidal result in plagiocephaly, and bilateral coronal or lambdoidal present with a brachiocephaly. Intracranial hypertension,^[2] visual impairment,^[3] limitation of brain growth, and neuropsychiatric disorders^[4-6] have been associated with craniosynostosis, generally with greater functional disturbance in proportion to the number of sutures involved [Figures 1 and 2].^[2,3]

While inherent risks with open cranial vault reshaping exist, the past two decades have enjoyed advances in resorbable fixation, imaging modalities, and perioperative medical management. The purpose of this review is to provide anesthetic and surgical techniques used in open cranial vault reshaping

for craniosynostosis repair at Louisiana State Health Center in Shreveport, LA, USA.

MATERIALS AND METHODS

This retrospective review of techniques was approved by the Institutional Review Board at Louisiana State Health Sciences Center in Shreveport, Louisiana (LSUH-S). Inclusion criteria were patients less than three years of age undergoing primary surgery with cranial vault reshaping.

All cases were performed at LSUH-S by a single craniofacial surgeon (GEG), two pediatric neurological surgeons (BW) (CN), using a single plating company (Lorenz/Biomet), and rotating anesthesiologists and pediatric intensivists assigned to the craniofacial team.

The surgical procedure of choice was single-stage open transcranial vault reshaping with barrel-staving and orbital bandeau advancement as needed for supraorbital rim deficiencies. Biodegradable plates and screws were used exclusively, owing to their lower incidence

of complications in pediatric craniofacial surgery.^[7]

Surgical techniques

Anesthesia

Standard monitoring using electrocardiogram (ECG), a temperature probe, and pulse oximetry were used. Induction

was achieved with sevoflurane. The standard protocol employed included central venous access and an arterial line placed by a pediatric surgeon, hypotensive anesthesia, and packed red blood cell transfusions given at key portions of the case to correspond with anticipated blood loss.^[8,9,10]

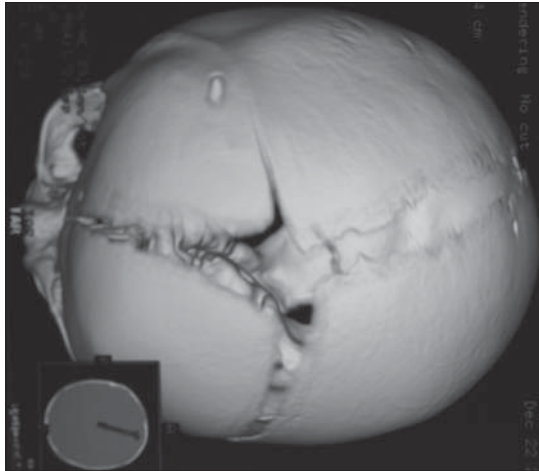


Figure 1: Preoperative computerized tomography scan showing right coronal suture fusion

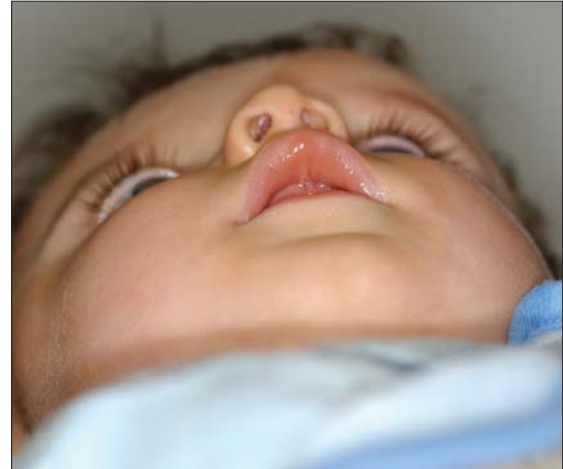

Figure 2: Preoperative view of right anterior plagiocephaly demonstrating left frontal bossing

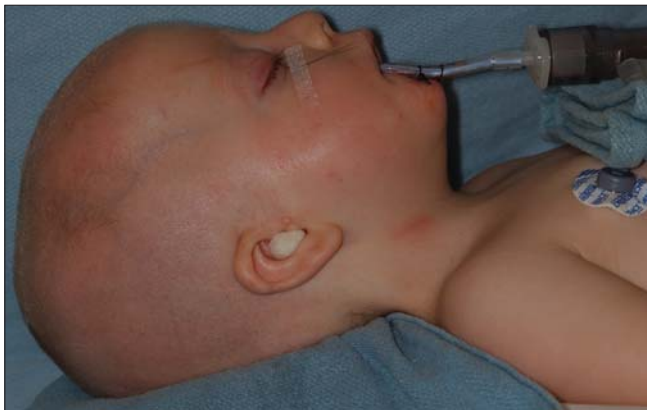

Figure 3: Patient positioned supine in Mayfield headrest with tarsorrhaphy sutures in place

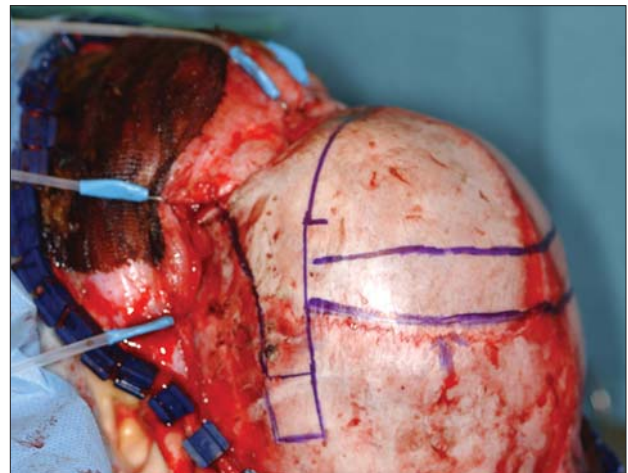
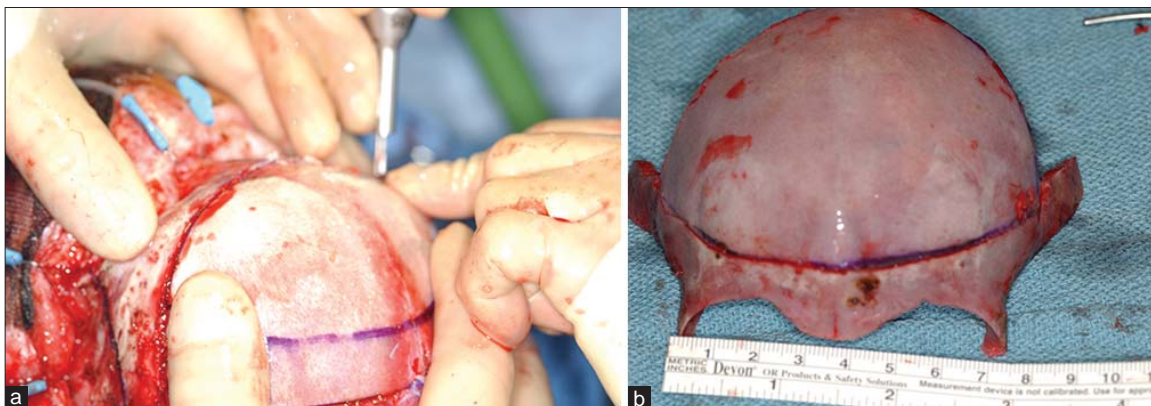


Figure 4: Exposed cranium with proposed osteotomies marked



Figures 5: Osteotomized frontal bone and orbital bandeau

Positioning

Patients undergoing anterior cranial vault reshaping for metopic or coronal suture synostosis were placed supine in the Mayfield headrest [Figure 3]. The endotracheal tube was secured to the chin using 2-0 silk suture. Temporary tarsorrhaphy sutures were placed for protection of the globes. Those undergoing surgery for posterior or total cranial vault reshaping were placed prone with the neck slightly extended to allow access to the entire cranial vault. In prone cases, extra care in the way of foam padding was used to protect the globes.

Procedures

All procedure employed a coronal approach using Raney clips to aid in hemostasis. Dissection was carried out in a sub-periosteal plane to expose the necessary area for reshaping [Figure 4].

Surgical correction of anterior plagiocephaly was performed with unilateral orbital rim advancement and frontal bone reshaping. With complex defects, bilateral advancement was necessary. The osteotomies for the bilateral orbital rim advancement were made superior to the nasofrontal and at the frontozygomatic sutures

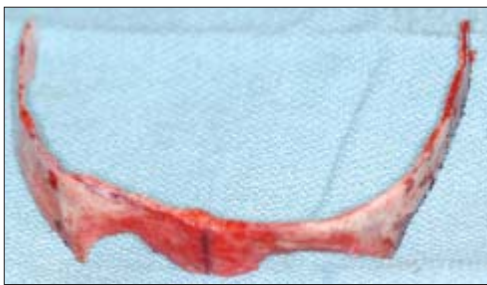

Figure 6: Orbital bandeau with deformation visible when comparing supraorbital rim positions

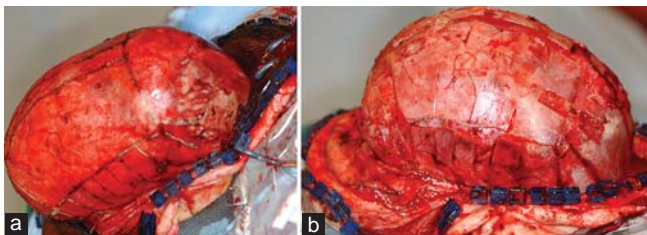


Figure 7: Sagittal suture fusion before osteotomies

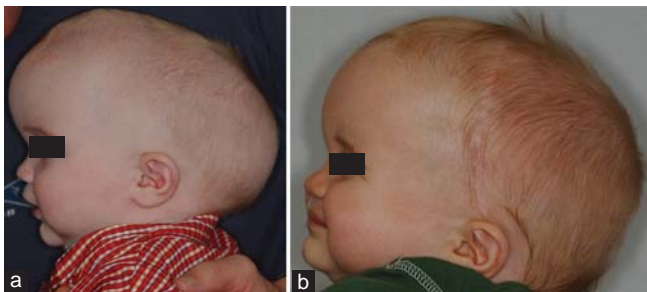


Figure 9: Comparison of the scaphocephalic head shape preoperative and 1 month postoperative, respectively

and extended to the squamous portion of the temporal bone [Figures 5 and 6].

Treatment of scaphocephaly consisted of total cranial vault reshaping, with variations depending on which part of the sagittal suture was fused. When the posterior half was fused, the patient was treated in the prone position with the posterior two thirds of the cranial vault reshaped. When the anterior half was fused, the patient was treated in the supine position with the anterior two thirds of the cranial vault reshaped, with or without superior orbital rim reshaping. When the entire suture was fused, a combination of both approaches was necessary. Complete sagittal suture synostosis (anterior and posterior) was treated at one operative setting in the prone position via total cranial vault reshaping. In older children (older than 1 year) or children with a need for upper orbital reconstruction, the preference was to treat them in the supine position at one operative setting or, rarely, in a staged fashion, with posterior reconstruction preceding anterior and orbital reconstruction by 4 to 6 months [Figure 7].

Cases of bilateral coronal suture synostosis were treated with simultaneous frontal bone and bilateral orbital rim advancement. The single case of posterior brachycephaly was treated with total cranial vault reshaping using bone flaps and barrel-staving cuts.

Correction of trigonocephaly involved metopic suture release, simultaneous bilateral orbital rim advancements, and lateral widening via frontal bone advancement. Orbital hypotelorism was corrected by splitting the supra-orbital unit in the midline and placing autogenous cranial bone grafts to increase the intra-orbital distance [Figure 8].

RESULTS

The outcomes of single-stage cranial vault reshaping with selective postoperative dynamic orthotics yielded symmetrical and consistent clinical results with only three children out of

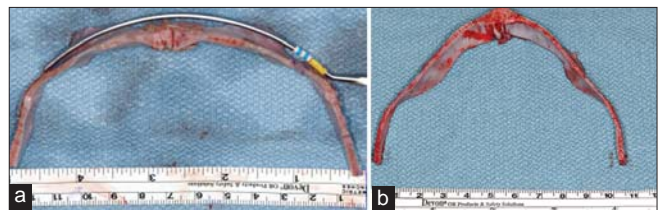


Figure 8: Orbital bandeau before midline osteotomy to facilitate widening at temporal regions and resorbable plate fixation

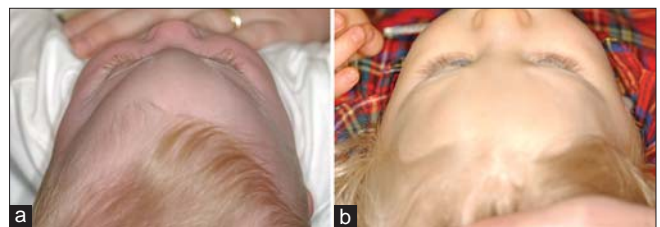


Figure 10: (a) Trigonocephalic head shape preoperative and (b) 3 months postoperative, respectively

over 100 cases requiring later surgical correction. The efficacy of the approach was more than 97% [Figures 9 and 10].

DISCUSSION

While endoscopic approaches, distraction osteogenesis, and spring-assisted procedures have gained favor due to lower estimated blood losses, decreased operative times, and shorter hospital stays; they often require multiple operations for device placement and removal, or rely on compliance with shaping helmets to achieve desired results. The use of the open techniques illustrated here demonstrate symmetrical clinical results in conjunction with a low incidence of reoperation to correct residual deformities.

Obtaining symmetry at the time of surgery is essential, as clinical results did not generally improve over time.^[11,12] With the ability to achieve the desired shape at the time of surgery, open cranial vault reshaping remains the most viable method of repair for significant defects due to predictable results.

REFERENCES

- Slater BJ, Lenton KA, Kwan MD, Gupta DM, Wan DC, Longaker MT. Cranial Sutures: A Brief Review. *Plast Reconstr Surg* 2008;121:170e-8e.
- Bristol RE, Lekovic GP, ReKate HL. The effects of craniosynostosis on the brain with respect to the intracranial pressure. *Semin Pediatr Neurol* 2004;11:262-7.
- Siatkowski RM, Fortney AC, Nazir SA, Cannon SL, Panchal J, Francel P, *et al.* Visual field defects in deformational posterior plagiocephaly. *J AAPOS* 2005;9:274-8.
- Magge SN, Westerveld M, Pruzinsky T, Persing JA. Long-term neuropsychological effects of sagittal craniosynostosis on child development. *J Cranio Fac Surg* 2002;13:99-104.
- Panchal J, Amirshaybani H, Gurwitch R, Cook V, Francel P, Neas B, *et al.* Neurodevelopment in children with single-suture craniosynostosis and plagiocephaly without synostosis. *Plast Reconstr Surg* 2001;108:1492-8.
- Kordestani RK, Patel S, Bard DE, Gurwitch R, Panchal J. Neurodevelopmental delays in children with deformational plagiocephaly. *Plast Reconstr Surg* 2006;117:207-18.
- Eppley BL, Morales L, Wood R, Pensler J, Goldstein J, Havlik RJ, *et al.* Resorbable PLLA-PGA Plate and Screw Fixation in Pediatric Craniofacial Surgery: Clinical Experience in 1883 Patients. *Plast Reconstr Surg* 2004;114:850-6.
- Sinn DP, Ghali GE, Ortega M, Bryd HS, Sklar FH. Major Craniofacial Surgery. In: Levin DL, Moriss FC, editors. *Essentials of Pediatric Intensive Care*, 2nd ed. vol 68. New York: Churchill Livingstone; 1997. p. 636-43.
- Hilley MD, Ghali GE, Giesecke AH. Anesthesia for Orthognathic and Craniofacial Surgery. In: Bell W, editor. *Modern Practice in Orthognathic and Reconstructive Surgery*. vol 6. Philadelphia: WB Saunders C; 1992. p. 129-54.
- Ghali GE, Sinn D, Tantipasawasin S. Management of Nonsyndromic Craniosynostosis. *Atlas Oral Maxillofacial Surg Clin N Am* 2002;10:1-41.
- Esparza J, Hinojosa J. Complications in the surgical treatment of craniosynostosis and craniofacial syndromes: Apropos of 306 transcranial procedures. *Childs Nerv Syst* 2008;24:1421-30.
- Seruya M, Oh AK, Boyajian MJ, Posnick JC, Myseros JS, Yaun AL, *et al.* Long-Term Outcomes of Primary Craniofacial Reconstruction for craniosynostosis: A 12-Year Experience. *Plast Reconstr Surg* 2011;127:2397-406.

Cite this article as: Ghali GE, Zakhary G. Craniosynostosis: Esthetic protocol in open technique. *Ann Maxillofac Surg* 2013;3:62-5.

Source of Support: Department of Oral and Maxillofacial Surgery LSU Health Shreveport LA USA, **Conflict of Interest:** No.