

Received: 2017.10.08
Accepted: 2018.02.02
Published: 2018.05.07

e-ISSN 1941-5923
© Am J Case Rep, 2018; 19: 534-539
DOI: 10.12659/AJCR.907444

Primary Papillary Serous Carcinoma of the Fallopian Tube Presenting as a Vaginal Mass: A Case Report and Review of the Literature

Authors' Contribution:
Study Design A
Data Collection B
Statistical Analysis C
Data Interpretation D
Manuscript Preparation E
Literature Search F
Funds Collection G

BE 1 **Einav Kadour-Peero**
AE 2 **Lena Sagi-Dain**
B 1 **Gil Cohen**
D 1 **Roman Korobochka**
B 3 **Abed Agbarya**
E 4 **Jacob Bejar**
ABDE 1 **Shlomi Sagi**

1 Department of Obstetrics and Gynecology, Bnai-Zion Medical Center, Faculty of Medicine, Technion-Israel Institute of Technology, Haifa, Israel
2 Department of Obstetrics and Gynecology, Carmel Medical Center, Haifa, Israel
3 Department of Oncology, Bnai-Zion Medical Center, Haifa, Israel
4 Department of Pathology, Bnai-Zion Medical Center, Faculty of Medicine, Technion-Israel Institute of Technology, Haifa, Israel

Corresponding Author: Einav Kadour, e-mail: einavkadour@gmail.com
Conflict of interest: None declared

Patient: Female, 41
Final Diagnosis: Serous papillary carcinoma
Symptoms: Vaginal discharge • weakness
Medication: —
Clinical Procedure: Total abdominal hysterectomy
Specialty: Obstetrics and Gynecology

Objective: Unusual clinical course

Background: There is now evidence to support that some cases of high-grade serous papillary carcinoma arise from the fallopian tubes rather than the ovaries. Common symptoms at presentation include abdominal pain and swelling, vomiting, altered bowel habit and urinary symptoms. To our knowledge, this is the first case of serous papillary carcinoma presenting as a vaginal mass lesion.

Case Report: A 41-year-old woman was referred to the Bnai-Zion Medical Center with the main complaint of irregular vaginal bleeding, vaginal mucous discharge, and suspected pelvic mass. Physical examination showed a soft, painless mass, measuring about 10 cm in diameter located mainly in the recto-vaginal septum, but not involving the uterus. Ultrasound examination showed no abnormal ovarian or uterine findings. Transvaginal biopsies of the mass showed a poorly differentiated serous papillary carcinoma of ovarian, tubal, or peritoneal origin. The physical examination and imaging findings strongly indicated an inoperable tumor, and the patient was treated with neoadjuvant (pre-surgical) chemotherapy. Pre-operative computed tomography (CT) imaging showed the partial involvement of the colon, and so surgical treatment included total abdominal hysterectomy, bilateral salpingo-oophorectomy, omentectomy, partial vaginectomy, anterior rectal resection, and lymph node dissection. Histopathology of the surgical specimens showed a poorly differentiated serous carcinoma originating from the fimbria of the right fallopian tube.

Conclusions: To the best of our knowledge, this is the first report to describe primary fallopian tube papillary serous carcinoma presenting as a vaginal mass. Therefore, physicians should be aware of this possible diagnosis.

MeSH Keywords: Adenocarcinoma, Papillary • Ovarian Neoplasms • Vaginal Neoplasms

Full-text PDF: <https://www.amjcaserep.com/abstract/index/idArt/907444>



1716



—



6



9



Background

The lifetime risk for ovarian epithelial cancer in the female population is 1.7%, and this malignancy has the highest mortality to incidence ratio of all gynecological cancers [1]. Ovarian carcinoma remains cancer with the highest mortality rate among gynecologic malignancies, and ovarian serous papillary carcinoma represents the most common histologic type of ovarian carcinoma. Because of the insidious onset of the disease and the lack of reliable screening tests, two-thirds of patients have advanced disease when diagnosed [1].

Recent evidence has begun to accumulate that indicates that many cases of high-grade serous papillary carcinoma arise from the fallopian tubes rather than the ovaries [2–4]. However, at clinical presentation, the malignancy usually involves both the ovaries and the fallopian tubes, and also the peritoneum and omentum. The vagueness of the presenting symptoms, which may be interpreted by patients as being due to the effects of childbearing, the menopause, or aging, and the late stage at presentation results in high mortality from ovarian and fallopian tubal serous papillary carcinoma [5]. Common symptoms at presentation include abdominal pain and swelling, dyspepsia, vomiting, urinary symptoms and abnormal vaginal bleeding [6,7]. Some of these nonspecific complaints have been shown to have a predictive value for lower survival rate [5]. However, less common symptoms of presentation of serous papillary carcinoma can further aggravate the delay in diagnosis, and thus adversely affect patient survival.

We describe an unusual case of a recto-vaginal mass as a presenting symptom of serous papillary carcinoma arising from the fallopian tube.

Case Report

A 41-year-old woman was referred to Ultrasound Unit of the Gynecology Department, at the Bnai-Zion Medical Center, complaining of irregular vaginal bleeding, vaginal aqueous mucous discharge, and a suspected pelvic mass. She had no gastrointestinal or urinary symptoms and no previous history of medical or surgical disease. The patient had four uncomplicated pregnancies and one spontaneous abortion. She reported that her sister died at the age of 45 years due to urinary tract malignancy.

Physical examination showed a large immobile mass, completely blocking the vaginal outlet and preventing satisfactory characterization of the lesion location and spread. Ultrasound examination performed in our department (Figure 1) demonstrated an irregular solid mass with cystic areas, measuring 8×9.5cm in diameter, with an abundant vascular flow. The lesion was also located behind the posterior vaginal wall in the rectovaginal space area, adjacent to the right vaginal wall, the rectum, and the cervix. No abnormal adnexal or uterine findings were noted. There was no evidence of ascites or abdominal lymph node enlargement. These initial findings resulted in a provisional diagnosis of a primary vaginal tumor.

An examination under general anesthesia was performed, which showed a soft, painless mass about 10 cm in diameter located mainly in the recto-vaginal septum, not involving the uterus. In contrast to the usual spread of vaginal squamous cell carcinoma, the mass did not involve the vaginal mucosa but rather was entirely submucosal, except for a small breach about 1cm in diameter through which multiple biopsies were taken. Per-rectum examination demonstrated no colonic mucosal involvement. The patient's serum cancer antigen 125 (Ca-125) level was 135.4 U/mL (normal range, 0–35 U/mL).

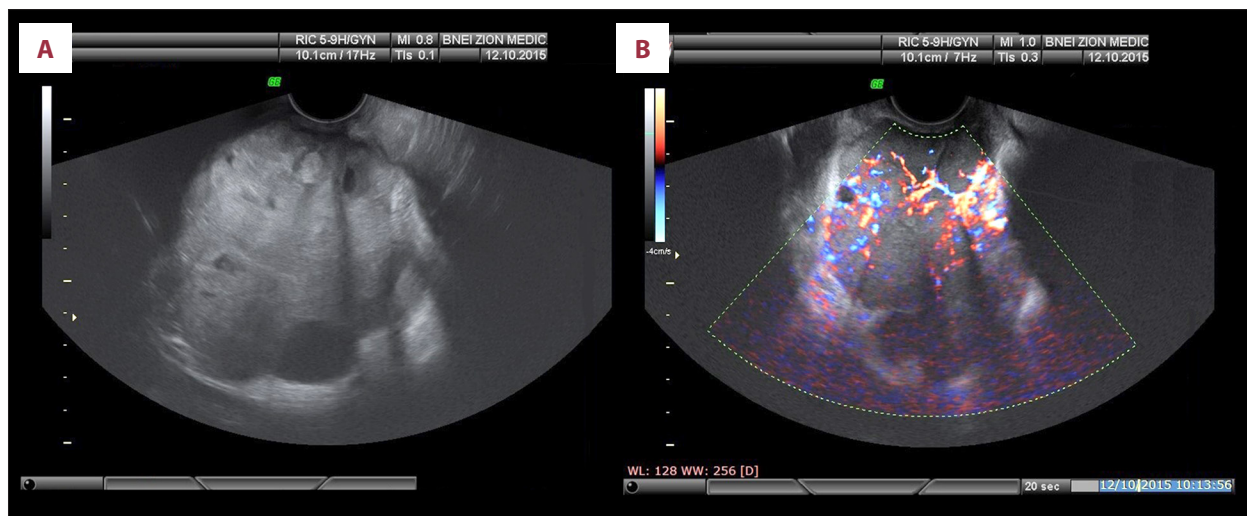


Figure 1. Pelvic ultrasound imaging. (A) The image shows an irregular solid mass with some cystic areas, measuring 8×9.5cm. (B) The same solid mass, imaged with color Doppler, demonstrates an abundant vascular blood flow.

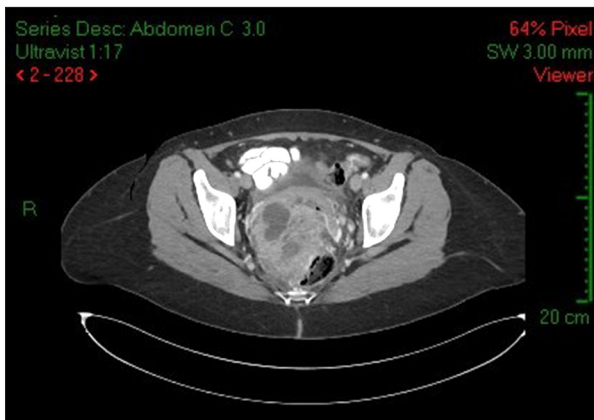

Figure 2. Computed tomography (CT) imaging in the transverse plane. Abdominal and pelvic computed tomography (CT) shows a non-homogenous mass in the recto-uterine pouch, measuring 72×84×103 cm, resulting in anterior pressure on the vagina and posterior pressure on the rectum, but with no signs of obstruction.

Abdominal and pelvic computed tomography (CT) showed a non-homogenous mass in the recto-uterine pouch, measuring 72×84×103 cm, exerting anterior pressure on the vagina and posterior pressure on the rectum, but with no signs of obstruction (Figure 2). No evidence of further spread was noted. No clear indication of the origin of the mass lesion was possible at that time.

Histologic analysis of the transvaginal biopsies showed a poorly differentiated carcinoma with very high proliferative index, a solid growth pattern, and some glandular differentiation. On immunohistochemical analysis, the tumor cells stained positively for cytokeratin 7,8 and Wilm's tumor protein (WT1), and were weakly positive for estrogen receptor (ER) and progesterone receptor (PR), and were negative for carcinoembryonic antigen (CEA) and p53. Also, P16 was strongly and diffusely positive, while vimentin, S100, chromogranin, and synaptophysin, cytokeratin 20, and the homeobox protein CDX-2 were negative. Given these findings, a diagnosis of a poorly differentiated serous papillary carcinoma of ovarian, tubal, or peritoneal origin was made, rather than a primary vaginal tumor. A consultation by an expert in gynecologic pathology reached the same conclusion. Therefore, from the pathology results in addition to lack of mucosal involvement led to the conclusion that this tumor was either a metastasis from, or a direct invasive extension from, a primary serous papillary carcinoma of adnexal or peritoneal origin.

Because the physical findings and the imaging findings supported a diagnosis of an inoperable tumor, the patient was initially treated with neoadjuvant chemotherapy. The patient received four courses of 75 mg cisplatin and 175 mg paclitaxel. Her Ca-125 serum level after neoadjuvant chemotherapy

decreased to 32.6 U/mL. Abdominal and pelvic CT imaging following completion of chemotherapy showed a reduction in the size of the tumor to a diameter of 6 cm, with no evidence of further spread (Figure 3). However, at this stage, the tumor appeared to encircle the rectum and invade the right psoas muscle. According to Gastroenterologist consulting in our institution, colonoscopy was not recommended in order to avoid perforation. Cystoscopy ruled out mucosal bladder involvement. Due to an apparent progression of tumor invasion, abdominal magnetic resonance imaging (MRI) was performed for more extensive pre-operative characterization of the lesion. This examination showed a 5 cm vaginal mass, involving the colon and the right psoas muscle, with no involvement of the urinary bladder or pelvic muscles.

At this stage, a diagnosis of a primary gynecologic tumor with secondary extension to the vaginal and colonic wall was made, and the patient was prepared for total abdominal hysterectomy, bilateral salpingo-oophorectomy, omentectomy, partial vaginectomy, anterior resection of the colon, and lymph node dissection. During surgery, tumor tissue measuring about 3 cm in diameter, merging with the intestinal wall on one side and with the vagina from the other side was present. Due to the absence of enlarged lymph nodes during surgery, lymph node dissection was not performed, but adjuvant chemotherapy was planned to follow surgery.

The macroscopic and histopathological assessment of the surgically resected specimen showed a poorly differentiated papillary serous carcinoma, showing enlarged cell nuclei with prominent nucleoli and abundant mitoses. Architecturally the tumor showed a solid and pseudo-glandular growth pattern, with no papillary structures. Immunohistochemistry showed positive immunostaining for P16, WT1, CK7, CK8, PAX8. CDX2 (a colonic marker), Synaptophysin and chromogranin (neuroendocrine markers), TTF1, Napsin A (a lung marker) were negative. Immunostaining for ER and PR were weakly and focally positive. p53 was completely negative. Based on the histomorphology and the immunohistochemical profile of the tumor, pathological assessment concluded that the specimen was a poorly differentiated (high-grade) papillary serous carcinoma with 25% necrosis and hyalinosis (Figure 4).

On examination of the fimbria of the right fallopian tube, small foci of intraepithelial and invasive high-grade serous carcinoma were found, showing the same immunoprofile as the main tumor (Figure 5). Although this tumor penetrated the intestinal and vaginal wall, there was no evidence of invasion into the colonic or vaginal mucosa (Figure 6A, 6B). The specimen resection margins were found to be free from tumor. Metastases were found in two out of six lymph nodes, resulting in the tumor staging of T1aN1M1.

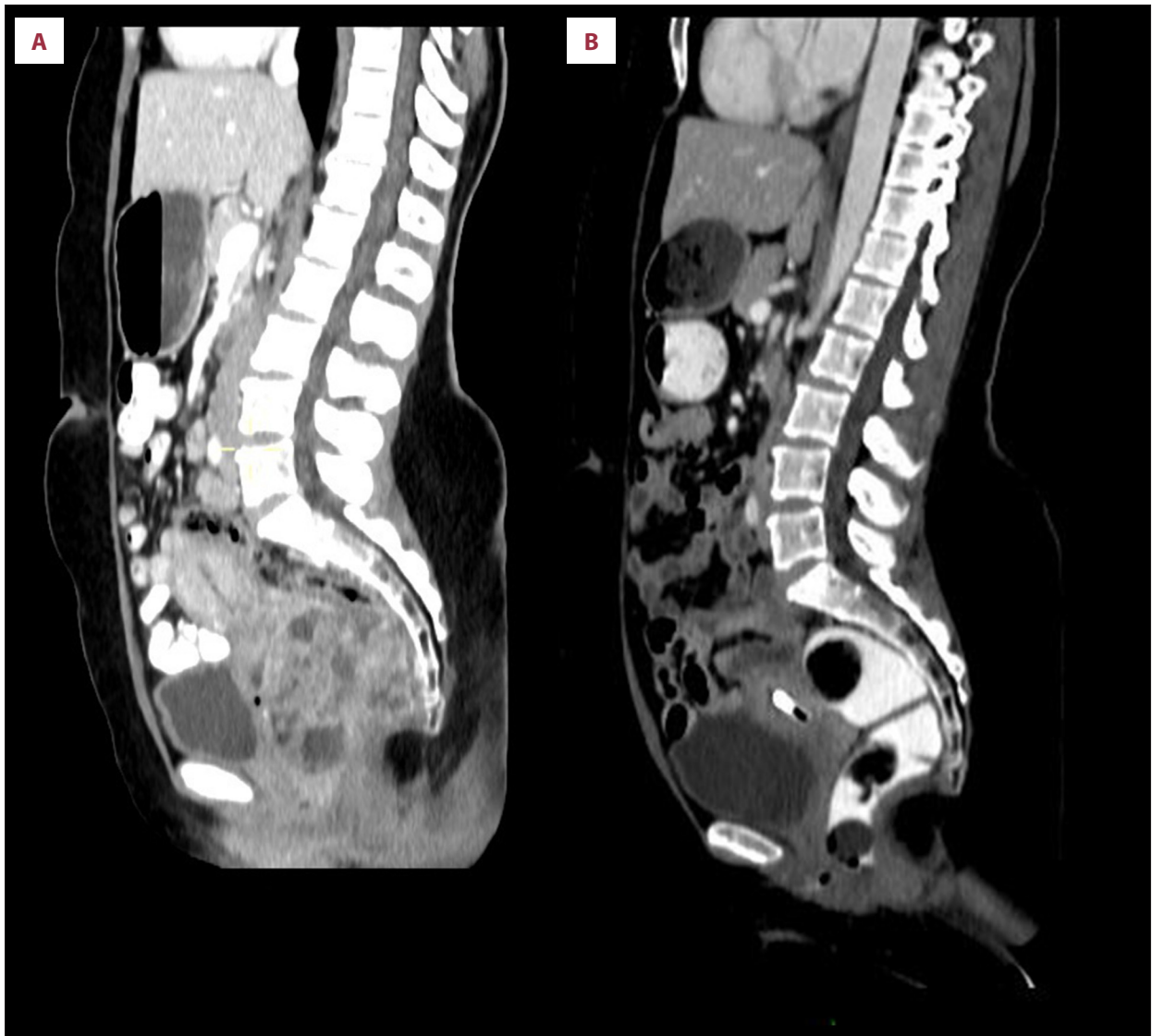


Figure 3. Computed tomography (CT) imaging in the sagittal plane. (A) (left) Computed tomography (CT) imaging before neo-adjuvant therapy. (B) (right). Computed tomography (CT) imaging in the sagittal plane following neo-adjuvant therapy.

Discussion

This report has described a rare case of serous papillary tubal carcinoma stage IIIc, presenting primarily with a vaginal mass causing atypical symptoms of irregular vaginal bleeding and vaginal discharge in a 41-year-old woman.

Because vaginal involvement in advanced serous papillary carcinoma is rare, but when it does occur, it usually occurs late in the course of the disease, symptoms related to such spread are typically preceded by more common complaints [8]. Thus, serous papillary carcinoma presenting primarily as a vaginal lesion has rarely been previously noted in the literature and has mainly been described in association with the spread of ovarian carcinoma. For example, Bergman et al. reported vaginal

involvement in 12% of cases in an autopsy series of 86 patients with advanced ovarian malignancy [9]. Lifshitz et al. described five cases of ovarian carcinoma presenting as a vaginal lesion [8]. Similar to the patient described in this case report, vaginal bleeding and spotting were noted by all five women and were the presenting symptoms, while in one patient vaginal bleeding was accompanied by low back pain [8,9]. Only one patient had no other pathologic findings on pelvic examination, while two patients had nodular masses in the vaginal fornix [8,9]. In these previous reports, the maximum diameter of the masses was up to 4 cm [8,9]. However, our patient had a mass of a 10 cm diameter, located mainly in the rectovaginal septum. Similarly to the patient described in this case report, in none of the previously reported cases was ovarian carcinoma suspected until the biopsy report was performed,

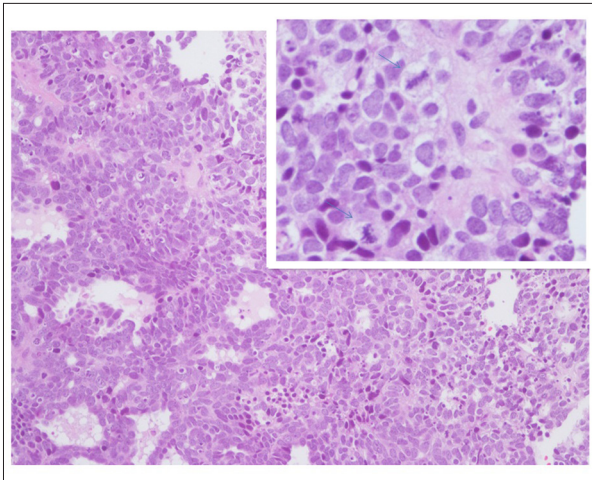


Figure 4. Photomicrographic appearance of the histopathology of a high-grade (poorly differentiated) serous carcinoma. Poorly differentiated serous carcinoma, with a solid pattern of growth and irregular empty pseudoglandular spaces. The tumor cells are cuboidal, with high-grade atypia and numerous mitotic figures (see inset), with cellular pleomorphism. Hematoxylin and eosin (H&E).

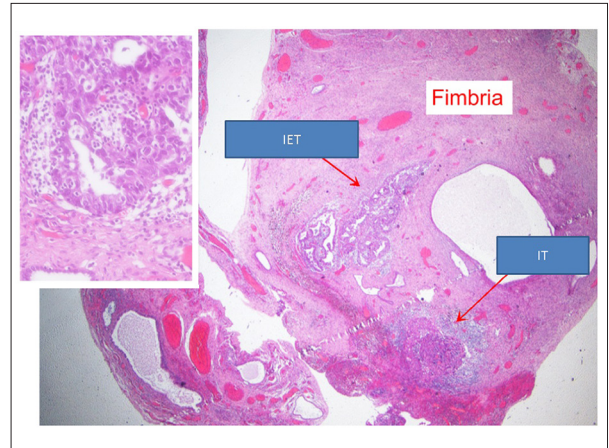
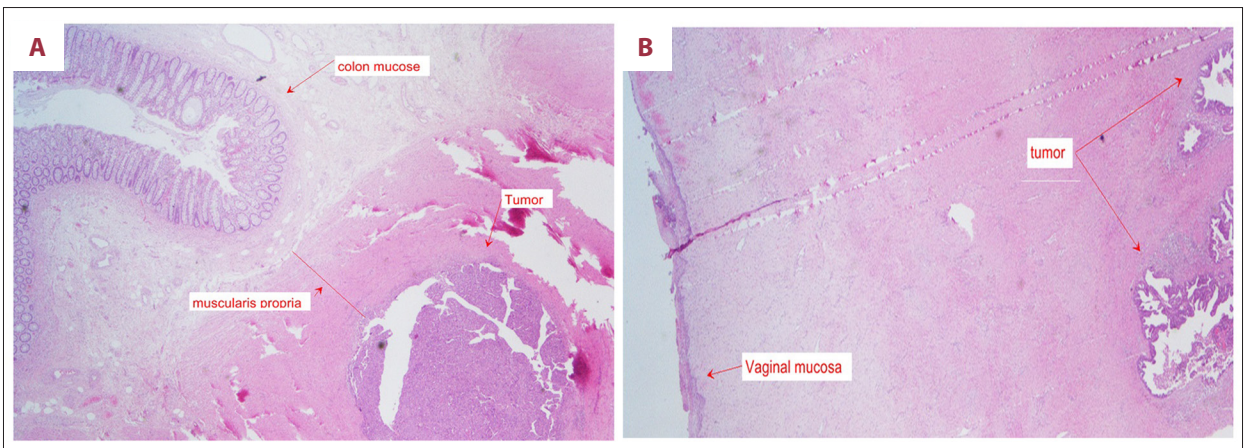


Figure 5. Photomicrographic appearance of the histopathology of a high-grade (poorly differentiated) serous carcinoma. Low-power image of the fallopian tube, with a high-power image (inset). Small foci of invasive serous carcinoma are present in the fallopian tube. In the right fallopian tube fimbria, small foci of intraepithelial and invasive high-grade serous carcinoma are seen, showing the same immunohistochemical profile as the primary tumor. Intraepithelial tumor, IET – invasive tumor; IT – fimbria; F – hematoxylin and eosin (H&E).



Figures 6. (A, B) Photomicrographic appearance of the histopathology of the tumor invasion into the colonic and vaginal wall. Low-power images of the tumor penetrating the intestinal and vaginal wall, but not breaching the colonic mucosa. Hematoxylin and eosin (H&E).

and in all cases described, the histology of the primary ovarian tumor was that of a vaginal metastasis [8,9].

The patient described in this report, with vaginal involvement, is the only case in which no macroscopic or microscopic disease was seen in either ovary. The only microscopic solitary focus to explain the origin of the tumor was seen in the right fallopian tube, representing the primary tumor origin. To the best of our knowledge, this is the first report describing a fallopian tubal carcinoma presenting as a vaginal mass.

This case report highlights the fact that some high-grade serous carcinomas of tubal or ovarian origin may be clinically deceptive and can present as a vaginal mass. Spread of serous papillary carcinoma to the vagina can occur by one of several routes, by direct extension from a prior peritoneal site, by topical dissemination, and less commonly, by retrograde lymphatic or hematogenous spread. In our case, according to the pathology findings, there were no signs of direct extension from the peritoneum. Due to lymph node metastasis, it is likely that lymphatic dissemination had occurred.

Conclusions

Fallopian tube or ovarian carcinoma presenting as a vaginal mass is an unusual finding, which may cause the clinician considerable concern and lead to delay in diagnosis and treatment, potentially affecting the survival of the patient. Despite its rareness, vaginal mass can be one of the presenting signs of tubal and ovarian carcinoma, and physicians should be aware of this possible diagnosis at an early stage.

References:

1. Jemal A, Siegel R, Xu J, Ward E: Cancer statistics, 2010. *Cancer J Clin*, 2010; 60(5): 277–300
2. Medeiros F, Muto MG, Lee Y et al: The tubal fimbria is a preferred site for early adenocarcinoma in women with familial ovarian cancer syndrome. *Am J Surg Pathol*, 2006; 30(2): 230–36
3. Crum CP, Drapkin R, Kindelberger D et al: Lessons from BRCA: The tubal fimbria emerges as an origin for pelvic serous cancer. *Clin Med Res*, 2007; 5(1): 35–44
4. Kurman RJ, Shih le M: Molecular pathogenesis and extraovarian origin of epithelial ovarian cancer – shifting the paradigm. *Human Pathol*, 2011; 42(7): 918–31
5. Goff BA, Mandel LS, Melancon CH, Muntz HG: Frequency of symptoms of ovarian cancer in women presenting to primary care clinics. *JAMA*, 2004; 291(22): 2705–12
6. Wikborn C, Pettersson F, Silfversward C, Moberg PJ: Symptoms and diagnostic difficulties in ovarian epithelial cancer. *Int J Gynecol Obstet*, 1993; 42(3): 261–64
7. Wikborn C, Pettersson F, Moberg PJ: Delay in diagnosis of epithelial ovarian cancer. *Int J Gynecol Obstet*, 1996; 52(3): 263–67
8. Lifshitz S, Newland WH, Dolan TE, Buchsbaum HJ: Ovarian carcinoma presenting as a vaginal lesion. *JAMA*, 1978; 239(17): 1788–89
9. Bergman F: Carcinoma of the ovary. A clinicopathological study of 86 autopsied cases with special reference to mode of spread. *Acta Obstet Gynecol Scand*, 1966; 45(2): 211–31

Conflict of interest

None.