

Management of parotid fistula and Frey's syndrome with Botulinum neurotoxin type A

ABSTRACT

The common cause of parotid fistula is parotid gland surgery and is frequently due to injury to the gland rather than to the duct. The frequency of postparotidectomy fistula is 14%. Other causes include facial trauma, congenital anomalies of the parotid gland, malignancies originating from the parotid gland and infections. Although there are several options for the treatment of parotid fistula and Frey's syndrome, very few treatment options are deemed optimal. The use of Botulinum A neurotoxin as a conservative method of treatment for parotid fistula and Frey's syndrome is a recent and evolving concept.

Keywords: Botulinum A neurotoxin, Frey's syndrome, parotid fistula

INTRODUCTION

A parotid fistula is a rare complication and difficult to treat. Parotid fistula is an epithelialized tract between the parotid gland or its duct and the skin, which is manifested by salivary discharge from a wound site. The common cause of parotid fistula is parotid gland surgery and is frequently due to injury to the gland rather than to the duct, and the frequency of postparotidectomy fistula is 14%.^[1] Other causes are facial trauma, congenital anomalies of the parotid gland, malignancies originating from the parotid gland and infections.^[2]

Frey's syndrome, also called gustatory sweating, which was first described by Lucie Frey in 1923,^[3] is a complication of parotid surgery and the occurrence rate varies from 4% to 62%.^[4-7] Frey's syndrome is characterized by sweating, flushing, burning, itching, or neuralgic pain in the preauricular region in response to mastication and salivation. The pathophysiological mechanism is due to an aberrant reinnervation of the postganglionic parasympathetic nerve fibers to the denervated sweat glands and cutaneous blood vessels. Consequently, when acetylcholine is liberated from the parasympathetic nerve endings in response to mastication and salivation, it induces sweating and flushing which was initially a sympathetic response.^[8]

Currently, there are several options for the treatment of parotid fistula and Frey's syndrome, but there are very few optimum treatment options. The use of Botulinum A neurotoxin (BTA) as a conservative method of treatment for parotid fistula and Frey's syndrome^[9,10] is a recent and evolving concept. In this article, we report a case of simultaneous parotid fistula and Frey's syndrome, which developed after superficial parotidectomy and was successfully treated with BTA injection.

CASE REPORT

A 32-year-old male patient presented with the complaints of watery discharge from a wound over the left parotid

RIPON CHOWDHURY, DEV ROY¹, ABHIMANYU ROY¹


Department of Oral and Maxillofacial Pathology, Hi-Tech Dental College and Hospital, Bhubaneswar, Odisha,

¹Department of ENT, Rabindranath Tagore International Institute of Cardiac Sciences, Kolkata, West Bengal, India

Address for correspondence: Dr. Ripon Chowdhury, Department of Oral and Maxillofacial Pathology, Hi-Tech Dental College and Hospital, High Tech Hospital Road, Pandara, Rasulgarh, Bhubaneswar - 751 025, Odisha, India.
E-mail: riponc@yahoo.com

Received: 03 May 2020, **Revised:** 15 May 2020,

Accepted: 09 July 2020, **Published:** 16 March 2021

Access this article online	
Website: www.njms.in	Quick Response Code 
DOI: 10.4103/njms.NJMS_72_20	

This is an open access journal, and articles are distributed under the terms of the Creative Commons Attribution-NonCommercial-ShareAlike 4.0 License, which allows others to remix, tweak, and build upon the work non-commercially, as long as appropriate credit is given and the new creations are licensed under the identical terms.

For reprints contact: WKHLRPMedknow_reprints@wolterskluwer.com

How to cite this article: Chowdhury R, Roy D, Roy A. Management of parotid fistula and Frey's syndrome with Botulinum neurotoxin type A. *Natl J Maxillofac Surg* 2021;12:106-8.

region for the past 8 months. The fistula had started 2 weeks after he had undergone superficial parotidectomy for pleomorphic adenoma. The patient was diagnosed as a case of postparotidectomy parotid fistula and initially treated conservatively with regular pressure dressing, anticholinergics, and antibiotics, but symptoms were not relieved. Subsequently, the patient had also developed features of Frey's syndrome 7 months after the surgery.

The patient was diagnosed with simultaneous parotid fistula and Frey's syndrome [Figure 1]. Forty units of BTA was injected subcutaneously in the parotid region. There were no complications such as facial nerve injury and facial artery or masseter muscle trauma. The parotid fistula got resolved within 4 days with complete closure of the fistulous opening and gustatory sweating (Frey's syndrome) ceased after 6 days [Figure 2]. There was no recurrence later, after a follow-up period of 1 year.

DISCUSSION

The treatment options for parotid fistula can be listed as surgical and conservative. Surgeries such as duct ligation, sectioning of the auriculotemporal (Jacobsen's nerve), delayed primary repair of duct, reconstruction of the duct with a vein graft or mucosal flaps, excision of fistulous tract, and total parotidectomy have been mentioned in literature. Conservative treatment options including anticholinergic therapy, radiotherapy, stopping oral intake, and insertion of drains have been reported.^[1] Currently, there is no established treatment option for parotid fistula. Although the use of BTA as a subcutaneous injection is a novel technique, very little data have been mentioned in literature.

Frey's syndrome can be corrected surgically by using temporalis fascia, sternocleidomastoid flap, superficial

musculoaponeurotic system flap, and biomaterial or autologous implants as interpositioning grafts. Over the past few years, the medical treatment of Frey's syndrome has been done with topical antiperspirant and injection with alcohol, scopolamine, and glycopyrrolate. However, presently, BTA is the most widely used substance for the treatment of Frey's syndrome, and BTA treatment is comparatively well established as it has shown to improve gustatory symptoms drastically, thereby improving the quality of life.^[8]

BTA is a potent neurotoxin produced by a Gram-positive anaerobic bacteria *Clostridium botulinum* and was first described in 1895.^[9] The mechanism by which BTA acts on the peripheral cholinergic nerve endings is by its inhibitory action on the calcium-mediated release of acetylcholine vesicles at the presynaptic neuromuscular junction.^[10,11] There are seven serotypes of Botulinum neurotoxin designated A through G, each with its own immunogenic specificity. BTA is the most potent of all and a widely used serotype, which is commercially available for medical use and is FDA approved. In 1978, Botulinum toxin (BTX) was used to treat strabismus.^[12] Since then, there have been several indications of BTA for a wide spectrum of medical conditions.

The treatment of parotid fistula by BTA was first reported in 2001.^[13] As the secretomotor nerve fibers of the salivary gland are mostly cholinergic, autonomic, and parasympathetic, when BTA gets transported to the nervous tissue, it blocks the neurotransmitter release at the cholinergic nerve endings and thus decrease salivary production and as a result, the fistula tract closes.

BTX injections are usually effective in several patients with Frey's syndrome.^[14] Mainly, BTX-A is used for salivary gland

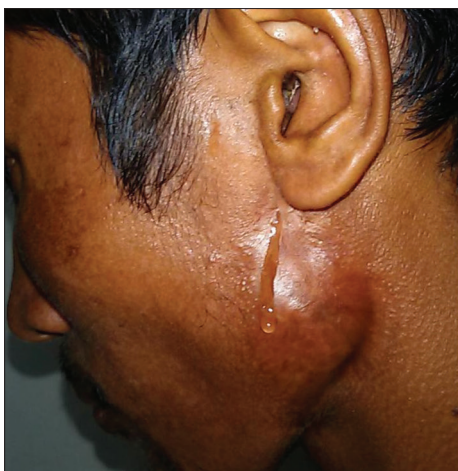

Figure 1: Parotid fistula and Frey's syndrome

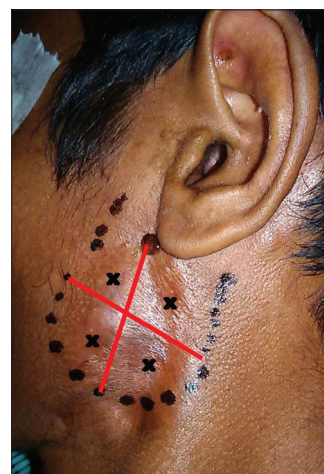

Figure 2: The parotid region is divided into four quadrants. The injection points are at 1 cm from each other

disorders^[15-17] and gustatory sweating, although the use of BTX-B^[18] and BTX-F^[19] has been described in salivary gland diseases. To treat sialoceles and salivary fistulae, the dose of BTX-A injected in the parotid gland, varied in several studies, ranging from 10 to 60 mouse units.^[20]

Laskawi *et al.* reported a total dose of BTX-A between 10 and 40 U, depending on the size of the remaining glandular compartment for postparotidectomy fistulae.^[16]

The technique of BTA injection can be done as an outpatient procedure under topical anesthesia. BTA 100 units is diluted with 2.5 ml of normal saline. Hence, each 0.1 ml is equal to 4 units. The parotid region is divided into four quadrants (anterior, posterior, upper, and lower). For parotid fistula and Frey's syndrome, the injection is done with 1cc BD syringe and 26G needle in the subcutaneous plane in the affected region. A total of 40 units of BTA is injected in the subcutaneous plane of the parotid region.^[20] The remnant 60 units of BTA can be stored in refrigerator for 7 days. If there are residual symptoms of gustatory sweating or fistula, BTA injection can be repeated within 7 days.

The complications of BTA injection are abscess formation at the injection site, nausea, vomiting, dry mouth, respiratory muscle weakness and headache. The lethal dose in humans is around 3000 U. The therapeutic dose ranges from 25 to 300 U. The peak neuromuscular blockade effect of the toxin occurs within 24–72 h after exposure and persists for 4–6 months. The secretomotor fibers of glands are blocked for 10–12 months.

The treatment of parotid fistula or Frey's syndrome is very difficult and frustrating and at present, most of the treatment options presently available are suboptimal and ineffective. BTA injection is very safe and appears to be a very effective technique for patients suffering from parotid fistula and Frey's syndrome.

Declaration of patient consent

The authors certify that they have obtained all appropriate patient consent forms. In the form the patient(s) has/have given his/her/their consent for his/her/their images and other clinical information to be reported in the journal. The patients understand that their names and initials will not be published and due efforts will be made to conceal their identity, but anonymity cannot be guaranteed.

Financial support and sponsorship

Nil.

Conflicts of interest

There are no conflicts of interest.

REFERENCES

1. Rao JK, Gehlot N, Laxmy V, Siwach V. Management of parotid fistula using hypertonic saline. *Natl J Maxillofac Surg* 2011;2:177-80.
2. Managutti A, Tiwari S, Prakasam M, Puthanakar N. Fistulectomy of the parotid fistula secondary to suppurative parotitis: A case report. *J Int Oral Health* 2015;7:59-62.
3. Frey L. Le syndrome du nerf auriculo-temporal. *Rev Neurol* 1923;2:92-104.
4. Freedberg AS, Shaw RS, McManus MJ. The auriculotemporal syndrome. A clinical and pharmacologic study. *J Clin Invest* 1948;27:669-76.
5. Drummond PD. Mechanisms of gustatory flushing in Frey's syndrome. *Clin Auton Res* 2002;12:144-6.
6. Rustemeyer J, Eufinger H, Bremerich A. The incidence of Frey's syndrome. *J Craniomaxillofac Surg* 2008;36:34-7.
7. Neumann A, Rosenberger D, Vorsprach O, Dazert S. The incidence of Frey syndrome following parotidectomy: Results of a survey and follow-up. *HNO* 2011;59:173-8.
8. Motz KM, Kim YJ. Auriculotemporal Syndrome (Frey Syndrome). *Otolaryngol Clin North Am* 2016;49:501-9.
9. Madhok S, Singh G, Gupta A. Botulinum Toxin: Dentistry Insight. *British J Med Res* 2016;12:1-13.
10. Nigam PK, Nigam A. Botulinum toxin. *Indian J Dermatol* 2010;55:8-14.
11. Hirai Y. *Clostridium botulinum* and botulinum neurotoxin. *Brain Nerve* 2011;63:755-61.
12. Scott AB. Botulinum toxin injection of eye muscles to correct strabismus. *Trans Am Ophthalmol Soc* 1981;79:734-70.
13. Marchese-Ragona R, de Filippis C, Staffieri A, Restivo DA, Restino DA. Parotid gland fistula: Treatment with botulinum toxin. *Plast Reconstr Surg* 2001;107:886-7.
14. Xie S, Wang K, Xu T, Guo XS, Shan XF, Cai ZG. Efficacy and safety of botulinum toxin type A for treatment of Frey's syndrome: Evidence from 22 published articles. *Cancer Med* 2015;4:1639-50.
15. Capaccio P, Torretta S, Osio M, Minorati D, Ottaviani F, Sambataro G, *et al.* Botulinum toxin therapy: A tempting tool in the management of salivary secretory disorders. *Am J Otolaryngol* 2008;29:333-8.
16. Laskawi R, Winterhoff J, Köhler S, Kottwitz L, Matthias C. Botulinum toxin treatment of salivary fistulas following parotidectomy: Follow-up results. *Oral Maxillofac Surg* 2013;17:281-5.
17. Nahlieli O, Bar T, Shacham R, Eliav E, Hecht-Nakar L. Management of chronic recurrent parotitis: Current therapy. *J Oral Maxillofac Surg* 2004;62:1150-5.
18. Pantel M, Volk GF, Guntinas-Lichius O, Wittekindt C. Botulinum toxin type b for the treatment of a sialocele after parotidectomy. *Head Neck* 2013;35:E11-2.
19. Tugnoli V, Marchese Ragona R, Eleopra R, de Grandis D, Montecucco C. Treatment of Frey syndrome with botulinum toxin type F. *Arch Otolaryngol Head Neck Surg* 2001;127:339-40.
20. Lovato A, Restivo DA, Ottaviano G, Marioni G, Marchese-Ragona R. Botulinum Toxin Therapy: Functional Silencing of Salivary Disorders. *Acta Otorhinolaryngol Ital.* 2017;37:168-71.