


CASE REPORT

Tubal hydatidiform mole treated with salpingotomy: A case report

Ting Zhao¹  | Xiuhong Hou² | Chunlin Su¹ | Qinjiao Wu¹

¹Department of Gynecology, Obstetrics and Gynecology Hospital of Fudan University, Shanghai, China

²Department of Obstetrics and Gynecology, Shanghai Jinshan TCM-integrated Hospital, Shanghai, China

Correspondence

Qinjiao Wu, Obstetrics and Gynecology Hospital of Fudan University, Shanghai, China.

Email: wqj6688@163.com

Key Clinical Message

Tubal hydatidiform mole is rare and mostly treated with salpingectomy. This manuscript presented a case treated with salpingotomy plus methotrexate that possessed a satisfactory outcome. Our report adds to the experience of using salpingotomy in tubal molar patients.

KEYWORDS

ectopic pregnancy, hydatidiform mole, methotrexate, salpingectomy, salpingotomy

1 | INTRODUCTION

Hydatidiform moles mainly develop within the uterine cavity, but may also occur in ectopic pregnancy. Tubal hydatidiform mole is a very rare entity which was first reported in 1871. To date, patients affected by this disease are mostly treated with salpingectomy while salpingotomy was only reported in one case.¹

For common ectopic pregnancies in the fallopian tube, increased risks of persistent trophoblast (7% vs <1%; relative risk (RR) = 15.0, 95% confidence interval (CI) = 2.0-113.4) and repeat ectopic pregnancy (8% vs 5%; RR = 1.6, 95% CI = 0.8-3.3) were documented in patients treated with salpingotomy compared to those with salpingectomy.² For tubal molar pregnancy, the main threat after salpingotomy is gestational trophoblastic neoplasia (GTN), which is not estimated yet because only one case was reported before. Here, we present another case of tubal hydatidiform mole that was treated with salpingotomy and possessed a favorable prognosis.

2 | CASE PRESENTATION

A 27-year-old Chinese G1P0 female consulted the outpatient department with complaints of spotting per vaginum and intermittent abdominal pain for 5 days. Her

last menstruation was 30 days before. Physical examination revealed incassation in the right adnexal area. No signs of peritonitis were detected. Urine pregnancy test was positive and pelvic ultrasonography revealed a right adnexal mass measuring 31 × 28 × 18 mm (medium/low echogenic), while no sac was detected in the uterine cavity. Serum beta-HCG titer was 6178 mIU/mL, and progesterone titer was 3.73 ng/mL. The patient had an induced abortion of the first trimester and an appendicectomy, 3 and 11 years before the attendance, respectively. The family history was not significant, and she was a non-smoker.

The patient was primarily diagnosed with ectopic pregnancy. Explorative laparoscopy was performed and an unruptured mass with a purple blue appearance was found in the ampulla of the right fallopian tube. There was little free fluid collection in the pouch of Douglas. Right salpingotomy was performed and 100 mg methotrexate was injected into the right mesosalpinx as a routine at the time of salpingotomy for ectopic gestation in this institution. The specimen was sent for histological evaluation. Grossly, the content of the tube consisted of a lump of dun-colored blood clots in which villi were seen. Microscopically, circumferentially proliferated cytotrophoblastic and syncytiotrophoblastic cells were presented with irregular shape and enriched stroma. Hydropic appearance was mild in this case as the pregnancy was still in its early days. No embryonic tissue was present.

This is an open access article under the terms of the Creative Commons Attribution-NonCommercial License, which permits use, distribution and reproduction in any medium, provided the original work is properly cited and is not used for commercial purposes.

© 2019 The Authors. *Clinical Case Reports* published by John Wiley & Sons Ltd.

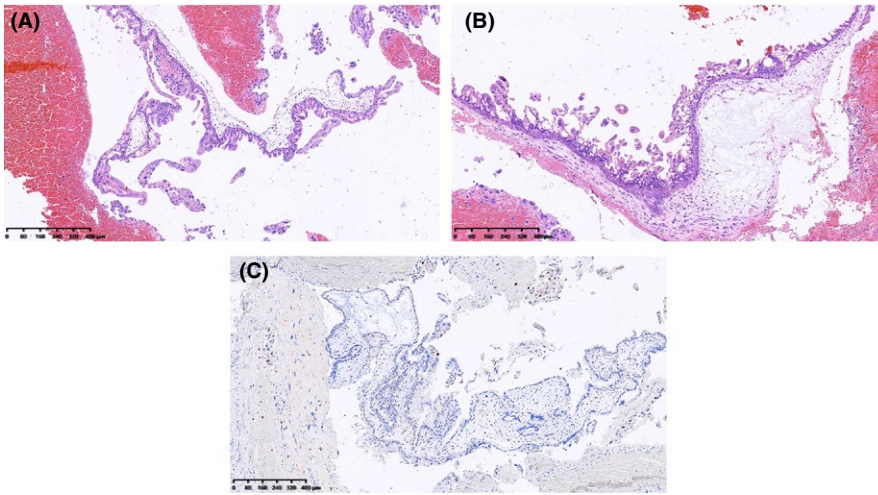


FIGURE 1 The microscopic features of the presented case. A and B, Hematoxylin and eosin staining of the specimen. Circumferential proliferated trophoblast cells were presented which are irregular-shaped and enriched in stroma. Hydropic appearance was mild in this case. C, The immunohistochemistry staining of P57. Cytotrophoblast cells or villous stroma was negative for P57 expression

The P57 expression in villous trophoblast cells or stroma was negative. The result of the karyotype analysis of the sample was 46, XX. All the above features were highly suggestive of tubal complete hydatidiform mole (Figure 1).

The postoperative course was uneventful, and no side effects of methotrexate such as leucopenia or hepatic dysfunction were reported. The patient was then monitored according to the guidelines for hydatidiform moles. At the second day of surgery, the beta-HCG fell to 996.79 mIU/mL and returned to normal after two weeks. After that, she was followed-up every week until three consecutive negative beta-HCG titers were achieved. Then, she was followed-up every one or two months for one year, during which oral contraceptive pills were suggested. Progression was not detected in the 24 months after surgery. Written informed consent was obtained from the patient.

3 | DISCUSSION

Tubal hydatidiform mole is an extremely rare event. The incidence of this disease is estimated to be between 1/200 000 and 1/10 000, which varied considerably in different countries.³ In the United Kingdom, an incidence of 1.5/1 000 000 as documented in a 15-year study⁴; while in Tunisia, an incidence of 4.3/10 000 was reported in a university hospital in 2012.⁵

The diagnosis of tubal hydatidiform moles depends mainly on pathology in the present case. Histologically, they are difficult to be distinguished from two situations: non-molar hydropic abortion and early placentation.⁶ Burton et al reviewed 25 patients suspected of ectopic moles out of 4261 patients, but confirmed only 3 (12.0%) cases on central pathological review.⁶ Gillespie et al and Sebire et al found even lower rates of final identification in suspected patients (9.7% and 6.1%, respectively).^{4,7} The diagnostic deviation mainly arose from the fact that in tubal gestation extravillous trophoblast

cells may be particularly exuberant and the blighting of ova is common, which are easily misleading to hydatidiform moles.⁶ Pathologically, tubal hydatidiform moles are characterized by marked circumferential proliferation of trophoblast accomplished by the presence of hydropic changes affecting some or all of the placental villi.⁶ In early placentation, polar trophoblastic proliferation is characteristic while hydropic is absent or mild. In hydropic abortion, mild to moderated edema of the villous stroma is characteristic while circumferential trophoblastic excess is absent.⁶

Molecular techniques were helpful in distinguishing partial from complete moles. In the present case, negative expression of P57 of the villous trophoblast cells or stroma was used for confirming the complete mole diagnosis.⁸ Genotyping, DNA flow cytometry, and chromosome in situ hybridization were also considered to be helpful in differentiating moles by ploidy.⁶ This conclusion was based on the traditional wisdom that complete mole is diploid whereas partial mole is triploid. However, it was reported that only 94% of the complete moles were diploidy and 65% of the partial moles were triploidy.⁹

The risk of GTN after salpingectomy in tubal moles is considered much lower compared to intrauterine counterparts because the lesion was completely removed. For intrauterine moles, approximately 20% of complete and 3.5% of partial moles progressed to GTN.¹⁰ There were only sporadic reports of tubal moles progressed to GTN after salpingectomy and all the reported cases achieved remission after methotrexate or second-line chemotherapy.^{6,11,12}

Yet the risk of GTN after salpingotomy in tubal moles is undefined and our case may add to the experience of using salpingotomy in such patients. Most of the time, the diagnosis of tubal molar pregnancy occurs after pathological examination and common ectopic pregnancy was ordinarily suspected before the surgery. In such cases, salpingotomy may be chosen by patients possessing strong willingness to preserve the tube. In 1998, Newcomer reported a patient of tubal partial mole treated with salpingotomy. That was

a 25-year-old woman with beta-HCG titer of 6909 mIU/mL at 8 week's gestation. She did not receive chemotherapy and recovered well without persistence or recurrence.¹ Here, we presented a case of tubal complete mole treated with salpingotomy plus methotrexate, which possessed a favorable outcome. Being a folic acid antagonist that blocks cell division¹³ and thus able to kill the possible residual trophoblast cells, methotrexate was used comprehensively in conservative surgery of ectopic pregnancy in China. In this case, methotrexate acted as prophylactic chemotherapy and may have contributed to the remission of disease.

4 | CONCLUSION

Tubal hydatidiform mole is really rare and mostly treated with salpingectomy. The risk of GTN after salpingotomy for this disease is unknown as salpingotomy was seldomly reported before. Here, we presented a case of tubal complete mole treated with salpingotomy plus methotrexate that possessed a favorable outcome. Our report adds to the experience of using salpingotomy in tubal molar patients.

CONFLICT OF INTEREST

None declared.

AUTHOR CONTRIBUTION

TZ: analyzed and interpreted the patient data, designed and wrote the manuscript. XH: wrote the manuscript. CS: revised the manuscript. QW: designed the manuscript. All the authors had read and approved the final manuscript.

ORCID

Ting Zhao  <https://orcid.org/0000-0003-3795-939X>

REFERENCES

- Newcomer JR. Ampullary tubal hydatidiform mole treated with linear salpingotomy. A case report. *J Reprod Med*. 1998;43:913-915.
- Mol F, van Mello NM, Strandell A, et al. Salpingotomy versus salpingectomy in women with tubal pregnancy (ESEP study): an open-label, multicentre, randomised controlled trial. *Lancet*. 2014;383:1483-1489.
- Siozos A, Sriemevan A. A case of true tubal hydatidiform mole and literature review. *BMJ Case Rep*. 2010. <https://doi.org/10.1136/bcr.07.2009.2123>
- Gillespie AM, Lidbury EA, Tidy JA, Hancock BW. The clinical presentation, treatment, and outcome of patients diagnosed with possible ectopic molar gestation. *Int J Gynecol Cancer*. 2004;14:366-369.
- Mbarki C, Jerbi E, Hsayaoui N, Zouari F, Ben Brahim E, Oueslati H. Molar tubal ectopic pregnancy: report of two cases. *J Obstet Gynaecol Res*. 2015;41:985-988.
- Burton JL, Lidbury EA, Gillespie AM, et al. Over-diagnosis of hydatidiform mole in early tubal ectopic pregnancy. *Histopathology*. 2001;38:409-417.
- Sebire NJ, Lindsay I, Fisher RA, Savage P, Seckl MJ. Overdiagnosis of complete and partial hydatidiform mole in tubal ectopic pregnancies. *Int J Gynecol Pathol*. 2005;24:260-264.
- Fisher RA, Hodges MD, Rees HC, et al. The maternally transcribed gene p57(KIP2) (CDNK1C) is abnormally expressed in both androgenetic and biparental complete hydatidiform moles. *Hum Mol Genet*. 2002;11:3267-3272.
- Hemming JD, Quirke P, Womack C, Wells M, Elston CW, Bird CC. Diagnosis of molar pregnancy and persistent trophoblastic disease by flow cytometry. *J Clin Pathol*. 1987;40:615-620.
- Mungan T, Kuscu E, Dabakoglu T, Senoz S, Ugur M, Cobanoglu O. Hydatidiform mole: clinical analysis of 310 patients. *Int J Gynaecol Obstet*. 1996;52:233-236.
- Soares PD, Costa OL, Costa LA, Maesta I. Gestational trophoblastic neoplasia following molar ectopic pregnancy: a case report. *J Reprod Med*. 2008;53:579-582.
- Ji YI, Jung MH. Gastrointestinal bleeding caused by ileal metastasis of a tubal complete mole: a case report. *J Womens Health (Larchmt)*. 2010;19:1217-1220.
- Lermann J, Segl P, Jud SM, et al. Low-dose methotrexate treatment in ectopic pregnancy: a retrospective analysis of 164 ectopic pregnancies treated between 2000 and 2008. *Arch Gynecol Obstet*. 2014;289:329-335.

How to cite this article: Zhao T, Hou X, Su C, Wu Q. Tubal hydatidiform mole treated with salpingotomy: A case report. *Clin Case Rep*. 2019;7:653–655. <https://doi.org/10.1002/ccr3.2037>