

Clinical Aspects of Pterygium in the Presence of Cataract

MARIA FILOFTEA MERCUȚ (NICOLCESCU)¹,
ȘTEFANIA CRĂIȚOIU¹, CARMEN LUMINIȚA MOCANU¹,
ALIN ȘTEFĂNESCU-DIMA¹, ANDREI BĂLĂȘOIU¹, RĂZVAN MERCUȚ²,
ALIN-GABRIEL IONESCU³, MIHAELA IONESCU⁴

¹Department of Ophthalmology, University of Medicine and Pharmacy of Craiova, Romania

²Department of Plastic Surgery and Reconstructive Microsurgery,
University of Medicine and Pharmacy of Craiova, Romania

³Department of Medical History, University of Medicine and Pharmacy of Craiova, Romania

⁴Department of Medical Informatics and Biostatistics, University of Medicine and Pharmacy of Craiova, Romania

ABSTRACT: Two of the most common UV-induced eye affections are pterygium and cataract. They are both defined as progressive diseases that impair patients' vision and share some common elements in their evolution process. The purpose of this study was to determine whether the presence of cataract influences the clinical signs and symptoms of patients with pterygium. Therefore, we have analyzed 84 patients with pterygium, among which 23 also presented cataract, as an overall study lot, as well as divided by age decades. We have determined that almost all patients with both pterygium and cataract declared extensive UV exposure in antecedents and have also reported a blurred vision. We found no correlation between the presence of cataract and the size of pterygium lesions, or symptoms like foreign body sensation, tearing or symblepharon.

KEYWORDS: Pterygium, cataract, UV-induced eye lesions

Introduction

During the past decades, the impact of ultraviolet radiation (UVR) upon eyes and skin has been the main subject for many research studies, given the fact that the protecting ozone layer is decreasing in size and light exposure is significantly higher.

The surface radiation levels are amplified and even if the eyes look down, the reflective ground surface increases the cumulative ocular exposure, impacting the periorbital region, cornea, lens and bulbar conjunctiva [1-2].

Protective measures are easy to apply-wearing UV blocking sunglasses or contact lens, brimmed hats and appropriate clothes [3-4].

Two of the most common diseases favored by UV-exposure are pterygium and cataract. Pterygium is a proliferative disorder, represented by a wing-shaped fibrovascular growth of the bulbar conjunctiva towards the cornea.

Cataract is defined as an opacity or clouding of the lens of the eye that causes it to lose its transparency and/or scatter light. Regarding the morphological types, cataracts are divided into four basic categories: nuclear, posterior subcapsular, cortical and advanced cataract.

Numerous epidemiological studies have been carried out regarding the prevalence and the risk

factors incriminated in pterygium, their results highlighting a wide variation of the prevalence value according to the geographical area, UV-exposure and age. It was observed that the highest prevalence is found in the geographical area delimited by the coordinates 37 North and 37 South of the Equator, called the "pterygium belt" [5].

Furthermore, numerous studies have demonstrated a causative effect of chronic ultraviolet radiation on pterygium [6].

Having an outdoor occupation such as farmer, hunter is a strong risk factor, as spending long hours exposed to sunlight increases the odds of developing pterygium. This fact can also be correlated with higher pterygium prevalence in rural residents compared to urban residents. Various authors have studied lens UV-induced damage, indicating that UVB can be associated with an increased cortical cataract risk in various populations. Sasaki et al. reported a higher prevalence of early cortical cataract in the lower nasal quadrant, fact that could be explained by the incident oblique rays' pathway which transverse the anterior chamber and focus in the nasal quadrant [7].

Both cataract and pterygium are UV-induced diseases. The purpose of this study is to provide a comparative data analysis between two groups:

patients with pterygium and patients with both pterygium and cataract, in order to see if there are any significant differences between groups, and also to determine whether an association with cataract may potentiate clinical manifestations of pterygium.

Material and Methods

We have conducted our study on 84 patients with a confirmed diagnostic of pterygium, admitted within the Ophthalmology Clinic of the Emergency County Hospital Craiova. The study lot was composed in accordance to the following selection criteria: admittance between 01.03.2017 and 01.03.2019, procedure to be followed- pterygium surgical removal and age above 60 years old. All patients gave their consent for being included in this study. The Ethic Committee from the University of Medicine and Pharmacy of Craiova approved this research.

Before surgery, we have investigated all patients regarding their symptomatology, clinical signs, medical history, and factors that define their general habits and living context.

Pterygium lesions sizes were measured in mm, before the surgical excision. Patients were divided in age decades (60-69, 70-79, 80-89, 90-99 years). The presence of symptoms was recorded in patients' charts based on YES/NO responses, as well as previous medical conditions.

Given the purpose of our study, we have divided the initial study lot in two subgroups, in accordance with cataract presence or absence: 23 patients with both pterygium and cataract (denoted group P+C), and 61 patients with pterygium only (denoted group P). Then, we have performed comparisons between all analyzed variables. We have used Microsoft Excel (San Francisco, USA) to apply Chi-square (with Yates correction, if necessary) and T-student tests in order to evaluate the two groups distributions (significance level *p* was considered 5%).

Results

Our study lot comprised 46 females and 38 males, with ages between 60 and 91 years old (mean age 71.4±6.9 years).

According to Table 1, most of the patients have ages included in the first two decades (from 60 to 79 years). Group P+C has a higher mean age, with almost 74% patients included within the age decade 70-79 years, while group P has 50.8% patients included within the first age decade (60-69 years).

Table 1. Study lot description

	P		P+C	
	M	F	M	F
Total	27	34	11	12
Mean age	69.1	71.9	73	73.75
60-69 years	18	13	2	3
70-79 years	5	15	8	9
80-89 years	3	5	1	0
90-99 years	1	1	0	0
Urban	10	2	3	0
Rural	17	32	8	12

Most of the patients live in the rural area (80.3% for group P, respectively 86.9% for group P+C), having general activities more likely to be conducted outside (specific for farmers), thus being more exposed to UV-radiation.

An important parameter assessed before surgery was pterygium lesion size. Patients from both study groups exhibited lesions with sizes between 1mm and 8mm. The distribution of the study lot, divided by the presence of cataract, age decades and pterygium size, indicate that there are no major differences between the patients with and without cataract (*p*>0.05).

The maximum difference is 3.42%, for lesions of 3mm. Fig.1a presents the distribution of the study lot, both groups in parallel, in terms of pterygium lesion size.

Fig.1b presents the mean size of pterygium lesions for all four age decades, divided by groups P and P+C.

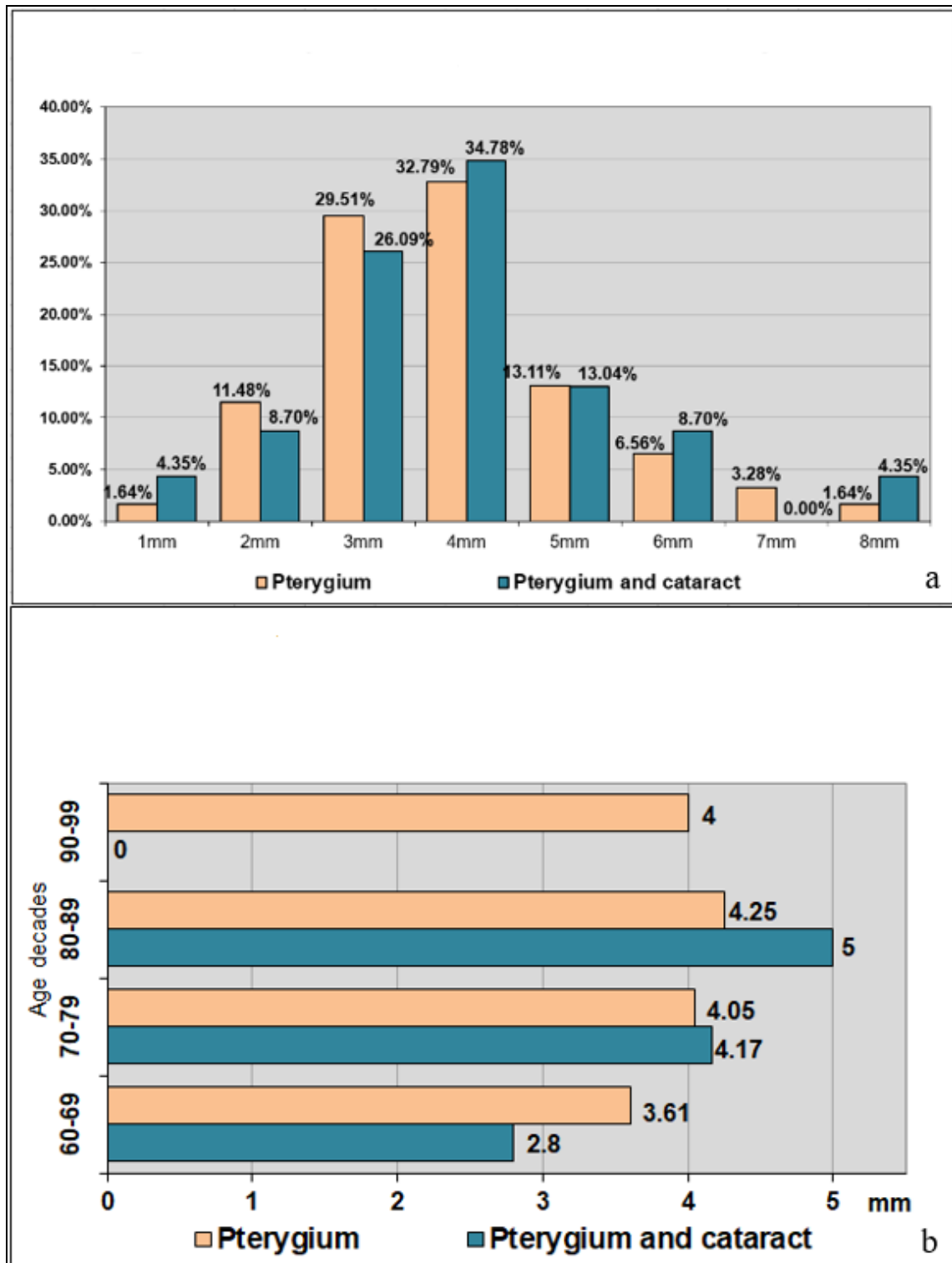


Fig.1. Distribution of the study lot by: a) pterygium lesion size and presence of cataract; b) age decades, presence of cataract and pterygium lesions mean size

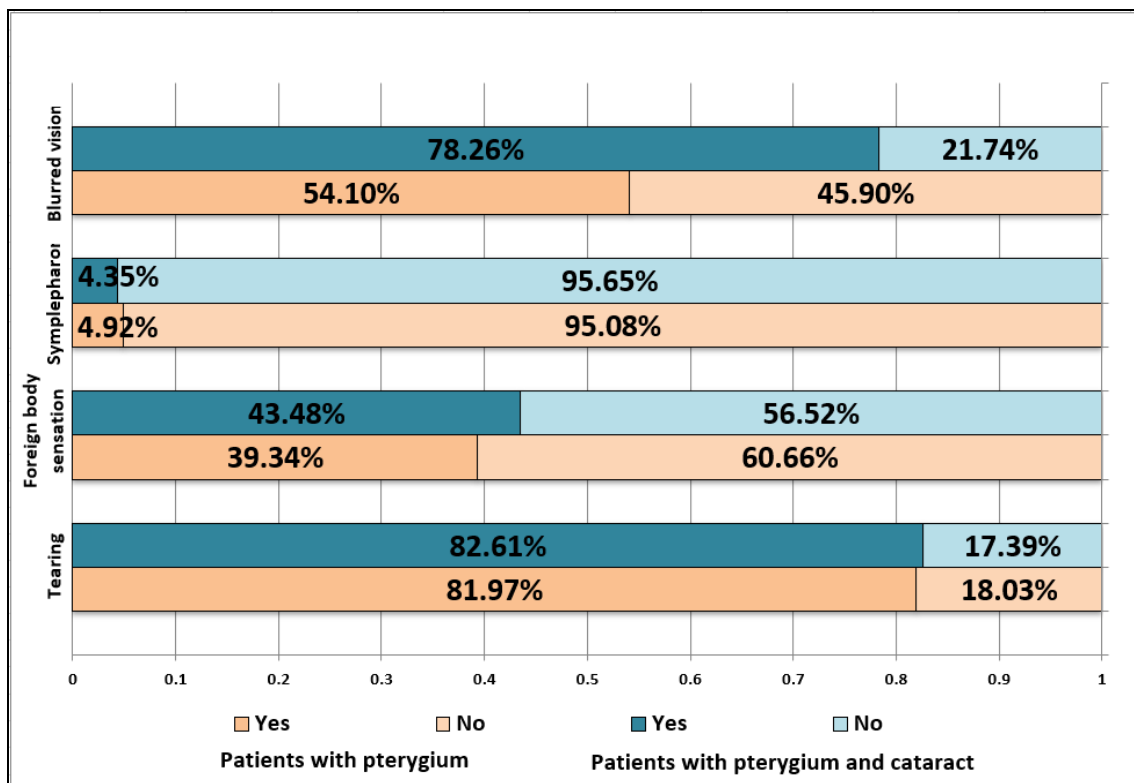


Fig.2. Distribution of the study lot according to the presence of clinical manifestations

A comparison between groups P and P+C regarding sex distribution, rural/urban area, left eye/right eye affected by pterygium, revealed similar percentages (no significant differences, $p>0.05$).

Similarly, for medical antecedents, we have observed close percentages in what concerns arterial hypertension, cardiomyopathy, asthma, diabetes mellitus, pulmonary thromboembolism, primary open angle glaucoma, primary closed angle glaucoma, Sicca Syndrome (no significant differences, $p>0.05$).

In terms of symptoms presence, we have noticed very small differences between percentages regarding tearing, foreign body sensation and symblepharon ($p>0.05$). However, in what concerns blurred vision, the difference is significant: 78.26% patients with both pterygium and cataract reported this symptom, compared to 54.10% patients with pterygium only ($p<0.05$).

A smaller difference is present for foreign body sensation: 43.48% patients within group P+C, compared to 39.34% patients within group P. Fig.2 reflects the distribution of the study lot, divided by groups and symptoms presence.

A more detailed analysis of both groups regarding the reported blurred vision indicates that patients whose vision was not blurred (33 patients, representing 39.3% from the entire study lot) had smaller lesions, mainly up to 4mm.

Only 2 patients (6.06% from group without this symptom) presented lesions of 5mm, respectively 6 mm (Fig.3a).

On the other hand, patients with blurred vision had lesions from 2 to 8mm, and the percentage of this symptom's presence was higher for patients within group P+C, for almost all lesion sizes (Fig.3b).

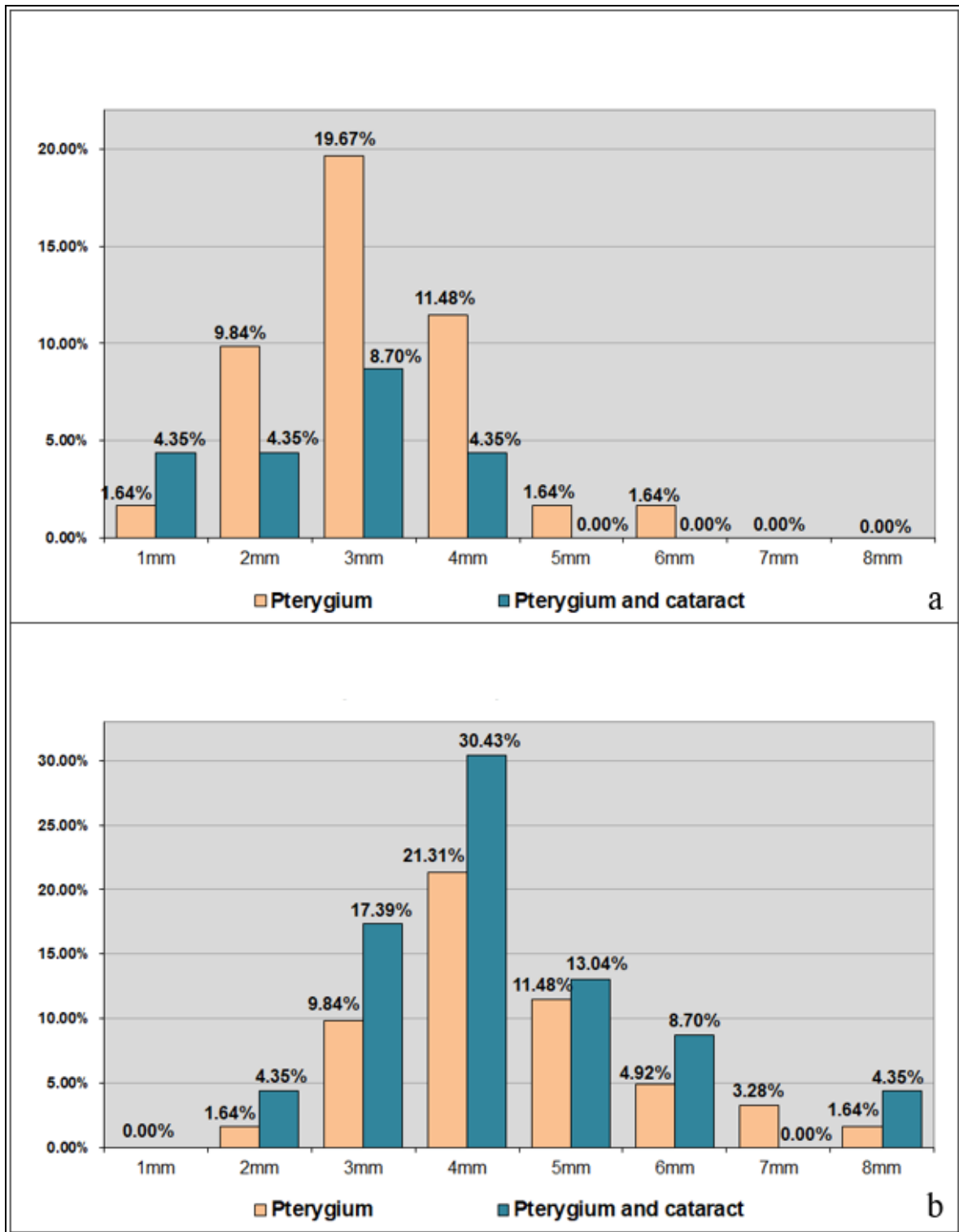


Fig.3. Distribution of the study lot for patients without blurred vision (a), and with blurred vision (b)

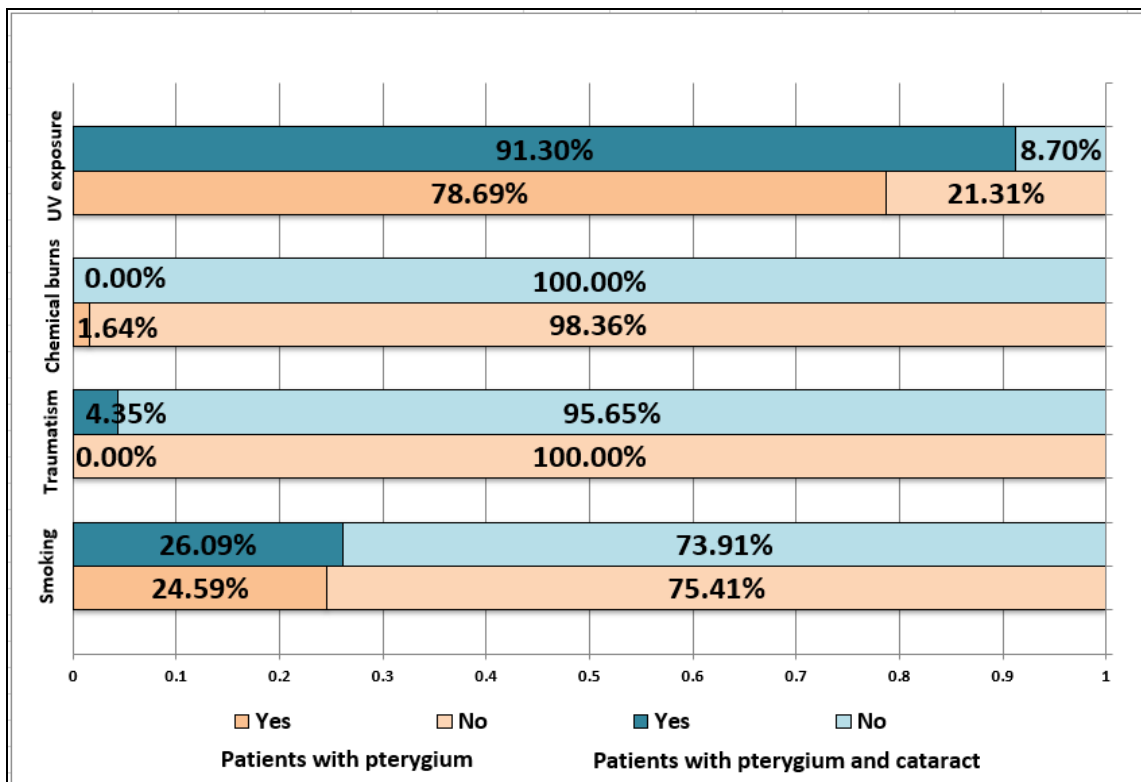


Fig.4. Distribution of the study lot according to general habits, divided by groups

It is uncertain whether the blurred vision declared by each patient is related to pterygium or cataract.

For almost all lesion sizes, the group P+C presented larger lesions which could also generate a blurred vision, next to cataract which is known to generate cloudy vision.

A comparison between general factors and habits indicates similar percentages in what concerns chemical burns, traumatism and smoking habits ($p > 0.05$).

Regarding UV-exposure, there is a significant difference between groups: 78.69% patients within group P reported UV exposure, compared to 91.30% patients within group P+C (Fig.4).

We have further analyzed those values, adding also a division by pterygium lesion size. Patients who declared that were not exposed to UV radiation (15 patients, representing 17.86% from the entire study lot) had small lesions, from 1mm to 5mm (only one patient had a lesion with this maximum value). Patients within group P+C only had lesions of 1mm and 3mm (Fig.5a).

Most patients were exposed to UV radiation (69 patients, 82.14%) and had lesions from 2mm to 8mm. For almost all sizes, patients within group P+C presented a higher percentage of reported exposure (Fig.5b).

All other comparisons (division by decade or lesion size) revealed similar values between groups P and P+C ($p > 0.05$).

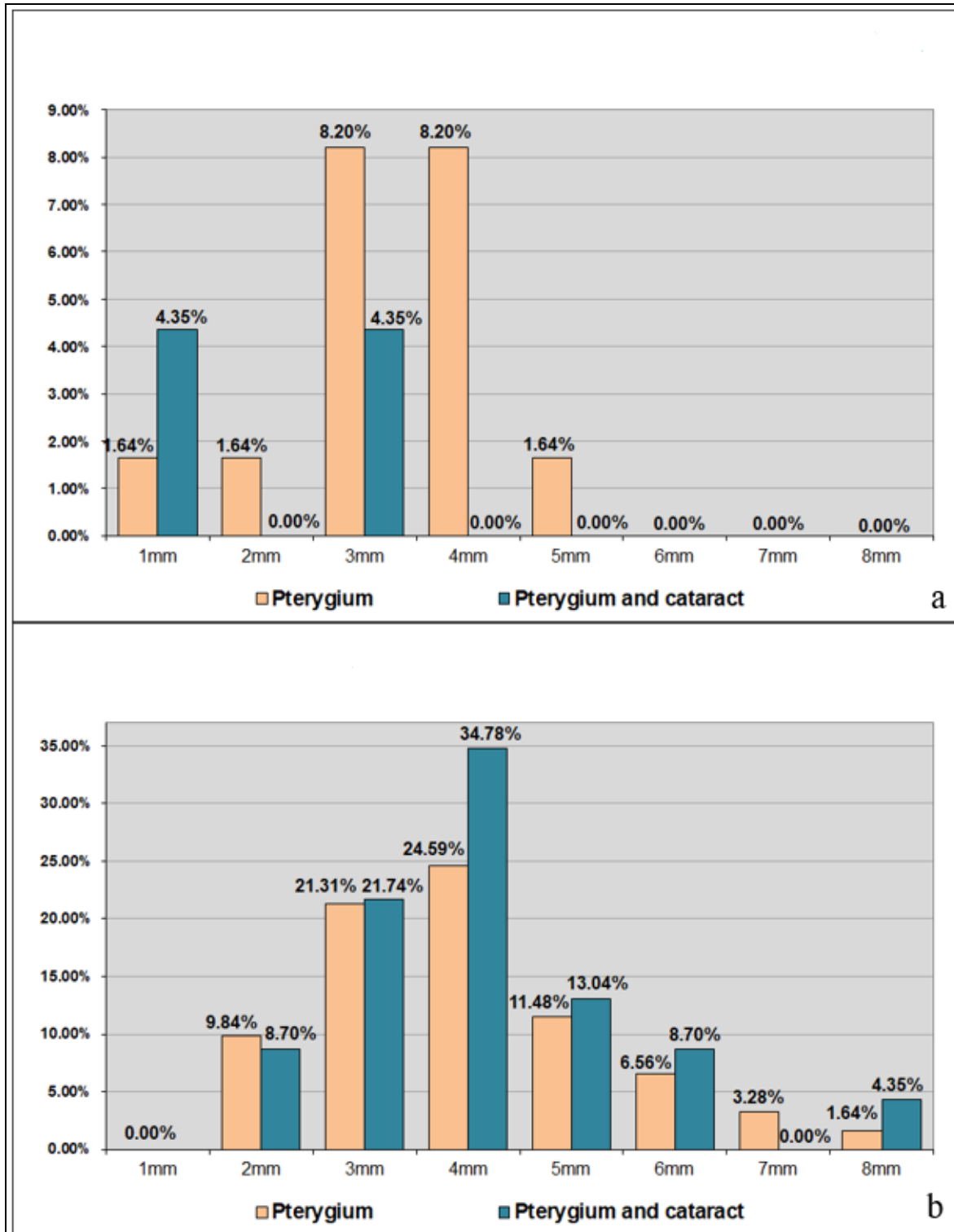


Fig.5. Distribution of the study lot for patients without UV exposure (a), and with UV exposure (b) in antecedents

Discussions

As seen in the previous section, UV exposure seems to be an important factor influencing both pterygium and cataract, results also confirmed by similar studies [8-12].

UVR is electromagnetic radiation with wavelengths ranging from 10nm to 400nm (being shorter than visible light wavelength).

UVR has a proven potential to produce biological damage by increasing the expression of matrix metalloproteinases (MMPs). Within

the eye, there are various inner structures that absorb UVR differently. Longer wavelengths usually pass through the cornea (and reach the lens), while shorter wavelengths are mostly absorbed at that level (UV below 300nm) [3].

Ocular cells exposed to UV radiation synthesize MMPs, which are zinc-dependent endopeptidases that mediate the degradation of extracellular matrix (ECM) proteins like collagen, elastin or fibronectin [13-15].

Within the family of MMPs (over 28 recently discovered), the gelatinases MMP2 and MMP9 are the most studied MMPs from the ocular tissue. They play a major role in degrading collagen type IV, which is a component of the lens capsule. They are also expressed, specifically at low levels, within the lens epithelium [16].

Altered expression of MMPs is known to be associated with cataractogenesis [16-17].

So, next to several proved risk factors like increasing age, obesity, diabetes, smoking and high blood pressure, the impact of UV exposure was also analyzed by multiple studies [15,18,19].

Many authors have attempted to determine a correlation between cataract and the degree of UV exposure [7,20-22], leading to the conclusion that intensive UV exposure or long-term low exposure represent indeed a potential factor in cataract development.

An altered expression of MMPs is also known to impact pterygium, a fibrovascular tissue grown over the corneal surface, usually at the inner corner of the eye [23].

Di Girolamo et al. have identified the presence of pro-inflammatory cytokines and MMP2, MMP3, MMP9, MMP1 in pterygium tissue, following the activation of epidermal growth factor receptors [3,24-25].

There is no clear quantification of the UV exposure, increased expression of MMPs and development of pterygium lesions, although many scientists have identified interconnections between these factors [8,26].

For both pterygium and cataract, light exposure is an important factor in their genesis and progression. Cao et al. defines them as some of the most common ocular diseases caused by UVR and attempted to identify a relationship between them. The authors have proved that age-related cataract represents a risk factor for pterygium, and in the same time, patients with pterygium have an increased prevalence rate of cataract [27].

In our study, we have analyzed several clinical aspects of pterygium, in order to see if they are modified by the presence of cataract. We have compared two groups of patients: group P including patients with pterygium, and group P+C including patients with pterygium and cataract. After the initial analysis based on the basic descriptive parameters of the study lot, we have noticed a clear gap of mean age between the two studied groups, as cataract is a disease that is more frequent in elderly persons [28].

However, despite this difference, the mean size of pterygium lesions is very similar (4.17mm compared to 4.05mm).

Symptomatology comparison reveals that more patients within group P+C reported having a blurred vision, compared with those from group P. But cataract is represented by lens opacity, leading implicitly to an altered vision. However, the symptom cannot be clearly associated with only cataract, since group P also reported it, so there is a possibility that the perception level is amplified by the presence of both diseases.

There is no apparent connection between pterygium and cataract in terms of clinical manifestations. This hypothesis is sustained by our results, since the two groups of patients (P and P+C) presented relatively small differences for almost all analyzed parameters.

The most important progression factor of pterygium analyzed in our study was the lesion size (measured before surgery). The general tendency of size distribution is similar for both groups, thus indicating that the presence of cataract does not influence this specific parameter.

Our study has some limitations, as it does not consider the type of cataract or its progression level. Thus, it may be extended to study potential connections with specific types of cataract.

Conclusion

Pterygium and cataract have a common factor in their development-the increased expression of MMPs (specifically MMP2 and MMP9), as a potential consequence of UV-exposure. However, these two diseases do not seem to be related in terms of clinical data, as it was shown by our research.

As chronic UV radiation effects at the level of the cornea and the lens are cumulative, UV-protective measures should be implemented full time through the year for all age groups.

References

1. Garzón-Chaveza D, Quentind E, Harrison S, Parisi A, Butler H, Downs N. The geospatial relationship of pterygium and senile cataract to ambient solar ultraviolet in tropical Ecuador. *Photochem Photobiol Sci*, 2018, 17(8):1075-1083.
2. Behar-Cohen F, Baillet G, de Ayguavives T. Ultraviolet damage to the eye revisited: eye-sun protection factor (E-SPF®), a new ultraviolet protection label for eyewear. *Clin Ophthalmol*, 2014, 8:87-104.
3. Yam JC, Kwok AK. Ultraviolet light and ocular diseases. *Int Ophthalmol*, 2014, 34(2):383-400.
4. Miyashita H, Hatsusaka N, Shibuya E, Mita N, Yamazaki M, Shibata T, Ishida H, Ukai Y, Kubo E, Sasaki H. Association between ultraviolet radiation exposure dose and cataract in Han people living in China and Taiwan: A cross-sectional study. *PLoS ONE*, 2018, 14(4):e0215338.
5. Hashemi H, Khabazkhoob M, Yekta A, Jafarzadehpour E, Ostadi moghaddam H, Kangari H. The prevalence and determinants of pterygium in rural areas. *Journal of Current Ophthalmology*, 2016, 29(3):194-198.
6. Zhou W, Zhu Y, Zhang B, Qiu W, Yao Y. The role of ultraviolet radiation in the pathogenesis of pterygia. *Molecular Medicine Reports*, 2016, 14:3-15.
7. Sasaki H, Jonasson F, Shui Y, Kojima M, Ono M, Katoh N. High prevalence of nuclear cataract in the population of tropical and subtropical areas. *Dev Ophthalmol*, 2002, 35:60-69.
8. Paula J, Thorn F, Cruz A. Prevalence of pterygium and cataract in indigenous populations of the Brazilian Amazon rain forest. *Eye*, 2006, 20(5):533-536.
9. Youn B, Chou B, Sivak J. Phototoxicity. *Open Toxicol J*, 2010, 4:13-20.
10. Chalam K, Khetpal V, Rusovici R, Balaiya S. A review: role of ultraviolet radiation in age-related macular degeneration. *Eye Contact Lens*, 2011, 37(4):225-232.
11. Khan J, Shahid H, Thurlby D, Bradley M, Clayton D, Moore A. Age related macular degeneration and sun exposure, iris colour, and skin sensitivity to sunlight. *Br J Ophthalmol*, 2006, 90(1):29-32.
12. Sui G, Liu G, Liu G, Gao Y, Deng Y, Wang W. Is sunlight exposure a risk factor for age-related macular degeneration? A systematic review and meta-analysis. *Br J Ophthalmol*, 2013, 97(4):389-394.
13. Pittayapruek P, Meephansan J, Prapapan O, Komine M, Ohtsuki M. Role of Matrix Metalloproteinases in Photoaging and Photocarcinogenesis. *Int. J. Mol. Sci*, 2016, 17(6):868.
14. Sachdev N, Di Girolamo N, Nolan T, McCluskey P, Wakefield D, Coroneo M. Matrix metalloproteinases and tissue inhibitors of matrix metalloproteinases in the human lens: Implications for cortical cataract formation. *Invest Ophthalmol Vis Sci*, 2004, 45:4075-4082.
15. Vasudevan S, Abraham A. Age Related or Senile Cataract: Pathology, Mechanism and Management. *Austin J Clin Ophthalmol*, 2016, 3(2):1067.
16. Li J, Wang N, Wang J. Expression of matrix metalloproteinases of human lens epithelial cells in the cultured lens capsule bag. *Eye*, 2008, 22:439-444.
17. West-Mays J. Matrix Metalloproteinases as Mediators of Primary and Secondary Cataracts. *Expert Rev Ophthalmol*, 2007, 2(6):931-938.
18. Pastor-Valero M, Fletcher A, de Stavola B, Chaques-Alepuz V. Years of sunlight exposure and cataract: a case-control study in a Mediterranean population. *BMC Ophthalmol*, 2007, 7:18.
19. Tan A, Tay W, Mitchell P, Sandar M, Aung T, Saw S. Prevalence of lens opacities in Asian Malays. *Ophthalmic Epidemiol*, 2012, 19(6):380-387.
20. Giblin F, Leverenz V, Padgaonkar V, Unakar N, Dang L, Lin L. UVA light in vivo reaches the nucleus of the guinea pig lens and produces deleterious, oxidative effects. *Exp Eye Res*, 2002, 75(4):445-458.
21. Delcourt C, Carriere I, Ponton-Sanchez A, Lacroux A, Covacho M, Papoz L. Light exposure and the risk of cortical, nuclear, and posterior subcapsular cataracts: the Pathologies Oculaires Liees a l'Age. *Arch Ophthalmol*, 2000, 118(3):385-392.
22. Hayashi L, Hayashi S, Yamaoka K, Tamiya N, Chikud M, Yaho E. Ultraviolet B exposure and type of lens opacity in ophthalmic patients in Japan. *Sci Total Environ*, 2003, 302(1-3):53-62.
23. Aletras A, Trilivas I, Christopoulou M, Drakouli S, Georgakopoulos C, Pharmakakis N. UVB-mediated down-regulation of proteasome in cultured human primary pterygium fibroblasts. *BMC Ophthalmology*, 2018, 18:328.
24. Di Girolamo N, McCluskey P, Lloyd A, Coroneo M, Wakefield D. Expression of MMPs and TIMPs in human pterygia and cultured pterygium epithelial cells. *Invest Ophthalmol Vis Sci*, 2000, 41:671-679.
25. Di Girolamo N, Wakefield D, Coroneo M. Differential expression of matrix metalloproteinases and their tissue inhibitors at the advancing pterygium head. *Invest Ophthalmol Vis Sci*, 2000, 41:4142-4149.
26. Ip M, Chui J, Tat L, Coroneo M. Significance of Fuchs Flecks in Patients With Pterygium/Pinguecula: Earliest Indicator of Ultraviolet Light Damage. *Cornea*, 2015, 34(12):1560-1563.
27. Cao X, Li X, Bao Y. Relationship between pterygium and age-related cataract among rural populations living in two different latitude areas in China. *Int J Clin Exp Med*, 2017, 10(2):3494-3501.
28. Gupta V, Rajagopala M, Ravishankar B. Etiopathogenesis of cataract: An appraisal. *Indian J Ophthalmol*, 2014, 62(2):103-110.

Corresponding Author: Răzvan Mercuț, Department of Plastic Surgery and Reconstructive Microsurgery, University of Medicine and Pharmacy of Craiova, Romania, e-mail: razvanmercut@gmail.com
