



Contents lists available at ScienceDirect

## International Journal of Surgery Case Reports

journal homepage: [www.casereports.com](http://www.casereports.com)

## Successful transcatheter arterial embolization of a ruptured right gastroepiploic artery aneurysm: A case report

Tohru Ishimine<sup>a,\*</sup>, Toshiho Tengan<sup>a</sup>, Akio Nakasu<sup>a</sup>, Hiroaki Takara<sup>b</sup><sup>a</sup> Department of Cardiovascular Surgery, Okinawa Prefectural Chubu Hospital, 281, Miyazato, Uruma-shi, Okinawa 904-2293, Japan<sup>b</sup> Department of Radiology, Okinawa Prefectural Chubu Hospital, 281, Miyazato, Uruma-shi, Okinawa 904-2293, Japan

## ARTICLE INFO

## Article history:

Received 27 June 2018

Received in revised form 18 August 2018

Accepted 20 August 2018

Available online 25 August 2018

## Keywords:

Gastroepiploic artery aneurysm

Transcatheter embolization

Splanchnic artery aneurysm

Visceral artery aneurysm

## ABSTRACT

**BACKGROUND:** Gastroepiploic artery aneurysms (GEAAs) are extremely rare. Ruptured GEAAs are related to high mortality and often treated by open surgery. We describe a case of a ruptured right GEEA that was successfully treated by transcatheter arterial embolization (TAE).

**PRESENTATION OF CASE:** An 80-year-old woman presented to the emergency department with sudden abdominal pain. We diagnosed her as having a ruptured right GEEA based on the contrast-enhanced computed tomography finding. We performed TAE for the GEEA after resuscitation. The patient had an uneventful recovery and was discharged 10 days after TAE.

**DISCUSSION:** A ruptured GEEA causes high mortality; thus, immediate and adequate treatment is mandatory. Previously, many cases of successful surgical resections of ruptured GEAAs have been reported. In our case, we decided that the patient was not suitable for surgery because of her advanced age and bronchiectasis; therefore, we performed TAE and had a good outcome.

**CONCLUSION:** In patients at high risk for surgery, TAE can be an effective treatment for a ruptured GEEA.

© 2018 The Author(s). Published by Elsevier Ltd on behalf of IJS Publishing Group Ltd. This is an open access article under the CC BY-NC-ND license (<http://creativecommons.org/licenses/by-nc-nd/4.0/>).

## 1. Introduction

Splanchnic artery aneurysms (SAAs) are rare, and gastroepiploic artery aneurysms (GEAAs) account for only about 0.4% of them [1]. GEEA rupture is associated with a high mortality rate [2]. Few cases of ruptured GEAAs have been reported, and most of those patients were treated by open surgery. We describe the case of a ruptured right GEEA that was successfully treated by transcatheter arterial embolization (TAE). This case report has been written in line with the SCARE criteria [3].

## 2. Case report

An 80-year-old woman presented to the emergency room with sudden onset of abdominal pain. She had a history of bronchiectasis with home oxygen therapy. She had a blood pressure of 80/50 mmHg, heart rate of 110 beats/min, body temperature of 35.9 °C, and respiratory rate of 32 breaths/min.

During the abdominal examination, there was diffuse abdominal tenderness and rebound tenderness without muscle guard-

ing. Results of the laboratory investigations showed anemia (hemoglobin level 6.6 g/dl), leukocytosis (white blood cell count, 19 700/mm<sup>3</sup>), and normal renal function with a serum creatinine level of 0.8 mg/dl. The abdominal ultrasonogram showed a moderate volume of intraperitoneal fluid and an SAA measuring 4 cm in diameter in the lower abdomen, which was of unknown origin. After stabilization of vital signs with fluid resuscitations with 1 l of crystalloid, abdominal contrast-enhanced computed tomography (CT) was performed. The CT scan showed a right GEEA with a diameter of 4 cm without extravasation, as well as a moderate amount of intra-abdominal fluid collection (Figs. 1 and 2). Based on the CT findings, we diagnosed her as having hemorrhagic shock because of rupture of the right GEEA. Considering hemodynamic stability and the operative risks such as advanced age and bronchiectasis, we chose to perform TAE, not open surgery.

The angiogram showed a right GEEA without extravasation (Fig. 3a). Through a 5.5-French (Fr) shepherd hook catheter (Terumo Clinical Supply, Tokyo, Japan) placed in the celiac artery, a 2.2-Fr Progreat microcatheter (Terumo Clinical Supply) was inserted into the distal part of the right GEEA. Embolization was performed using 5 Vortex coils (Boston Scientific, Fremont, CA, USA) and 8 Tornado Coils (Cook, Bloomington, IN, USA) at the proximal and distal arteries of the GEEA. The postembolization angiogram revealed no GEEA filling (Fig. 3b). The patient was given 4 U of packed red blood cells.

The contrast-enhanced CT scan obtained 5 days after TAE confirmed no blood flow to the GEEA. The patient had an uneventful recovery and was discharged 10 days after TAE without any

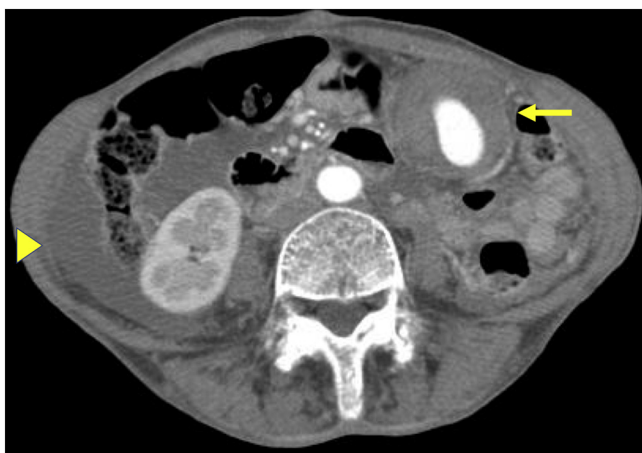*Abbreviations:* SAA, splanchnic artery aneurysm; GEEA, gastroepiploic artery aneurysm; TAE, transcatheter arterial embolization; CT, computed tomography; Fr, French.

\* Corresponding author.

E-mail address: [ishimine.toru@hosp.pref.okinawa.jp](mailto:ishimine.toru@hosp.pref.okinawa.jp) (T. Ishimine).

<https://doi.org/10.1016/j.ijscr.2018.08.039>

2210-2612/© 2018 The Author(s). Published by Elsevier Ltd on behalf of IJS Publishing Group Ltd. This is an open access article under the CC BY-NC-ND license (<http://creativecommons.org/licenses/by-nc-nd/4.0/>).



**Fig. 1.** Contrast-enhanced computed tomography scan showing a large aneurysm (arrow) and a moderate amount of intra-abdominal fluid collection (arrowhead).

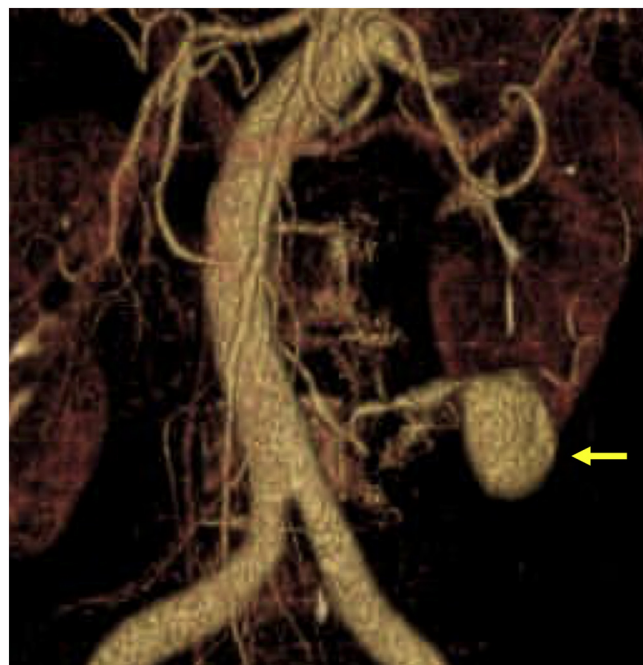
complications. The ultrasonogram 3 months after TAE showed no blood flow to the GEAA in the outpatient department. The patient died of exacerbation of bronchiectasis at 5 months after TAE.

**3. Discussion**

SAA are very rare, accounting for 0.1% of cases according to autopsy statistics [4]. GEAs are extremely rare among all SAAs. Stanley et al. reported that 60% of SAAs are splenic artery aneurysms, followed by hepatic artery aneurysms (20%), superior mesenteric artery aneurysms (5.5%), celiac artery aneurysms (4%), and gastropiploic artery aneurysms (0.4%) [1]. SAAs are associated with arteriosclerosis, aortic dissection, infection, inflammation, trauma, vasculitis due to collagen disease, and segmental arterial mediolysis [5]. The mortality rate after rupture of these SAAs has been reported to be 70% [2].

The patients with ruptured GEAs typically present with abdominal pain, unconsciousness, and shock secondary to intra-abdominal hemorrhage [6]. Although many patients were diagnosed by angiography previously, those diagnosed by contrast-enhanced CT, as in our case, are increasing. Because of its superior imaging resolution and less invasiveness, CT is a useful modality for diagnosing GEAA.

The treatment options for SAAs, including GEAA, are divided into surgical therapy (the open or laparoscopic approach) and TAE. The

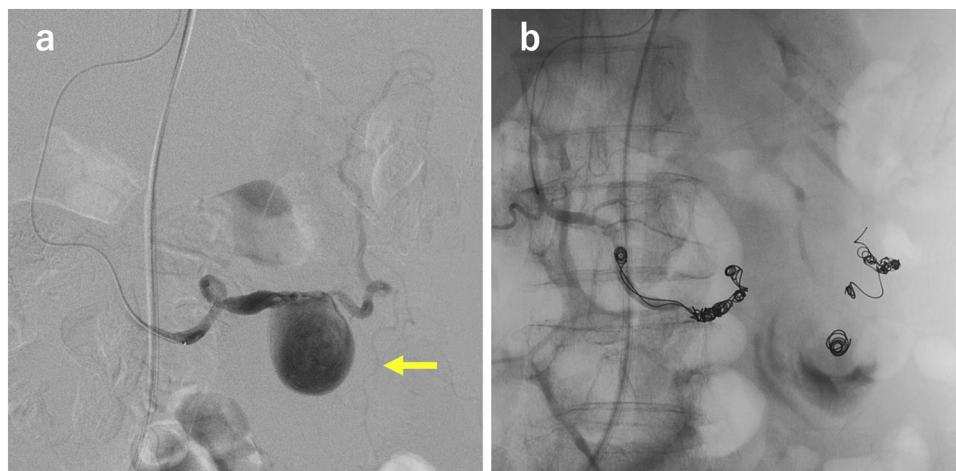


**Fig. 2.** Angiogram reconstructed from computed tomography demonstrating a right gastropiploic artery aneurysms with a diameter of 4 cm (arrow).

treatment strategy for GEAA depends on the patient’s vital signs, age, and comorbidities. In patients with unstable vital signs due to rupture of the GEAA, open surgery should be performed to control bleeding promptly. In patients with stable vital signs, laparoscopic surgery may be an acceptable treatment choice. When patients are stable and at high risk for surgery, TAE can be another option.

According to previous reports, most patients with GEAA were treated by open surgical resection or ligation [7,8]. Successful laparoscopic resections of ruptured and unruptured GEAs in patients with stable vital signs have been also described in literatures [9,10]. The superficial anatomical location of GEAs compared to other SAAs makes it easy to perform laparoscopic surgery.

Although TAE is a widely accepted treatment option for other SAAs [11], few cases of GEAs treated by TAE have been reported [12,13]. In our case, because the patient was at high risk for surgery (advanced age and bronchiectasis with home oxygen therapy) and her vital signs were stable after resuscitation, TAE was



**Fig. 3.** a: Angiogram of the right gastroepiploic artery (GEA) showing a GEA aneurysm (GEAA) (arrow). b: Angiogram of the right GEA showing successful embolization of the distal and proximal arteries of the GEAA.

considered to be first-line treatment. Additionally, unlike other SAAs, GEAAAs can be embolized without any functional disorders. Although TAE is feasible in selected patients, incomplete exclusion may be observed, requiring late reintervention [11]. Since our patient died at 5 months after TAE, the patients who undergo TAE require careful follow-up [11,14].

#### 4. Conclusions

In our case, contrast-enhanced CT was useful in the diagnosis of GEAA. TAE can be an effective treatment for a ruptured GEAA, especially in patients with a high risk for surgery.

#### Conflicts of interest

All authors declare no conflicts of interest.

#### Funding source

No source of funding.

#### Ethical approval

This case report was approved by the Ethics Committee of Okinawa Prefectural Chubu Hospital. Since our case report does not violate the patient's privacy, informed consent was not necessary.

#### Consent

No consent was obtained from the patient in this case report. Because the patient died, and we do not have current address and telephone number of her family, we could not obtain signed consent. Therefore, the chief of Ethics Committee of our hospital has taken responsibility that exhaustive attempts have been made to contact the family and that the paper has been sufficiently anonymised not to cause harm to the patient or their family. We have uploaded this signed document.

#### Author contributions

Tohru Ishimine: Study design, data collection, writing the paper.  
Toshiho Tengan: Review manuscript.  
Akio Nakasu: Data collection, obtain images.  
Hiroaki Takara: Data collection, review manuscript.

#### Registration of research studies

Not applicable for case report.

#### Guarantor

Tohru Ishimine.

#### Provenance and peer review

Not commissioned, externally peer-reviewed.

#### Acknowledgement

We would like to thank Editage ([www.eitage.jp](http://www.eitage.jp)) for English language editing.

#### References

- [1] J.C. Stanley, T.W. Wakefield, L.M. Graham, W.M. Whitehouse Jr., G.B. Zelenock, S.M. Lindenaue, Clinical importance and management of splanchnic artery aneurysms, *J. Vasc. Surg.* 3 (1986) 836–840.
- [2] S. Chandran, A. Parvaiz, A. Karim, I. Ghaffoor, B. Steadman, N.W. Pearce, et al., Ruptured left gastric artery aneurysm successfully treated by thrombin injection: case report and literature review, *Sci. World J.* 5 (2005) 20–23.
- [3] R.A. Agha, A.J. Fowler, A. Saetta, I. Barai, S. Rajmohan, D.P. Orgill, for the SCARE Group, The SCARE statement: consensus-based surgical case report guidelines, *Int. J. Surg.* 34 (2016) 180–186.
- [4] J. Jakschik, D. Decker, H. Vogel, A. Hirner, Acute upper gastrointestinal hemorrhage caused by ruptured aneurysm of the right gastroepiploic artery, *Zentralbl. Chir.* 118 (1993) 157–159.
- [5] Y.K. Takemoto, N. Fujikuni, K. Tanabe, H. Amano, T. Noriyuki, M. Nakahara, A rare case of spontaneous rupture of an aneurysm of the right gastric artery, *Int. J. Surg. Case Rep.* 40 (2017) 27–31.
- [6] T. Sarigoz, S. Carakit, O. Topuz, T. Ertan, A. Koc, Spontaneous rupture of right gastroepiploic artery aneurysm: a rare cause of hemorrhagic shock. Case report, *Sao Paulo Med. J.* (2017), <http://dx.doi.org/10.1590/1516-3180.2017.0070210417>.
- [7] B. Faler, D. Mukherjee, Hemorrhagic shock secondary to rupture of a right gastroepiploic artery aneurysm: case report and brief review of splanchnic artery aneurysms, *Int. J. Angiol.* 16 (2007) 24–26.
- [8] A.S. Ashrafi, M.J. Horkoff, J. Yousuf, A. Stedman, Ruptured gastroepiploic artery aneurysm: a case report, *Int. J. Surg. Case Rep.* 41 (2017) 132–133.
- [9] Y. Murakami, H. Saito, S. Shimizu, Y. Kono, H. Kuroda, T. Matsunaga, et al., A case of unruptured right gastroepiploic artery aneurysm successfully resected by laparoscopic surgery, *Yonago Acta Med.* 60 (2017) 56–58.
- [10] S.J. Go, S.G. Lee, M.S. Lee, B.S. Cho, M.K. Lee, Y.J. Choi, et al., Ruptured gastroepiploic artery aneurysm as an unusual cause of hemoperitoneum, *EJVES Extra* 27 (2014) e27–8.
- [11] E.M. Marone, D. Mascia, A. Kahlberg, C. Brioschi, Y. Tshomba, R. Chiesa, Is open repair still the gold standard in visceral artery aneurysm management? *Ann. Vasc. Surg.* 25 (2011) 936–946.
- [12] M. Shimohira, H. Ogino, M. Kitase, S. Sasaki, M. Ishii, Y. Shibamoto, Embolization of a right gastroepiploic artery pseudoaneurysm associated with Churg–Strauss syndrome, *J. Vasc. Interv. Radiol.* 19 (2008) 301–302.
- [13] M. Koganemaru, T. Abe, M. Nonoshita, R. Iwamoto, M. Kusumoto, A. Kuhara, et al., Follow-up of true visceral artery aneurysm after coil embolization by three-dimensional contrast-enhanced MR angiography, *Diagn. Interv. Radiol.* 20 (2014) 129–135.
- [14] A. Rohatgi, T. Cherian, Spontaneous rupture of a left gastroepiploic artery aneurysm, *J. Postgrad. Med.* 48 (2002) 288–289.

#### Open Access

This article is published Open Access at [sciedirect.com](http://sciedirect.com). It is distributed under the [IJSCR Supplemental terms and conditions](#), which permits unrestricted non commercial use, distribution, and reproduction in any medium, provided the original authors and source are credited.