



ELSEVIER

Available online at [www.sciencedirect.com](http://www.sciencedirect.com)

ScienceDirect

journal homepage: [www.elsevier.com/locate/radcr](http://www.elsevier.com/locate/radcr)

## Case Report

# Transcatheter arterial embolization for initial hemostasis in a hemodynamically unstable patient with mesenteric hemorrhage: A case report

Rakuhei Nakama, MD<sup>a,b,\*</sup>, Yoshimitsu Izawa, MD, PhD<sup>a</sup>, Dai Kujirai, MD<sup>a</sup>, Toshiaki Yagami, MD<sup>b</sup>, Isao Kono, MD<sup>b</sup>, Keiichi Tanimura, MD<sup>b</sup>, Masanori Honda, MD<sup>b</sup>, Kenichi Kase, MD<sup>a</sup>, Alan Kawarai Lefor, MD, MPH, PhD<sup>c</sup>

<sup>a</sup>Department of Emergency Medicine, Saiseikai Utsunomiya Hospital, 911-1 Takebayashi-machi, Utsunomiya, Tochigi 321-0974, Japan

<sup>b</sup>Department of Radiology, Saiseikai Utsunomiya Hospital, 911-1 Takebayashi-machi, Utsunomiya, Tochigi 321-0974, Japan

<sup>c</sup>Department of Surgery, Jichi Medical University, 3311-1 Yakushiji, Shimotsuke, Tochigi 329-0498, Japan

## ARTICLE INFO

## Article history:

Received 30 October 2018

Revised 3 November 2018

Accepted 5 November 2018

Available online 22 November 2018

## Keywords:

Transcatheter arterial embolization  
Traumatic mesenteric injury

## ABSTRACT

Surgical treatment of mesenteric injuries is necessary to control hemorrhage, manage bowel injuries, and evaluate bowel perfusion. It has recently been suggested that some patients can be managed with transcatheter arterial embolization (TAE) for initial hemostasis. We present a hemodynamically unstable patient who was initially managed by TAE for traumatic mesenteric hemorrhage. A 60-year-old man was injured in a motor vehicle accident and transported to our facility. On arrival, the patient was hemodynamically stable, and had abdominal pain. Physical examination revealed a seatbelt sign on the lower abdomen. A contrast-enhanced computed tomography (CT) scan showed intra-abdominal hemorrhage, mesenteric hematoma, and a giant-pseudoaneurysm, but no intra-abdominal free air or changes in the appearance of the bowel wall. After the CT scan, his vital signs deteriorated and surgical intervention was considered, but TAE was performed to control the hemorrhage. After TAE, the patient was hemodynamically stable and had no abdominal tenderness. A follow-up CT scan was performed 2 days later which showed partial necrosis of the transverse colon and some free air. Resection of the injured transverse colon with primary anastomosis was performed. The patient improved and was discharged 35 days after injury. TAE can be effective as the initial hemostatic procedure in patients with traumatic mesenteric hemorrhage.

© 2018 The Authors. Published by Elsevier Inc. on behalf of University of Washington.

This is an open access article under the CC BY-NC-ND license.

(<http://creativecommons.org/licenses/by-nc-nd/4.0/>)

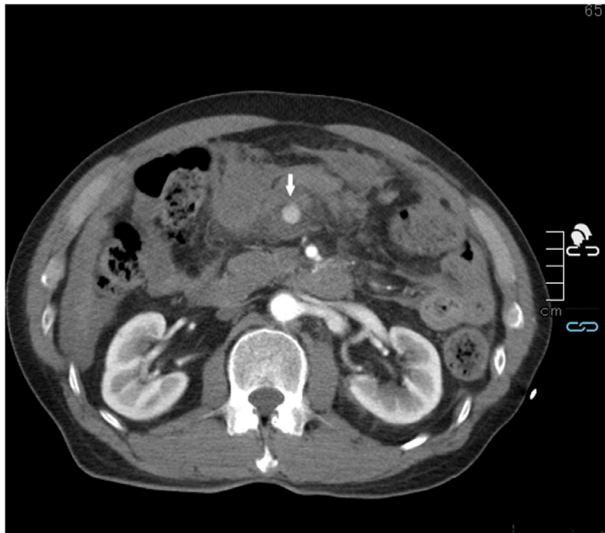**Conflict of Interest:** The authors declare that they have no conflicts of interest.

\* Corresponding author.

E-mail address: [r.n.emergency0611@gmail.com](mailto:r.n.emergency0611@gmail.com) (R. Nakama).

<https://doi.org/10.1016/j.radcr.2018.11.003>

1930-0433/© 2018 The Authors. Published by Elsevier Inc. on behalf of University of Washington. This is an open access article under the CC BY-NC-ND license. (<http://creativecommons.org/licenses/by-nc-nd/4.0/>)



**Fig. 1 – Contrast-enhanced computed tomography scan showed a pseudoaneurysm (arrow) and mesenteric hematoma.**

## Introduction

Surgical treatment of mesenteric injuries is necessary to control hemorrhage, identify bowel injuries, and evaluate bowel perfusion. It has recently been suggested that some patients can be managed with transcatheter arterial embolization (TAE) and careful repeat evaluation [1]. TAE can be the first-line therapy for initial hemostasis in selected patients, especially if operative management is delayed. We present a hemodynamically unstable patient who was initially managed by TAE for traumatic mesenteric bleeding.

## Case report

A 60-year-old man was injured in a motor vehicle accident and transported by the helicopter emergency medical service. *En route*, the systolic blood pressure (BP) dropped to less than 60 mm Hg. He was treated with fluid administration which resulted in stabilization of his hemodynamic status. Ultrasound in the field showed intra-abdominal fluid and he was suspected to have intra-abdominal hemorrhage.

On arrival at the hospital, his vital signs : BP 104/65 mm Hg, heart rate 78/min, respiratory rate 20/min, and oxygen saturation 100% (10 L mask). He complained of abdominal pain and physical examination revealed a seatbelt sign on the lower abdomen. Although his hemodynamic status was relatively stable, abdominal sonography detected massive intra-abdominal hemorrhage and a 5-French sheath was placed in the right femoral artery as access for TAE or resuscitative endovascular balloon of the aorta (REBOA). A contrast-enhanced computed tomography (CT) scan of the abdomen was performed to evaluate the patient, which showed intra-abdominal hemorrhage, mesenteric hematoma and a giant-pseudoaneurysm,

but did not suggest a bowel injury (Fig. 1). There was no intra-abdominal free air or change in the appearance of the bowel wall. Evaluation showed no central nervous system, chest, or extremity injuries. The patient was returned to the emergency room and the BP gradually decreased despite continued aggressive fluid administration. REBOA was immediately placed in the left femoral artery and inflated, and emergency laparotomy was considered. TAE was then performed to control the hemorrhage.

The superior mesenteric artery was selectively cannulated using a shepherd-hook catheter, and a large pseudoaneurysm of a branch of the middle colic artery was visible on angiography (Fig. 2A). A vessel distal to this pseudoaneurysm was cannulated, using a microguidewire (Silverspeed 14. Ev3 Inc. Irvine, CA) and microcatheter (Lighthouse. Piolax Medical Devices, Inc., Kanagawa, Japan). The proximal and distal sides were embolized using detachable microcoils (Galaxy, Codman & Shurtleff, Raynham, MA). Following deployment of the coils, the pseudoaneurysm was no longer visible on angiography (Fig. 2B), and the vital signs improved. The REBOA was then deflated.

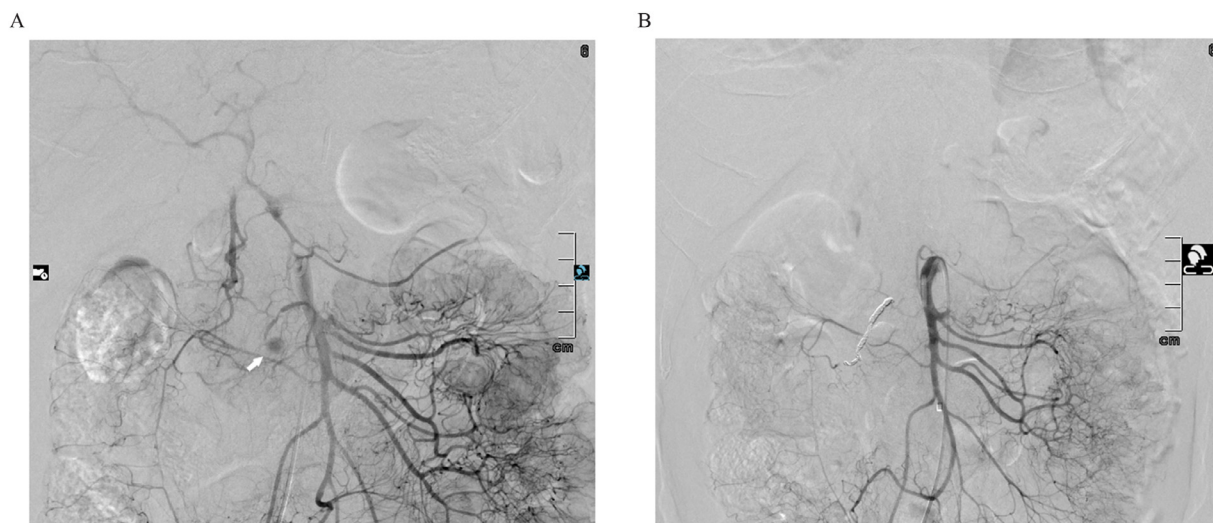
His vital signs remained stable and the abdomen was distended but there was no tenderness 2 days after TAE. Although there was no suggestion of a bowel injury, we performed a follow-up CT scan which showed that a lack of enhancement in the wall of the transverse colon, with a small amount of free air (Fig. 3). Exploratory laparotomy was then performed, and we found a thin, dark circumferential area in the wall of the transverse colon. The pseudoaneurysm was seen including the microcoils nearby. Resection and primary anastomosis of the injured transverse colon were performed. He had transient delayed gastric emptying postoperatively, and was discharged home 35 days after injury.

## Discussion

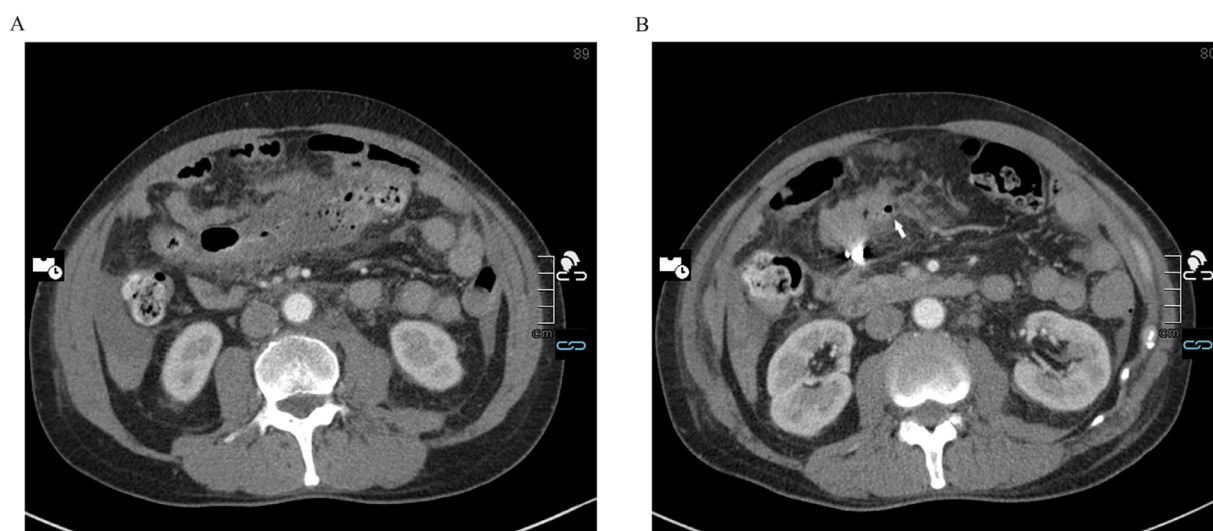
TAE is widely used to control traumatic bleeding as a hemostatic procedure and has been used in many situations. Recently, there are a number of reports that TAE is useful in the treatment of patients with mesenteric injuries [1–5]. TAE has the some of the advantages of surgical control of bleeding, and is also minimally invasive. Initial hemostasis by TAE may make surgical exploration easier [4] because active bleeding is stopped by the TAE. In this patient, a mesenteric injury with hemodynamic instability was initially controlled by TAE. Laparotomy was necessary 2 days later for bowel wall ischemia.

Rapid control of active bleeding is the most important first step to treat patients with traumatic injuries. In hemodynamically unstable trauma patients, time delay to therapeutic intervention has been shown to be independently associated with increased mortality [6]. Thus, any hemostatic procedures, surgery or TAE, should be promptly performed.

It is true that mesenteric injuries often accompany bowel injuries, and laparotomy is essential in these patients as first-line therapy for contamination control, especially for hemodynamically unstable patients. However, in selected patients, TAE can be effective for initial hemostasis, instead of laparotomy.



**Fig. 2 –** Angiography showed a giant pseudoaneurysm (arrow) of a branch of the middle colic artery (A). After embolization, the pseudoaneurysm was no longer visible angiographically (B).



**Fig. 3 –** Contrast-enhanced computed tomography scan two days after transcatheter arterial embolization showed no enhancement of the transverse colon (A) and free air (arrow) (B).

After TAE, patients must be carefully evaluated with serial physical examinations, careful evaluation of vital signs and urine output, and imaging studies as indicated for early detection of delayed bowel injuries. If bowel injuries are suspected, surgical management is usually indicated. If close follow-up does not suggest bowel injury, these patients can be managed solely by TAE [1–3]. In the present patient, CT scan was consistent with ischemia of the transverse colon 2 days after TAE, and surgical resection was performed. The patient recovered after the serial use of TAE and resection.

In conclusion, TAE is a valuable procedure for hemostasis in selected patients. We initially select TAE or surgery based on a number of factors including patient stability, resource availability, and which approach is likely to provide the most

rapid control of bleeding to allow stabilization of the patient's hemodynamic status

#### REFERENCES

- [1] Hagiwara A, Takasu A. Transcatheter arterial embolization is effective for mesenteric arterial hemorrhage in trauma. *Emerg Radiol* 2009;16:403–6.
- [2] Asayama Y, Matsumoto S, Isoda T, Kunitake N, Nakashima H. A case of traumatic mesenteric bleeding controlled by only transcatheter arterial embolization. *Cardiovasc Intervent Radiol* 2005;28:256–8.

- [3] Kakizawa H, Toyota N, Hieda M, Ishida M, Takeda T, Matsuura K, et al. Traumatic mesenteric bleeding managed solely with transcatheter embolization. *Radiat Med* 2007;25:295–8.
- [4] Ghelfi J, Frandon J, Barbois S, Vendrell A, Rodiere M, Sengel C, et al. Arterial embolization in the management of mesenteric bleeding secondary to blunt abdominal trauma. *Cardiovasc Intervent Radiol* 2016;39:683–9.
- [5] Shin JS, Shin JH, Ko HK, Kim JW, Yoon HK. Transcatheter arterial embolization for traumatic mesenteric bleeding: a 15-year, single-center experience. *Diagn Interv Radiol* 2016;22:385–9.
- [6] Howell GM, Peitzman AB, Nirula R, Rosengart MR, Alarcon LH, Billiar TR, et al. Delay to therapeutic interventional radiology post-injury: time is of the essence. *J Trauma* 2010;68:1296–300.