

Letter to the editor

Letter to the editor on “Catastrophic failure of a dual mobility bearing in a revision total hip arthroplasty”

We read with interest the article “Catastrophic failure of a dual mobility bearing in a revision total hip arthroplasty” by Brazier *et al.*, with this case report demanding attention due to its headline title. The authors present their personal use of a dual mobility (DM) system, which is found to be “off label” and not recommended by any manufacturer or by the French orthopedic community [1–11]. Consequently, we would like to widen the discussion and raise numerous concerns.

The first concern is about the cup inclination. As explained by the authors, the acetabular component orientation might influence the wear vector and cause accelerated polyethylene wear. The wear rate of a DM system may decrease when the abduction angle is increased by up to 65 degrees as demonstrated in vitro by Loving *et al* [12], but it seems logical that with an extreme abduction (70–75 degrees), the risk of the liner wear will become greater. Reading this article shows that the authors were aware of this concern; however, they describe changing only the bearing couple without changing the cup inclination. Figure 1 demonstrates the previous cup to be in an incorrect position. Author's case report figure 2 is annotated as “AP pelvis radiograph (a) completed 4 weeks after revision surgery. ... demonstrating acceptable position of components”. How can the authors state that the position of the component is now acceptable if the previous incorrectly positioned cup has not been removed?

The second concern is about the use of a liner of incorrect size. By magnifying their postoperative radiograph and drawing the position of the center of the head related to the center of the cup, it can be seen that the femoral head was “off centered” laterally and superiorly. The insert was not coupled with the cup at 4 weeks. The images of the retrieved implants also demonstrate a “mushroom” deformity, as if it was not fitted inside the cup but extruded as we can suspect on the enlarged picture.

Third, the authors state that “Intraoperatively, we determined ... that the monoblock acetabular component was also well fixed with no visual evidence of damage to the polished surface of the acetabular shell. The decision was made to leave

it in place.” We wonder what the intraoperative criteria were to determine how much wear or scratches were detectable.

To conclude, this clinical case lists a number of errors performed while revising this type of failed arthroplasty. It is illogical to leave in place an obviously poorly positioned cup, which is highly likely to lead to accelerated wear due to unacceptable edge-loading, and accentuate this by combining it with the use of a DM liner that was not compatible with the worn metallic shell. This type of misuse of implants has been seen before in cases described by Riviere *et al* [13] and Hwang *et al* [14]. Early failure was demonstrated while revising a failed resurfacing arthroplasty using a mobile liner initially designed for another DM shell, coupled with the previous cup left in situ. A subsequent letter to the editor [15] confirmed that the implantation of a DM liner in a cup not designed for DM must not be performed. It is incompatible to implant a DM liner in a large-diameter Metal on Metal cup, which was the case in the current case report.

In conclusion, we clearly disagree with the conclusions of this case report. Such an off-label use of DM has to be blamed. Perhaps the title should have read “Cumulative technical errors and poor decision-making: DM concept will not save you.”

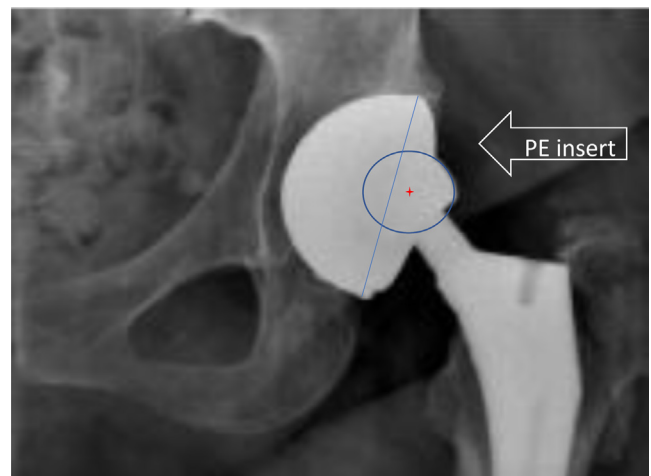


Figure 1. Magnifying postoperative radiograph presented in author's case report figure 2.

DOI of original article: <https://doi.org/10.1016/j.artd.2018.03.004>.

One or more of the authors of this paper have disclosed potential or pertinent conflicts of interest, which may include receipt of payment, either direct or indirect, institutional support, or association with an entity in the biomedical field which may be perceived to have potential conflict of interest with this work. For full disclosure statements refer to <https://doi.org/10.1016/j.artd.2018.11.005>.

<https://doi.org/10.1016/j.artd.2018.11.005>

2352-3441/Copyright © 2019 The Authors. Published by Elsevier Inc. on behalf of The American Association of Hip and Knee Surgeons. This is an open access article under the CC BY-NC-ND license (<http://creativecommons.org/licenses/by-nc-nd/4.0/>).

References

- [1] Caton JH, Prudhon JL, Ferreira A, Aslanian T, Verdier R. A comparative and retrospective study of three hundred and twenty primary Charnley type hip replacements with a minimum follow up of ten years to assess whether a dual mobility cup has a decreased dislocation risk. *Int Orthop* 2014;38:1125.
- [2] Philippot R, Camilleri JP, Boyer B, Adam P, Farizon F. The use of a dual-articulation acetabular cup system to prevent dislocation after primary total hip arthroplasty: analysis of 384 cases at a mean follow-up of 15 years. *Int Orthop* 2009;33:927.
- [3] Prudhon JL, Ferreira A, Verdier R. Dual mobility cup: dislocation rate and survivorship at ten years of follow-up. *Int Orthop* 2013;37:2345.
- [4] Combes A, Migaud H, Girard J, Duhamel A, Fessy MH. Low rate of dislocation of dual-mobility cups in primary total hip arthroplasty. *Clin Orthop Relat Res* 2013;471:3891.
- [5] Epinette JA, Beracassat R, Tracol P, Pagazani G, Vandebussche E. Are modern dual mobility cups a valuable option in reducing instability after primary hip arthroplasty, even in younger patients? *J Arthroplasty* 2014;29:1323.
- [6] Philippot R, Adam P, Farizon F, Fessy M-H, Bousquet G. Survie à dix ans d'une cupule double mobilité non cimentée. *Rev Chir Orthop Reparatrice Appar Mot* 2006;92:326.
- [7] Guyen O, Pibarot V, Vaz G, et al. Unconstrained tripolar implants for primary total hip arthroplasty in patients at risk for dislocation. *J Arthroplasty* 2007;22:849.
- [8] Lautridou C, Lebel B, Burdin G, Vielpau C. Survie à 16,5 ans de recul moyen de la cupule, double mobilité, non scellée de Bousquet dans l'arthroplastie totale de hanche. Série historique de 437 hanches. *Rev Chir Orthop Reparatrice Appar Mot* 2008;94:731.
- [9] Vielpeau C, Lebel B, Ardouin L, Burdin G, Lautridou C. The dual mobility socket concept: experience with 668 cases. *Int Orthop* 2011;35:225.
- [10] Leclercq S, Benoit JY, de Rosa JP, et al. Evora chromium-cobalt dual mobility socket: results at a minimum 10 years' follow-up. *Orthop Traumatol Surg Res* 2013;99:758.
- [11] Vermersch T, Viste A, Desmarchelier R, Fessy MH. Prospective longitudinal study of one hundred patients with total hip arthroplasty using a second-generation cementless dual-mobility cup. *Int Orthop* 2015;39:2097.
- [12] Loving L, Lee RK, Herrera L, Essner AP, Nevelos JE. Wear performance evaluation of a contemporary dual mobility hip bearing using multiple hip simulator testing conditions. *J Arthroplasty* 2013;28(6):1041.
- [13] Riviere C, Lavigne M, Alghamdi A, Vendittoli PA. Early failure of metal-on-metal large-diameter head total hip arthroplasty revised with a dual-mobility bearing: a case report. *JBJS Case Connect* 2013;3(3 Suppl 9):e951.
- [14] Hwang JH, Kim SM, Oh KJ, Kim Y. Dislocations after use of dual-mobility cups in cementless primary total hip arthroplasty: prospective multicentre series. *Int Orthop* 2018;42(4):761.
- [15] Viste A, Girard J, Epinette JA, Migaud H, Fessy MH. Letter to the editor on "Dislocations after use of dual-mobility cups in cementless primary total hip arthroplasty: prospective multicentre series" by Hwang, et al. *Int Orthop* 2018;42(2):451.

Jean Louis Prudhon, MD^{a,*}, Domenico Tigani, MD^b,
Thomas Neri, MD^{c,d}, André Ferreira, MD^e, Jean Alain Epinette, MD^f,
Michel H. Fessy, MD^g, Jacques H. Caton, MD^h

^a Centre Osteo Articulaire Echirolles, Grenoble, France

^b Direttore UOC Ortopedia, Ospedale Maggiore, Bologna, Italy

^c Sydney Orthopaedic Research Institute, Australia

^d Inter-university Laboratory of Human Movement Biology (LIBM EA 7424), University of Lyon - Jean Monnet, France

^e Clinique du Parc-Lyon, Lyon, France

^f Orthopaedic Research and Imaging Centre in Arthroplasty Houdain, France

^g Centre Hospitalier Lyon Sud Pierre Benite, France

^h Institut d'Orthopédie, Caluire, France

* Corresponding author. Centre Osteo Articulaire Echirolles, 5 Rue Raoul Blanchard, Grenoble, 38000 France. Tel.: +33 6 07 17 56 96. E-mail address: jean-louis.prudhon@wanadoo.fr (J. Louis Prudhon).

23 October 2018

Available online 11 March 2019