

Contents lists available at [ScienceDirect](http://www.sciencedirect.com)

International Journal of Surgery Case Reports

journal homepage: www.casereports.com

Scerosing stromal tumor of the ovary treated with 2-incision total laparoscopic cystectomy



Shigenori Furukawa*, Kiyoshi Kanno, Manabu Kojima, Miki Ohara, Shu Soeda, Satoshi Suzuki, Takafumi Watanabe, Hiroshi Nishiyama, Tsuyoshi Honda, Keiya Fujimori

Department of Obstetrics and Gynecology, Fukushima Medical University School of Medicine, Fukushima 960-1295, Japan

ARTICLE INFO

Article history:

Received 9 January 2015

Received in revised form 30 January 2015

Accepted 2 February 2015

Available online 16 February 2015

Keywords:

Scerosing stromal tumor

Ultrasonography

Color Doppler

2-Incision laparoscopy

ABSTRACT

Scerosing stromal tumor (SST) is an extremely rare benign tumor of the ovary that is derived from the sex cord stroma [1,2] and occurs in young women [3–11]. Preoperative diagnosis of the tumor is difficult as it often mimics a malignant tumor. Oophorectomy is usually performed in many cases of young women [3], and diagnosis of SST is made based on post-operative pathological examination. Laparoscopic surgery is seldom performed in SST cases. Here, we report a case of SST of the ovary in an 18-year-old girl who was diagnosed by preoperative imaging and underwent laparoscopic cystectomy. Accurate preoperative imaging helped to perform minimally invasive surgery for SST.

© 2015 The Authors. Published by Elsevier Ltd. on behalf of Surgical Associates Ltd. This is an open access article under the CC BY-NC-ND license (<http://creativecommons.org/licenses/by-nc-nd/4.0/>).

1. Case report

An 18-year-old girl visited our hospital with a complaint of irregular menses. Ultrasonography revealed a 5 cm mass in the right pelvic cavity. As she had no symptoms except for irregular menses, no further examination or operation was performed. Nine months later, she visited our hospital again. The mass was enlarged, and she hoped to have an operation before enrolling to university. In order to determine the characterization of the mass, hormone assays, tumor marker assays, ultrasonography, color Doppler imaging, computed tomography (CT), and magnetic resonance imaging (MRI) were performed. All results for tumor markers (CA125, CEA, CA19-9, AFP) and ovarian hormone assay (LH, FSH, PRL, E2) were normal.

2. Gray-scale and color Doppler findings

Transabdominal ultrasound scanning showed a 6 cm sized echogenic mass separated from the uterus (Fig. 1). Color Doppler showed peripheral hypervascularity. Pulsed Doppler was also performed, which showed a peak systolic velocity of 33.3 cm/s, and resistance index of 0.61. The uterus and right ovary were within normal size range.

3. CT and MRI findings

CT showed a well-circumscribed round tumor derived from the left ovary (Fig. 2). In the arterial phase, the margin of the tumor was well enhanced similar to that of cotton-wool, unlike the central area, which was not enhanced. MRI of the enhanced region found on CT revealed flow voids on T2-weighted images. Thus we predicted the hypervascularity of the tumor. The central area of the tumor had high intensity which suggested edematous stroma of the region (Fig. 3). These mentioned findings suggested that the left ovarian tumor was a scerosing stromal tumor. As we could not exclude the possibility of malignancy, we decided to perform total laparoscopic cystectomy via two-incision using three ports under pathological diagnosis during operation.

4. Operative findings and clinical course

The total laparoscopic cystectomy was performed under general anesthesia. We made two incisions in the navel and left lower quadrant. A lap protector was inserted through the transumbilical incision and an EZ access was mounted on the lap protector. Two 5 mm trocars were then placed on the EZ access. A 12 mm trocar was inserted through the left lower incision. We confirmed that the uterus and right ovary were normal sized. The left ovarian tumor was white and solid (Fig. 4). The size of the tumor was about 6 cm and the surface was hypervascular. We made an incision into the surface with monopolar cautery. Because the tumor was hemorrhagic, we stopped the bleeding from the surface by using a bipolar energy device during operation. A cystectomy was performed and the resected tumor was inserted into the endobag and removed.

* Corresponding author. Tel.: +81 245471290; fax: +81 24 548 3878.
E-mail address: s-furu@infoseek.jp (S. Furukawa).

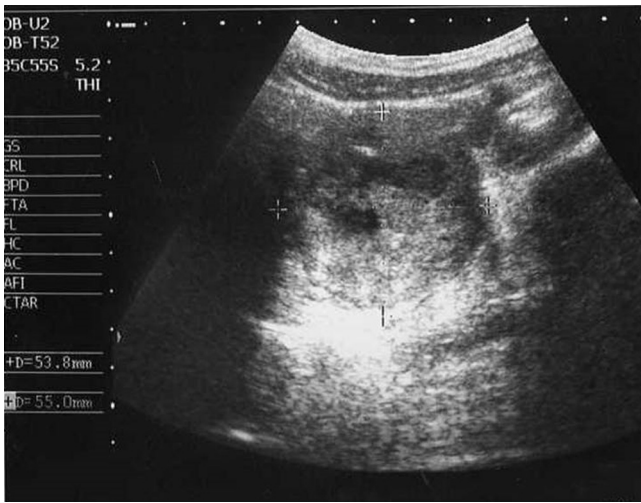

Fig. 1. USG shows a left ovarian solid tumor. The tumor has sharp edges with partial hypochoic inner structure.

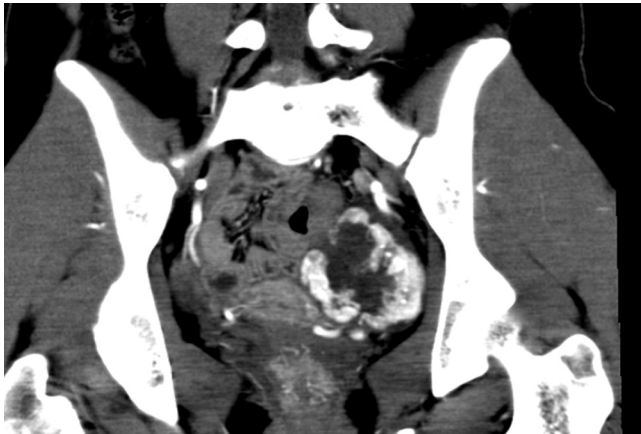


Fig. 2. Contrast-enhanced CT shows a left ovarian tumor with early peripheral enhancement reflecting hypervascularity.

via the umbilical incision. The left ovary was sutured with 2-0 vicryl to stop the bleeding. The tumor was pathologically diagnosed as ovarian fibroma during operation. Subsequently, the peritoneal incisions were closed and the operation was completed. The post-operative course was uneventful and the patient was discharged on day 3.

5. Pathological findings

The tumor was entirely solid and yellowish. The surface of the cut sections of the tumor was divided into compartments by white fibrous tissue. Postoperative microscopic findings (Fig. 5) revealed an irregular distribution of spindle cells, foamy cells, and cells that had a round nuclei and clear cytoplasm, which formed cellular pseudobulbes separated by fibrous stroma. As fibrous sections were mainly seen in the pathology during the operation, the tumor was assumed to have mimicked a fibroma. No mitoses were observed. Thus, we diagnosed the tumor as a stromal sclerosing tumor. Three years after the operation, the bilateral ovaries remained within normal size and there was no sign of recurrence.

6. Discussion

SST of the ovary is an extremely rare benign tumor and is derived from the sex-cord stroma. Eighty percent of cases occur in the sec-

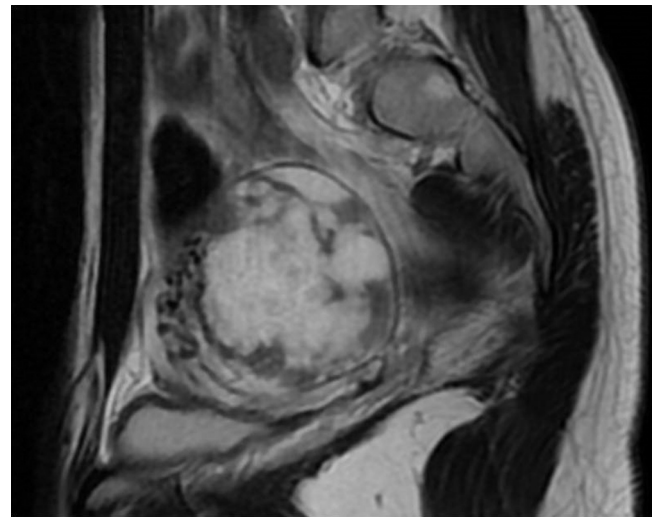


Fig. 3. Unenhanced MRI (sagittal). Central area of the tumor shows high intensity suggesting an edematous stroma of the tumor. Low intensity part of the tumormay correspond to fibrous tissue.

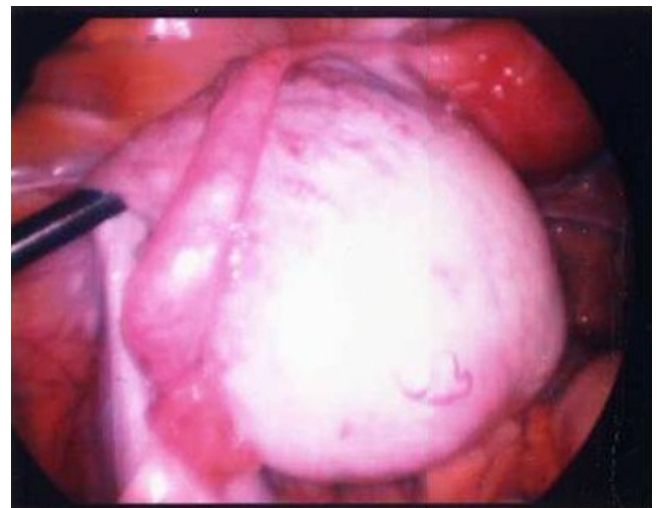


Fig. 4. Macroscopic finding of the left ovarian tumor (laparoscopy). Left ovarian tumor is white and solid. The surface is hypervascular as preoperative imaging suggested. 2-incision total laparoscopic cystectomy was performed.

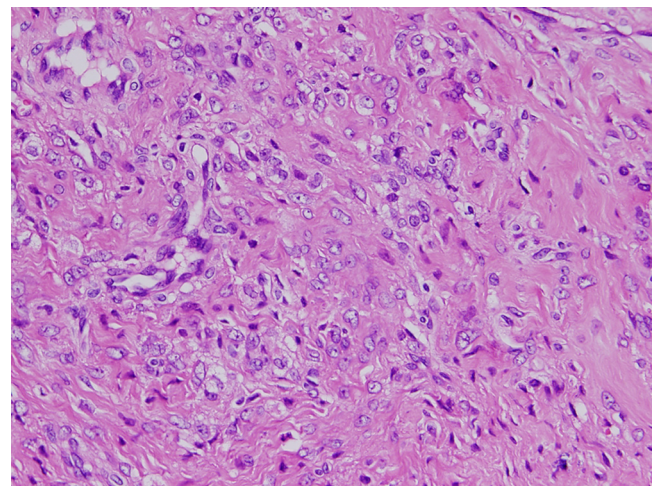


Fig. 5. Pathological findings of the SST of the left ovary (×400). The irregular distribution of spindle cells, foamy cells, and cells with round nuclei and clear cytoplasm forming cellular pseudobulbes separated by fibrous stroma.

ond and third decades, with a mean age of 28 years old [12]. As with our current case, there are some reports on SST occurring in teenagers [3,4], with menstrual irregularities being the most common symptom. Many cases of SST are unilateral [13–15] and rarely bilateral [3,16,17]. It is often reported that clinicians were unable to rule out malignant tumor with preoperative images and many cases had to undergo oophorectomy.

In our case we first preoperatively performed several imaging studies such as ultrasonography with color Doppler, CT and MRI and suspected a unilateral SST of the ovary. Color Doppler showed higher peripheral vascularity with vessels flowing into the central area of the ovary. Some previous reports have shown that the presence of marked peripheral vascularity is useful for diagnosis of SST of the ovary [7,8]. After ultrasonography, we confirmed peripheral hypervascularity by enhanced CT and flow voids by T2-weighted MRI. On T2-weighted MRI, hypointensity of the peripheral part and hyperintensity of the central part were observed. Hypervascularity on enhanced CT and flow voids on MRI supported the preoperative diagnosis of SST [3,8,19,20]. Jung et al. showed that hypointensity of the peripheral part reflects a compressed ovarian cortex due to a slow-growing tumor, and hyperintensity and enhancement of the central portion reflects the cellular areas [19]. The imaging findings in our case strongly suggested SST of the ovary.

In order to preserve the function of bilateral ovaries, we next selected a total laparoscopic cystectomy via two incisions as surgical procedure, unlike many cases of SST which undergo oophorectomy, as previously mentioned. It is rare for such patients to undergo laparoscopic cystectomy as almost all cases who receive laparoscopy undergo laparoscopic adnexectomy [12]. Thus, despite young age of patients, preservation of normal ovarian tissue around SST was rarely performed. To our knowledge, at present only one case of laparoscopic cystectomy has been reported [7]. In the current case, we were able to perform laparoscopic cystectomy by preoperative diagnosis. At the time of therapy of the ovarian SST, accurate preoperative diagnosis by imaging helped to prevent the resection of the normal part of the ovary. Furthermore, in order to avoid dissemination, we think that SST need to be contained in the endobag before removal through the small wound at the time of laparoscopic operation.

In conclusion, a combination of color Doppler, enhanced CT and MRI could preoperatively diagnose SST of the ovary. Such a diagnosis enabled us to perform a low invasive surgery, total laparoscopic cystectomy, and preserve the function of the bilateral ovaries of a young woman.

Conflicts of interest

The authors declare that there are no conflicts of interest.

Funding

We declare that there are no sources of funding for our research.

Author contribution

All authors contributed study design and writing. Especially, Shigenori Furukawa and Shu Soeda contributed data collections and data analysis.

Open Access

This article is published Open Access at sciedirect.com. It is distributed under the [IJSCR Supplemental terms and conditions](#), which permits unrestricted non commercial use, distribution, and reproduction in any medium, provided the original authors and source are credited.

Consent

Written informed consent was obtained from the patient for publication of this case report and accompanying images. A copy of the written consent is available for review by the Editor-in-Chief of this journal on request.

References

- [1] A. Chalvardjian, R.E. Scully, Sclerosing stromal tumor of the ovary, *Cancer* 331 (1973) 664–670.
- [2] H. Fox, M. Wells, Haines and Taylor obstetrical and gynecological pathology, 5th ed, Cherrchill Livingstone, New York, 2003, pp. 842–843.
- [3] Y.W. Chang, S.S. Hong, Y.M. Jeon, M.K. Kim, E.S. Suh, Bilateral sclerosing stromal tumor of the ovary in a premenarchal girl, *Pediatr. Radiol.* 39 (2009) 731–734.
- [4] S.M. Park, Y.N. Kim, Y.J. Woo, H.S. Choi, J.S. Lee, S.H. Heo, C.J. Kim, A sclerosing stromal tumor of the ovary with masculinization in a premenarchal girl, *Korean J. Pediatr.* 54 (2011) 224–227.
- [5] H.H. Peng, T.C. Chang, S. Hsueh, Sclerosing stromal tumor of ovary, *Chang Gung Med. J.* 26 (2003) 444–448.
- [6] G. Irvanloo, Z. Nozarian, B. Sarrafpour, P. Motahhary, Sclerosing stromal tumor of the ovary, *Arch. Iran. Med.* 11 (2008) 561–562.
- [7] B. Deval, A. Rafii, E. Darai, D. Hugol, J.N. Buy, Sclerosing stromal tumor of the ovary: color Doppler findings, *Ultrasound Obstet. Gynecol.* 22 (2003) 531–534.
- [8] P. Torricelli, A.C. Lombardi, F. Boselli, G. Rossi, Sclerosing stromal tumor of the ovary: US, CT, and MRI findings, *Abdom. Imaging.* 27 (2002) 588–591.
- [9] O. Zekioglu, N. Ozdemir, C. Terek, A. Ozsaran, Y. Dikmen, Clinicopathological and immunohistochemical analysis of sclerosing stromal tumours of the ovary, *Arch. Gynecol. Obstet.* 282 (2010) 671–676.
- [10] M. Khanna, A. Khanna, M. Manjari, Sclerosing Stromal Tumor of Ovary: a Case Report, *Case Rep. Pathol.* 592 (2012) 836, <http://dx.doi.org/10.1155/2012/592836>.
- [11] E. Yen, M. Deen, I. Marshall, Youngest reported patient presenting with an androgen producing sclerosing stromal ovarian tumor, *J. Pediatr. Adolesc. Gynecol.* 13 (2014) 293.
- [12] E.I. Kaygusuz, S. Cesur, H. Cetiner, H. Yavuz, N. Koc, Sclerosing stromal tumour in young women: clinicopathologic and immunohistochemical spectrum, *J. Clin. Diagn. Res.* 7 (2013) 1932–1935.
- [13] A. Qureshi, A. Raza, N. Kayani, The morphologic and immunohistochemical spectrum of 16 cases of sclerosing stromal tumor of the ovary, *Indian J. Pathol. Microbiol.* 53 (2010) 658–660.
- [14] J. Korczyński, L. Gottwald, G. Pasz-Walczak, R. Kubiak, A. Bięńkiewicz, Sclerosing stromal tumor of the ovary in a 30-year-old woman: a case report and review of the literature, *Ginekol. Pol.* 76 (2005) 471–475.
- [15] S. Bouraoui, C. Ben Fadhl, K. Bellil, H. Guettiti-Tounsi, A. Mekni, N. Kchir, Sclerosing stromal tumor of the ovary. report of 3 cases, *Tunis. Med.* 82 (2004) 1111–1115.
- [16] S. Kawachi, T. Tsuji, T. Kaku, Sclerosing stromal tumor of the ovary: a clinicopathologic, immunohistochemical, ultrastructural, and cytogenetic analysis with special reference to its vasculature, *Am. J. Surg. Pathol.* 22 (1998) 83–92.
- [17] S.M. Ismail, S.M. Walker, Bilateral virilizing sclerosing stromal tumors of the ovary in a pregnant woman with Gorlin's syndrome: implications for pathogenesis of ovarian stromal neoplasms, *Histopathology* 17 (1990) 159–163.
- [18] S.E. Jung, S.E. Rha, J.M. Lee, S.Y. Park, S.N. Oh, K.S. Cho, E.J. Lee, J.Y. Byun, S.T. Hahn, CT and MRI findings of sex cord-stromal tumor of the ovary, *AJR* 185 (2005) 207–215.
- [19] H. Wada, A. Mitsumori, T. Hyoudou, S. Matsubara, M. Yamamoto, M. Fujisawa, N. Akamatsu, S. Kanazawa, Sclerosing stromal tumor of the ovary with atypical Magnetic resonance imaging findings in a middle-aged woman, *Jpn. J. Radiol* 27 (2009) 247–251.