



Research Paper

Regression of Some High-risk Features of Age-related Macular Degeneration (AMD) in Patients Receiving Intensive Statin Treatment



Demetrios G. Vavvas^{*}, Anthony B. Daniels^{*}, Zoi G. Kapsala, Jeremy W. Goldfarb, Emmanuel Ganotakis, John I. Loewenstein, Lucy H. Young, Evangelos S. Gragoudas, Dean Elliott, Ivana K. Kim, Miltiadis K. Tsilimbaris^{*}, Joan W. Miller^{*}

Retina Service, Department of Ophthalmology, Mass. Eye and Ear Infirmary, Harvard Medical School, Boston, MA, USA
Retina Service, Department of Ophthalmology, University of Crete, Heraklion, Crete, Greece

ARTICLE INFO

Article history:

Received 19 November 2015
Received in revised form 26 January 2016
Accepted 27 January 2016
Available online 4 February 2016

Keywords:

AMD
Statins
High-dose
Reversal
Soft-drusen
Vision gain

ABSTRACT

Importance: Age-related macular degeneration (AMD) remains the leading cause of blindness in developed countries, and affects more than 150 million worldwide. Despite effective anti-angiogenic therapies for the less prevalent neovascular form of AMD, treatments are lacking for the more prevalent dry form. Similarities in risk factors and pathogenesis between AMD and atherosclerosis have led investigators to study the effects of statins on AMD incidence and progression with mixed results. A limitation of these studies has been the heterogeneity of AMD disease and the lack of standardization in statin dosage.

Objective: We were interested in studying the effects of high-dose statins, similar to those showing regression of atherosclerotic plaques, in AMD.

Design: Pilot multicenter open-label prospective clinical study of 26 patients with diagnosis of AMD and the presence of many large, soft drusenoid deposits. Patients received 80 mg of atorvastatin daily and were monitored at baseline and every 3 months with complete ophthalmologic exam, best corrected visual acuity (VA), fundus photographs, optical coherence tomography (OCT), and blood work (AST, ALT, CPK, total cholesterol, TSH, creatinine, as well as a pregnancy test for premenopausal women).

Results: Twenty-three subjects completed a minimum follow-up of 12 months. High-dose atorvastatin resulted in regression of drusen deposits associated with vision gain (+3.3 letters, $p = 0.06$) in 10 patients. No subjects progressed to advanced neovascular AMD.

Conclusions: High-dose statins may result in resolution of drusenoid pigment epithelial detachments (PEDs) and improvement in VA, without atrophy or neovascularization in a high-risk subgroup of AMD patients. Confirmation from larger studies is warranted.

© 2016 The Authors. Published by Elsevier B.V. This is an open access article under the CC BY-NC-ND license (<http://creativecommons.org/licenses/by-nc-nd/4.0/>).

1. Introduction

Age-related macular degeneration (AMD) is the leading cause of irreversible vision loss in the developed world (Miller, 2013; Wong et al., 2014). The non-neovascular or “dry” form accounts for 85% of all AMD and is characterized by accumulation of extracellular deposits, termed drusen (Sarks et al., 1994), between the basal lamina of retinal pigmented epithelium (RPE) and inner collagenous layer of Bruch's membrane (BM), which is the inner wall of the choroid. Progression to advanced AMD involves atrophy of the RPE and overlying photoreceptors (geographic atrophy), and/or choroidal neovascularization (neovascular or “wet” AMD). While there are effective anti-angiogenic

therapies for the less prevalent neovascular AMD, there are no effective treatments for the more prevalent dry form (Miller, 2013).

Several clinical and epidemiological studies have established cardiovascular risk factors (including smoking, hypertension, and serum lipid status) to be associated with AMD development and progression, and both diseases share susceptibility genes (Miller, 2013; Yip et al., 2015; Tomany et al., 2004; Sene and Apte, 2014; Sene et al., 2015). This suggests that both diseases share similarities in their pathogenesis, and that interventions that reduce cardiovascular disease risk factors may be useful in AMD.

Bruch's membrane (BM) lies under the RPE and forms the inner margin of the choriocapillaris, and thus is considered the structural analog of the vascular intima (Curcio et al., 2001). Analogous aging changes in the vascular intima and BM are thought to relate to the pathogenesis of atherosclerosis and AMD, respectively (Sivaprasad et al., 2005). Similarities in the protein molecular composition of drusen and

^{*} Corresponding authors at: 243 Charles St., Boston, MA 02114, USA.
E-mail addresses: vavvas@meei.harvard.edu (D.G. Vavvas),
joan_miller@meei.harvard.edu (J.W. Miller).

arteriosclerotic deposits corroborate this perception (Mullins et al., 2000). In both conditions, apolipoprotein B (apo B) and cholesterol accumulate, with subsequent modification, oxidation, and aggregation. Drusen components are derived from local tissues (retina/RPE secreting apo B,E-containing lipoproteins (Wang et al., 2009; Johnson et al., 2011)) and from the circulation (Curcio et al., 2011; Wu et al., 2010), and both AMD and atherosclerotic coronary artery disease involve lipoprotein retention. In AMD, an inflammatory response to the accumulated material may ensue with activation of complement and other components of the immune system, which can lead to atrophy of RPE cells and/or induction of a pro-angiogenic state and neovascular AMD.

Given these observations and similarities between atherosclerosis and AMD, it has been hypothesized that statin treatment may affect AMD status and/or progression (Hall et al., 2001). Statins suppress cholesterol synthesis by inhibiting HMG-CoA reductase (the enzyme catalyzing the rate limiting step in cholesterol biosynthesis). In addition, they increase liver LDL receptors levels (Bilheimer et al., 1983), reduce apo B synthesis (Arad et al., 1990) and suppress prenylation (the addition of hydrophobic molecules to a protein that is a physiologic process that control localization and function) (Kino et al., 2005). Multiple epidemiological studies have examined this relationship with conflicting data (Gehlbach et al., 2009). A 2015 Cochrane report (Gehlbach et al., 2015) concluded that “[evidence is] insufficient to conclude if statins have a role in preventing or delaying the onset or progression of AMD.” A small, proof-of-concept, randomized, placebo-controlled study of the effect of simvastatin on the course of AMD was recently published, and suggested that simvastatin at 40 mg (equivalent to 20 mg atorvastatin) daily may slow progression of early/intermediate AMD, especially for those with the at-risk complement factor H (CFH) genotype CC (Y402H) (Guymer et al., 2013). Another recent study in patients with elevated plasma lipid levels found that statin use for more than a year was associated with an increased hazard for neovascular AMD (VanderBeek et al., 2013), and the authors postulated that these patients were resistant to statin treatment, rather than statins leading to increased risk for neovascular AMD. The Alienor study suggested that elderly patients with high HDL concentration may be at increased risk for AMD; furthermore, it found that HDL dysfunction might be implicated in AMD pathogenesis (Cougnaud-Gregoire et al., 2014). In contrast, data from a recent meta-analysis of three population-based cohorts over a 20-year follow-up period did not show a significant association between lipid levels or lipid pathway genes with the incidence or progression of AMD (Klein et al., 2014a).

A major limitation in almost all studies thus far is the large heterogeneity of AMD disease (more than 100 at-risk genes and several phenotypes) (Miller, 2013; Fritsche et al., 2015) and lack of standardization in statin dosage (Gehlbach et al., 2009, 2015) or lipophilicity (Wu et al., 2010; Chitose et al., 2014; Fong, 2014). There is clear evidence from the cardiovascular literature that statin dose does matter (Cannon et al., 2004; Pitt et al., 1999). The PROVE-IT study (Khush and Waters, 2004) suggested that statin dose may be more important than LDL-c levels, whereas the REVERSAL and ASTEROID trials showed benefit of aggressive over moderate intensity/dosage therapy (Nissen, 2005; Nissen et al., 2006, 2004). The ASTEROID trial even showed regression of coronary atherosclerosis with very high-intensity statin therapy (Nissen et al., 2006). Similarly, Yu et al. showed that intensive but not regular-dose atorvastatin therapy resulted in regression of carotid atherosclerotic disease (Yu et al., 2007) and two magnetic resonance (MR) imaging studies have shown regression of the lipid core of atheromatous plaque after high-dose statin (Kramer et al., 2011; Zhao et al., 2011).

Here we present the first evidence that treatment with high dose atorvastatin may result in regression of drusen and improvement of visual acuity (VA) in patients with AMD with high-risk features for progression.

2. Methods

A case report and pilot multicenter phase1–2 prospective interventional study (Mass. Eye and Ear, Boston, United States, and University

of Crete, Heraklion, Greece) were conducted with institutional review board (IRB) approval, and informed consent was obtained from all participants. Since there is some evidence in the literature that hydrophilic statins (such as pravastatin) may not be equivalent to hydrophobic statins (Wu et al., 2010; Chitose et al., 2014; Fong, 2014) we use the hydrophobic atorvastatin (80 mg, daily). Pilot study inclusions were as follows: patients over 50 years of age with diagnosis of AMD and the presence of many large (>300 µm in diameter and more than 100 µm in height) soft drusenoid PEDs. Exclusion criteria were as follows: presence (or history) of significant geographic atrophy or choroidal neovascularization in either eye; other eye diseases that could reduce VA (excluding mild cataract); history of eye surgery (other than cataract extraction); statin therapy (within the previous 2 years) at a dose equivalent to atorvastatin ≥40 mg; history of liver disease, rhabdomyolysis, or allergy to statins; pregnancy or nursing; current use of medications known to interact with statins (e.g., cyclosporine, systemic itraconazole, clarithromycin, HIV protease inhibitors); and elevated transaminases or creatine phosphokinase (CPK) at baseline. Pseudophakia was not a reason for exclusion, unless accompanied by significant posterior capsular opacity. Patients received 80 mg of atorvastatin daily. Baseline complete ophthalmologic exam, best-corrected VA by Early Treatment Diabetic Retinopathy Study (ETDRS) chart, fundus photographs, fundus autofluorescence, optical coherence tomography (OCT) and blood work (AST, ALT, CPK, total cholesterol, TSH, creatinine, as well as a pregnancy test for premenopausal women) were obtained. If there was any suspicion of occult neovascular AMD and FA and ICG were performed. Patients were monitored every 3 months with an eye exam, OCT imaging and AST, ALT, total cholesterol, and CPK monitoring. Best corrected VA acuity (EDTRS) and fundus photography were obtained every 6 months and at exit from the study. Duration of treatment was a minimum of 1 year. Physicians trained in internal medicine were involved in the design of the pilot study and in monitoring the patients during the study. Statistics were performed using GraphPad Statistical Software analysis (La Jolla, CA 92037 USA). The primary endpoint was reduction of drusenoid pigment epithelial detachment (PED) volume >50% based on OCT imaging at exit from the study. Drusen volume was measured by automated analysis of macular retinal pigment epithelium (RPE) elevations with the Cirrus HD-OCT. Any automated measurement can have artifacts in segmentation especially if the quality of OCT obtain is not adequate. All scans were verified that the segmentation was appropriate.

3. Results

3.1. Report of Initial Case

An otherwise healthy 63-year-old man with AMD on Age-Related Eye Disease Study (AREDS) vitamin supplements presented for a second opinion because of deteriorating VA. Baseline VA was 20/25 in each eye with significant distortion. Fundoscopy revealed bilateral extensive confluent large soft drusen and pigmentary alterations (Fig. 1, top row). Spectral domain OCT (SD-OCT) confirmed significant drusenoid PEDs as well as architectural distortion of the overlying RPE and photoreceptor layers (Fig. 2, top row). No subretinal or intraretinal fluid was present. Standard AREDS vitamin supplementation was continued. One year later, the patient became more symptomatic, and VA was slightly decreased to 20/30 in each eye. After extensive discussion, the patient was started on atorvastatin, beginning with 10 mg daily and increasing gradually over 9 months by a predetermined rate (two-month intervals of 10 mg/day, 20 mg/day, 40 mg/day, 60 mg/day, and 80 mg/day) to the target 80 mg daily dose. Six months after reaching a daily dose of 80 mg atorvastatin, VA improved by 12 letters to 20/20, and examination with fundus examination and SD-OCT revealing complete disappearance of the drusen without accompanying atrophy of the RPE. Intraretinal hyper-reflective foci remained (Figs. 1 and 2, bottom row).

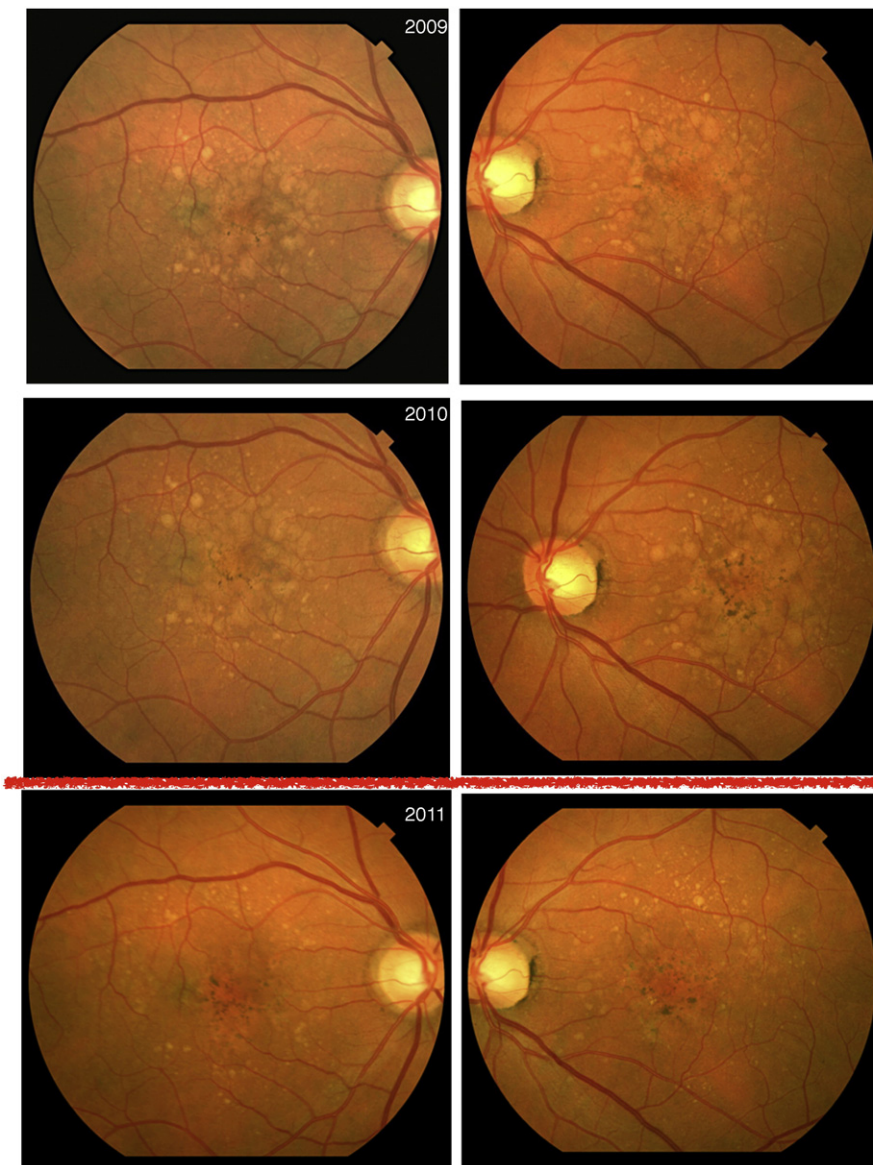


Fig. 1. Color fundus images of a 63-year-old man with AMD and large soft drusen and drusenoid pigment epithelial detachments. Upper panel at presentation, middle panels one year later at start of atorvastatin and lower panels a year after atorvastatin treatment.

3.2. Pilot Study

Given these dramatic results, we initiated a pilot open-label multi-center interventional prospective trial at two academic medical centers, one in the United States and one in Europe, to determine if these effects might be generalizable. Of 26 patients enrolled in the two centers, 23 completed the pilot study (10 from Europe, 13 from the United States). All patients were Caucasians, and seven were men. Three patients exited the study: one because of cramps, one because of muscle aches, and one because the patient felt the drug was inducing hair loss. No patient exhibited elevated liver function tests (LFTs) that required exit from the study.

Ten of 23 patients (Table 1) responded to the treatment with significant regression of drusen deposits, with eight patients showing near complete regression (similar to Fig. 2). Responders (4 from United States, 6 from Europe, $p = 0.1221$) had a reduction in volume from $0.57 \pm 0.47 \text{ mm}^3$ to $0.049 \pm 0.051 \text{ mm}^3$ ($p = 0.012$). Non-responders volume changed from $0.23 \pm 0.20 \text{ mm}^3$ to $0.35 \pm 0.32 \text{ mm}^3$. On

average, responders gained 3 letters whereas the non-responders lost 2.3 letters. The average time to response (resolution of the drusenoid deposits without atrophy) was 11.7 months (range 3–22). Six patients responded by 12 months and nine by month 18. The average person-years of follow-up were ~ 30 . None of the patients converted to neovascular AMD. According to the online risk calculator (<http://caseyamdcalc.ohsu.edu>), it would be expected that 14% of our cases (3–4/23 patients) would convert to neovascular AMD. Our alpha error in detecting zero cases is 2.1%.

Responders were slightly older than non-responders (70.6 ± 6.2 vs. 66.2 ± 5.5 , $p = 0.081$) and had equal baseline cholesterol levels (210 ± 33.4 vs. 207 ± 37.4 , $p = 0.86$). Reduction of cholesterol levels did not appear to correlate with response status (49 ± 31.2 in responders vs. 71 ± 35.9 in non-responders, $p = 0.14$). Women had a higher odds ratio (7.71) of being responders, but this was not statistically significant (95% confidence limits 0.746–79.7746, $p = 0.0886$). There were no apparent differences in multivitamin use, aspirin use, fish oil consumption, or anti-hypertensive medications. There was only one smoker in

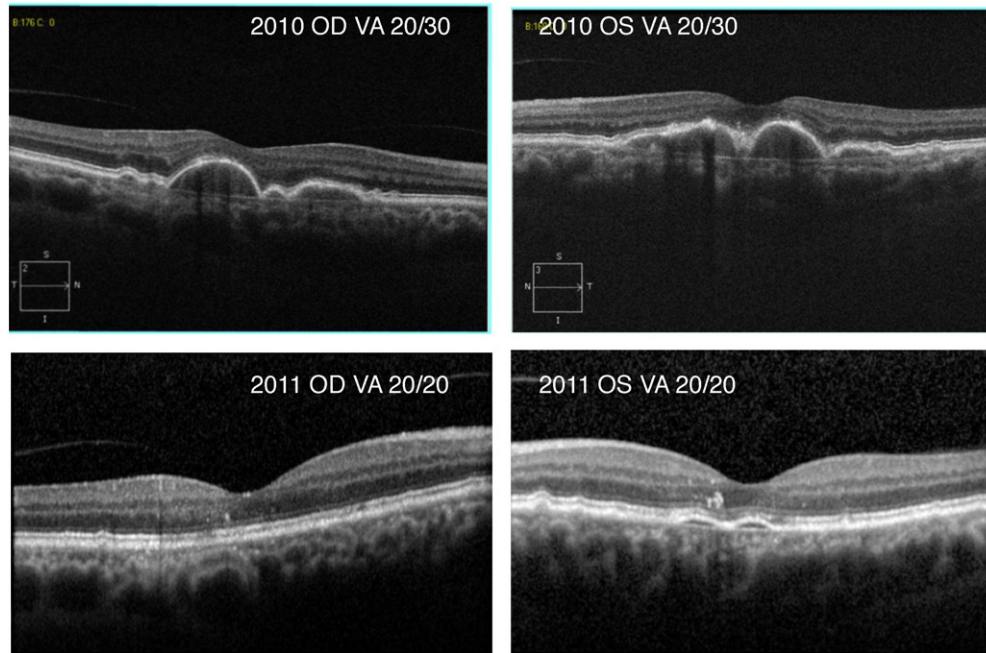


Fig. 2. High resolution optical coherence tomography of patient in Fig. 1. Upper panel prior to initiation of atorvastatin treatment and lower panels a year after atorvastatin treatment. Intraretinal hyperreflective foci remained at the end of treatment.

our study. Atorvastatin did not appear to have a positive or negative effect on progression of pigmentary changes in fundus photographs or on intraretinal hyper-reflective foci.

4. Discussion

AMD is the leading cause of irreversible vision loss in adults in the industrialized world (Wong et al., 2014). Hallmarks of this disease include lipid-rich basal linear deposits and drusen between the RPE basal lamina and the remainder of BM (Wang et al., 2009; Curcio et al., 2011), which are known to contain complement (Crabb, 2014) and several immunogenic and toxic materials, such as 7-ketocholesterol (Rodriguez et al., 2014) and amyloid (Luibl et al., 2006). In many studies, drusen sampled for analysis are not confined to the macula; this is important to note because peripheral drusen (which can differ from macular drusen) may predominate (Crabb, 2014; Crabb et al., 2002). Lipidation of BM is thought to impair transport of compounds necessary for the health of the retina and RPE (Moore et al., 1995; Pauleikhoff et al., 1990; Ethier et al., 2004; Cankova et al., 2011; Hussain et al., 2010). Elimination of these deposits is widely regarded as of potential benefit to patients. Although drusen can regress spontaneously, new lesions may appear in other locations (Klein et al., 2004; Yehoshua et al., 2011) and

most often, development of late stages of disease (geographic atrophy and or choroidal neovascularization) is often preceded by drusen reduction (Klein et al., 2004; Yehoshua et al., 2011; Brader et al., 2013). Several trials have studied ways to reduce drusen, notably the Prophylactic Treatment of Age-related Macular Degeneration (PTAMD) Study, which used 810 nm laser to treat drusen (Friberg et al., 2006), and the more recently complement C5 inhibitor trial (Garcia Filho et al., 2014). Unfortunately, both studies failed to show regression or prevention of progression to late AMD or improvement in visual acuity. Here we present a case report and results of an open-label pilot prospective study that provide the first evidence that medical intervention with high-dose atorvastatin may cause regression of large drusen without progression to advanced AMD, and with possible improvement in VA.

AMD is a heterogeneous disease, with several different phenotypes, including types and size of drusen (Miller, 2013). Prior epidemiological studies examining the role of statins in AMD (Hall et al., 2001; Gehlbach et al., 2009, 2015; Guymer et al., 2013; VanderBeek et al., 2013; Cougnard-Gregoire et al., 2014; Klein et al., 2014a, 2007; Tan et al., 2007) did not stratify or distinguish patients based on AMD subtype. It is unlikely that statins would have across-the-board effectiveness in a heterogeneous disease, and for this reason we focused on patients with large soft drusen and drusenoid PEDs, which are known risk factors

Table 1
Characteristics of responders vs. non-responders.

	All (n = 23)	Responders (n = 10)	Non responders (n = 13)	
Age (years)	68.1 ± 6	70.6 ± 6.2	66.2 ± 5.5	p = 0.08137
Hypertension	10	5/10	5/13	Fisher 0.685018
Initial cholesterol (total Chol mg/dL)	208 ± 34.9	210 ± 33.4	207 ± 37.4	p = 0.859484
Last cholesterol	147 ± 31	161 ± 34.2	136 ± 24.4	p = 0.057162
Chol. reduction	−62 ± 35	−49 ± 31.2	−71 ± 35.9	p = 0.140764
Eye vitamins	14	7/10	7/13	Fisher 0.669269
Vitamin D use	5	3/10	2/13	Fisher 0.635117
Fish oil use	5	2/10	3/13	Fisher 1
Aspirin use	7	3/10	4/13	Fisher 1
Initial VA (letters)	77.6 ± 8.3	74.2 ± 9.9	80.2 ± 6	p = 0.089024
Last VA (letters)	77.7 ± 8.4	77.5 ± 10.3	77.9 ± 7.1	p = 0.908481
VA gain (loss)		+3.3	−2.3	p = 0.061144

for progression to advanced disease. AMD is also multifactorial, with >100 reported at-risk genes that can be grouped into pathways (Miller, 2013) with a subset of AMD-related genes that can be aligned on an atherosclerosis-like progression (Fritsche et al., 2015; Pikuleva and Curcio, 2014; Chen et al., 2010; Cheng et al., 2015; Neale et al., 2010; Reynolds et al., 2010; Fritsche et al., 2013). Although prior studies showed negative overall association between AMD and statin use, they did suggest a potential protective role in a subset of patients with soft drusen or in patient with the at risk CFH genotype CC (Y402H) risk gene (Guymer et al., 2013; Klein et al., 2007; Tan et al., 2007). These findings, taken together with our study, suggest that statins may have a particular role in certain (intermediate-high risk, large drusenoid deposits), but not all, AMD patients.

Cardiovascular studies suggest that the effect of statins on regression of atheromatous pathology may not be related to actual serum LDL or HDL levels achieved, as shown by the PROVE-IT trial (Khush and Waters, 2004) or by a more recent head-to-head comparison of atorvastatin 80 mg vs. rosuvastatin 40mg (Nicholls et al., 2011). Likewise, we did not observe any differences in cholesterol level reduction between responders and non-responders in our pilot study, suggesting that factors other than lipid lowering response may be important for the observed phenomena. That does not mean that lipid lowering is not needed; lipid lowering may be a permissive state for drusen regression to happen via other mechanisms. Aging macrophages have reduced levels of the cholesterol transporter ABCA1, impaired cholesterol efflux, and a pro-angiogenic polarization (Sene et al., 2013). Increased cholesterol intake recapitulates these “aging” changes in macrophages and leads to advanced neovascular AMD pathology in mice (Sene et al., 2013). Mechanistically, lipid lowering by statins may reverse this “aging” of macrophages and thereby improve AMD pathology. In addition, mice fed a high-fat diet exhibit RPE and BM changes similar to human aging and AMD, such as lipid droplets in the BM; administration of simvastatin led to significant reversal of these changes (Barathi et al., 2014). This suggests that lipid lowering may be a necessary factor in reversing AMD pathology (Barathi et al., 2014).

Statins are thought to have antioxidant properties (Profumo et al., 2014). The RPE, bathed by the high oxygen tension environment of the choriocapillaris (Friedman et al., 1964; Linsenmeier and Braun, 1992), is susceptible to chronic oxidative stress, which may play a role in AMD pathogenesis (Hollyfield, 2010; Klein et al., 2014b; Suzuki et al., 2007, 2012; Winkler et al., 1999). Statins have been shown to reduce oxidative stress-induced injury to the RPE and increase viability (Kim et al., 2012; Qian et al., 2011). Statins modulate ApoB100 secretion in cultured human RPE cells via modulation of RPE cholesterol levels (Wu et al., 2010), although not all statins are equivalent, with lipophilic ones (like atorvastatin) being more effective than hydrophilic ones (such as pravastatin). This differential effect of statin class on RPE function is yet another potential confounding variable that can affect results of epidemiological studies that do not distinguish between classes of statins.

Despite the high-risk characteristics of our patient cohort, none of them progressed to neovascular or wet AMD. As noted earlier, mice fed high cholesterol diet had a switch to the proangiogenic type of macrophages and increased wet AMD phenotype (Sene et al., 2013). Statins have been shown to reduce inflammatory cytokine IL-6 (Ito et al., 2002), to downregulate VEGF expression in TNF α -induced tortuosity of retinal vessels in mice (Robinson et al., 2011), and to reduce laser-induced choroidal neovascularization in a mouse model of neovascular AMD (Yamada et al., 2007), suggesting a beneficial role of statins in preventing conversion to neovascular AMD.

In addition, statins may benefit patients with large lipid-rich sub-RPE drusenoid deposits through multiple potential mechanisms: by preventing their accumulation through reduction of local and systemic production, increasing the ability of macrophages and/or RPE to clear debris, and/or by reducing oxidative damage and by stabilizing the vascular supply to the macula.

Our open-label pilot safety/efficacy study suggests that intensive statin treatment may cause regression of high-risk features of AMD, such as drusen, without progression to advanced AMD and without the vision loss that often accompanies spontaneous disappearance of drusen. These results are consistent with the “locally produced oil-spill” hypothesis (Curcio et al., 2011) of AMD pathogenesis. Of course there are several obvious limitations of our study. It is an open label, non-randomized pilot study with a small and rather homogeneous sample size that is followed on average for only 1.5 years. It is known that rarely, spontaneous reduction or collapse of drusen without atrophy may occur and it is conceivable that our narrow cohort selected for such patients. In addition, we do not know how long the effects can last and how long statins should be administered. Finally, the effects of statins in cases with preexisting atrophy are not addressed in this pilot study. For these reasons, future larger randomized prospective studies are needed to assess the exact role of statins in AMD. These studies should take into account genotype and phenotype subgroups of AMD, as well as dosing, lipophilicity, and potency of the statin tested.

Author Contributions

DGV conceived the study. DGV, ABD, JWG, EG, MKT and JWM were involved in the design of the pilot study and writing of the manuscript. JWG, EG, ZGK, JIL, LHY, ESG, DE, and IKK contributed patients, data gathering, analytical discussions, and contributed to writing.

Disclosures

There are no relevant financial disclosures.

Acknowledgments/Funding

We like to thank Wendy Chao Ph.D. for professional editing of the manuscript. The study was supported by the Yeatts Family foundation, the Mass. Eye and Ear Neovascular AMD funds, the Loefflers Family foundation, and the Research to Prevent Blindness Foundation (DGV and JWM). The funders had no role in study design, data collection, data analysis, interpretation, or writing of the report.

References

- Arad, Y., Ramakrishnan, R., Ginsberg, H.N., 1990. Lovastatin therapy reduces low density lipoprotein apoB levels in subjects with combined hyperlipidemia by reducing the production of apoB-containing lipoproteins: implications for the pathophysiology of apoB production. *J. Lipid Res.* 31, 567–582.
- Barathi, V.A., Yeo, S.W., Guymer, R.H., Wong, T.Y., Luu, C.D., 2014. Effects of simvastatin on retinal structure and function of a high-fat atherogenic mouse model of thickened Bruch's membrane. *Invest. Ophthalmol. Vis. Sci.* 55, 460–468.
- Bilheimer, D.W., Grundy, S.M., Brown, M.S., Goldstein, J.L., 1983. Mevinolin and colestipol stimulate receptor-mediated clearance of low density lipoprotein from plasma in familial hypercholesterolemia heterozygotes. *Proc. Natl. Acad. Sci. U. S. A.* 80, 4124–4128.
- Brader, H.S., Ying, G.S., Martin, E.R., Maguire, M.G., 2013. Complications of age-related macular degeneration prevention trial research Group. Characteristics of incident geographic atrophy in the complications of age-related macular degeneration prevention trial. *Ophthalmology* 120, 1871–1879.
- Cankova, Z., Huang, J.D., Kruth, H.S., Johnson, M., 2011. Passage of low-density lipoproteins through Bruch's membrane and choroid. *Exp. Eye Res.* 93, 947–955.
- Cannon, C.P., Braunwald, E., McCabe, C.H., et al., 2004. Intensive versus moderate lipid lowering with statins after acute coronary syndromes. *N. Engl. J. Med.* 350, 1495–1504.
- Chen, W., Stambolian, D., Edwards, A.O., et al., 2010. Genetic variants near TIMP3 and high-density lipoprotein-associated loci influence susceptibility to age-related macular degeneration. *Proc. Natl. Acad. Sci. U. S. A.* 107, 7401–7406.
- Cheng, C.Y., Yamashiro, K., Chen, L.J., et al., 2015. New loci and coding variants confer risk for age-related macular degeneration in East Asians. *Nat. Commun.* 6, 6063.
- Chitose, T., Sugiyama, S., Sakamoto, K., et al., 2014. Effect of a hydrophilic and a hydrophobic statin on cardiac salvage after ST-elevated acute myocardial infarction — a pilot study. *Atherosclerosis* 237, 251–258.
- Cougnard-Gregoire, A., Delyfer, M.N., Korobelnik, J.F., et al., 2014. Elevated high-density lipoprotein cholesterol and age-related macular degeneration: the Alienor study. *PLoS One* 9, e90973.
- Crabb, J.W., 2014. The proteomics of drusen. *Cold Spring Harb. Perspect. Med.* 4, a017194.
- Crabb, J.W., Miyagi, M., Gu, X., et al., 2002. Drusen proteome analysis: an approach to the etiology of age-related macular degeneration. *Proc. Natl. Acad. Sci. U. S. A.* 99, 14682–14687.
- Curcio, C.A., Millican, C.L., Bailey, T., Kruth, H.S., 2001. Accumulation of cholesterol with age in human Bruch's membrane. *Invest. Ophthalmol. Vis. Sci.* 42, 265–274.

- Curcio, C.A., Johnson, M., Rudolf, M., Huang, J.D., 2011. The oil spill in ageing Bruch membrane. *Br. J. Ophthalmol.* 95, 1638–1645.
- Ethier, C.R., Johnson, M., Ruberti, J., 2004. Ocular biomechanics and biotransport. *Annu. Rev. Biomed. Eng.* 6, 249–273.
- Fong, C.W., 2014. Statins in therapy: understanding their hydrophilicity, lipophilicity, binding to 3-hydroxy-3-methylglutaryl-CoA reductase, ability to cross the blood brain barrier and metabolic stability based on electrostatic molecular orbital studies. *Eur. J. Med. Chem.* 85, 661–674.
- Friberg, T.R., Musch, D.C., Lim, J.I., et al., 2006. Prophylactic treatment of age-related macular degeneration report number 1: 810-nanometer laser to eyes with drusen. Unilaterally eligible patients. *Ophthalmology* 113, 622 e1.
- Friedman, E., Kopal, H.H., Smith, T.R., 1964. Retinal and choroidal blood flow determined with Krypton-85 anesthetized animals. *Invest. Ophthalmol.* 3, 539–547.
- Fritsche, L.G., Chen, W., Schu, M., et al., 2013. Seven new loci associated with age-related macular degeneration. *Nat. Genet.* 45, 433–439 (9e1–2).
- Fritsche, L.G., Igl, W., JN, Bailey, et al., 2015. A large genome-wide association study of age-related macular degeneration highlights contributions of rare and common variants. *Nat. Genet.*
- Garcia Filho, C.A., Yehoshua, Z., Gregori, G., et al., 2014. Change in drusen volume as a novel clinical trial endpoint for the study of complement inhibition in age-related macular degeneration. *Ophthalmic Surg. Lasers Imaging Retina* 45, 18–31.
- Gehlbach, P., Li, T., Hatef, E., 2009. Statins for age-related macular degeneration. *Cochrane Database Syst. Rev.* CD006927.
- Gehlbach, P., Li, T., Hatef, E., 2015. Statins for age-related macular degeneration. *Cochrane Database Syst. Rev.* 2, CD006927.
- Guymier, R.H., Baird, P.N., Varsamidis, M., et al., 2013. Proof of concept, randomized, placebo-controlled study of the effect of simvastatin on the course of age-related macular degeneration. *PLoS One* 8, e83759.
- Hall, N.F., Gale, C.R., Syddall, H., Phillips, D.I., Martyn, C.N., 2001. Risk of macular degeneration in users of statins: cross sectional study. *BMJ* 323, 375–376.
- Hollyfield, J.G., 2010. Age-related macular degeneration: the molecular link between oxidative damage, tissue-specific inflammation and outer retinal disease: the proctor lecture. *Invest. Ophthalmol. Vis. Sci.* 51, 1275–1281.
- Hussain, A.A., Starita, C., Hodgetts, A., Marshall, J., 2010. Macromolecular diffusion characteristics of ageing human Bruch's membrane: implications for age-related macular degeneration (AMD). *Exp. Eye Res.* 90, 703–710.
- Ito, T., Ikeda, U., Shimpō, M., et al., 2002. HMG-CoA reductase inhibitors reduce interleukin-6 synthesis in human vascular smooth muscle cells. *Cardiovasc. Drugs Ther.* 16, 121–126.
- Johnson, L.V., Forest, D.L., Banna, C.D., et al., 2011. Cell culture model that mimics drusen formation and triggers complement activation associated with age-related macular degeneration. *Proc. Natl. Acad. Sci. U. S. A.* 108, 18277–18282.
- Khush, K.K., Waters, D., 2004. Lessons from the PROVE-IT trial. higher dose of potent statin better for high-risk patients. *Cleve. Clin. J. Med.* 71, 609–616.
- Kim, K.J., Kim, K.S., Kim, N.R., Chin, H.S., 2012. Effects of simvastatin on the expression of heme oxygenase-1 in human RPE cells. *Invest. Ophthalmol. Vis. Sci.* 53, 6456–6464.
- Kino, T., Kozasa, T., Chrousos, G.P., 2005. Statin-induced blockade of prenylation alters nucleocytoplasmic shuttling of GTP-binding proteins gamma2 and beta2 and enhances their suppressive effect on glucocorticoid receptor transcriptional activity. *Eur. J. Clin. Invest.* 35, 508–513.
- Klein, R., Peto, T., Bird, A., Vannewkirk, M.R., 2004. The epidemiology of age-related macular degeneration. *Am. J. Ophthalmol.* 137, 486–495.
- Klein, R., Deng, Y., Klein, B.E., et al., 2007. Cardiovascular disease, its risk factors and treatment, and age-related macular degeneration: women's health initiative sight exam ancillary study. *Am. J. Ophthalmol.* 143, 473–483.
- Klein, R., Myers, C.E., Buitendijk, G.H., et al., 2014a. Lipids, lipid genes, and incident age-related macular degeneration: the three continent age-related macular degeneration consortium. *Am. J. Ophthalmol.* 158, 513–524 e3.
- Klein, R., Myers, C.E., Cruickshanks, K.J., et al., 2014b. Markers of inflammation, oxidative stress, and endothelial dysfunction and the 20-year cumulative incidence of early age-related macular degeneration: the Beaver Dam eye study. *JAMA Ophthalmol.* 132, 446–455.
- Kramer, C.M., Mani, V., Fayad, Z.A., 2011. MR imaging-verified plaque delipidation with lipid-lowering therapy important questions remain. *JACC Cardiovasc. Imaging* 4, 987–989.
- Linsenmeier, R.A., Braun, R.D., 1992. Oxygen distribution and consumption in the cat retina during normoxia and hypoxemia. *J. Gen. Physiol.* 99, 177–197.
- Luihl, V., Isas, J.M., Kaye, R., Glabe, C.G., Langen, R., Chen, J., 2006. Drusen deposits associated with aging and age-related macular degeneration contain nonfibrillar amyloid oligomers. *J. Clin. Invest.* 116, 378–385.
- Miller, J.W., 2013. Age-related macular degeneration revisited—piecing the puzzle: the LXIX Edward Jackson memorial lecture. *Am. J. Ophthalmol.* 155, 1–35 e13.
- Moore, D.J., Hussain, A.A., Marshall, J., 1995. Age-related variation in the hydraulic conductivity of Bruch's membrane. *Invest. Ophthalmol. Vis. Sci.* 36, 1290–1297.
- Mullins, R.F., Russell, S.R., Anderson, D.H., Hageman, G.S., 2000. Drusen associated with aging and age-related macular degeneration contain proteins common to extracellular deposits associated with atherosclerosis, elastosis, amyloidosis, and dense deposit disease. *FASEB J.* 14, 835–846.
- Neale, B.M., Fagerness, J., Reynolds, R., et al., 2010. Genome-wide association study of advanced age-related macular degeneration identifies a role of the hepatic lipase gene (LIPC). *Proc. Natl. Acad. Sci. U. S. A.* 107, 7395–7400.
- Nicholls, S.J., Ballantyne, C.M., Barter, P.J., et al., 2011. Effect of two intensive statin regimens on progression of coronary disease. *N. Engl. J. Med.* 365, 2078–2087.
- Nissen, S.E., 2005. Effect of intensive lipid lowering on progression of coronary atherosclerosis: evidence for an early benefit from the reversal of atherosclerosis with aggressive lipid lowering (REVERSAL) trial. *Am. J. Cardiol.* 96, 61F–68F.
- Nissen, S.E., Tuzcu, E.M., Schoenhagen, P., et al., 2004. Effect of intensive compared with moderate lipid-lowering therapy on progression of coronary atherosclerosis: a randomized controlled trial. *JAMA* 291, 1071–1080.
- Nissen, S.E., Nicholls, S.J., Sipahi, I., et al., 2006. Effect of very high-intensity statin therapy on regression of coronary atherosclerosis: the ASTEROID trial. *JAMA* 295, 1556–1565.
- Pauleikhoff, D., Harper, C.A., Marshall, J., Bird, A.C., 1990. Aging changes in Bruch's membrane. A histochemical and morphologic study. *Ophthalmology* 97, 171–178.
- Pikuleva, I.A., Curcio, C.A., 2014. Cholesterol in the retina: the best is yet to come. *Prog. Retin. Eye Res.* 41, 64–89.
- Pitt, B., Waters, D., Brown, W.V., et al., 1999. Aggressive lipid-lowering therapy compared with angioplasty in stable coronary artery disease. Atorvastatin versus revascularization treatment investigators. *N. Engl. J. Med.* 341, 70–76.
- Profumo, E., Buttari, B., Saso, L., Rigano, R., 2014. Pleiotropic effects of statins in atherosclerotic disease: focus on the antioxidant activity of atorvastatin. *Curr. Top. Med. Chem.* 14, 2542–2551.
- Qian, J., Keyes, K.T., Long, B., Chen, G., Ye, Y., 2011. Impact of HMG-CoA reductase inhibition on oxidant-induced injury in human retinal pigment epithelium cells. *J. Cell. Biochem.* 112, 2480–2489.
- Reynolds, R., Rosner, B., Seddon, J.M., 2010. Serum lipid biomarkers and hepatic lipase gene associations with age-related macular degeneration. *Ophthalmology* 117, 1989–1995.
- Robinson, R., Ho, C.E., Tan, Q.S., et al., 2011. Fluvastatin downregulates VEGF-A expression in TNF-alpha-induced retinal vessel tortuosity. *Invest. Ophthalmol. Vis. Sci.* 52, 7423–7431.
- Rodriguez, I.R., Clark, M.E., Lee, J.W., Curcio, C.A., 2014. 7-Ketocholesterol accumulates in ocular tissues as a consequence of aging and is present in high levels in drusen. *Exp. Eye Res.* 128, 151–155.
- Sarks, J.P., Sarks, S.H., Killingsworth, M.C., 1994. Evolution of soft drusen in age-related macular degeneration. *Eye (Lond.)* 8 (Pt 3), 269–283.
- Sene, A., Apte, R.S., 2014. Eyeballing cholesterol efflux and macrophage function in disease pathogenesis. *Trends Endocrinol. Metab.* 25, 107–114.
- Sene, A., Khan, A.A., Cox, D., et al., 2013. Impaired cholesterol efflux in senescent macrophages promotes age-related macular degeneration. *Cell Metab.* 17, 549–561.
- Sene, A., Chin-Yee, D., Apte, R.S., 2015. Seeing through VEGF: innate and adaptive immunity in pathological angiogenesis in the eye. *Trends Mol. Med.* 21, 43–51.
- Sivaprasad, S., Bailey, T.A., Chong, V.N., 2005. Bruch's membrane and the vascular intima: is there a common basis for age-related changes and disease? *Clin. Experiment. Ophthalmol.* 33, 518–523.
- Suzuki, M., Kamei, M., Itabe, H., et al., 2007. Oxidized phospholipids in the macula increase with age and in eyes with age-related macular degeneration. *Mol. Vis.* 13, 772–778.
- Suzuki, M., Tsujikawa, M., Itabe, H., et al., 2012. Chronic photo-oxidative stress and subsequent MCP-1 activation as causative factors for age-related macular degeneration. *J. Cell Sci.* 125, 2407–2415.
- Tan, J.S., Mitchell, P., Rochtchina, E., Wang, J.J., 2007. Statins and the long-term risk of incident age-related macular degeneration: the Blue Mountains eye study. *Am. J. Ophthalmol.* 143, 685–687.
- Tomany, S.C., Wang, J.J., Van Leeuwen, R., et al., 2004. Risk factors for incident age-related macular degeneration: pooled findings from 3 continents. *Ophthalmology* 111, 1280–1287.
- VanderBeek, B.L., Zacks, D.N., Talwar, N., Nan, B., Stein, J.D., 2013. Role of statins in the development and progression of age-related macular degeneration. *Retina* 33, 414–422.
- Wang, L., Li, C.M., Rudolf, M., et al., 2009. Lipoprotein particles of intraocular origin in human Bruch membrane: an unusual lipid profile. *Invest. Ophthalmol. Vis. Sci.* 50, 870–877.
- Winkler, B.S., Boulton, M.E., Gottsch, J.D., Sternberg, P., 1999. Oxidative damage and age-related macular degeneration. *Mol. Vis.* 5, 32.
- Wong, W.L., Su, X., Li, X., et al., 2014. Global prevalence of age-related macular degeneration and disease burden projection for 2020 and 2040: a systematic review and meta-analysis. *Lancet Glob. Health* 2, e106–e116.
- Wu, T., Fujihara, M., Tian, J., et al., 2010. Apolipoprotein B100 secretion by cultured ARPE-19 cells is modulated by alteration of cholesterol levels. *J. Neurochem.* 114, 1734–1744.
- Yamada, K., Sakurai, E., Itaya, M., Yamasaki, S., Ogura, Y., 2007. Inhibition of laser-induced choroidal neovascularization by atorvastatin by downregulation of monocyte chemotactic protein-1 synthesis in mice. *Invest. Ophthalmol. Vis. Sci.* 48, 1839–1843.
- Yehoshua, Z., Wang, F., Rosenfeld, P.J., Penha, F.M., Feuer, W.J., Gregori, G., 2011. Natural history of drusen morphology in age-related macular degeneration using spectral domain optical coherence tomography. *Ophthalmology* 118, 2434–2441.
- Yip, J.L., Khawaja, A.P., Chan, M.P., et al., 2015. Cross sectional and longitudinal associations between cardiovascular risk factors and age related macular degeneration in the EPIC-Norfolk eye study. *PLoS One* 10, e0132565.
- Yu, C.M., Zhang, Q., Lam, L., et al., 2007. Comparison of intensive and low-dose atorvastatin therapy in the reduction of carotid intimal-medial thickness in patients with coronary heart disease. *Heart* 93, 933–939.
- Zhao, X.Q., Dong, L., Hatsukami, T., et al., 2011. MR imaging of carotid plaque composition during lipid-lowering therapy a prospective assessment of effect and time course. *JACC Cardiovasc. Imaging* 4, 977–986.