

## CASE REPORT

# Ankle arthrodesis using a retrograde intramedullary rod with fins for highly destructive joints in elderly patients with rheumatoid arthritis: A report of two cases

Shun Takahashi<sup>1</sup> | Naoki Kondo<sup>1</sup>  | Yasufumi Kijima<sup>1</sup> | Rika Kakutani<sup>1</sup> | Hajime Ishikawa<sup>2</sup> | Hiroyuki Kawashima<sup>1</sup>

<sup>1</sup>Division of Orthopedic Surgery, Department of Regenerative and Transplant Medicine, Niigata University Graduate School of Medical and Dental Science, Niigata, Japan

<sup>2</sup>Department of Rheumatology, Niigata Rheumatic Center, Shibata, Japan

## Correspondence

Naoki Kondo, Division of Orthopedic Surgery, Department of Regenerative and Transplant Medicine, Niigata University Graduate School of Medical and Dental Science, 1-757 Asahimachidori, Chuo-ku, Niigata, Niigata 951-8510, Japan.  
Email: naokikondo1214@gmail.com

## Funding information

The authors declare that they have no funding regarding the contents of this case report

## Abstract

Herein, we present two cases of older adult patients with highly destructive changes in ankle joints (Larsen grade IV) who underwent retrograde intramedullary ankle nail fixation with fins. In both patients, bony union was achieved, and full weight-bearing was attained at 3 months after surgery.

## KEYWORDS

destructive ankle joint, elderly, functional outcome, intramedullary ankle nail with fin, rheumatoid arthritis

## 1 | INTRODUCTION

Recent developments in drug therapy have improved the disease activity of rheumatoid arthritis (RA). These developments include the administration of conventional synthetic disease-modifying antirheumatic drugs (DMARDs), biological DMARDs, and targeted synthetic DMARDs.<sup>1</sup> However, the progression of joint destruction in the lower extremities remains a major problem in clinical settings.<sup>2</sup>

In previous reports, the incidence of ankle involvement in joint destruction ranged from 4% to 90%.<sup>3–6</sup> In the Korean registry, 29% (598/2046) of patients with RA had

foot and/or ankle arthritis, with greater severity of disease activity and lower remission rate compared with those without foot and/or ankle RA.<sup>6</sup> In the United Kingdom registry, 35.4% (207/585) of patients reported current foot pain as the presenting symptom.<sup>4</sup> Most studies report a high prevalence of foot and ankle involvement in patients with RA. Yano et al. reported that patients with RA and foot impairment had higher disease activity and lower activities of daily living than those without foot impairment.<sup>7</sup>

The elderly population with RA includes both patients with elderly-onset RA (EORA), in which the disease manifests after the age of 60 years, and individuals diagnosed

with RA early in life (young-onset RA or YORA). There are treatment concerns for the older adult population group, as RA drugs can induce several age-related adverse events.<sup>8</sup> In addition, the reversibility of functional impairments is reduced in older patients with RA due to age-related factors or comorbidities.<sup>9</sup>

In the KURAMA cohort (a Japanese cohort of patients with RA), patients with EORA showed higher bone erosion than patients with YORA.<sup>10</sup> Furthermore, complaints of ankle deformity and functional disability were higher in patients with EORA.

When ankles are deformed by RA, both the talocrural and subtalar joints are damaged, and ankle arthrodesis with a retrograde intramedullary ankle nail is the surgical procedure of choice.<sup>11–16</sup>

Fujimori et al. developed retrograde intramedullary ankle nail fixation with fins (a total of four fins with a cruciform in the distal part, with each fin having a height of 7.5 cm). These fins tightly stabilize rotational instability, and transverse screws are prepared in the proximal part to prevent rotational instability. This system enables early weight-bearing after surgery.<sup>11</sup>

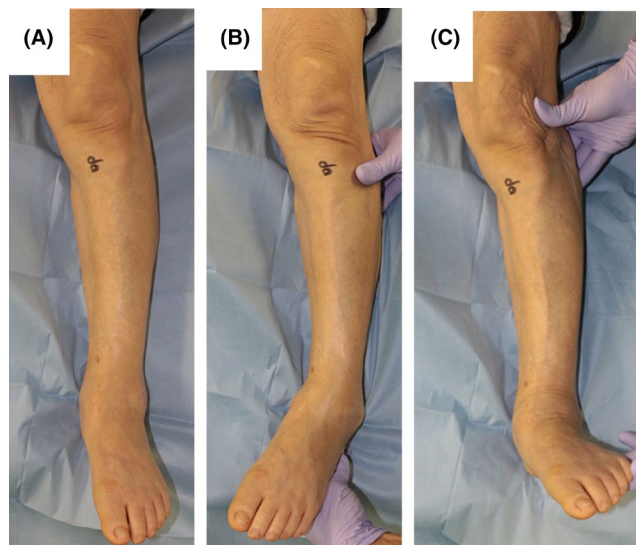
Herein, we present two cases of patients with RA who presented with highly destructive changes in the ankle joint. We performed retrograde intramedullary ankle nail fixation with fins in both patients, which resulted in good functional outcomes.

## 2 | CASE PRESENTATIONS

### 2.1 | Case 1

An 86-year-old woman was diagnosed with RA at the age of 83 years. Due to the high disease activity of RA, she received tofacitinib (5 mg/day). This treatment did not significantly improve her Disease Activity Score-28 (DAS28), which was initially 3.07 and improved to 2.93 after 3 months of drug therapy. The bone mineral density T-score of the left hip was  $-2.8$ , and she was subsequently diagnosed with osteoporosis. However, she received no treatment because she had not been prescribed a glucocorticoid. She complained of both gait and weight-bearing pain with varus deviation in the left ankle joint (Figure 1A–C). At her initial visit, the radiographic findings for her left ankle joint were Larsen grade IV in the talocrural joint and Larsen grade III in the subtalar joint (Figure 2A,B). Triamcinolone acetonide (15 mg) was injected into the left talocrural joint at 5 months before surgery; nonetheless, pain and swelling persisted. We decided to perform ankle arthrodesis to improve the patient's functional outcome.

We used a transfibular approach during surgery. Both the talocrural and subtalar joints were exposed, and each



**FIGURE 1** Preoperative macroscopic findings of Case 1 (left ankle). Anteroposterior view in neutral position (A). Passive varus instability is moderately observed (B), but no passive valgus deformity is observed (C)

joint surface was curetted. The finned intramedullary retrograde ankle nail (Intramedullary nail with fin, Teijin Nakashima Medical, Co. Ltd.) was inserted from the plantar side. Cancellous bone grafts were performed using bone harvested from the distal fibula (Figure 3A,B).

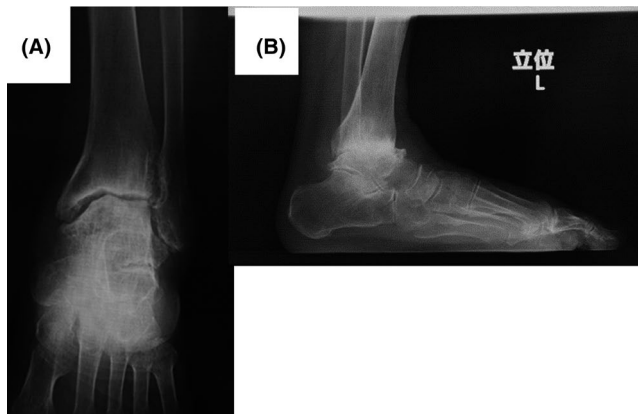
After surgery, non-weight-bearing was maintained for 3 weeks. A patellar tendon-bearing orthosis was applied, and walking exercises were started at 3 weeks postoperatively. The orthosis was released, and free gait with full weight bearing was started at 3 months postoperatively.

#### 2.1.1 | Results

Bony union was detected on radiography (Figure 3C,D) 6 months after surgery, although a radiolucent area surrounding the implant remained. The patient could walk without support. The passive range of motion of the left ankle joint was  $5^{\circ}/20^{\circ}$  in dorsiflexion/plantar flexion before surgery and  $5^{\circ}/10^{\circ}$  after surgery. The functional outcome of the ankle joint was measured using the Japanese Society for Surgery of the Foot (JSSF)-RA foot ankle scale,<sup>17</sup> and the RA activity was measured using the DAS28 score. The patient's JSSF-RA and DAS28 scores improved from 37 and 3.07 before surgery to 72 and 2.22 after surgery, respectively.

### 2.2 | Case 2

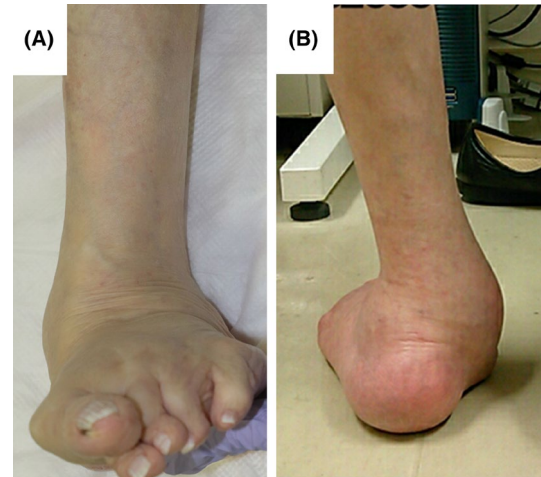
An 81-year-old woman was diagnosed with RA at the age of 27 years. She was treated with methotrexate (6 mg/week) and prednisolone (4 mg/day). She had been treated



**FIGURE 2** Preoperative radiographs of Case 1 (left ankle). Anteroposterior (A) and lateral (B) views when standing. The joint space of the talocrural joint is irregular. Narrowing of the joint space is detected in the talofibular joint (A). Larsen grades IV and III are determined in the talocrural and subtalar joints, respectively

with denosumab (60 mg/6 months) and vitamin D for osteoporosis (the bone mineral density T-score of the left hip was  $-2.8$ ). She had previously undergone partial talectomy (only the protruded region) 8 years prior for recurrent skin infection of the contact region with floor in her left foot. During this surgery, a bony protrusion of the talus caused by a calcaneovalgus abnormality was removed. Callosity was detected in her left foot, and a severe calcaneovalgus deformity remained (Figure 4A,B). The patient presented to our hospital complaining of gait and weight-bearing pain in her left ankle joint. The radiographic findings for the patient's left ankle joint were Larsen grade IV in both the talocrural and subtalar joints (Figure 5A,B), and we decided to perform ankle arthrodesis to correct the deformity and improve the functional outcome.

We used the same surgical approach and grafting procedure (Figure 6A,B) for this patient as those described in Case 1. The finned intramedullary retrograde ankle nail was inserted from the plantar side. Postoperative care was the same as in Case 1. Macroscopic findings showed correction of ankle alignment and no skin issues 1 year postoperatively (Figure 7A–C).



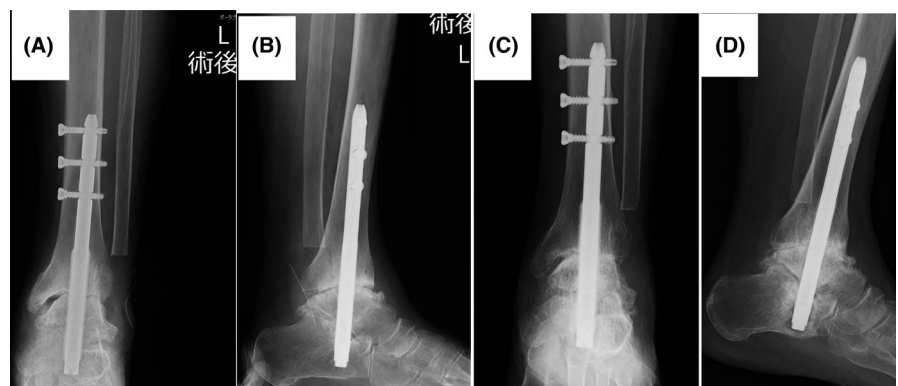
**FIGURE 4** Preoperative macroscopic findings of Case 2 (left ankle). Anteroposterior (A) and posteroanterior (B) views. Hallux valgus deformity and a remarkable calcaneovalgus deformity are observed

## 2.2.1 | Results

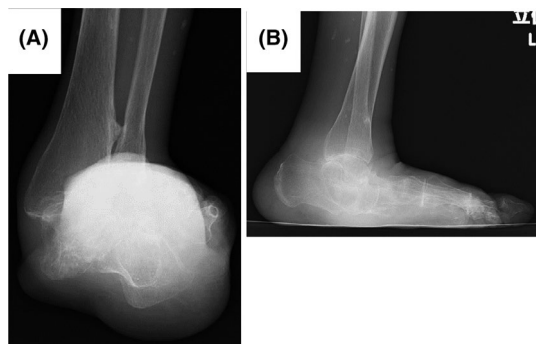
Four months after surgery, bony union was detected on radiographic imaging without a radiolucent zone surrounding the implant (Figure 6C,D) and was completely achieved 1 year after surgery (Figure 6E,F). The patient could walk without support. The passive range of motion of the left ankle joint was  $10^{\circ}/20^{\circ}$  in dorsiflexion/plantar flexion before surgery and  $10^{\circ}/5^{\circ}$  after surgery. The patient's JSSF-RA and DAS28 scores improved from 36 and 3.23 before surgery to 66 and 2.81 after surgery, respectively.

## 2.3 | Patient consent and ethics statement

Written informed consent was obtained from both patients for the publication of this case report and the accompanying images. All procedures were conducted in accordance with the Declaration of Helsinki (1964).



**FIGURE 3** Postoperative radiographs of Case 1 (left ankle) just after surgery (A, B) and at 6 months after surgery (C, D)

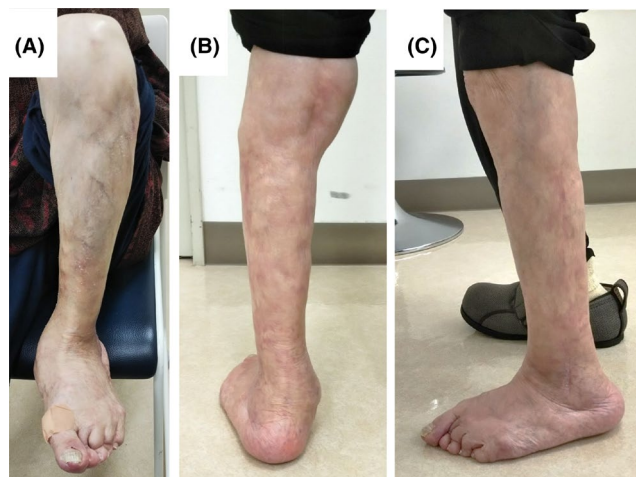


**FIGURE 5** Preoperative radiographs of Case 2 (left ankle). Anteroposterior (A) and lateral (B) views when standing. The joint space of the talocrural joint is irregular. Larsen grade IV is determined in both the talocrural and subtalar joints

### 3 | DISCUSSION

Some older adult patients with RA develop complications as their joints are destroyed by the disease, resulting in functional disability or persistent weight-bearing pain. Conservative treatments, such as drug therapy or orthosis therapy, are unable to correct severe deformity of the ankle joints. In particular, weight-bearing joints in the lower extremities, such as the hip, knee, and ankle joints, tend to worsen or show a progression of osteoarthritic changes, and patients often complain of weight-bearing or gait pain.<sup>2</sup> For damaged joints where pain or functional disability persist, joint surgery is sometimes indicated even when the DAS28 scores are maintained at low or moderate values. When joint destruction occurs in the lower extremities, surgeries such as knee or hip joint arthroplasties and ankle arthrodesis may be required.

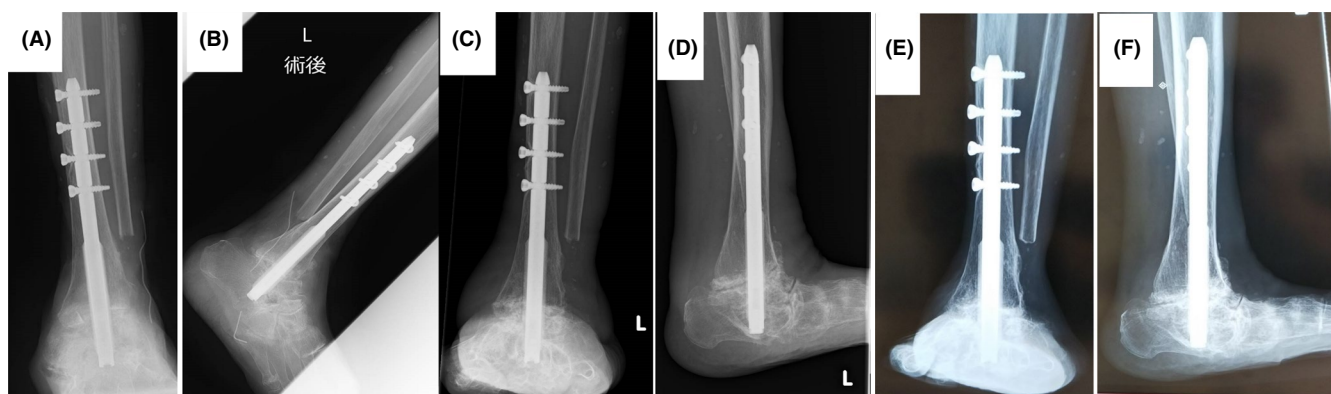
Both patients in our study were over 80 years old, and tofacitinib (in Case 1) or methotrexate (in Case 2) maintained moderate disease activity. However, persistent ipsilateral ankle joint pain and walking disability indicated surgical treatment for the damaged ankle joints.



**FIGURE 7** One year postoperative macroscopic findings of Case 2 (left ankle). Anteroposterior (A), posteroanterior (B), and lateral (C) views on weight-bearing position. Tibiotalar alignment is corrected

For destructive ankle joints due to RA, total ankle arthroplasty is one option. However, its long-term outcomes remain unknown and several complications, such as radiolucent line (73%), migration of the tibial component (21.1%), subsidence of the talar component (28.9%), and intraoperative malleolus fracture (7.7%), are concerning.<sup>18</sup> Tibiotalocalcaneal joint fusion is another option. Furthermore, locking nail systems biomechanically show better stiffness than unlocking nail systems.<sup>13</sup>

For conservative treatment of moderately to highly destructive ankle deformities, orthosis (called the “MAX brace”<sup>19</sup>) or triamcinolone injections have been performed at our facility. In cases that are refractory to conservative therapy, we have performed surgical interventions such as talocrural joint arthrodesis with ankle arthroscopic synovectomy and tibiotalocalcaneal arthrodesis using a retrograde intramedullary ankle nail.



**FIGURE 6** Postoperative radiographs of Case 2 (left ankle) just after surgery (A, B), at 4 months after surgery (C, D), and at 12 months after surgery (E, F). Osseous fusion is achieved

Mid- and long-term outcomes of retrograde intramedullary ankle nail fixation with fins for patients with RA have been reported.<sup>14–16</sup> The mid-term result after intramedullary ankle nail fixation for 51 highly destructive ankle joint cases showed a mean follow-up duration of  $71.6 \pm 51.1$  months and a mean postoperative JSSF score of  $65.3 \pm 14.9$  (range, 30–84). However, nonunion of the subtalar joint was detected in 43.3% of cases (23 joints), and an absence of subtalar curettage and earlier postoperative weight-bearing were significantly associated with subtalar nonunion on multivariate analysis of risk factors for nonunion.<sup>14</sup> We performed subtalar joint curettage, and it took approximately 12 weeks for weight-bearing training in both cases. Neither of our cases showed subtalar nonunion.

The technical points of this procedure are as follows: (1) The talocrural and subtalar joints should be thoroughly curetted, including osteotomy; (2) a fixed position is neutral in the talocrural joint with slight calcaneovalgus; (3) the calcaneal pitch should be considered to preserve the longitudinal arch in the foot; and (4) an intramedullary nail should be sufficiently inserted into the calcaneus.

Nagashima et al. reported 25 cases of severe hindfoot deformity due to RA that underwent intramedullary nail fixation with fins and were followed up for 7 years and 1 month.<sup>15</sup> All cases achieved osseous fusion of the talocrural joint by 14 weeks postoperatively. Additionally, 23 cases achieved osseous fusion of the subtalar joints; the 2 exceptions were cases of mutilating type. The Japanese Orthopaedic Association (JOA) foot score also significantly improved from  $35.9 \pm 10.6$  preoperatively to  $64.3 \pm 9.3$  postoperatively, and the authors concluded that this procedure had satisfactory outcomes. For 30 RA cases that underwent ankle arthrodesis using this system, the long-term results were satisfactory because they showed that a high JOA foot score was maintained (64.3 points), even after an average postoperative period of 10.7 years.<sup>16</sup>

We used a finned intramedullary retrograde ankle joint nail (unlocking nail system) in these two cases for two reasons. First, this system is easier for surgical procedures than a locking nail system because insertion of distal screws is not required. The nail has four fins with sharp distal tips; these fins effectively prevent the ankle from moving in various directions.<sup>11</sup> In addition, we used a transfibular approach in these two cases, which provided good visualization and easy access to the autogenous bone graft using the cancellous bone from the cut end of the fibula (or iliac bone). Second, it usually takes a longer time to correct highly destructive ankle deformities with a locking nail system, and a longer time for surgery would often cause postoperative surgical-site infections. On the contrary, distal screws are not necessary for the finned intramedullary nail; hence, it requires a shorter operative

time than distal screw-type intramedullary ankle nails. Actually, no surgical-site infection occurred in our two cases.

Although this treatment is not appropriate in cases of severe osteoporosis, bony union was achieved in both cases, although Case 1 showed a radiolucent zone around the nail. In Case 1, the bone mineral density T-score of the left hip was  $-2.8$ . This patient was not diagnosed with severe osteoporosis; therefore, no treatment for osteoporosis was performed. In Case 2, the bone mineral density T-score of the left hip was  $-2.8$ . Because the patient had been treated with 4 mg/day of prednisolone, denosumab and vitamin D were administered to prevent insufficiency fractures.

Finned intramedullary retrograde ankle joint nails are inserted from the subtalar joint to the talocrural joint to prevent the nail from rotating. Weight bearing adds a compressive force around the nail and promotes bony union.<sup>11</sup> The intramedullary ankle nail system accepts weight bearing in the early postoperative stage. In our patients, postoperative treatment included 3 weeks of using a patellar tendon-bearing brace to prevent weight-bearing on the affected joints.

The use of this type of nail limits the range of motion of the subtalar and ankle joints.<sup>11</sup> However, since destruction of the subtalar joint was observed in both patients, we considered the use of this nail to be appropriate. Dorsiflexion and plantar flexion of the ankle joint relies not only on the talocrural joint but also on the Chopart joint.<sup>20</sup> Both patients could therefore retain a partial range of motion of dorsiflexion and plantar flexion.

In conclusion, we presented two cases of RA affecting a unilateral ankle joint, with the symptoms of persistent weight-bearing and pain on walking. Intramedullary retrograde ankle nails with fins were inserted, and both functional outcome and disease activity scores improved 6 months after surgery.

## ACKNOWLEDGEMENTS

We thank Editage ([https://www/editage.jp](https://www.editage.jp)) for English proof reading.

## CONFLICT OF INTEREST

The authors declare that they have no conflicts of interest regarding the contents of this case report.

## AUTHOR CONTRIBUTIONS

Shun Takahashi (ST) and Naoki Kondo (NK): were equally contributed to this manuscript. NK: supervised and conducted the whole contents of the manuscript and figures. ST and NK: prepared the manuscript. YK, RK, HI, and HK: reviewed the manuscript. All the authors were agreement with the submission.

## CONSENT

Informed consent was obtained from the patients.

## DATA AVAILABILITY STATEMENT

The clinical details, radiological and histopathological details, and investigation reports used to support the findings of this case report are available from the corresponding author upon request.

## ORCID

Naoki Kondo  <https://orcid.org/0000-0002-8985-3055>

## REFERENCES

1. Tanaka Y. Rheumatoid arthritis. *Inflamm Regen*. 2020;40:20.
2. Seki E, Matsushita I, Sugiyama E, et al. Radiographic progression in weight-bearing joints of patients with rheumatoid arthritis after TNF-blocking therapies. *Clin Rheumatol*. 2009;28(4):453-460.
3. Michelson J, Easley M, Wigley FM, Hellmann D. Foot and ankle problems in rheumatoid arthritis. *Foot Ankle Int*. 1994;15(11):608-613.
4. Otter SJ, Lucas K, Springett K, et al. Foot pain in rheumatoid arthritis prevalence, risk factors and management: an epidemiological study. *Clin Rheumatol*. 2010;29(3):255-271.
5. Ajeganova S, Andersson ML, Hafström I, BARFOT Study Group. Association of obesity with worse disease severity in rheumatoid arthritis as well as with comorbidities: a long-term follow up from disease onset. *Arthritis Care Res (Hoboken)*. 2013;65(1):78-87.
6. Lee SW, Kim SY, Chang SH. Prevalence of feet and ankle arthritis and their impact on clinical indices in patients with rheumatoid arthritis: a cross-sectional study. *BMC Musculoskelet Disord*. 2019;20(1):420.
7. Yano K, Ikari K, Inoue E, et al. Features of patients with rheumatoid arthritis whose debut joint is a foot or ankle joint: a 5,479-case study from the IORRA cohort. *PLoS One*. 2018;13(9):e0202427.
8. Serhal L, Lwin MN, Holroyd C, Edwards CJ. Rheumatoid arthritis in the elderly: characteristics and treatment considerations. *Autoimmun Rev*. 2020;19(6):102528.
9. Sugihara T, Ishizaki T, Hosoya T, et al. Structural and functional outcomes of a therapeutic strategy targeting low disease activity in patients with elderly-onset rheumatoid arthritis: a prospective cohort study (CRANE). *Rheumatology (Oxford, England)*. 2015;54(5):798-807.
10. Murata K, Ito H, Hashimoto M, et al. Elderly onset of early rheumatoid arthritis is a risk factor for bone erosions, refractory to treatment: KURAMA cohort. *Int J Rheum Dis*. 2019;22(6):1084-1093.
11. Fujimori J, Yoshino S, Koiwa M, Nakamura H, Shiga H, Nagashima S. Ankle arthrodesis in rheumatoid arthritis using an intramedullary nail with fins. *Foot Ankle Int*. 1999;20(8):485-490.
12. Murata H, Hachiya H, Muramatsu K, Harada M, Onitake H. Ankle arthrodesis using a finned intramedullary nail. *Japan J Joint Dis*. 2009;28(1):101-108. Japanese.
13. Mückley T, Eichorn S, Hoffmeier K, et al. Biomechanical evaluation of primary stiffness of tibiotalar calcaneal fusion with intramedullary nails. *Foot Ankle Int*. 2007;28(2):224-231.
14. Yoshimoto K, Fukushi JI, Tsushima H, et al. Does preparation of the subtalar joint for primary union affect clinical outcome in patients undergoing intramedullary nail for rheumatoid arthritis of the hindfoot and ankle? *J Foot Ankle Surg*. 2020;59(5):984-987.
15. Nagashima M, Tachihara A, Matsuzaki T, Takenouchi K, Fujimori J, Yoshino S. Follow-up study of ankle arthrodesis in severe hind foot deformity in patients with rheumatoid arthritis using an intramedullary nail with fins. *Mod Rheumatol*. 2005;15(4):269-274.
16. Takenouchi K, Morishita M, Saitoh K, Wauke K, Takahashi H, Nagashima M. Long-term results of ankle arthrodesis using an intramedullary nail with fins in patients with rheumatoid arthritis hindfoot deformity. *J Nippon Med Sch*. 2009;76(5):240-246.
17. Niki H, Aoki H, Inokuchi S, et al. Development and reliability of a standard rating system for outcome measurement of foot and ankle disorders I: development of standard rating system. *J Orthop Sci*. 2005;10(5):457-465.
18. Yano K, Ikari K, Okazaki K. Radiographic outcomes of mobile-bearing total ankle arthroplasty for patients with rheumatoid arthritis. *Foot Ankle Int*. 2019;40(9):1037-1042.
19. Kondo N, Yamagishi T, Murasawa A, et al. The usefulness of ankle brace (MAX<sup>®</sup>) for highly destructive ankle joints in patients with rheumatoid arthritis. *Arch Niigata Soc Orthop Surg Traumatol*. 2000;16:23-26. Japanese.
20. Kapandji AI. Ankle joint. In: Kapandji AI, editor. *Anatomie Fonctionnelle II lower extremity*, 6th edn. Ishiyaku Publishers, Inc; 2015:160-161. Japanese.

**How to cite this article:** Takahashi S, Kondo N, Kijima Y, Kakutani R, Ishikawa H, Kawashima H. Ankle arthrodesis using a retrograde intramedullary rod with fins for highly destructive joints in elderly patients with rheumatoid arthritis: A report of two cases. *Clin Case Rep*. 2022;10:e05348. doi:[10.1002/ccr3.5348](https://doi.org/10.1002/ccr3.5348)