

A spontaneous protruded angle-supported anterior chamber intraocular lens

A case report

Hsin-Le Lin, MD, Gow-Lieng Tseng, MD, PhD*

Abstract

Rationale: Anterior chamber intraocular lens (ACIOL) remains a surgical option for visual rehabilitation during complicated cataract surgeries with minimal or no capsular support. ACIOL causing scleral perforation is rare, and the involved causes remain debatable.

Patient concerns: Here, we present the case of a 62-year-old female with spontaneous protrusion of an angle-supported ACIOL haptic tip through an extracapsular cataract extraction (ECCE) wound, who presented with progressive right-eye ptosis and right-side headache.

Diagnosis: The slit lamp examination showed a vertically aligned angle-supported Kelman Multiflex ACIOL in the anterior chamber. The ACIOL had deviated upward, with upper haptic protruding from the previous ECCE scleral tunnel wound. Fundus examination and optical coherence tomography (OCT) revealed cystoid macular edema (CME) with mild epiretinal membrane (ERM).

Interventions: The patient was treated with ACIOL extraction, pars plana vitrectomy, ERM peeling, and scleral-fixated posterior chamber IOL implantation.

Outcomes: Three months after surgery, the best-corrected visual acuity in the right eye improved to 20/80 and the right-side headache and hyperemia of the conjunctiva had significantly subsided. Repeated OCT revealed improved CME.

Lessons: Poor construction of the scleral tunnel incision may cause wound dehiscence. The vertically aligned ACIOL haptic tip resting at the angle may exert stress toward the dehiscence wound, exacerbating tissue erosion and causing scleral perforation with haptic tip exposure.

Abbreviations: ACIOL = anterior chamber intraocular lens, anti-VEGF = anti-vascular endothelial growth factor, BCVA = best-corrected visual acuity, CME = cystoid macular edema, ECCE = extracapsular cataract extraction, ERM = epiretinal membrane, IOL = intraocular lens, OCT = optical coherence tomography, PCIOL = posterior chamber intraocular lens.

Keywords: anterior chamber intraocular lens, cataract surgery, scleral perforation

1. Introduction

The use of anterior chamber intraocular lens (ACIOL) after cataract extraction was first introduced in the 1960s.^[1,2] Although complications associated with ACIOL, including chronic inflammation, bullous keratopathy, glaucoma, cystoid macular edema (CME), and deformed pupil, have been reported,^[3] ACIOL remains a surgical option for visual rehabilitation during complicated cataract surgery with minimal or no capsular support. Eyes with traumatic wound dehiscence

after extracapsular cataract extraction (ECCE) and intraocular lens (IOL) implantation have been described in the literature.^[4] The occurrence of spontaneous IOL protrusion from a poorly constructed scleral wound without traumatic force is relatively rare. In addition, haptic tip exposure is not commonly observed among ACIOL complications. In the present article, we report a case of spontaneous protrusion of an angle-supported ACIOL haptic tip through upper limbus, causing scleral perforation.

2. Case report

A 62-year-old female presented to our department with a 6-month history of red eye and progressive right-eye ptosis with right-side headache for 2 months. Two years earlier, she underwent right-eye ECCE and ACIOL implantation due to intraoperative zonular dialysis. Postoperatively, the best corrected visual acuity (BCVA) was 20/25. The patient did not report any traumatic history. She had no underlying diseases (eg, diabetes mellitus, allergy, or autoimmune disease). The patient noticed blurred vision and redness in the right eye approximately 6 months before the current presentation. She received treatment twice with intravitreal injections of bevacizumab for unspecified CME in the right eye at a local clinic, without the improvement of symptoms.

At our clinic, the ophthalmic examination revealed a BCVA of 20/630 and 20/20 in the right and left eye, respectively. The intraocular pressure was 8 and 15 mm Hg, respectively. The slit lamp examination showed right-side diffuse limbal neovasculari-

Editor: N/A.

The authors declare that they have no conflicts of interest.

Department of Ophthalmology, Taipei City Hospital, Renai Branch, Taipei, Taiwan.

* Correspondence: Gow-Lieng Tseng, Department of Ophthalmology, Taipei City Hospital, Renai Branch, No. 10, Sec. 4, Renai Road, Daan District, Taipei City 10629, Taiwan (e-mail: daa26@tpech.gov.tw).

Copyright © 2019 the Author(s). Published by Wolters Kluwer Health, Inc. This is an open access article distributed under the terms of the Creative Commons Attribution-Non Commercial License 4.0 (CCBY-NC), where it is permissible to download, share, remix, transform, and buildup the work provided it is properly cited. The work cannot be used commercially without permission from the journal.

Medicine (2019) 98:22(e15814)

Received: 19 December 2018 / Received in final form: 13 April 2019 / Accepted: 29 April 2019

<http://dx.doi.org/10.1097/MD.00000000000015814>

zation and serious bulbar conjunctiva injection. The pupil was oval and distorted to the upper side. A peripheral iridectomy was detected at the 6 o'clock position, and a vertically aligned angle-supported Kelman Multiflex ACIOL was found in the anterior chamber. The ACIOL had deviated upward, with upper haptic protruding from the previous ECCE scleral tunnel wound. The upper haptic was exposed without coverage of the intact conjunctiva (Fig. 1). We performed a Seidel test, which was positive. Fundus examination and optical coherence tomography (OCT) revealed CME with mild epiretinal membrane (ERM) (Fig. 2). The white-to-white distance was 13.4 mm. The examination of the left eye was unremarkable.

Considering the risk of endophthalmitis, the patient agreed to undergo extraction of the ACIOL. During operation, the ACIOL was easily extracted by loosening the fragile tissues surrounding the perforated wound after conjunctival peritomy. The sclera and conjunctiva wounds were erosive and dehiscent. Afterwards, the perforated wounds were sutured. The upper part of the intact conjunctiva was advanced toward the limbus to cover and protect the sutured scleral wound. Subsequently, we performed pars plana vitrectomy, ERM peeling, and scleral-fixated posterior chamber IOL (PCIOL) implantation using an Alcon CZ70BD (Alcon, Fort Worth) poly methyl methacrylate lens.

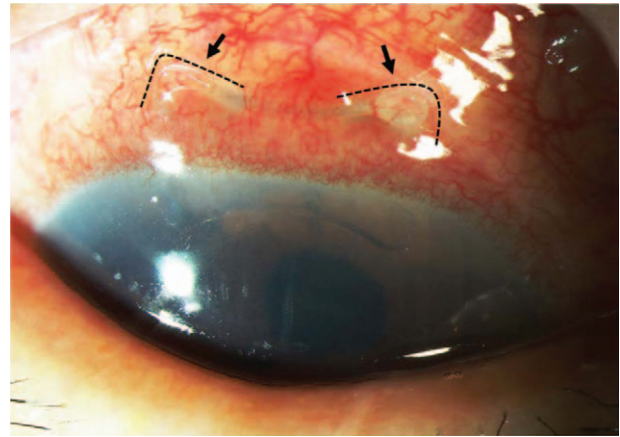


Figure 1. The angle-supported Kelman Multiflex anterior chamber intraocular lens was vertically aligned. The upper haptic was exposed from the upper limbus, perforating sclera, and conjunctiva (arrow).

Three months after surgery, the BCVA in the right eye improved to 20/80 and the right-side headache and hyperemia of the conjunctiva had significantly subsided. Moreover, the cornea and anterior chamber were clear. The iris was oval-shaped and

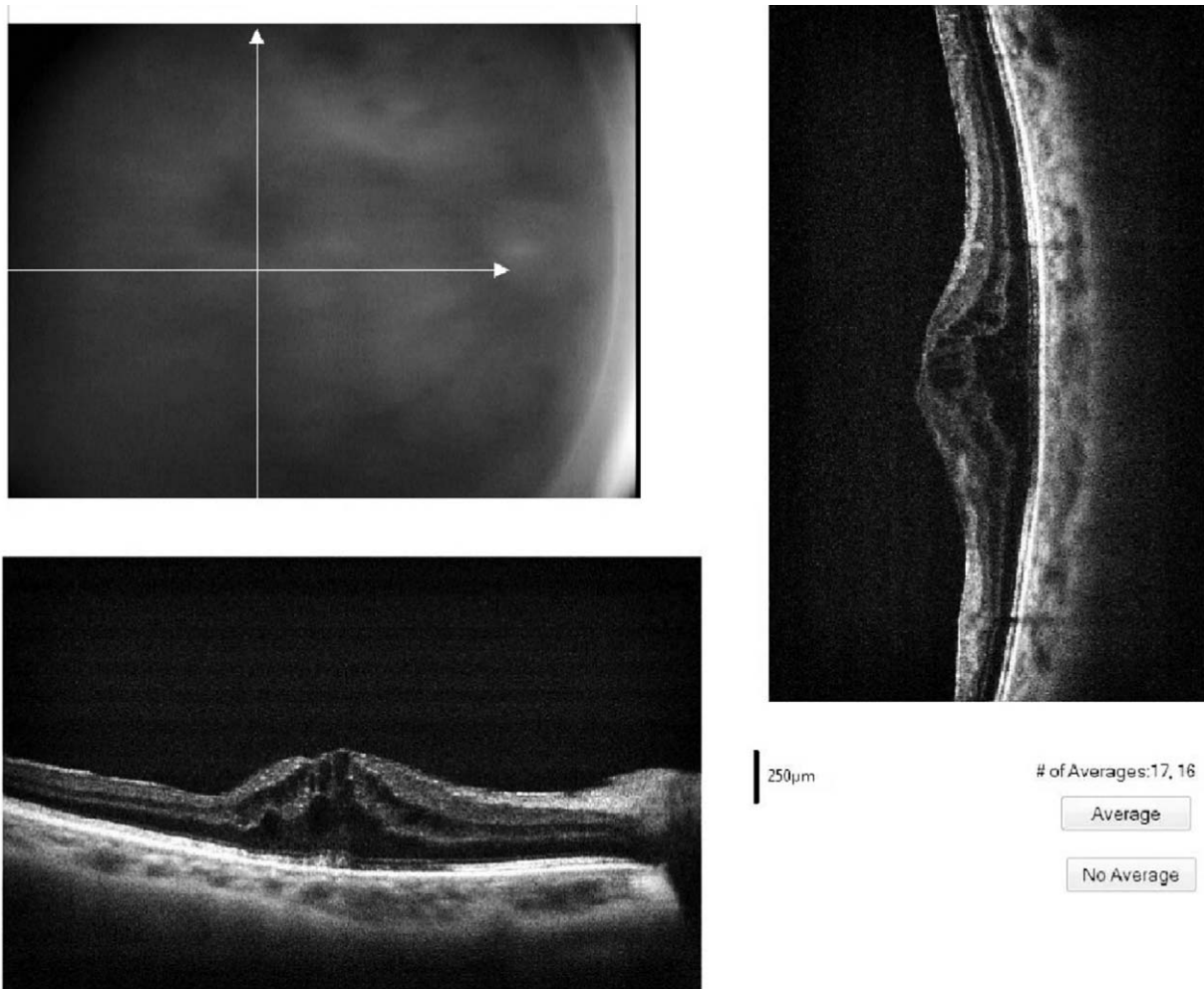


Figure 2. Preoperative optical coherence tomography revealed cystoid macular edema with mild epiretinal membrane. The central retinal thickness was 596 μm.

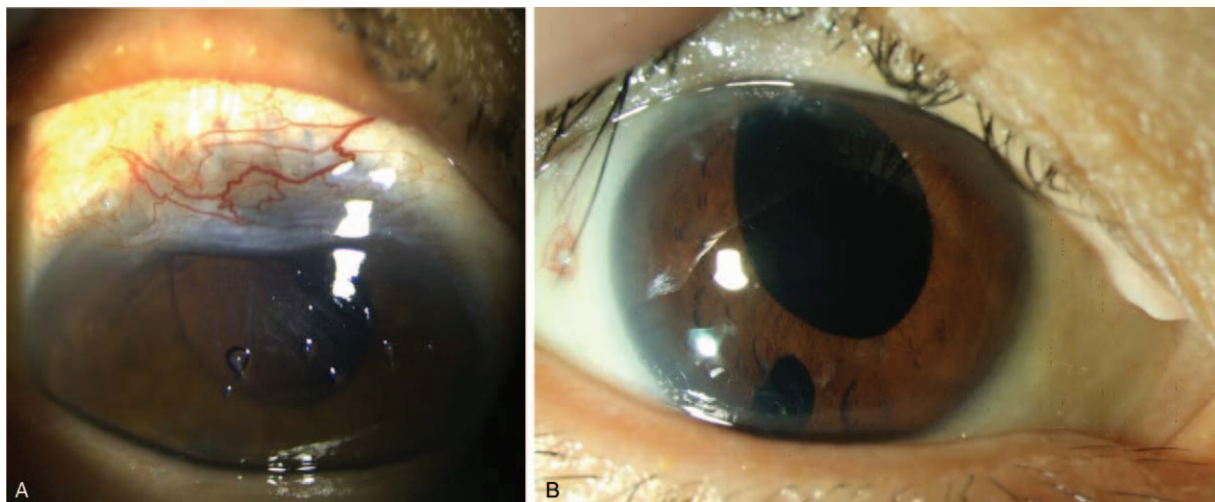
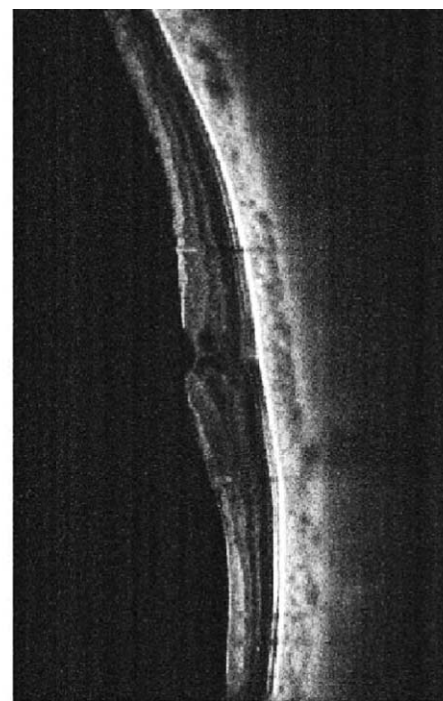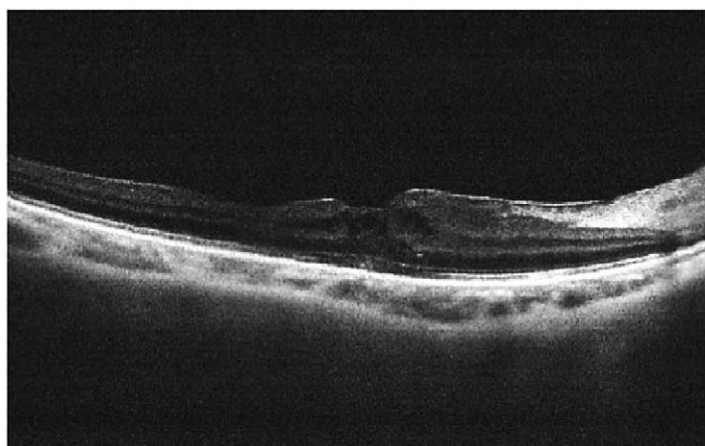


Figure 3. After operation, the ocular surface injection was significantly improved. The upper-part intact conjunctiva was advanced toward the limbus to cover and protect the sutured scleral wound. (A) The iris was oval-shaped, and the scleral-fixated PCIOL remained centrally located (B).



250µm # of Averages:17, 15

Figure 4. After 3 months of the operation, optical coherence tomography revealed improved cystoid macular edema with mild residual epiretinal membrane. The central retinal thickness was 320µm.

shifted upwardly. The scleral-fixated PCIOL remained centrally located (Fig. 3). Fundus examination and repeated OCT revealed improved CME with decreased central retinal thickness (Fig. 4).

Written informed consent was provided by the patient for the publication of this case report.

3. Discussion

The potential complications of ACIOL implantation include endothelial failure with cornea edema, chronic intraocular inflammation, secondary glaucoma, uveitis-glaucoma-hyphema syndrome, and CME.^[5,6] The occurrence of spontaneous scleral perforation caused by ACIOL dislocation is relatively rare.

To our knowledge, Kumar et al^[7] reported the first case of subconjunctival dislocation of a Kelman Multiflex ACIOL after sustaining a blunt injury. In this case report, the ACIOL was located 4mm from the superior limbus, causing chronic inflammation with CME and mild vitritis. In addition, Gungel et al^[8] reported a case of bilateral eyes with ACIOL tip spontaneous exposure causing open-globe injury. They suggested that the possible risk factors of ACIOL tip exposure may be chronic allergic conjunctivitis with frequent eye rubbing causing minor trauma and the long-term use of topical steroids causing scleral and corneal thinning. Rong and Lu^[9] reported a case of ocular rosacea, in which spontaneous ACIOL haptic tip exposure through the inferior limbus was detected 22 years after cataract extraction. Rong and Lu assumed that the ACIOL inferior protrusion may be the result of gravity on the ACIOL, chronic vigorous rubbing of the eye tissue, and oversize of the ACIOL. However, the main causes of ACIOL haptic tip exposure remained undetermined.

In the present case, the ACIOL upper haptic tip was exposed through the superior limbus. Notably, the previous ECCE scleral tunnel wound was found to be erosive and dehiscent. Therefore, the ACIOL was extracted without effort after conjunctival peritomy. We assumed that the vertically placed angle-supported ACIOL applied stress on the “angle,” which was near to the scleral tunnel wound. The stress pressed on the wound interfered with wound healing and facilitated ACIOL haptic tip exposure (Fig. 5B and C).

Scleral tunnel incision is the initial step of cataract surgery. Scleral tunnel incisions may occasionally be challenging for an inexperienced surgeon. A properly constructed wound is expected to be a water-tight tri-planar incision (Fig. 5A). A poorly constructed wound (ie, excessively deep or superficial, excessively wide or narrow) may lead to surgical consequences. Excessively deep penetration of the scalpel may result in direct injury to the anterior chamber (Fig. 5B), leading to globe perforation, injury to the ciliary body, and a poorly closed scleral incision. On the contrary, an overly superficial incision may result in a thin scleral flap and proneness to tearing. Inexperienced surgeons may consider performing a direct 1-plane scleral groove instead of a triplanar incision (Fig. 5C). Although, in the present case, we were unable to determine the record of the patient’s initial surgical condition, it is thought that the scleral tunnel was poorly constructed, with premature entry or a 1-plane incision. Moreover, the initial orientation of the ACIOL was unknown. A properly oriented ACIOL is placed into the iridocorneal angle with the footplates of the lens in contact with the scleral spur, and the haptics distant from iridectomies and wounds. In this case, the initial scleral tunnel was made at 12 o’clock and was poorly constructed. The ACIOL haptic was expected to place away from the scleral tunnel. However, in a proportion of cases, it is possible

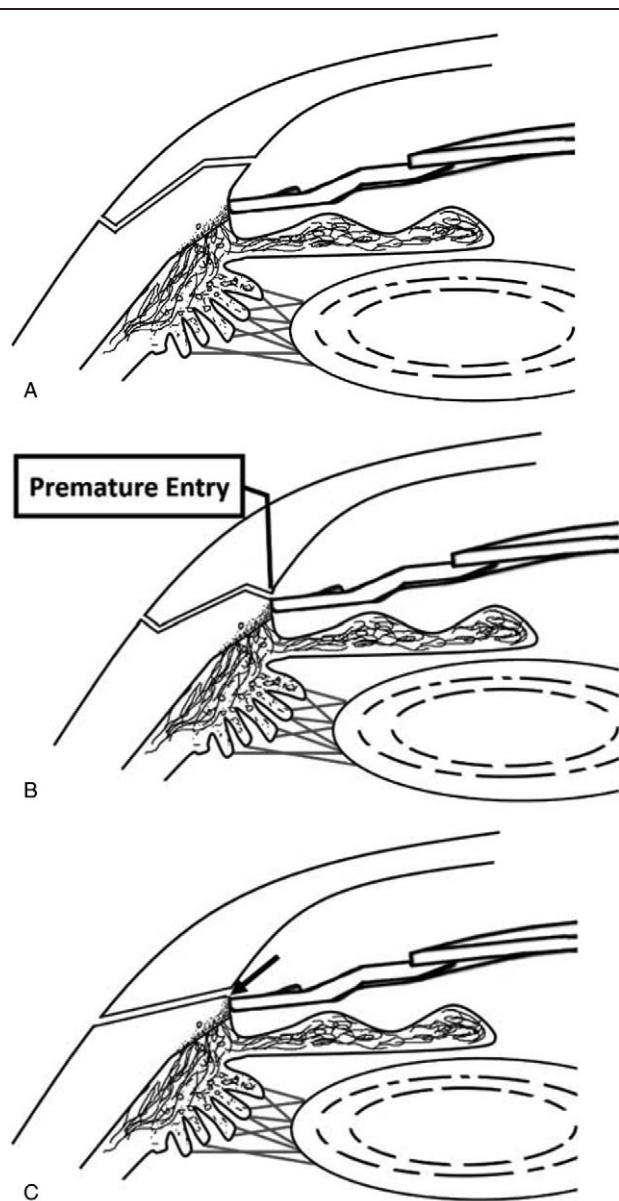


Figure 5. (A) A scleral tunnel with a triplanar incision. (B) A deep scleral tunnel incision with premature entry. (C) Scleral tunnel with a direct 1-plane incision. The ACIOL haptic tip resting on the angle-applied stress on the wound, interfered with wound healing (arrow), and facilitated ACIOL haptic tip exposure.

that the ACIOL may rotate from a horizontal to a vertical position a few years after implantation due to long-term eye rubbing or disparity in the size of the ACIOL.^[10]

In patients with ACIOL implantation, the potential movement of the IOL may cause inflammation in localized tissue, leading to prolonged CME. We hypothesize that the CME and ERM were sequelae of the localized inflammation process initiated after protrusion of the ACIOL haptic tip. Injection of antivascular endothelial growth factor (anti-VEGF) drugs is unable to inhibit the origins of inflammatory process. Currently, the most effective treatment to cease intraocular inflammation is removal of the ACIOL. In this case, after ACIOL extraction, the CME was controlled and the thickness of the central retina was reduced compared with that observed preoperatively. In general, good

vision may be restored after the resolution of the intraretinal fluid. However, in certain chronic or severe cases of CME, the resolution of the intraretinal fluid may not restore good vision if permanent damage to the macular cells has already occurred.^[11] In the present case, CME persisted for 6 months, despite the administration of injections with an anti-VEGF agent. It is thought that the retinal macular cells were already damaged, disrupting the integrity of the blood–retinal barrier.

In our opinion, poor construction of the scleral tunnel incision may cause wound dehiscence. The vertically aligned ACIOL haptic tip resting at the angle may exert stress toward the dehiscence wound, exacerbating tissue erosion and causing scleral perforation with haptic tip exposure. In such cases, IOL extraction and wound closure should be urgently managed to prevent wound infection and subsequent endophthalmitis. The early removal of the dislocated ACIOL may assist in controlling intraocular inflammation and improve CME. In contrast, delayed removal of an exposed ACIOL may cause prolonged CME, leading to permanent loss of vision.

Acknowledgments

We express our thanks to all colleagues and students who contributed to this study. Furthermore, we thank the editor, series editor, and reviewers for their constructive comments.

Author contributions

Conceptualization: Gow-Lieng Tseng.

Data curation: Hsinle Lin.

Investigation: Hsinle Lin.

Writing – original draft: Hsinle Lin.

Writing – review & editing: Hsinle Lin, Gow-Lieng Tseng.

References

- [1] Emmrich K. Correction of the aphakic eye with anterior chamber lenses. *Dtsch Gesundheitsw* 1958;13:353–5.
- [2] Strampelli B. Tolerance of acrylic lenses in the anterior chamber in aphakia and refraction disorders. *Ann Ottomol Clin Ocul* 1954;80:75–82.
- [3] Sawada T, Kimura W, Kimura T, et al. Long-term follow-up of primary anterior chamber intraocular lens implantation. *J Cataract Refract Surg* 1998;24:1515–20.
- [4] Johns KJ, Sheils P, Parrish CM, et al. Traumatic wound dehiscence in pseudophakia. *Am J Ophthalmol* 1989;108:535–9.
- [5] Apple DJ, Hansen SO, Richards SC, et al. Anterior chamber lenses. Part II: a laboratory study. *J Cataract Refract Surg* 1987;13:175–89.
- [6] Apple DJ, Brems RN, Park RB, et al. Anterior chamber lenses. Part I: complications and pathology and a review of designs. *J Cataract Refract Surg* 1987;13:157–74.
- [7] Kumar A, Nainiwal SK, Dada T, et al. Subconjunctival dislocation of an anterior chamber intraocular lens. *Ophthalmic Surg Lasers* 2002;33:319–20.
- [8] Gungel H, Altan C, Baylancicek DO. Endophthalmitis due to exposure of anterior chamber intraocular lens haptic tip. *J Cataract Refract Surg* 2009;35:1633–6.
- [9] Rong X, Lu Y. Spontaneous exposure of angle-supported anterior chamber intraocular lens haptic tip. *J Cataract Refract Surg* 2016;4:1–4.
- [10] Carlson AN, Stewart WC, Tso PC. Intraocular lens complications requiring removal or exchange. *Surv Ophthalmol* 1998;42:417–40.
- [11] Rotsos TG, Moschos MM. Cystoid macular edema. *Clin Ophthalmol* 2008;2:919–30.