

[CASE REPORT]

Favorable Outcome Following Sotrovimab Monoclonal Antibody in a Patient with Prolonged SARS-CoV-2 Omicron Infection with HIV/AIDS

Eisuke Adachi¹, Makoto Saito², Michiko Koga², Takeya Tsutsumi² and Hiroshi Yotsuyanagi^{1,2}

Abstract:

Persistent viral shedding or prolonged coronavirus disease 2019 (COVID-19) symptom is one of unresolved problem in immunocompromised individuals. We herein report an HIV/AIDS patient with *Pneumocystis jirovecii* pneumonia and prolonged COVID-19, possibly due to immune reconstitution inflammatory syndrome. His viral shedding and COVID-19 symptoms persisted for 39 days but were promptly resolved following sotrovimab monoclonal antibody therapy. This case suggests that prolonged COVID-19 and persistent viral shedding due to severe cellular immunodeficiency can occur in patients with severe acute respiratory syndrome coronavirus 2 (SARS-CoV-2) omicron infection and that sotrovimab is effective in the treatment of prolonged COVID-19 caused by omicron/BA.1.

Key words: prolonged COVID-19, HIV/AIDS, persistent viral shedding, passive immunity, monoclonal antibody therapy, sotrovimab

(Intern Med 61: 3459-3462, 2022)

(DOI: 10.2169/internalmedicine.0485-22)

Introduction

Since the beginning of the coronavirus disease 2019 (COVID-19) pandemic, it has remained a threat to immunocompromised people. Persistent viral shedding or prolonged COVID-19 symptoms is unresolved problems in immunocompromised individuals, especially in patients post-solid-organ-transplant, those using anti-CD20 monoclonal antibody and those with advanced HIV/AIDS (1, 2).

mRNA vaccines have been proven to reduce the severity of COVID-19. However, while immunocompromised individuals are highly encouraged to be vaccinated, they are at an increased risk of primary or secondary vaccine failure, so not everyone can benefit from these highly effective vaccines (3). Convalescent plasma therapy and neutralizing antibody therapy have been attempted for prolonged COVID-19 (4), and successful clearance of the virus with casirivimab plus imdevimab combination has been reported (5). However, because casirivimab plus imdevimab has no neu-

tralizing ability against severe acute respiratory syndrome coronavirus 2 (SARS-CoV-2) omicron (6), there is currently no effective treatment for prolonged COVID-19 infection caused by the omicron variant.

We herein report a case of prolonged COVID-19 caused by SARS-CoV-2 omicron/BA.1 complicated with unmasking *Pneumocystis jirovecii* pneumonia (PCP) in a patient with HIV/AIDS that was successfully treated with sotrovimab.

Case Report

A 47-year-old man with HIV presented to our hospital with a week-long low-grade fever and cough. He had been on antiretroviral therapy (ART), but his adherence had been poor for several years and he had not taken any medication for the past three years. His SARS-CoV-2 quantitative reverse transcription polymerase chain reaction (qRT-PCR) test result was positive, and the SARS-CoV-2 omicron/BA.1 was identified based on L452R-, S371L+ and S373P+ using VirSNiP SARS-CoV-2 Spike L452R and VirSNiP SARS-

¹Department of Infectious Diseases and Applied Immunology, IMSUT Hospital of the Institute of Medical Science, the University of Tokyo, Japan and ²Division of Infectious Diseases, Advanced Clinical Research Center, Institute of Medical Science, the University of Tokyo, Japan
Received: June 13, 2022; Accepted: July 24, 2022; Advance Publication by J-STAGE: September 6, 2022

Correspondence to Eisuke Adachi, eadachi-ims@umin.ac.jp

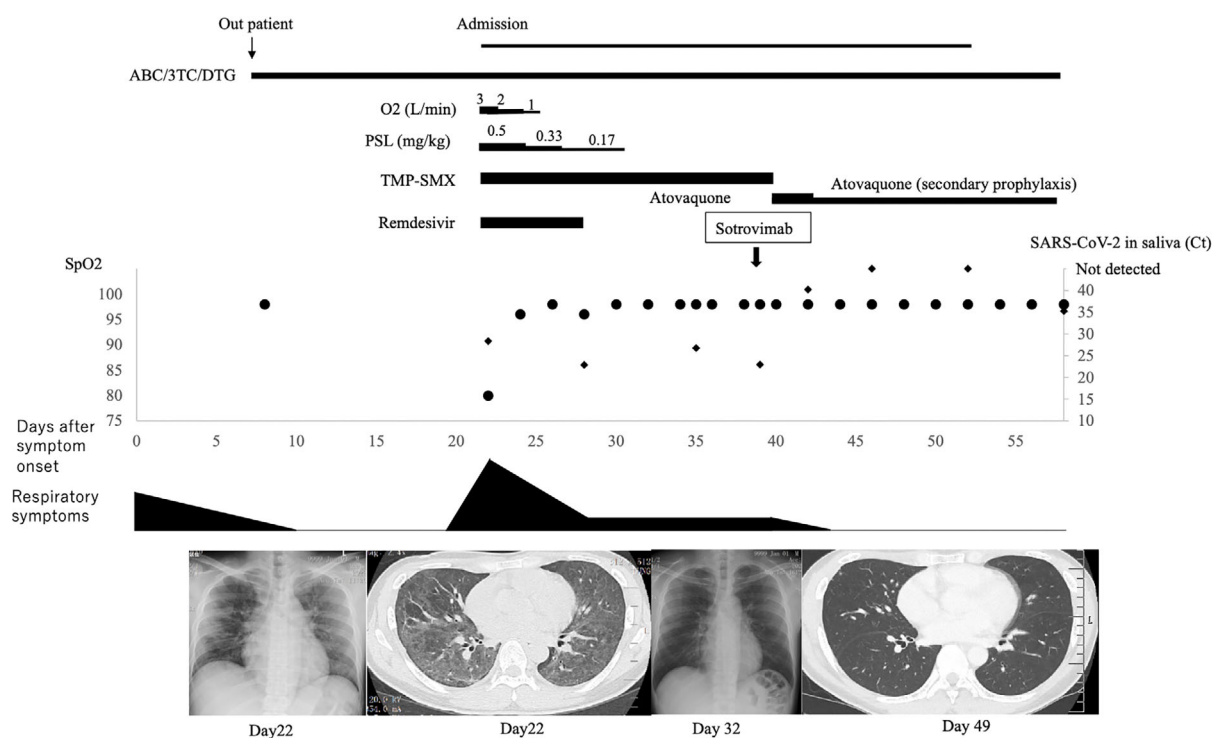


Figure. The course of treatment from outpatient to post-hospitalization. The chest tomography findings shown are from Day 22 and Day 49 on left and right, respectively, and the chest X-ray images are from Day 22 and Day 32 on left and right, respectively. Ct: cycle threshold value, ABC/3TC/DTG: abacavir/lamivudine/dolutegravir, TMP-SMX trimethoprim-sulfamethoxazole

CoV-2 Spike S371L/S373P (TIB MLBIOL, Berlin, Germany). His blood test showed a slightly elevated C-reactive protein (CRP) level of 0.70 mg/mL, CD4+ T cell count of 47 cells/ μ L and HIV RNA count of 36,000 copies/mL.

As he did not require oxygen administration and was showing improvement on the eighth day after the onset and we were unable to assess his immune status on the same day, he was treated at home and restarted on ART with abacavir/lamivudine/dolutegravir (ABC/3TC/DTG). Over the following 10 days, his condition gradually ameliorated; however, 14 days later, he was brought to our hospital with a fever of 39°C and dyspnea.

A physical examination showed a high breathing frequency of 30/min and low pulse oxygenation of 80. Infiltration mixed with ground-glass attenuation (GGA) was found over the entire bilateral lung fields on a chest computed tomography (CT) (Figure). Blood test findings at admission are shown in Table 1. In addition, based on the positive result of PCR for *Pneumocystis jirovecii* (*P. jirovecii* Quantitative-LQ; BML, Tokyo, Japan) using his sputum sample and a positive plasma 1,3- β -D-Glucan of 210 pg/mL, he was diagnosed with PCP. His HIV-RNA level had decreased to 34 copies/mL, suggesting that he had developed unmasking immune reconstitution inflammatory syndrome (IRIS) associated with PCP.

The course of treatment from outpatient to post-hospitalization is shown in Figure. We started trimethoprim-sulfamethoxazole (TMP-SMX; 15 mg/kg/day of TMP) with

prednisolone (PSL; tapering from 0.5 mg/kg over 9 days) and remdesivir for 5 days considering the paradoxical IRIS of COVID-19. ART was continued after admission. TMP-SMX was discontinued after 18 days due to skin rash and switched to atovaquone (1,500 mg/day), which was continued as secondary prophylaxis after the treatment period. Following the treatment, his symptoms subsided, and he no longer required oxygen administration after three days. PSL administration was discontinued after chest X-ray showed disappearance of GGA. However, mild symptoms, such as sore throat and cough, persisted, and the SARS-CoV-2 viral load did not decrease in saliva or nasopharyngeal (NP) swab samples after stopping remdesivir administration.

The results of qRT-PCR for SARS-CoV-2 after the onset of symptoms are shown in Table 2. Since the viral load estimated from the cycle threshold (Ct) value remained consistently high, and the anti-spike protein IgG (Alinity SARS-CoV-2 IgG II Quant assay; Abbott, Chicago, USA) also did not increase from the onset to day 39, it was inferred that achieving a cure by the restoration of cellular immunity would take longer, so we decided to administer the neutralizing antibody with the aim of curing the disease in a shorter period of time.

After administration of sotrovimab, his symptoms promptly resolved; his inflammation markers, such as CRP, ferritin, and soluble interleukin-2 (IL-2) receptor, decreased to a normal range; and his viral load gradually decreased with the clearance of the viral RNA in saliva seven days af-

Table 1. Blood Test Findings at Admission.

AST	19 U/L	PT	14.3 s
ALT	15 U/L	APTT	40.3 s
LDH	304 U/L	Fib	525 mg/dL
UN	13.8 mg/dL	D-dimer	1.2 µg/mL
Cre	0.87 mg/dL	WBC	12,780 cells/µL
CK	28 U/L	Lym	1,080 cells/µL
TC	148 mg/dL	Hb	12.2 g/dL
TP	6.4 g/dL	Plt	38.5×10 ⁴ cells/µL
Alb	2.7 g/dL	CD4+cell count	47 cells/µL
CRP	0.70 mg/dL	HIV-RNA	36,000 copies/mL
Ferritin	288 ng/mL	CMV-Ag (C10, C11)	Negative
Soluble IL-2 receptor	969 U/mL	Cryptococcus-Ag	Negative
Anti-spike protein IgG	<50 AU/mL	1,3-β-D-Glucan	210 pg/mL

AST: aspartate aminotransferase, ALT: alanine aminotransferase, LDH: lactate dehydrogenase, UN: urine nitrogen, Cre: creatinine, CK: creatinine kinase, TC: total cholesterol, TP: total protein, Alb: albumin, CRP: C-reactive protein, PT: prothrombin time, APTT: activated partial thromboplastin time, Fib: fibrinogen, WBC: white blood cells, Lym: lymphocyte, Hb: hemoglobin, Plt: platelets, CMV: cytomegalovirus

Table 2. The Results of the Quantitative RT-PCR Test for SARS-CoV-2 and the Status of HIV Infection.

Days from the symptom onset	Remdesivir				Sotrovimab					
	Day 8	Day 22	Day 28	Day 35	Day 39	Day 42	Day 46	Day 53	Day 58	Day 75
CD4+cell count (cells/µL)	47	45	80	26	52	70	42	55	37	49
HIV-RNA (copies/mL)	36,000	34	n.d	n.d	n.d	n.d	<20	n.d	n.d	Not detected
SARS-CoV-2 in NP swab (Ct)	23.1	22.5	16.4	16.0	18.0	21.6	23.5	22.2	27.8	Not detected
SARS-CoV-2 in saliva (Ct)	n.d	28.4	22.9	26.8	23.0	30.3	Not detected	n.d	35.3	Not detected
Anti-spike protein IgG (AU/mL)*	<50	<50	<50	<50	<50	23,970	18,088	15,151	16,099	10,279
CRP (mg/dL)	0.70	2.18	0.15	1.07	0.51	0.15	0.44	0.05	0.24	0.40
Ferritin (ng/mL)	288	387	392	381	n.d	288	263	213	214	90
Soluble IL-2 receptor (U/mL)	969	1,048	895	1,451	n.d	605	500	418	477	400

Ct: cycle threshold value, NP: nasopharyngeal, CRP: C-reactive protein, n.d: no data

* Cut off Value, 50 AU/mL

ter administration. He was discharged with a negative result on a saliva sample test, and at the second outpatient visit, five weeks after administration, viral RNA in an NP swab sample was confirmed to be negative.

Discussion

There are many evidence gaps regarding COVID-19 in immunocompromised individuals. The present study highlights the notion that immunocompromised people are at an increased risk of not only severe disease but also long-lasting persistent viral shedding. Previously reported patients with prolonged COVID-19 or persistent viral shedding, as in this case, did not have a post-infection antibody response (1, 7). Patients with severe cellular immunodeficiency, in which an adequate initial immune response to pathogens does not occur, are at a high risk of prolonged COVID-19 (7, 8). With more than 38 million people worldwide infected with HIV and having potentially severe cellular immunodeficiency, prolonged COVID-19 will continue to be a public health problem.

Given that severe cellular immunodeficiency is associated

with a high risk of primary vaccine failure, including mRNA vaccine (3), passive immunity is a reasonable option for patients with primary vaccine failure in order to treat and prevent prolonged COVID-19. Clinical trials are underway to use passive immunity as therapy in cases of HIV infection where the vaccine has failed to induce sufficient neutralizing antibodies against HIV. There have been reports of successful clearance of SARS-CoV-2 persisting for more than six months in patients with secondary antibody deficiency administered casirivimab plus imdevimab combination therapy (5).

However, due to the nature of passive immunization with monoclonal antibodies, immune evasion of SARS-CoV-2 can significantly affect the therapeutic strategy for prolonged COVID-19. Omicron variants in particular are known to have immune evasion potential, with these variants showing at least 33 mutations compared with early SARS-CoV-2 strains identified in Wuhan, China (9). Notably, 15 of the 29 amino acid substitutions were in the receptor-binding domain of the S protein, which is the primary target for monoclonal antibody therapy. Casirivimab plus imdevimab combination retained activity against the beta and gamma variants

but lost inhibitory capability against the omicron/BA1 variant (6). S309, the precursor to the drug marketed as sotrovimab, also retained neutralizing activity against the beta, gamma, and omicron variants, although less neutralizing activity was reported for the omicron variant than for the beta or gamma variant (6).

To our knowledge, this is the first report of prolonged COVID-19 caused by omicron variant infection, and clinicians should keep in mind that prolonged COVID-19 and persistent viral shedding can occur in patients with SARS-CoV-2 omicron infection, as was the case with previously circulating variants of concern (VOC). Furthermore, our case demonstrates the efficacy of sotrovimab against prolonged COVID-19 in a clinical setting; neutralizing antibody therapy results in the rapid clearance of extracellular viruses in saliva but with a slower rate of reduction in NP swab samples, which reflect the presence of viruses in pharyngeal epithelial cells. Neutralizing antibodies may prevent reentry of viruses to cells and reduce the viral load in saliva but be unable to inhibit the replication of intracellular viral RNA. Passive immunization strategies may thus not remain effective against VOCs that circulate in the future. We need to continue to investigate which monoclonal antibodies are effective against newly emerging endemic VOCs.

Another possible alternative treatment option is to restore immunity. Previously reported prolonged COVID-19 and viral shedding that persisted for several months disappeared spontaneously, and in several other reported cases of HIV co-infection, prolonged COVID-19 was cured with the restoration of cellular immunity by ART (8). However, these reports showed that full recovery from COVID-19 takes several months, and even when there were signs of immune recovery, such as pulmonary IRIS, as in this report, viral shedding was not suppressed. To detect prolonged COVID-19 in the early stage and perform intervention treatment early, it may be useful to examine the antibody response.

Our case also highlights clinical issues related to the management of HIV/AIDS. The rapid progression 14 days after ART initiation in our patient could have been paradoxical IRIS of COVID-19, but it was unclear which pathogen caused the symptoms, due to *P. jirovecii* co-infection. Pulmonary IRIS has been described in *Mycobacterium tuberculosis*, *M. avium complex*, *P. jirovecii*, *Cryptococcus neoformans* and Kaposi's sarcoma and can present with a spectrum of clinical manifestations, including pneumonitis, pulmonary infiltrates, lymphadenopathy, cough and dyspnea (10). Although the virulence of SARS-CoV-2 is highly associated with host cellular immunity, further findings are needed to determine whether or not SARS-CoV-2 is involved in pulmonary IRIS.

In summary, sotrovimab appears to be effective against

persistent viral shedding and prolonged COVID-19 caused by SARS-CoV-2 omicron/BA.1 and is expected to accelerate the cure of COVID-19 in HIV/AIDS patients. Passive immunization is currently the only treatment for persistent viral shedding or prolonged COVID-19 in immunocompromised patients, and the efficacy of monoclonal antibody products should be evaluated in the event of a novel VOC outbreak.

Ethics approval was granted by the ethics board of the Institute of Medical Science, University of Tokyo.

The authors state that they have no Conflict of Interest (COI).

References

1. Tarhini H, Recoing A, Bridier-Nahmias A, et al. Long-term severe acute respiratory syndrome coronavirus 2 (SARS-CoV-2) infectiousness among three immunocompromised patients: from prolonged viral shedding to SARS-CoV-2 superinfection. *J Infect Dis* **223**: 1522-1527, 2021.
2. Nakajima Y, Ogai A, Furukawa K, et al. Prolonged viral shedding of SARS-CoV-2 in an immunocompromised patient. *J Infect Chemother* **27**: 387-389, 2021.
3. Touizer E, Alrubayyi A, Rees-Spear C, et al. Failure to seroconvert after two doses of BNT162b2 SARS-CoV-2 vaccine in a patient with uncontrolled HIV. *Lancet HIV* **8**: e317-e318, 2021.
4. Hueso T, Pouderoux C, Péré H, et al. Convalescent plasma therapy for B-cell-depleted patients with protracted COVID-19. *Blood* **136**: 2290-2295, 2020.
5. Taha Y, Wardle H, Evans AB, et al. Persistent SARS-CoV-2 infection in patients with secondary antibody deficiency: successful clearance following combination casirivimab and imdevimab (REGN-COV2) monoclonal antibody therapy. *Ann Clin Microbiol Antimicrob* **20**: 85, 2021.
6. Takashita E, Kinoshita N, Yamayoshi S, et al. Efficacy of antibodies and antiviral drugs against COVID-19 omicron variant. *N Engl J Med* **386**: 995-998, 2022.
7. Spinelli MA, Lynch KL, Yun C, et al. SARS-CoV-2 seroprevalence, and IgG concentration and pseudovirus neutralising antibody titres after infection, compared by HIV status: a matched case-control observational study. *Lancet HIV* **8**: e334-e341, 2021.
8. Ketels T, Gisolf J, Claassen M, et al. Prolonged COVID-19 infection in a patient with newly diagnosed HIV/AIDS. *AIDS Res Hum Retroviruses* **38**: 399-400, 2022.
9. Qin S, Cui M, Sun S, et al. Genome characterization and potential risk assessment of the novel SARS-CoV-2 variant omicron (B.1.1.529). *Zoonoses* **1**: 2737-7466, 2021.
10. Gopal R, Rapaka RR, Kolls JK. Immune reconstitution inflammatory syndrome associated with pulmonary pathogens. *Eur Respir Rev* **26**: 160042, 2017.

The Internal Medicine is an Open Access journal distributed under the Creative Commons Attribution-NonCommercial-NoDerivatives 4.0 International License. To view the details of this license, please visit (<https://creativecommons.org/licenses/by-nc-nd/4.0/>).