



Efficacy and Safety of Endoscopic Nasopharyngectomy Combined With Low-Dose Radiotherapy for Primary T1-2 Nasopharyngeal Carcinoma

Technology in Cancer Research & Treatment
Volume 20: 1-7
© The Author(s) 2021
Article reuse guidelines:
sagepub.com/journals-permissions
DOI: 10.1177/15330338211011975
journals.sagepub.com/home/tct


Benjian Zhang, MD¹, Yiliang Li, MD¹, Jingjin Weng, MD¹,
Bo Huang, MD¹, Molu Ban, MD¹, Guiping Lan, MD¹, Yu Lu, MD¹,
Jianhui Luo, MD¹, Shenhong Qu, MD¹, and Yongfeng Si, MD¹ 

Abstract

Aim: Intensity-modulated radiotherapy (IMRT) is a widely accepted therapy for nasopharyngeal carcinoma (NPC), but it inevitably brings out radiation-related complications and seriously affects the quality of life (QoL). Endoscopic nasopharyngectomy (ENPG) has been successfully conducted in locally recurred NPC, but few studies evaluated its application in early NPC. This study aims to assess the feasibility and safety of ENPG combined with low-dose radiotherapy (LDRT) in T1-2 NPC. **Patients and Methods:** We recruited 37 newly diagnosed localized T1-2 NPC patients who voluntarily accepted ENPG +LDRT from June 2013 to September 2016. Meanwhile, the data of 132 T1-2 NPC patients treated with IMRT were collected and used as control group. The survival outcomes, QoL score and late RT-related sequelae were compared between the 2 groups. **Results:** After a median follow-up of 54 months, only 1 patient in ENPG+LDRT group died along with hepatic metastases. The 5-year overall survival, distant metastasis-free survival, local relapse-free survival and regional relapse-free survival in ENPG+LDRT group were 97.3%, 97.3%, 100% and 100%, which were not statistically different from the control group (97.7%, 90.2%, 95.5%, 97.0%, respectively, all $P > 0.05$). In comparison with IMRT group, ENPG+LDRT exhibited better QoL and less rate of late RT-related sequelae including hearing loss (53.8% vs 27.0%, $P = 0.005$), xerostomia (46.2% vs 24.3%, $P = 0.023$) and dysphagia (25.8% vs 8.1%, $P = 0.024$). **Conclusions:** ENPG+LDRT provided satisfactory survival outcomes, and improved the QoL and reduced the incidence of sequelae for T1-2 NPC patients.

Keywords

nasopharyngeal carcinoma, endoscopic nasopharyngectomy, intensity-modulated radiotherapy, low-dose radiotherapy, quality of life

Received: October 06, 2020; Revised: January 26, 2021; Accepted: March 29, 2021.

Introduction

Nasopharyngeal carcinoma (NPC) is highly prevalent in south-eastern China and other Asian countries, where the incidence even reaches to 50/100,000 people per year.¹ According to the World Health Organization (WHO) standards, the histopathologic type of NPC is divided into keratinized and non-keratinized types, grade of which is classified into differentiated and undifferentiated types, and more than 90% them are undifferentiated non-keratinizing.² Because of the special anatomical location of the nasopharynx, early local NPC is hard to detected, and most cases are in the advanced stage when they are diagnosed.³ These clinical and biological characteristics of NPC and its high

sensitivity to radiotherapy limit the application of surgery and make radiotherapy (RT) an unassailable track record as the backbone of NPC therapy.

¹ Department of Otolaryngology—Head and Neck Oncology, The People's Hospital of Guangxi Zhuang Autonomous Region, Nanning, China

Corresponding Author:

Yongfeng Si, MD, Department of Otolaryngology—Head and Neck Oncology, The People's Hospital of Guangxi Zhuang Autonomous Region, No. 6 of Taoyuan Road, Qingxiu District, Nanning 530021, China.
Email: gxsyongfeng@163.com



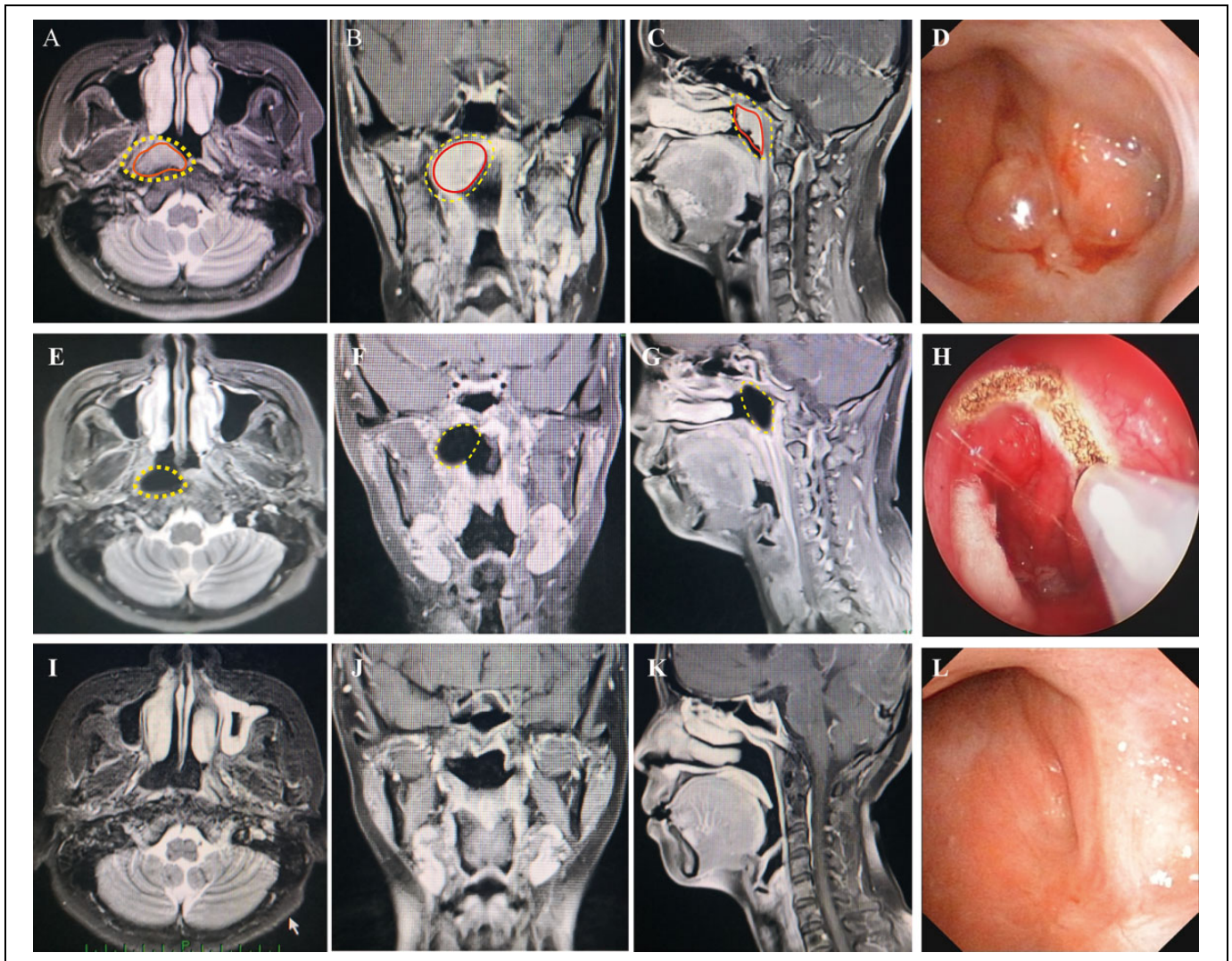


Figure 1. Comparisons of preoperative magnetic resonance imaging and endoscopic images to postoperative results. (A-C) T1-weighted magnetic resonance imaging in horizontal, coronal and sagittal planes showed tumor infiltration area (red line) and scope of operation (yellow line) before surgery. (D) Preoperative endoscopic image showed the tumor was in the right superior wall of the nasopharynx, which infiltrated into the bilateral pharyngeal recesses and eustachian tubes. (E-G) T1-weighted magnetic resonance imaging in horizontal, coronal and sagittal planes showed extent of surgical depletion, at 3 days after surgery. The scope of the excision is consistent with the plan (yellow line). (H) Intraoperative endoscopic image (I-K) T1-weighted magnetic resonance imaging in horizontal, coronal and sagittal planes found no signs of tumor recurrence, at 6 years after surgery. (L) Contemporaneous endoscopic image showed well epithelized nasopharyngeal mucous membrane and no signs of tumor recurrence.

Up to date, intensity-modulated RT (IMRT) is the standard RT modality, it provides a high dose of radiation to the tumor bed to achieve local control and protects surrounding structures from high-dose radiation damage. However, NPC patients continue to suffer from a high rate of severe RT-related complications because of high doses of radiation.⁴ Recently, several studies reported that low-dose radiotherapy (LDRT) can achieve long-term tumor control with mild late toxicities for T1-2 NPC patients, but the rate of recurrence is relatively high.^{5,6} With the popularity of health education and the development of early cancer screening methods such as narrow band imaging technique, plasma Epstein-Barr virus (EBV) DNA screening and nasopharyngeal brushing samples detection, the

detection rate of early-stage NPC in high-risk groups has been greatly improved, making it possible to perform endoscopic nasopharyngectomy (ENPG) for these NPC patients.^{7,8} Previous publications have observed that salvage ENPG were successfully conducted in recurrent NPC patients and resulted in better survival outcomes and less occurrence of complications than IMRT.⁹ Therefore, it is theoretically feasible to apply ENPG to resect localized early-stage NPC and avoid RT-related sequelae. In a recent study, Liu *et al*¹⁰ treated 10 localized stage I NPC patients with single ENPG, and these patients all got good long-term survival outcomes with zero recurrence and satisfactory QoL. However, the number of patients in that study was small and the risk of tumor recurrence is uncertain,

Table 1. Characteristics of NPC Patients According to Their Therapeutic Regimen.

Variable	IMRT (n = 132)	ENPG+LDRT (n = 37)	P value
Age (years)	47.6 ± 10.8	46.1 ± 10.6	0.454
Gender			0.841
Male	92 (69.7)	25 (67.6)	
Female	40 (30.3)	12 (32.4)	
BMI (kg/m ²)	23.6 ± 2.6	24.1 ± 2.9	0.315
Smoking history			0.542
No	96 (72.7)	25 (67.6)	
Yes	36 (27.3)	12 (32.4)	
Karnofsky performance status score	85.2 ± 4.7	86.4 ± 5.6	0.191
T stage			0.161
1	37 (28.0)	15 (40.5)	
2	95 (72.0)	22 (59.5)	
N stage			0.338
0	80 (60.6)	26 (70.3)	
1	52 (39.4)	11 (29.7)	
Clinical stage			0.296
I	33 (25.0)	13 (35.1)	
II	99 (75.0)	24 (64.9)	
Radiotherapy dose (Gy)	70.7 ± 1.9	58.6 ± 0.9	<0.001
Chemotherapy			0.296
No	33 (27.3)	13 (37.8)	
Yes	99 (72.7)	24 (62.2)	

IMRT, intensity-modulated radiotherapy; ENPG, endoscopic nasopharyngectomy; LDRT, low-dose radiotherapy; BMI, body mass index. Bold values indicate statistically significant, $P < 0.05$.

which limits its wide applications. In the present study, we reported the application of ENPG+LDRT in patients with newly diagnosed localized T1-2 NPC, and evaluated the long-term survival outcomes, QoL and late treatment-related sequelae of this regimen and assessed whether it may become an alternative regimen for conventional treatment.

Patients and Methods

Patient Population

One hundred sixty-nine newly diagnosed localized T1-2 NPC patients from June 2013 to September 2016 in the inpatient system of People's Hospital of Guangxi Zhuang Autonomous Region were recruited. All patients met the following inclusion criteria: (1) newly diagnosed early-stage (T1-2N0-1) NPC according to the 2007 NPC staging of the Union for International Cancer Control (UICC); (2) no previous treatment for NPC; (3) age ranges from 18 to 70 years old; (4) patients with Karnofsky performance status score ≥ 80 ; (5) patients voluntarily participated and signed informed consents. We exclude the following patients: (1) T2 patients with oropharynx or posterior parapharyngeal space, or patients with parapharyngeal lymph node enlargement; (2) tumor basis diameter > 1.5 cm, or occupied the entire nasopharyngeal cavity; (3) with bone, liver, lung or other distant metastasis; (4) with severe heart, liver and kidney damage and related diseases; (5) history of

another malignant tumor. Before onset of treatment, all patients received essential clinical and laboratory examinations, including magnetic resonance imaging (MRI), B ultrasound, chest X-ray, and hematologic and biochemistry profiles, and etc. The present study was approved by the ethical committee of People's Hospital of Guangxi Zhuang Autonomous Region (No: KY-SY-2013-1), and all patients provided preoperative written informed consent.

Treatment Protocols

All patients were divided into ENPG+LDRT group and IMRT group based on the treatment protocols. In the ENPG+LDRT group, the detailed procedures of ENPG were performed as previous publications described.^{10,11} Surgical instruments adopt the German KARL STORZ endoscopic system, and preoperative gross tumor volume (GTV) and high-risk clinical target volume (CTV) in radiotherapy were used to determine the tumor infiltration area and surgical margin.¹² Surgical margin was defined as the tumor invasion regions plus at least 5 mm of normal peripheral mucosa and 3 mm basal margin on the posterior bone surface and the clivus in the skull base. Intraoperative biopsies were performed at peripheral and basal incision lines to ensure safety of the surgical margins (Figure 1A-C). First, we removed the posterior part of the nasal septum and separated the mucous membrane of the posterior nasopharyngeal wall from the sphenoid bone surface to the clivus the resection of bilateral cartilaginous tube auditive. The vascular pedicle above the posterior nostril was left to repair the nasopharyngeal defect. All patients received IMRT in the radiation regimen, the target area was sketched according to the tumor image form MRI. The radiotherapy dose in the ENPG+LDRT group was 56.63 ± 13.36 Gy, and 70.69 ± 1.85 Gy in the IMRT group. Clinical stage II Patients were administrated with 3 cycles chemotherapy, including cisplatin (40 mg/m^2), carboplatin (500 mg/m^2), and flurouracil (2000 mg/m^2), with intervals of 21 days between cycles.

Operation Effectiveness Evaluations

In the ENPG+LDRT group, the success of the operation was assessed by our NPC team. Evaluation of compliance with the conditions of radical resection: (1) no residual tumor under the endoscope during the operation (Figure 1D, H); (2) pathological examination of the incisional mucosa was negative; (3) comparison of pre- and post-operative MRI changes to determine whether it matched the planned excision extension on 1 week following surgery (Figure 1 A-C, E-G).

Follow-Up

The last follow-up date was on 15 August, 2019. During post-operation follow-up, nasal endoscopy was performed every 2-3weeks to evaluate the wound reconstruction until mucosal epithelialization. Subsequent follow-up evaluations were conducted every 3-6 months. The auxiliary examinations including

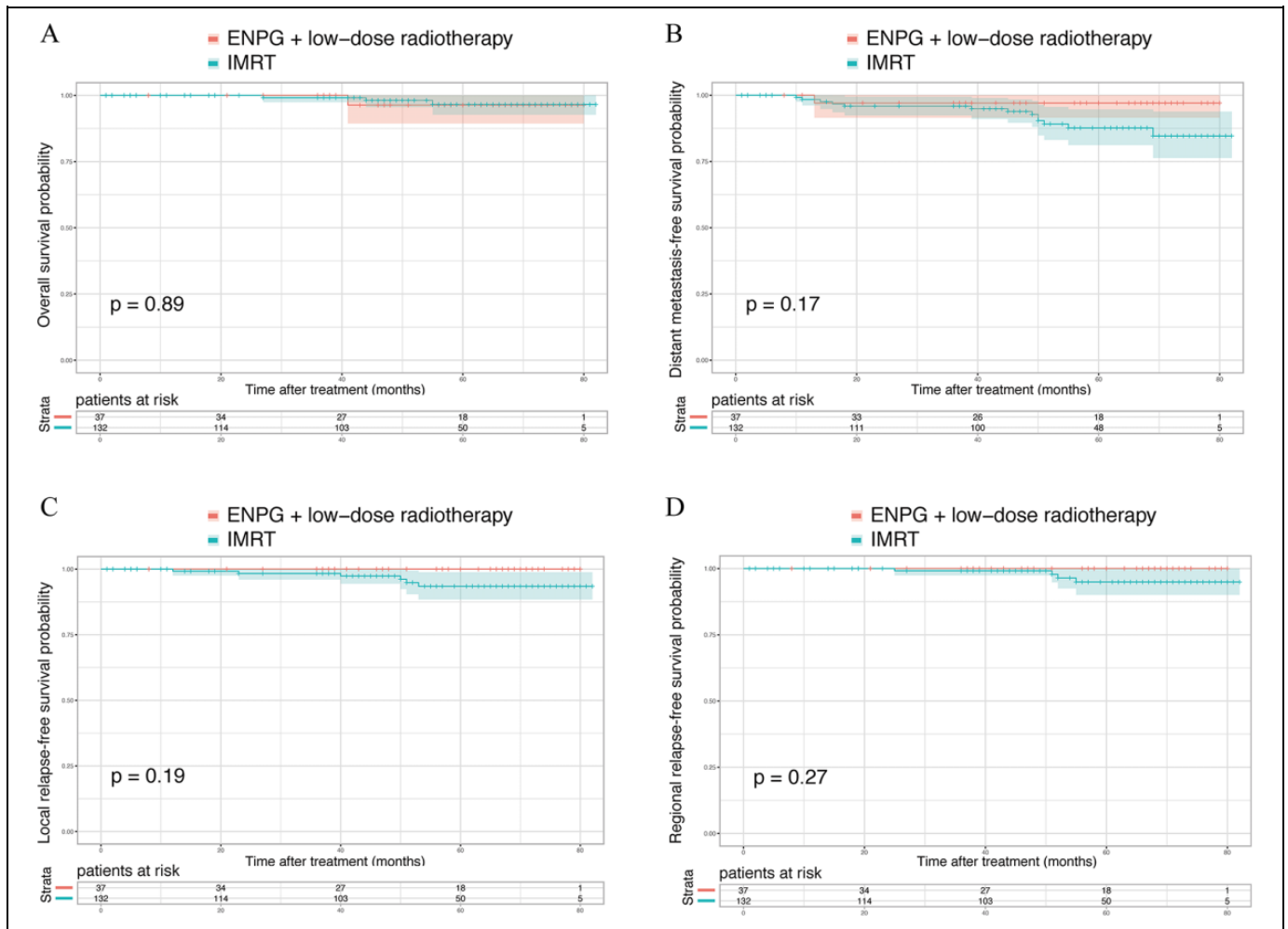


Figure 2. Kaplan–meier survival curves for NPC patients according to their therapeutic regimen. (A) Overall survival, (B) distant metastasis-free survival, (C) local relapse-free survival, and (D) regional relapse-free survival.

nasopharyngoscopy, MRI of neck, chest radiography and ultrasonography were performed at each follow-up visit.

Patients' Health-Related Quality of Life

Assistant nurses asked all follow-up cases to fill out the questionnaires, including The European Organization for Research and Treatment of Cancer Quality of Life Questionnaire Core 30, version 3.0 (EORTC QLQ-C30) and The EORTC Quality of Life Questionnaire–Head and Neck Module (EORTC QLQ-H&N35).¹³ Ten common RT-related complications were recorded simultaneously, and then the differences between the 2 groups were compared.

Statistical Analysis

Chi-square test and Mann–Whitney U test were used to analyze categorical variables and continuous variables, respectively. The survival results were calculated by the Kaplan–Meier method, and the log-rank test was performed to compare the differences. All analyses were performed by SPSS software (version 23.0). Double-tailed $P < 0.05$ was considered statistically significant.

Results

Patient Characteristics

A total of 169 newly diagnosed localized T1–2 NPC patients were recruited in the study. Among these patients, 39 patients were included in the ENPG+LDRT group and 132 patients in the IMRT group. In the ENPG+LDRT group, the average RT dose was 58.6 ± 0.9 Gy, which was significantly lower than in the IMRT group (70.7 ± 1.9 Gy, $P < 0.001$). There is no statistic difference in age, gender, BMI, smoking history, Karnofsky performance status score, T stage, N stage, clinical stage and chemotherapy between 2 groups (Table 1).

Survival Outcomes

After a median follow-up of 54 months, only 1 case in the ENPG+LDRT group died along with hepatic metastases, and no patient developed tumor recurrence. In the IMRT group 3 cases died, 13 cases developed distant metastasis, and 6 cases developed local recurrence and 4 cases regional recurrence. The 5-year overall survival (OS), distant metastasis-free

survival (DMFS), local relapse-free survival (LRFS) and regional relapse-free survival (RRFS) of patients in ENPG+LDRT group was 97.3%, 97.3%, 100% and 100%, which were not statistically different from the IMRT group, 97.7%, 90.2%, 95.5% and 97.0%, respectively (all $P > 0.05$) (Figure 2).

Life of Quality Outcomes and Late RT-Related Sequelae

All participants completed the questionnaires of EORTC QLQ-C30 and EORTC QLQ-H&N35. Patients in the ENPG+LDRT exhibited significantly better QoL outcomes than IMRT group, particularly in items of cognitive functioning (97.6 ± 2.7 vs 95.6 ± 4.2 , $P = 0.007$), social functioning (98.4 ± 4.1 vs 96.2 ± 3.0 , $P < 0.001$), Pain (12.8 ± 4.7 vs 16.2 ± 5.6 , $P = 0.001$), dyspnea (12.6 ± 5.7 vs 23.5 ± 7.3 , $P < 0.001$), swallowing (11.3 ± 6.0 vs 23.9 ± 7.9 , $P < 0.001$), social eating (12.5 ± 5.4 vs 16.7 ± 6.9 , $P < 0.001$), social contacts (5.3 ± 3.0 vs 8.4 ± 4.6 , $P < 0.001$) and dry mouth (20.1 ± 13.9 vs 31.7 ± 17.6 , $P < 0.001$) (Table 2). Compared to IMRT group, patients in the ENPG+LDRT suffered less late RT-related sequelae including hearing loss (53.8% vs 27.0%, $P = 0.005$), xerostomia (46.2% vs 24.3%, $P = 0.023$) and dysphagia (25.8% vs 8.1%, $P = 0.024$) (Table 3).

Discussion

To the best of our knowledge, the present study was the first one to evaluate the efficacy and safety of ENPG+LDRT in the treatment of localized T1-2 NPC patients compared to IMRT alone. We found similar survival outcomes, including 5-year overall survival, distant metastasis-free survival, local relapse-free survival and regional relapse-free survival, between ENPG+LDRT group and IMRT group. Moreover, ENPG+LDRT exhibited better QoL and less rate of late RT-related sequelae.

Currently, IMRT is the standard RT modality for NPC patients and it provides satisfactory disease control.¹⁴ However, it does not significantly improve the QoL of patients and continues to induce a high rate of RT-related complications after exposing to high dose of radiation.¹⁵ Therefore, more and more researchers try to explore innovative strategies to decrease the radiation dose and improve the QoL, especially in early-stage NPC patients. Miao and colleagues treated NPC patients with LDRT, and found this treatment could achieve long-term tumor control with mild late toxicities, but the rate of recurrence and metastasis was relatively high.⁵ With the development of the endoscopic technique, ENPG was widely used in the recurrent NPC patients, and it showed fewer invasions, better treatment effect and QoL than re-radiotherapy.¹⁶ In a recent study, researchers tried to utilize single ENPG to treat localized stage I NPC patients and found ENPG exhibited encouraging survival results, better QoL and less medical cost.¹⁰ However, Huang *et al* doubted the safety and feasibility of this innovative surgery for its uncertain tumor recurrence rate. In the present study, we combined ENPG and LDRT to

Table 2. Inquiry of Quality of Life Using the QLQ-C30 and QLQ-H&N35 Scales.

Observational items	IMRT (n = 132)	ENPG+LDRT (n = 37)	P value
QLQ-C30			
Global health status	91.7 ± 3.2	93.4 ± 8.5	0.062
Functional scales			
Physical functioning	96.3 ± 3.1	97.3 ± 4.2	0.112
Role functioning	96.4 ± 3.8	97.1 ± 3.5	0.316
Emotional functioning	97.9 ± 2.6	98.7 ± 2.8	0.106
Cognitive functioning	95.6 ± 4.2	97.6 ± 2.7	0.007
Social functioning	96.2 ± 3.0	98.4 ± 4.1	<0.001
Symptom scales			
Fatigue	24.3 ± 7.0	25.2 ± 3.0	0.448
Nausea/vomiting	4.2 ± 3.1	3.7 ± 3.0	0.384
Pain	16.2 ± 5.6	12.8 ± 4.7	0.001
Dyspnea	23.5 ± 7.3	12.6 ± 5.7	<0.001
Insomnia	19.6 ± 6.2	17.8 ± 4.6	0.102
Appetite loss	16.4 ± 8.6	13.7 ± 6.4	0.078
Constipation	11.0 ± 3.5	9.9 ± 4.1	0.106
Diarrhea	5.2 ± 2.5	4.5 ± 2.0	0.119
Financial difficulties	10.2 ± 3.6	9.4 ± 2.4	0.205
QLQ-H&N35 score			
Pain	10.5 ± 7.4	9.8 ± 4.7	0.586
Swallowing	23.9 ± 7.9	11.3 ± 6.0	<0.001
Senses	20.2 ± 10.7	18.9 ± 9.5	0.505
Speech	11.0 ± 4.5	9.6 ± 3.2	0.079
Social eating	16.7 ± 6.9	12.5 ± 5.4	0.001
Social contacts	8.4 ± 4.6	5.3 ± 3.0	<0.001
Sexuality	27.5 ± 11.6	25.1 ± 10.2	0.256
Teeth	11.5 ± 10.0	10.4 ± 7.8	0.537
Opening mouth	13.2 ± 10.5	10.67 ± 7.8	0.175
Dry mouth	31.7 ± 17.6	20.1 ± 13.9	<0.001
Sticky saliva	17.2 ± 10.3	15.8 ± 11.7	0.479
Coughing	22.5 ± 17.6	19.9 ± 16.3	0.421
Feeling ill	11.3 ± 8.4	9.8 ± 7.3	0.324
Pain killers	11.7 ± 7.6	9.7 ± 4.8	0.131
Nutritional supplement	20.4 ± 14.3	18.9 ± 16.2	0.585
Feeding tube	6.4 ± 3.1	5.7 ± 2.7	0.214
Weight loss	14.3 ± 7.4	12.8 ± 6.9	0.271
Weight gain	11.5 ± 5.6	10.3 ± 4.8	0.237

IMRT, intensity-modulated radiotherapy; ENPG, endoscopic nasopharyngectomy; LDRT, low-dose radiotherapy.

Bold values indicate statistically significant, $P < 0.05$.

treat the localized T1-2 NPC patients and observed that ENPG+LDRT presented with similar survival outcomes in comparison with IMRT. This suggests that ENPG+ LDRT could be technically feasible for primary localized T1-2 NPC patients.

Nowadays, effective disease control is relatively easily achieved with a variety of available treatments, NPC patients come to pursue individualize treatments to achieve the best possible results, better QoL and lower risk of late complications. Although IMRT is classic treatment for NPC patients and the survival time of patients is significantly prolonged, the late toxicity of IMRT is increasingly affecting the QoL of patients, including xerostomia, pharyngitis sicca, neck dermatitis,

Table 3. Late Treatment-Related Sequelae (n, %).

Sequelae	IMRT n = 132	ENPG+LDRT n = 37	P value
Hearing loss	71 (53.8)	10 (27.0)	0.005
Xerostomia	61 (46.2)	9 (24.3)	0.023
Neck fibrosis	26 (19.7)	6 (16.2)	0.813
Radiation encephalopathy	12 (9.1)	2 (5.4)	0.737
Cranial nerve palsy	11 (8.3)	2 (5.4)	0.736
Stomatitis	21 (15.9)	7 (18.9)	0.626
Dysphagia	34 (25.8)	3 (8.1)	0.024
Trismus	18 (13.6)	3 (8.1)	0.573
Dermatitis	31 (23.5)	12 (32.4)	0.290
Temporal bone necrosis	6 (4.5)	1 (2.7)	1.000

IMRT, intensity-modulated radiotherapy; ENPG, endoscopic nasopharyngectomy; LDRT, low-dose radiotherapy.

Bold values indicate statistically significant, $P < 0.05$.

hearing loss, radiation-induced cranial neuropathy, encephalopathy, pneumonitis and osteoradionecrosis.^{14,17} In general, severe radiotherapy toxicity is directly related to the dose and volume absorbed by the normal tissue.¹⁷ In the present study, the average radiotherapy dose was 58.6 ± 0.9 Gy, which was significantly lower than conventional RT and IMRT. Patients in the ENPG+LDRT exhibited significantly better QoL outcomes, particularly in items of cognitive functioning, social functioning, pain, dyspnea, swallowing, social eating, social contacts and dry mouth. We also found that patients in the ENPG+LDRT suffered less late RT-related sequelae including hearing loss, xerostomia and dysphagia in comparison with IMRT group. With this de-intensification technique, the treatment time was shortened and the health care resources were utilized more efficiently.

The present study has several limitations. First, this study is a retrospective analysis of collected clinical data which inevitably suffers the risk of selection bias. Second, the sample in this study was relatively small. All above problems may decrease the reliability of conclusion.

Conclusion

In primary localized T1-2 NPC, ENPG + LDRT provides survival outcome comparable to that with IMRT, and significantly improves the QoL and reduces late RT-related sequelae.

Well-designed large randomized clinical trials are needed to confirm our findings and to help formulate individualized therapies for these patients.

Author Contributions

Benjian Zhang and Yiliang Li contributed equally to this work.


Declaration of Conflicting Interests

The author(s) declared no potential conflicts of interest with respect to the research, authorship, and/or publication of this article.

Funding

The author(s) disclosed receipt of the following financial support for the research, authorship, and/or publication of this article: This work was supported by Guangxi Zhuang Autonomous Region Key Research and Development Program (No. AB19259002 and No. 14124003-3), Guangxi Zhuang Autonomous Region Health Commission Self-funded Research Project (No. Z20190741 and No. Z20190704), and a grant of Guangxi Science and Technology Base and Talent Project (Guangxi Nasopharyngeal Carcinoma Clinical Medicine Research Center).

ORCID iD

Yongfeng Si, MD  <https://orcid.org/0000-0003-4046-2480>

References

- Feng R-M, Zong YN, Cao SM, Xu RH. Current cancer situation in China: good or bad news from the 2018 Global Cancer Statistics? *Cancer Commun (Lond)*. 2019;39(1):22.
- Razak AR, Siu LL, Liu FF, Ito E, O'Sullivan B, Chan K. Nasopharyngeal carcinoma: the next challenges. *Eur J Cancer*. 2010;46(11):1967-1978.
- Si YF, Deng ZX, Weng JJ, et al. A study on the value of narrow-band imaging (NBI) for the general investigation of a high-risk population of nasopharyngeal carcinoma (NPC). *World J Surg Oncol*. 2018;16(1):126.
- Huang L, Chua MLK. Surgery as an alternative to radiotherapy in early-stage nasopharyngeal carcinoma: innovation at the expense of uncertainty. *Cancer Commun (Lond)*. 2020;40(2-3):119-121.
- Miao J, Di M, Chen B, et al. A prospective 10-year observational study of reduction of radiation therapy clinical target volume and dose in early-stage nasopharyngeal carcinoma. *Int J Radiat Oncol Biol Phys*. 2020;107(4):672-682.
- Peng G, Wang T, Yang KY, et al. A prospective, randomized study comparing outcomes and toxicities of intensity-modulated radiotherapy vs. conventional two-dimensional radiotherapy for the treatment of nasopharyngeal carcinoma. *Radiother Oncol*. 2012;104(3):286-293.
- King AD, Woo JKS, Ai QY, et al. Complementary roles of MRI and endoscopic examination in the early detection of nasopharyngeal carcinoma. *Ann Oncol*. 2019;30(6):977-982.
- Zheng XH, Wang RZ, Li XZ, et al. Detection of methylation status of Epstein-Barr virus DNA C promoter in the diagnosis of nasopharyngeal carcinoma. *Cancer Sci*. 2020;111(2):592-600.
- Yang J, Song X, Sun X, et al. Outcomes of recurrent nasopharyngeal carcinoma patients treated with endoscopic nasopharyngectomy: a meta-analysis. *Int Forum Allergy Rhinol*. 2020;10(8):1001-1011.
- Liu YP, Lv X, Zou X, et al. Minimally invasive surgery alone compared with intensity-modulated radiotherapy for primary stage I nasopharyngeal carcinoma. *Cancer Commun (Lond)*. 2019;39(1):75.
- Liu YP, Xie YL, Zou X, You R, Yang Q, Chen MY. Techniques of endoscopic nasopharyngectomy for localized stage I nasopharyngeal carcinoma. *Head Neck*. 2020;42(4):807-812.

12. Tang LQ, Chen DP, Guo L, et al. Concurrent chemoradiotherapy with nedaplatin versus cisplatin in stage II-IVB nasopharyngeal carcinoma: an open-label, non-inferiority, randomised phase 3 trial. *Lancet Oncol.* 2018;19(4):461-473.
13. Bian X, Song T, Wu S. Outcomes of xerostomia-related quality of life for nasopharyngeal carcinoma treated by IMRT: based on the EORTC QLQ-C30 and H&N35 questionnaires. *Expert Rev Anticancer Ther.* 2015;15(1):109-119.
14. Chua MLK, Wee JTS, Hui EP, Chan ATC. Nasopharyngeal carcinoma. *Lancet.* 2016;387(10022):1012-1024.
15. Stoker SD, van Diessen JNA, de Boer JP, Karakullukcu B, Leemans CR, Tan IB. Current treatment options for local residual nasopharyngeal carcinoma. *Curr Treat Options Oncol.* 2013;14(4):475-491.
16. Chen MY, Wen WP, Guo X, et al. Endoscopic nasopharyngectomy for locally recurrent nasopharyngeal carcinoma. *Laryngoscope.* 2009;119(3):516-522.
17. Chow JCH, Cheung KM, Au KH, et al. Radiation-induced hypoglossal nerve palsy after definitive radiotherapy for nasopharyngeal carcinoma: clinical predictors and dose-toxicity relationship. *Radiother Oncol.* 2019;138:93-98.