

# Pyoderma gangrenosum complicating a permanent pacemaker implantation: a case report and literature review

Pierre Frey <sup>1\*</sup>, Chrystelle Akret<sup>1</sup>, Didier Irles <sup>1</sup>, Antoine Dompnier<sup>1</sup>, and Anne-Claire Bing<sup>2</sup>

<sup>1</sup>Department of Cardiology, Centre Hospitalier Annecy Genevois, 1 Avenue de l'Hôpital, 74370 Metz-Tessy, France; and <sup>2</sup>Department of Dermatology, Centre Hospitalier Annecy Genevois, 1 Avenue de l'Hôpital, 74370 Metz-Tessy, France

Received 15 August 2019; first decision 10 October 2019; accepted 12 February 2020; online publish-ahead-of-print 12 March 2020

## Background

Pocket complications are common after cardiac implantable electronic device implantation. We report a rare case of pyoderma gangrenosum (PG) complicating a permanent pacemaker implantation, and the first literature review of 10 published cases.

## Case summary

Five days after pacemaker implantation for heart failure and 2:1 atrioventricular block, a 93-year-old man had pain in the scar and bleeding on contact. Two days later, he had fever, inflammatory syndrome, and a necrotic 7-cm wound. The pacemaker was removed and he was started on antibiotics. Due to a lack of bacterial growth in samples, PG (a rare aseptic, destructive inflammatory cutaneous condition) was suspected, and histology was compatible with this diagnosis. High-dose corticosteroids vastly improved his condition within 1 week, and after 2 months of decreasing-dose corticosteroid therapy, complete healing and normalization of the inflammatory syndrome were observed.

## Discussion

Pyoderma gangrenosum should be considered if there is aseptic skin ulceration that is not controlled by antibiotic treatment. The first-line treatment for PG is high-dose systemic corticosteroids.

## Keywords

Pyoderma gangrenosum • Pacemaker pocket infection • Older adult • Case report

## Learning points

- Pyoderma gangrenosum is a rare pacemaker pocket complication.
- Pyoderma gangrenosum should be considered if there is aseptic skin ulceration that is not controlled by antibiotic treatment.
- Prompt treatment with high-dose systemic corticosteroids is vital.
- Device extraction is not mandatory if the skin ulceration is controlled and not superinfected.

\* Corresponding author. Tel: +33 450636338, Fax: +33 450636953, Email: [pfrey@ch-annecygenevois.fr](mailto:pfrey@ch-annecygenevois.fr)

Handling Editor: Matteo Cameli

Peer-reviewers: David Niederseer and Esther Cambrono-Cortinas

Compliance Editor: Mark Philip Cassar

Supplementary Material Editor: Peregrine Green

© The Author(s) 2020. Published by Oxford University Press on behalf of the European Society of Cardiology.

This is an Open Access article distributed under the terms of the Creative Commons Attribution Non-Commercial License (<http://creativecommons.org/licenses/by-nc/4.0/>), which permits non-commercial re-use, distribution, and reproduction in any medium, provided the original work is properly cited. For commercial re-use, please contact [journals.permissions@oup.com](mailto:journals.permissions@oup.com)

## Primary specialties involved other than cardiology

- Dermatology.
- Infectious and tropical diseases.
- Haematology.

## Introduction

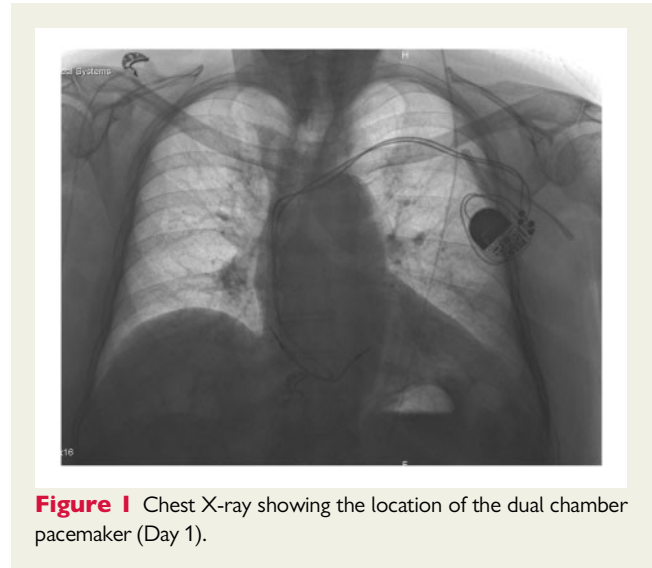
Pocket complications are common after cardiac implantable electronic device implantation, accounting for approximately one-third of complications and affecting 5% of all implantations.<sup>1</sup> We report a rare case of pyoderma gangrenosum (PG) (a rare aseptic, destructive inflammatory cutaneous condition) complicating a permanent pacemaker implantation and a literature review of all such case reported.

## Timeline

|        |  |
|--------|--|
| Day 0  | A 93-year-old man was implanted with a dual chamber pacemaker (Figure 1) for 2:1 atrioventricular block (Figures 2 and 3) and heart failure. |
| Day 2  | Patient was discharged.  |
| Day 5  | He had pain in the scar with bleeding on contact.  |
| Day 7  | He was readmitted after presenting with fever and inflammatory syndrome (Figure 4).  |
| Day 8  | The pacemaker was extracted and antibiotic therapy was started. A histological sample was taken.   |
| Day 9  | Pyoderma gangrenosum (PG) was suspected and high-dose systemic corticosteroids were started.   |
| Day 11 | Histological test results were compatible with PG (Figure 5).  |
| Day 12 | The antibiotics were stopped.  |
| Day 16 | The patient's general and cutaneous evolution were favourable (Figure 6).  |
| Day 60 | After decreasing-dose corticosteroid therapy, complete healing and normalization of the inflammatory syndrome were observed (Figure 7).      |

## Case presentation

A 93-year-old man with a history of ischaemic heart disease with preserved ejection fraction, who had undergone left anterior descending angioplasty 20 years ago, was implanted with a dual chamber pacemaker (MicroPort Group) (Figure 1) for sinus bradycardia with episodes of paroxysmal 2:1 atrioventricular block (Figures 2 and 3) and heart failure. His preoperative blood cell count showed moderate asymptomatic inflammatory syndrome with leucocytes  $10.4 \times 10^9/L$  (normal  $4.5\text{--}10.0 \times 10^9/L$ ), neutrophils  $7.3 \times 10^9/L$  (normal  $<5.9 \times 10^9/L$ ), lymphocytes  $0.79 \times 10^9/L$  (normal  $>1.07 \times 10^9/L$ ), and monocytes  $2.23 \times 10^9/L$  (normal  $<0.7 \times 10^9/L$ ). There were no immediate post-operative complications and the patient was

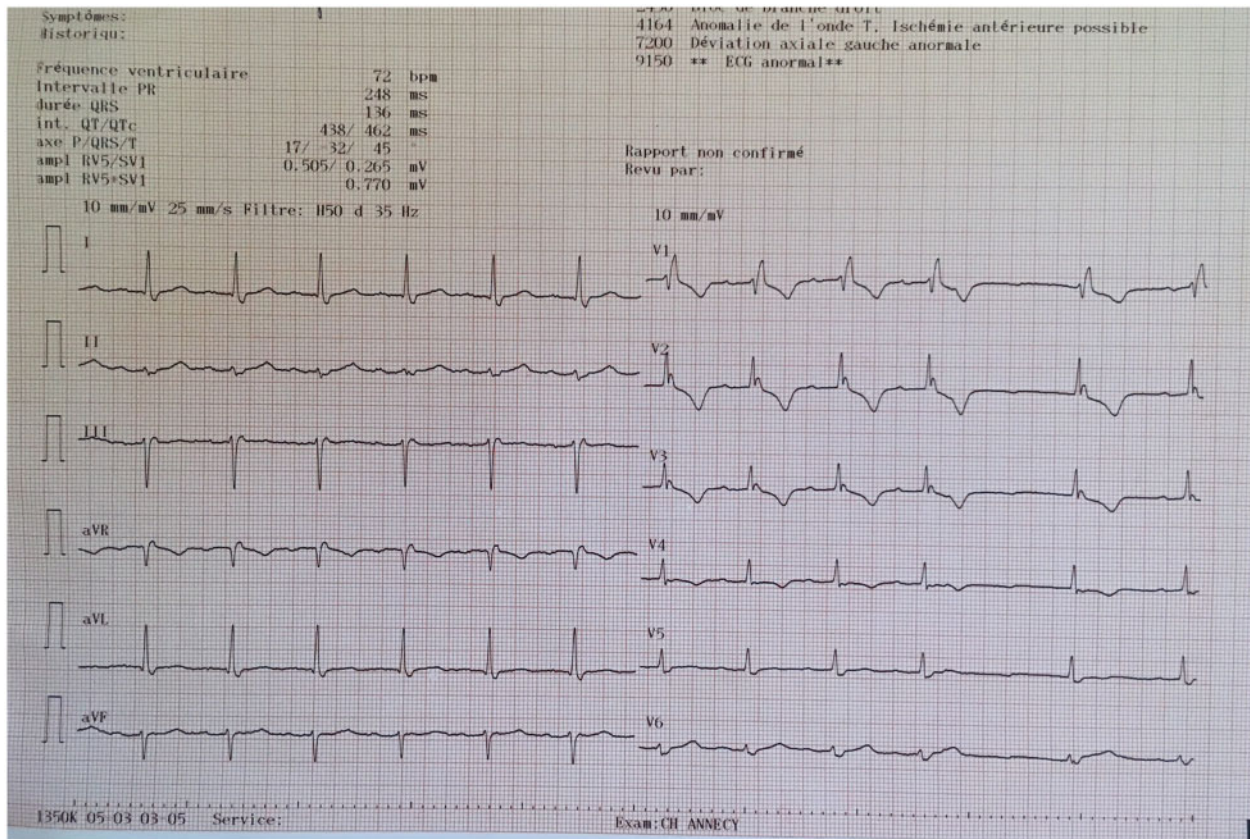


**Figure 1** Chest X-ray showing the location of the dual chamber pacemaker (Day 1).

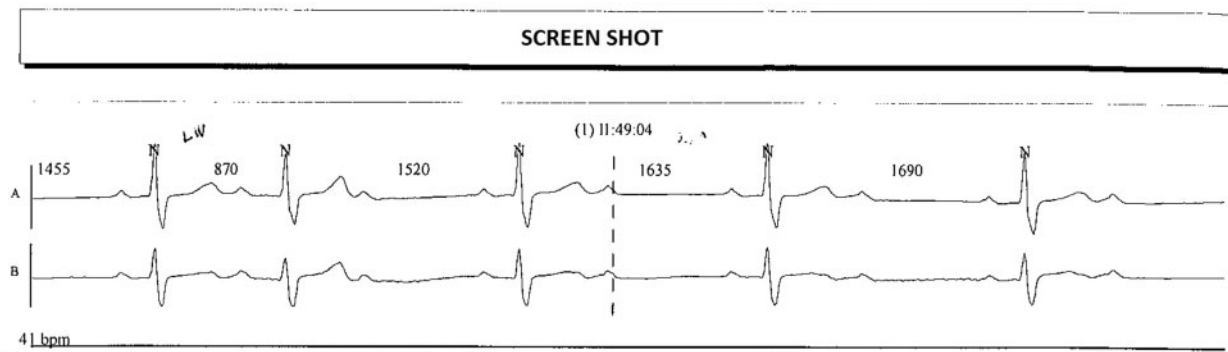
discharged home 2 days later. On the 5th post-operative day, he had pain in the scar with bleeding on contact. On the 7th day after implantation, he presented with fever ( $39^\circ\text{C}$ ) and inflammatory syndrome (leucocytes  $56 \times 10^9/L$ , neutrophils  $41 \times 10^9/L$ , monocytes  $13 \times 10^9/L$ , lymphocytes  $2.2 \times 10^9/L$ , and C-reactive protein  $247\text{ mg/L}$ ). The wound had rapidly become very inflamed, painful, oozing, and necrotic, extending to a diameter of 7 cm (Figure 4) and he was readmitted to our unit. The day after his readmission (8th day), he was taken to the operating room for device revision. After taking local samples, the pacemaker was extracted.

Transthoracic echocardiography showed left ventricular hypertrophy, left ventricular ejection fraction of 55%, no signs of endocarditis, and no pericardial effusion. The patient was then started on antibiotic therapy with amoxicillin/clavulanate and linezolid. As no growth was detected from the device, wound, or blood cultures, a clinical diagnosis of PG was suspected. Histological testing (Figure 5) showed a major inflammatory infiltrate consisting of neutrophils—sometimes altered with small foci of connective tissue necrosis—which was compatible with a diagnosis of PG. High-dose systemic corticosteroids (methylprednisolone  $1\text{ mg/kg/day}$ ) were started the day after the extraction and the antibiotics were stopped 3 days later. The patient's general and cutaneous evolution were favourable after 1 week of systemic corticosteroid treatment (Figure 6) and he did not have early recurrence of PG, including at the puncture sites of the intravenous lines. After 2 months of decreasing-dose corticosteroid therapy, complete healing and normalization of the inflammatory syndrome were observed (Figure 7).

Analysis of the patient's blood cell count was indicative of an underlying unknown haematopathy [e.g. chronic myelomonocytic leukaemia (CMML)], but the patient refused further investigations. He also refused to have a new pacemaker implanted, including a leadless pacemaker. One year after his PG diagnosis, the patient is still alive. His heart failure is controlled by medical treatment and there has been no recurrence of the skin disorder.



**Figure 2** Electrocardiogram showing Mobitz Type I atrioventricular block.



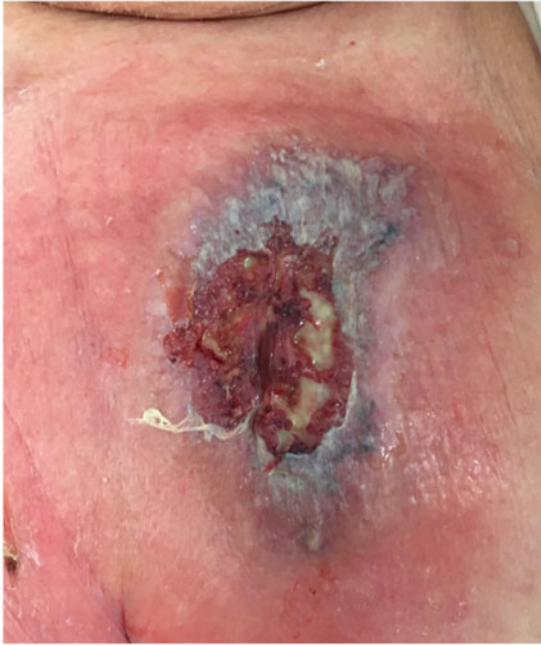
**Figure 3** Screenshot of 24 h Holter monitoring showing diurnal 2:1 atrioventricular block.

## Literature review

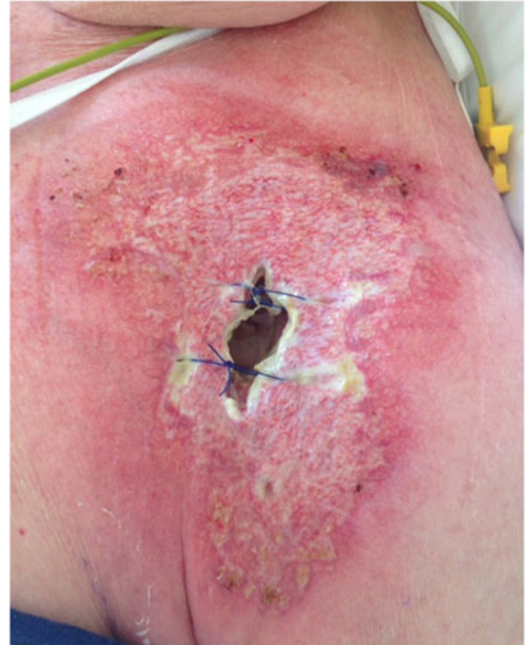
We searched the PUBMED and Cochrane database for PG and pacemaker or implantable cardiac defibrillator (ICD). To our knowledge, nine cases of PG complicating pacemaker or ICD implantation have been reported (Table 1).<sup>2-10</sup> Including our patient, there were eight pacemaker and two ICD cases, seven males and three females, and

their age varied from 51 to 93 years (median 71 years). This was a first implantation in 9/10 patients. The delay from implantation to clinical signs was known in eight patients and mainly varied from 4 to 28 days (median 14 days), although for one case, it occurred 450 days after implantation, a few days after a direct ICD trauma. The cutaneous signs of PG were present and predominant in all patients, and there was one case of ICD externalization. In 9/10 patients, the material

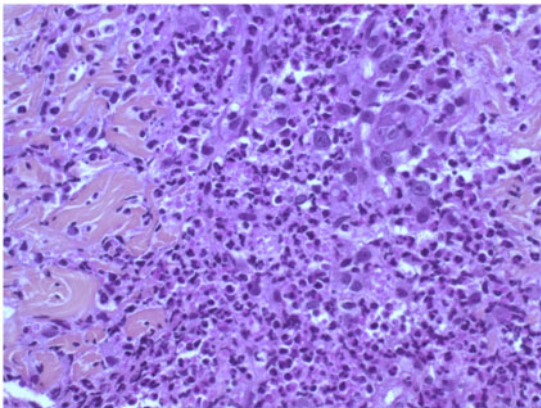




**Figure 4** Day 7 after implantation. A wide centrifugal extension necrotic ulcer, which had a well-defined limit and a purulent centre.



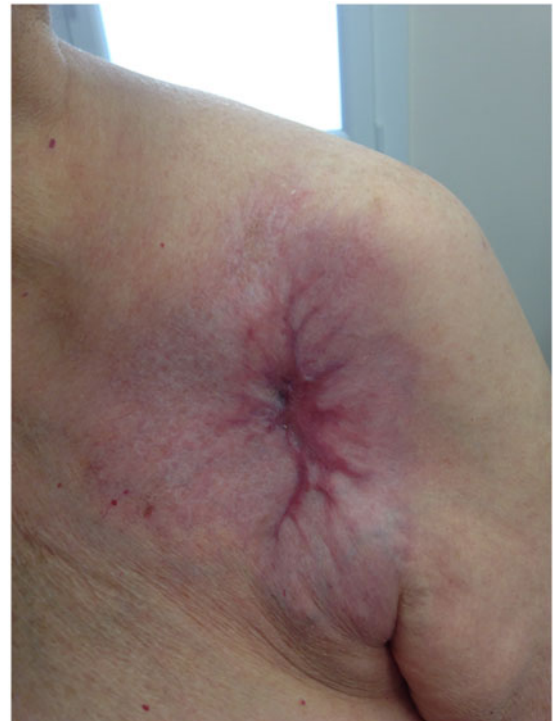**Figure 6** Day 16 (7 days after starting corticosteroid treatment). The lesion is less extensive; the inflammatory and necrotic aspects have disappeared; and there is budding of the wound that remains exudative.



**Figure 5** Day 8 operative sample. Histological examination, enlargement  $\times 400$ , haematoxylin–eosin–safron colouration. Dermal lesion by a polymorphic inflammatory infiltrate with a large predominance of neutrophils.

was explanted and was then reimplanted in 4/8 cases (two not reported). In 3/4 with contralateral reimplantation, the PG recurred on the new scar. In 7/9, bacteriological analysis was negative (one not reported), and two superficial cultures grew *Staphylococcus epidermidis*.

In all cases, a diagnosis of pocket infection was first suspected and systemic antibiotics were used as first-line treatment. The diagnosis of PG was only suspected after failure of antibiotic therapy in all



**Figure 7** Day 60 (2 months after starting corticosteroid therapy). Healed appearance with a hypertrophic centre.

**Table 1** Summary of all identified cases of PG after CIED implantation

| References                           | Sex    | Age (years) | CIED | Delay from implant to signs (days) | Underlying condition  | Bacteriology          | Histology  | Antibiotic                               | Anti-inflammatory therapy  | Complications               |
|--------------------------------------|--------|-------------|------|------------------------------------|-----------------------|-----------------------|--|--|--|-----------------------------|
| Selvapatt <i>et al.</i> <sup>2</sup> | Male   | 58          | ICD  | 28                                 | Ulcerative colitis    | Negative              | NR   | Yes (no details)                         | Topical corticosteroid   | PG recurrence               |
| Kasper <i>et al.</i> <sup>3</sup>    | Male   | 51          | ICD  | 21                                 | Arthritis             | Negative              | Necrosis and massive inflammatory purulent granulocytosis  | Meropenem, fluocloxacillin, fluconazole  | Systemic corticosteroid 250 mg/day, cyclosporine 150 mg b.i.d.   | Septic shock, PG recurrence |
| Duncan <i>et al.</i> <sup>4</sup>    | Male   | 64          | PM   | 450 (post-direct trauma)           | None                  | Negative              | Epidermis infiltrated with neutrophils, moderate inflammatory infiltrate in the dermis with palisading histiocytes and foreign-body giant cells, no evidence of vasculitis | Yes (no details)                         | Systemic corticosteroid 250 mg/day, cyclosporine 3 mg/kg/day   | No                          |
| Kaur <i>et al.</i> <sup>5</sup>      | Male   | 71          | PM   | 21                                 | None                  | Negative              | NR   | Fluoxacin, vancomycin, and ciprofloxacin | Systemic corticosteroid 20 mg/day, after failure of potent topical corticosteroid; plus cyclosporine 4 mg/kg | PG recurrence               |
| Lo <i>et al.</i> <sup>6</sup>        | Female | 85          | PM   | NR                                 | Monoclonal gammopathy | Negative              | NR   | Yes (no details)                         | Systemic corticosteroid  | No                          |
| Cosio <i>et al.</i> <sup>7</sup>     | Female | 79          | PM   | 7                                  | Monoclonal gammopathy | <i>S. epidermidis</i> | Massive neutrophilic infiltration and extensive necrosis compatible with PG  | Cloxacillin                              | Systemic corticosteroid 60 mg/day  | Death at 1 month            |
| Gebska <i>et al.</i> <sup>8</sup>    | Male   | 71          | PM   | NR                                 | NR                    | NR                    | NR   | Yes (no details)                         | Systemic corticosteroid  | No                          |
| Martel <i>et al.</i> <sup>9</sup>    | Female | 67          | PM   | 5                                  | NR                    | Negative              | NR   | Yes (no details)                         | High-dose systemic corticosteroid  | No                          |
| Marzak <i>et al.</i> <sup>10</sup>   | Male   | 72          | PM   | 4                                  | None                  | <i>S. epidermidis</i> | NR   | Amoxicillin, clavulanic acid             | Systemic corticosteroid 1 mg/kg; TNF alpha inhibitor <sup>a</sup>  | Septic shock, PG recurrence |
| Current                              | Male   | 93          | PM   | 5                                  | CMML                  | Negative              | Major inflammatory infiltrate consisting of neutrophils, sometimes altered with small foci of connective necrosis  | Amoxicillin/clavulanic acid, linezolid   | Systemic corticosteroid 1 mg/kg/day  | No                          |

CIED, cardiac implantable electronic device; CMML, chronic myelomonocytic leukaemia; ICD, implantable cardiac defibrillator; NR, not reported; PG, pyoderma gangrenosum; PM, pacemaker; TNF, tumour necrosis factor.  
<sup>a</sup>The TNF alpha inhibitor was given to limit further PG recurrence after the first PG recurrence.

previous cases, but in our case, the symptoms appeared very quickly after surgery, which made the diagnosis of infection unlikely. High-dose systemic corticosteroids were used in all but one case (one case of ineffective topical corticosteroids replaced by systemic corticosteroids and one case of effective topical steroid alone), associated with cyclosporine in 3/10 cases, and a tumour necrosis factor alpha inhibitor in 1/10 case. There was a delay in the administration of corticosteroids in all cases, often until after failure of antibiotics, and in one case, after several surgical interventions. Cutaneous histology was compatible with PG in all reported cases (five not reported). Local and general improvement was observed in 8/9 patients (one not reported) after corticosteroid therapy. One patient had worsening heart failure and nephrotic syndrome, which led to death (1 month after diagnosis of PG). In 4/8 patients (two not reported), there was a history of chronic inflammatory disease (one case of ulcerative colitis, one case of articular arthritis, two cases of monoclonal gammopathy, and, for our patient, CMML was suspected but not explored).

## Discussion

Pyoderma gangrenosum is a rare, aseptic, and destructive neutrophilic inflammatory cutaneous condition, the pathogenesis of which is complex and not completely understood. It is triggered by trauma (e.g. surgical incision) in 20% of cases.<sup>11</sup> In >50% of cases, it is associated with a systemic inflammatory or haematological disease. The prognosis of PG is poor, with up to 30% of patients dying in some cases series.<sup>11</sup> The cornerstone of treatment is topical, systemic, and targeted anti-inflammatories. High-dose systemic corticosteroids should be considered as first-line treatment, with cyclosporine and tumour necrosis factor alpha inhibitors as second- and third-line treatments, although these are not always effective.<sup>11,12</sup> Although measures directed at cleaning the ulcer and preventing bacterial overgrowth are important, more invasive surgical debridement should be avoided as it may trigger new lesions.<sup>11</sup> Conservative treatment without device extraction might be considered if feasible. Few cases of PG after implantation of a permanent pacemaker have been described in the literature<sup>2–10</sup>; in all cases, a wrong diagnosis of pocket infection was suspected, which delayed the adapted management by systemic corticosteroid therapy. In our patient, the time between implantation and first signs was very short (5 days), which alerted us to a probable skin disease. The proximity of our unit to the dermatology unit allowed us to correct the diagnosis of PG quickly, to introduce corticosteroids early (4th day after the onset of signs) and improve the prognosis of our patient.

## Differential diagnosis

From the beginning of symptoms (Day 5) until device extraction (Day 8), we sought the opinions of infectious disease colleagues, considering our initial clinical suspicion of material infection. They recommended device extraction and sample taking, washing the pocket, and intravenous antibiotic treatment targeting methicillin-sensitive staphylococcus.


In the absence of proven infection and considering the worsening condition of the post-operative wound, a dermatological opinion was sought. This immediately corrected the diagnosis (Day 9) to PG. High-dose corticosteroids were added to the antibiotic treatment, which was stopped on Day 12 in the absence of bacterial documentation. Dermatologists recommended not to revise the scar despite the initial oozing, necrotic appearance, given the risk of aggravation and evolution of PG. The wound was treated daily, by washing with water and changing the sterile dressing (Days 9–15).

We also sought the opinion of haematologists (Day 10), who strongly suspected CMML based on his preoperative blood cell count (hyperleucocytosis and hypermonocytosis). We proposed a myelogram to confirm the diagnosis, but the patient refused. Haematologists decided to monitor the patient (regular blood cell counts) without starting chemotherapy, given his age and comorbidities.

## Conclusion

Pyoderma gangrenosum is a rare pacemaker pocket complication, the main differential diagnosis of which is infection. Diagnosis of PG is often delayed, but this diagnosis must be considered if there is aseptic skin ulceration that is not controlled by antibiotic treatment. A diagnosis of PG should be considered as it may avoid unnecessary pacemaker extraction. The cornerstone of treatment is high-dose systemic corticosteroids.

## Lead author biography



Dr Pierre Frey (aged 31 years) works as cardiologist and electrophysiologist in the public hospital of Annecy (France). He has been undertaking device implantations and electrophysiology ablations for the last 3 years.

## Supplementary material

Supplementary material is available at *European Heart Journal - Case Reports* online.

## Acknowledgements

Editorial support was provided by MedLink Healthcare Communications Limited and was funded by the authors.

**Slide sets:** A fully edited slide set detailing this case and suitable for local presentation is available online as [Supplementary data](#).

**Consent:** The author/s confirm that written consent for submission and publication of this case report including image(s) and associated text has been obtained from the patient in line with COPE guidance.

**Conflict of interest:** none declared.

## References

1. Udo EO, Zuithoff NP, van Hemel NM, de Cock CC, Hendriks T, Doevendans PA, Moons K. Incidence and predictors of short- and long-term complications in pacemaker therapy: the FOLLOWPACE study. *Heart Rhythm* 2012;**9**:728–735.
2. Selvapatt N, Barry J, Roberts PR. Pyoderma gangrenosum complicating an implantable cardioverter defibrillator wound in a patient with ulcerative colitis. *Europace* 2009;**11**:1482–1482.
3. Kasper K, Manger B, Junger A, Reichert B, Sievers R, Herdtle S. [Pyoderma gangrenosum following AICD implantation: differential diagnosis to necrotizing fasciitis]. *Anaesthesist* 2012;**61**:47–51.
4. Duncan A, Bharati A, Wu J, Currie P, White SI. Pyoderma gangrenosum following pacemaker insertion. *Clin Exp Dermatol* 2009;**34**:444–445.
5. Kaur MR, Gach JE, Marshall H, Lewis HM. Recurrent postoperative pyoderma gangrenosum complicating pacemaker insertion. *J Eur Acad Dermatol Venereol* 2006;**20**:466–467.
6. Lo TS, Griffith M, Heber ME. Images in cardiology. Pyoderma gangrenosum presented as a refractory wound infection following permanent pacemaker implantation. *Heart* 2002;**87**:414–414.
7. Cosio FG, Herrada CG, Monereo A, Pastor A, Nunez A. Pyoderma gangrenosum complicating pacemaker implant. *Europace* 2006;**8**:1068–1069.
8. Gebska E, Pindycka-Piaszczyńska M, Zajecki W, Filipowska B, Sabat D, Jarzab J. [Pyoderma gangrenosum after a pacemaker implantation—case report]. *Pol Merkur Lekarski* 2005;**18**:92–95.
9. Martel J, Bourrel M, Bellemin JP, Bouchet P, Rogeaux O. Pyoderma gangrenosum after pace maker implantation [abstract FC26-9]. *J Eur Acad Dermatol Venereol* 1998;**11**:S176–S177.
10. Marzak H, Von Hunolstein JJ, Lipsker D, Chauvin M, Morel O, Jesel L. Management of a superinfected pyoderma gangrenosum after pacemaker implant. *HeartRhythm Case Rep* 2019;**5**:63–65.
11. Ruocco E, Sanguiliano S, Gravina AG, Miranda A, Nicoletti G. Pyoderma gangrenosum: an updated review. *J Eur Acad Dermatol Venereol* 2009;**23**:1008–1017.
12. Alavi A, French LE, Davis MD, Brassard A, Kirsner RS. Pyoderma gangrenosum: an update on pathophysiology, diagnosis and treatment. *Am J Clin Dermatol* 2017;**18**:355–372.