

Treatment strategies for the right heart in pulmonary hypertension

Berend E. Westerhof^{1,2*}, Nabil Saouti³, Willem J. van der Laarse⁴, Nico Westerhof¹, and Anton Vonk Noordegraaf¹

¹Department of Pulmonary Diseases, VU University Medical Center, De Boelelaan 1117, 1081 HV Amsterdam, The Netherlands; ²Department of Medical Biology, Academic Medical Center, Amsterdam, The Netherlands; ³Department of Cardio-Thoracic Surgery, St. Antonius Hospital, Nieuwegein, The Netherlands; and ⁴Department of Physiology, Institute for Cardiovascular Research, VU University Medical Center Amsterdam, Amsterdam, The Netherlands

Received 31 March 2017; revised 15 June 2017; editorial decision 14 July 2017; accepted 1 September 2017; online publish-ahead-of-print 5 September 2017

Abstract

The function of the right ventricle (RV) determines the prognosis of patients with pulmonary hypertension. While much progress has been made in the treatment of pulmonary hypertension, therapies for the RV are less well established. In this review of treatment strategies for the RV, first we focus on ways to reduce wall stress since this is the main determinant of changes to the ventricle. Secondly, we discuss treatment strategies targeting the detrimental consequences of increased RV wall stress. To reduce wall stress, afterload reduction is the essential. Additionally, preload to the ventricle can be reduced by diuretics, by atrial septostomy, and potentially by mechanical ventricular support. Secondary to ventricular wall stress, left-to-right asynchrony, altered myocardial energy metabolism, and neurohumoral activation will occur. These may be targeted by optimising RV contraction with pacing, by iron supplement, by angiogenesis and improving mitochondrial function, and by neurohumoral modulation, respectively. We conclude that several treatment strategies for the right heart are available; however, evidence is still limited and further research is needed before clinical application can be recommended.

Keywords

Diuretics • Ventricular-assist device • Cardiac resynchronisation • Mitochondrial function • Beta-blockade

This article is part of the **Spotlight Issue on Right Ventricle**.

1. Introduction

The normal pulmonary circulation represents a low-resistance, high compliance load to the right ventricle (RV) and a low pressure is sufficient to pump the blood to the lungs for oxygenation. The function of the RV is reflected in its structure, thin walled compared to the left ventricle (LV), and crescent shaped. The LV has a more circular/ellipsoidal cross-section and combined with its larger muscle mass it can build up higher pressures.

1.1 Increased ventricular wall stress

The pulmonary vascular resistance (PVR) can increase up to 500%, causing pulmonary hypertension (PH). The resulting increase in RV wall stress is a key driver of RV changes in pressure overload. Stress cannot be measured directly but can be estimated using Laplace's law, based on pressure, radius of the cavity, and wall thickness. When the progression

of the increase in pressure load is slow, the RV will adapt by increasing wall thickness^{1,2} (hypertrophy, cardiac muscle thickness) and contractility,^{3,4} to remain 'coupled' to its load, i.e. maintaining efficient transfer of energy. The RV remodels from a low-pressure to a high-pressure pump.⁵ The RV cannot hypertrophy indefinitely and when elevated pressures persist, it will dilate in an effort to maintain stroke volume by virtue of Frank&Starling law of the heart. The RV becomes uncoupled from the load making energy transfer inefficient, and ultimately RV failure develops.⁶ This process can visualised by pressure-volume loops (*Figure 1*) as proposed previously.⁶ Exercise testing may aid in distinguishing between PH patients who will progress to ventricular-vascular uncoupling.⁷

Wall stress is a major determinant of ventricular oxygen consumption.^{8,9} Increased muscle thickness increases diffusion distances and intensifies the negative effect of contraction on myocardial blood flow.¹⁰ These changes in the RV impact on oxygen delivery and consumption

* Corresponding author. Tel: +31 20 444 2196; fax: +31 20 444 4328, E-mail: b.westerhof@vumc.nl

© The Author 2017. Published on behalf of the European Society of Cardiology.

This is an Open Access article distributed under the terms of the Creative Commons Attribution Non-Commercial License (<http://creativecommons.org/licenses/by-nc/4.0/>), which permits non-commercial re-use, distribution, and reproduction in any medium, provided the original work is properly cited. For commercial re-use, please contact journals.permissions@oup.com

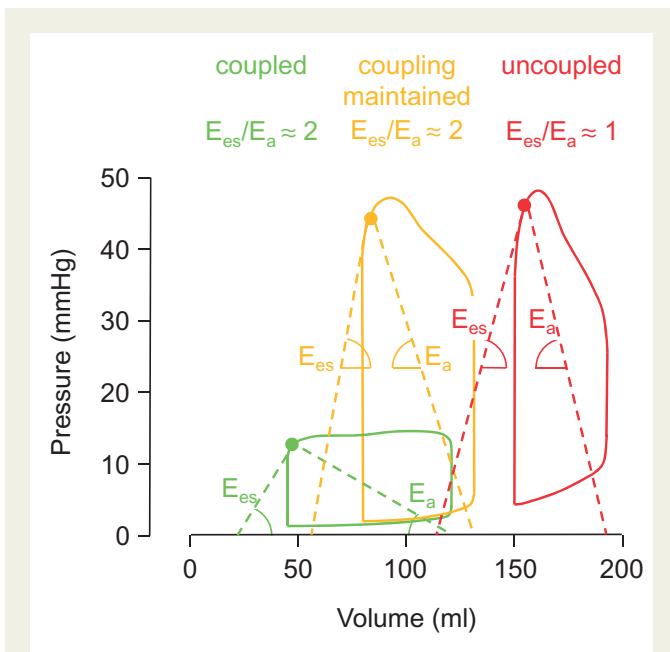


Figure 1 The right ventricle (RV) and its load in pulmonary hypertension, illustrated by pressure–volume (PV) loops. The two subsystems of the pulmonary circulation, the RV and its load, should be quantified independently of each other to describe their functioning. End systolic elastance (E_{es}) is a load-independent measure of RV contractility and arterial elastance E_a is ventricle-independent a measure of the load (not shown how E_{es} and E_a are determined). When the ratio of E_{es}/E_a is above a certain value (e.g. close to 2), efficient energy transfer is possible and the RV is “coupled” (green PV loop) to its load. When the load rises as in pulmonary hypertension (high E_a), the wall stress in the RV is increased. The RV will show an adaptive response, increasing wall thickness and contractility: E_{es} goes up. With the higher E_{es} , the ratio with E_a remains close to normal (“coupling maintained”, orange PV loop). E_{es} is increased with respect to control but still a load-independent measure, defining the adapted state of the RV. When the RV dilates, the RV may not be able to increase E_{es} further and the E_{es}/E_a is ratio drops to a lower value: the RV and vascular load become “uncoupled” (red PV loop). Since wall stress is central to these processes, treatment strategies should be aimed at lowering wall stress by reducing afterload (E_a) and RV volume (preload).

for energy metabolism, affect muscle contractility, counteract the efficient interaction between right and left ventricles, and are associated with neurohumoral activation (Figure 2).

1.2 Treatment strategies

Traditionally, therapy has been directed at lowering the load as this is the cause of RV dysfunction (Figure 2). Treatment of PH has improved substantially in recent years and we refer to recent publications and guidelines for an overview.^{11–15} However, in PH-patients with stable or even reduced afterload, RV failure may still ensue.¹⁶ Ultimately, RV function determines the prognosis of patients with pressure-overloaded hearts.^{17–20} Treatment to preserve or improve RV function itself is, therefore, required. Some treatment strategies, although previously suggested, are certainly not widespread when compared with established therapies for LV failure.²¹

In the current review, we will focus on RV function in PH (Figure 2). We will discuss potential treatment strategies for the RV, targeting wall stress itself by aiming to lower the afterload pressure (PH treatment) and ventricular volume by decreasing preload with diuretics, septostomy, and RV-assist devices. To combat the deleterious effects of RV wall stress, namely left–right asynchrony, impaired oxygen supply, and altered myocardial energy metabolism, and neurohumoral activation, we will discuss cardiac resynchronisation, ways to improve oxygen delivery and restore mitochondrial function, and possibilities for neurohumoral modulation (Figure 2).

2. Treatment strategies targeting RV wall stress

2.1 PH treatment

While not going into the details of PH treatment in this review on therapeutic strategies for the right heart, it is important to note that the first and most important mechanism to improve RV function is to normalise afterload. Afterload reduction can be attained in patients with PH by pulmonary thromboendarterectomy and balloon pulmonary angioplasty in case of chronic thromboembolic pulmonary hypertension (CTEPH), in rare cases by means of medication and ultimately by means of lung transplantation. Studies showed that with load reduction to about normal levels the RV will recover its normal shape and function within weeks.^{22,23} Although pulmonary arterial hypertension (PAH) specific medication is effective in lowering afterload, e.g. reducing PVR, the impact on the RV is minimal. One of the explanations is that this reduction in PVR is accompanied with an immediate increase of stroke volume leaving the systolic pulmonary artery pressure and thus the RV wall tension unaltered.²¹ Combination treatment might be a more effective approach in reducing PVR and thus saving the RV. In the Ambition trial, upfront combination therapy was shown to be more effective in reducing NT-proBNP than upfront monotherapy.²⁴ The most likely explanation is that combination therapy is more effective in lowering both pulmonary vascular resistance and pulmonary artery pressure than monotherapy (triple therapy).²⁵ In addition, it was recently shown that upfront combination therapy is able to reduce RV size whereas monotherapy is not.²⁶ Thus, although afterload reduction is the most effective mechanism to improve RV function, this reduction should be substantial to have an impact.

2.2 Atrial septostomy

Dr Rashkind was the first to perform atrial septostomy, saving an infant with transposition of the great arteries who became cyanotic when foramen ovale had begun to close.²⁷ Rich and Lam described the first atrial septostomy as treatment for PH patients.²⁸ Creating an opening between the right and left atrium can reduce the wall stress in the RV in PH, potentially delaying failure.²⁹ The shunting of blood to the left side and bypassing the lungs reduces oxygenation but the increase in LV preload augments cardiac output so that oxygen delivery to the tissues is not severely affected. Systemic congestion, ascites and oedema are reduced by lowering the pressure in the overloaded right atrium,³⁰ and sympathetic activation, which is increased in PH,³¹ is decreased by septostomy.³² It is unclear whether the beneficial effect of atrial septostomy is due to the reduction in sympathetic tone or due to reduction of RV preload.

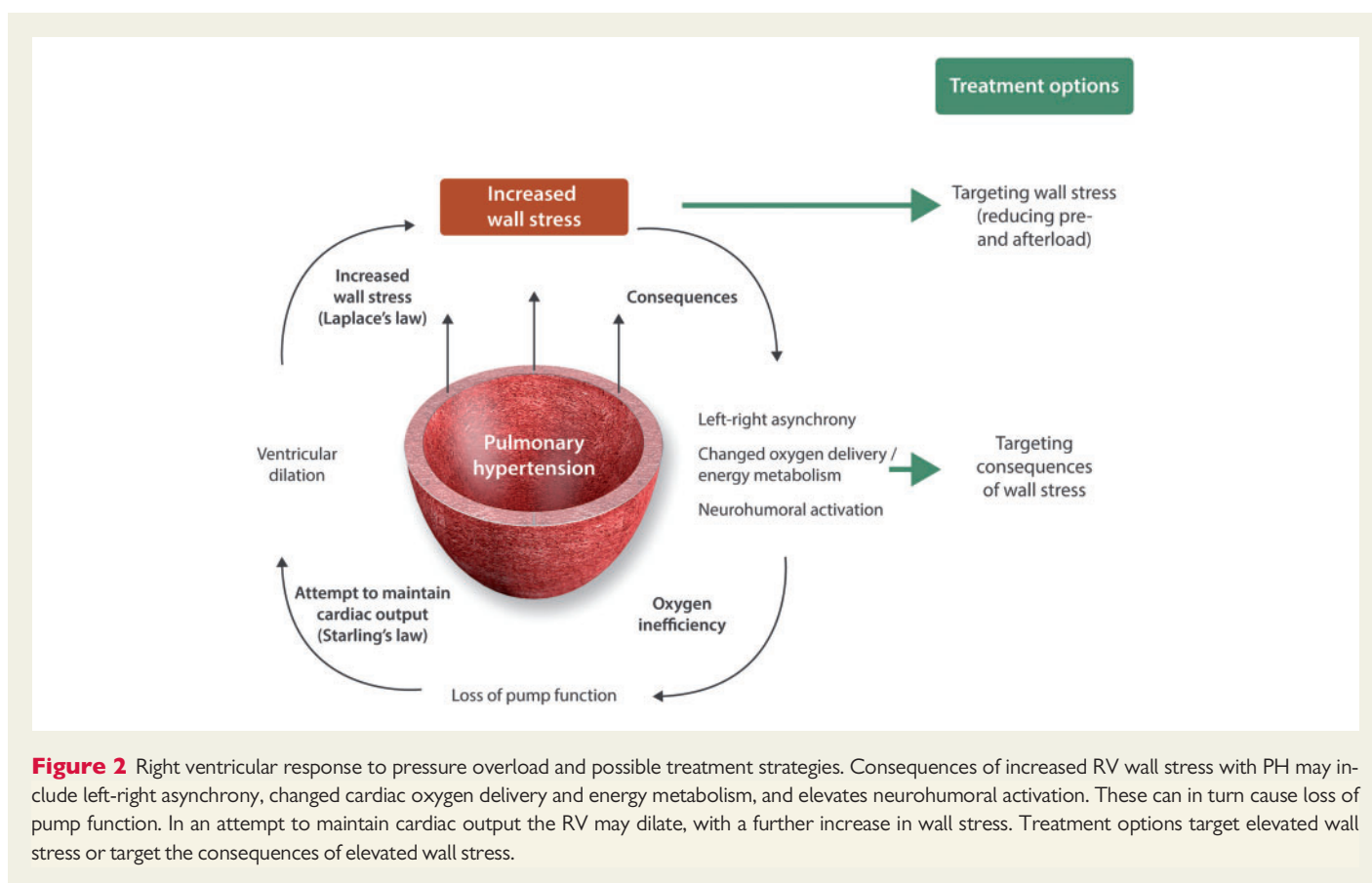


Figure 2 Right ventricular response to pressure overload and possible treatment strategies. Consequences of increased RV wall stress with PH may include left-right asynchrony, changed cardiac oxygen delivery and energy metabolism, and elevates neurohumoral activation. These can in turn cause loss of pump function. In an attempt to maintain cardiac output the RV may dilate, with a further increase in wall stress. Treatment options target elevated wall stress or target the consequences of elevated wall stress.

2.3 Diuretics

Although diuretics, including loop diuretics and aldosterone inhibitors, play a key role in the management of right heart failure as acknowledged in the current guidelines,¹⁴ the impact of diuretics on preservation of RV function and reduction on wall stress is not well studied. In addition, how to optimise diuretic therapy in the individual PAH patient is still unknown. Although prescription of diuretics in PH patients with overt symptoms of RV failure is common, the role of diuretics in patients without oedema or ascites in a good functional state is unknown. In LV failure, it has been shown that a rigorous diuretic management guided by NT-pro BNP leads to improvement of the functional state of the patient and reduced hospital admissions.³³ However, such studies are missing in the field of PH. Thus, although on conceptual and clinical grounds giving diuretics is the current best treatment for RV failure, the supporting evidence is limited. The impact of tolvaptan, an oral, non-peptide, selective vasopressin V2-receptor antagonist, has been investigated in a small prospective study showing beneficial impact on BNP levels and diuretic use, but a randomized controlled trial is currently lacking.³⁴ Further studies are required to assess the optimal diuretic regime to optimise RV function in individual patients.

2.4 RV-assist devices

Mechanical ventricular-assist devices (VADs) have progressed from bulky (pneumatic) paracorporeal apparatuses to implantable units presently even fitting in the pericardium.³⁵ Axial designs (HeartMate II, Thoratec) are being replaced by centrifugal pumps (Thoratec HeartMate III, HeartWare/Medtronic HVAD and MVAD). Small pumps built into a catheter, usually with an impeller to generate flow (Abiomed Impella),

can be inserted percutaneously. Recently, such a device (Abiomed Impella RP) was used for RV assist after a Humanitarian Device Exemption was provided [<http://www.accessdata.fda.gov/scripts/cdrh/cfdocs/cfhde/hde.cfm?id=H140001> (11 August 2017)]. Percutaneous devices and extracorporeal membrane oxygenation (ECMO) in the context of PH³⁶ are not suitable for long-term use. For potential long-term treatment strategies, implantable devices could show promise.

LV-assist devices have been quite successful in recent years as bridge to transplant or even as destination therapy for LV failure.³⁷ RV-assist devices are sometimes required after RV failure secondary to implanting LV-assist device.³⁸ After longer term LVAD support, RV afterload and RV adaptation improve and become stable.³⁹ As recently reviewed,⁴⁰ an LVAD allows the LV to remodel due to the mechanical unloading,⁴¹ rather than the normalisation of neurohormonal activation,⁴² since no changes were found in the RV after implantation.⁴³

Thus far, RV-assist devices have been used as bridge to heart transplantation for combined LV and RV failure. Experience with isolated and permanent RVAD implantation (HeartWare HVAD) devices was recently summarized by Bernhardt et al.⁴⁴ The first HVAD implanted for permanent isolated RV support was described in 2013.⁴⁵ At that time, the outflow graft of the device was adapted to increase the resistance so that the pump would experience a more systemic-like afterload.³⁸ Later it was found that HVAD device can be used to support the RV without modification because of its pre- and afterload sensitivity.⁴⁵

Relevant studies by Verbelen et al. in sheep comprised pulmonary artery banding and implantation of a small assist device (Synergy Pocket Micro-Pump, HeartWare, Framingham, MA) between right atrium and pulmonary artery (proximal of the banding). In a first study, RVAD implantation with a low-flow and high-flow operation unloaded the RV in

diastole and increased cardiac output (heart plus pump), while contractility was not changed.⁴⁶ In a second study, the effects of RVAD immediately after banding were compared with the effects 8 weeks after banding, which is more representative of the condition of patients with PH.⁴⁷ Interestingly, cardiac output was increased only in the acute group, and again contractility was not changed. The pressure–volume area was significantly reduced in the chronic group, suggesting a lower oxygen requirement.⁴⁸ Mathematical modelling studies can also be helpful in gaining understanding of the effects of cardiac support.⁴⁹ Although RV-assist devices do have potential benefits in terms of diastolic RV unloading and assisting systolic function, concerns on safety issues currently limit the use of these devices to bridge-to-transplant in end-stage disease.

3. Treatment strategies targeting the consequences of RV wall stress

3.1 Cardiac resynchronisation therapy

In advanced stages of PAH, left-to-right asynchrony can occur as readily seen from leftward ventricular septal bowing in early LV diastole.⁵⁰ The RV post-systolic isovolumic time as determined with echocardiography is prolonged.⁵¹ With cardiac MRI it was established that the main cause of leftward septal bowing is not a late start but a prolonged contraction duration of the RV in relation to LV contraction.⁵² This suggests that not an electrical conduction delay is the cause of interventricular mechanical asynchrony but increased wall tension and is, therefore, highly afterload dependent.⁵³ The increase in the post-systolic isovolumic period is not related to diastolic dysfunction as previously thought.⁵⁴ The RV volume being displaced into the relaxed LV by the septal bowing allows the pulmonary valve to close while the RV is still contracting and consuming oxygen. This part of the contraction is inefficient since it does not contribute to forward flow and hampers early diastolic LV filling.⁵⁵

Support for cardiac right–left resynchronisation therapy in PH is found in animal experiments, patient studies, and mathematical modelling. In an experimental animal model with chronic PH and RV failure, PH-related ventricular asynchrony was confirmed by cardiac MRI.⁵³ Leftward septal bowing was observed as in clinical PH. In the isolated hearts, RV and LV peak pressures were synchronised by pre-excitation of the RV free wall, improving RV systolic function.⁵³ At the same time, the negative effect of the prolonged contraction of the RV on diastolic LV function was reduced as demonstrated by decreased leftward septal bowing.⁵³ Mathematical modelling by Lumens et al. also provides support for right–left synchronization. Pump function improved wall strain, reduced muscle work, and made workload distribution more homogeneous.⁵⁶ In a later study, these authors combined animal experimental, clinical, and computational data to determine the hemodynamic and electromechanical effects of left ventricular and biventricular pacing. Interestingly, the results suggested that resynchronization therapy could also improve LV systolic function by mechanical recruitment of the RV myocardium.⁵⁷

Hardziyenka studied patients with RV failure and ventricular asynchrony due to CTEPH.⁵⁸ Based on ventricular asynchrony (called diastolic interventricular delay) as determined with Doppler echocardiography, seven patients were selected for a temporary pacing protocol. These patients were in the highest tertile of diastolic interventricular delay values in the CTEPH population of their institution. RV pacing indeed reduced asynchrony, increased RV contractility, optimised LV diastolic filling and increased LV stroke volume.⁵⁸

As a cautionary remark we stress that, as opposed to LV failure,^{59–61} the supporting evidence for pacing in RV failure is still limited. Stress in the ventricular wall is a complex interplay of afterload, the moment in time of maximal load, ventricular volume, and muscle shortening.⁶² It is difficult to foresee if the improvement of RV function in terms of output may not come at the cost of increased wall stress and oxygen demand or extreme load in a phase of the contraction where the RV is more vulnerable to stress. The earlier start of contraction by RV pacing may require more oxygen: since the RV is largest and wall thickness is lowest, wall tension highest, and cardiac oxygen demand is at its peak. In the un-paced heart, the LV would support the RV through this first phase.

3.2 Supporting myocardial oxygen delivery for energy metabolism

In the pressure-overloaded RV, oxygen supply is reduced whereas oxygen demand is increased, limiting the amount of oxygen available for contractile function and bringing the RV in danger of hypoxia.⁶³ Several studies have shown that hypoxia inducible transcription factor HIF1a is upregulated in experimental PH.^{64–67} Before discussing treatment options, first we briefly review the pathophysiology of myocardial oxygen demand, supply, efficiency, and mitochondrial adaptations.

Oxygen demand is proportional to muscle mass, and related to ventricular wall stress and thus pressure.^{8,9} Consequently, in PH, when the RV dilates and pressure is elevated, both augmenting wall stress, oxygen demand will increase. Similar to the LV, also in the RV O₂ demand is determined by heart rate (HR) as well, confirming that general physiologic concepts hold in PH.⁶⁸

Decreased oxygen delivery to the myocytes can be caused by insufficient coronary flow, capillary perfusion or O₂ extraction, or by increased diffusion distance and reduced intracellular facilitated diffusion. In normal physiology, right coronary artery flow is similar in systole and diastole; however, in PH, flow becomes biphasic with reduced systolic flow, comparable with what is normal in the LV.¹⁰ This is caused by ventricular compression of the transmural arteries and has been suggested to depend on the layer with subendocardial layers most affected.⁶⁹ Stiffening of the diastolic RV may reduce oxygen supply in diastole.^{10,70–73}

The myocytes in the pressure-overloaded RV are hypertrophied whereas the number of capillaries per muscle cell is not increased. Thus, the capillary density with respect to muscle mass of the RV is reduced in PH and consequently, diffusion distance is increased.⁷⁴ Capillary rarefaction in the RV of patients with PAH has also been observed, mainly in scleroderma-associated PAH.⁷⁵ The combination of these conditions limits the oxygen supply at the myocyte level.

In NYHA 3 PAH patients, oxygen consumption was increased in comparison with NYHA 2 patients although power output and pressures were the same in both patient groups.⁹ In isolated papillary muscles of hypertrophied RVs of a PH rat model, also a reduced RV mechanical efficiency was seen. Mechanical efficiency was inversely related to RV wall thickness and RV cardiomyocyte cross-sectional area. Therefore, intracellular changes during the hypertrophy process may lead to inefficient O₂ usage in relation to cardiomyocyte work, which was confirmed in humans.⁷⁶

Recently, radical scavengers were shown to be effective as the treatment in rats with experimental RV failure.^{77–81} This suggests that the increased mitochondrial reactive oxygen species (ROS) production in hypertrophied cardiomyocytes causes myocardial injury. Furthermore, oxygen not used for ATP resynthesis or ROS production by the electron transport chain may be used to release energy for futile H⁺ or Ca⁺⁺

cycling across the mitochondrial inner membrane or by oxidases other than cytochrome c oxidase or by nitric oxide synthase.

Based on these concepts, improving oxygen supply for ATP resynthesis potentially can be accomplished by enhancing intracellular facilitated diffusion by myoglobin, by increasing capillary density, or by targeting mitochondrial function. Treatment is increasingly directed to the mitochondria owing to their role in regulation metabolism and apoptosis.^{82–84}

3.2.1 Restoring myoglobin content

With the reduced capillary density in PH and increased diffusion distance,⁷⁴ intracellular facilitated diffusion by myoglobin becomes more relevant. However, the myoglobin concentration in RV tissue of PH patients was found to be significantly reduced compared to controls. In a PH rat model, a similar lower myoglobin content was demonstrated, with changes already beginning in stable disease.⁷⁴

In PH patients, a lower iron concentration was found and as iron is part of the haem molecule, an effective treatment strategy may be to upregulate myoglobin concentration by iron supplementation, and restoring intracellular O₂ facilitated diffusion.⁸⁵ Indeed, intravenous iron therapy increased exercise endurance capacity of idiopathic PAH patients, although a 6-min walking distance was unaltered. RV function at rest was not improved; however, skeletal muscle biopsies indicated increased myoglobin concentration after iron treatment.⁸⁶ In the rat PH model, the increased amount of myoglobin per RV myocyte is due to increased translation rather than transcription of the myoglobin gene, which did not change during hypertrophy.⁸⁷

3.2.2 Increasing capillary density

The transition from a compensated to a decompensated hypertrophied RV was shown to be associated with decreased RV angiogenesis in experimental animals⁶⁷ and downregulation of microRNA-126 could be involved. Patients with decompensated RV failure indeed had decreased MicroRNA-126 expression as compared with RV tissues from patients with compensated RV hypertrophy.⁸⁸ MicroRNA-126 upregulation increased angiogenesis of primary cultured endothelial cells from patients with decompensated RV failure *in vitro*. *In vivo* MicroRNA-126 upregulation improved RV microvascular density and RV function, and reduced fibrosis of monocrotaline-induced PAH animals. MicroRNA-126 downregulation exacerbated RV failure, suggesting a new treatment strategy for RV failure PH.⁸⁸

3.2.3 Targeting the mitochondria

Processes in the mitochondria are highly adaptive to their environment and recently these adaptations have become targets for treatment in a number of diseases, including RV failure.⁸⁹ Here we briefly consider fission/fusion and metabolic remodelling.

Mitochondria are very dynamic and fission and fusion are continuously ongoing. Fission is the process that creates new mitochondria, but also can remove damaged mitochondria and plays a role in apoptosis under environmental stress. Fusion is the process of combining (partially damaged) mitochondria to form new functional mitochondria,⁹⁰ and creating a more interconnected mitochondrial network. Changes in fission/fusion activity are mainly triggered by mediators in the cellular milieu.⁹¹ Disturbed mitochondrial dynamics are increasingly recognised as part of the pathogenesis of complex diseases in which mitochondria may not be immediately implicated.⁹¹ Several molecular mediators of mitochondrial dynamics have been identified and are currently being investigated. For instance, in a recent study, mitochondrial fission induced by RV ischemia/

reperfusion caused RV diastolic dysfunction in PAH rats. Dynamin-related protein 1 (Drp1)-mediated mitochondrial fission and Drp1 inhibitors (Mdivi-1 and P110) preserved RV diastolic function post-ischemia/reperfusion.⁹²

Changes in metabolism as seen in the vascular remodelling of the pulmonary arteries in PAH are probably a manifestation of a syndrome involving other organs as well, with mitochondrial abnormalities as underlying cause.⁹³ This complicates the identification of therapeutic targets, however, also opens up possibilities for new treatment strategies for the RV.⁹⁴

Mitochondrial metabolism includes oxidation of fatty acids and of glucose. In the healthy human (adult) heart, fatty acid oxidation is the predominant source of energy. RV cardiomyocytes in PAH shift from glucose oxidation towards aerobic glycolysis.⁹⁵ The relative contributions of the different energy sources can be modified by external stimuli such as hypoxia, pressure overload and hypertrophy.⁹⁵

As a recent example, in rats with PH by banding of the pulmonary artery, fatty acid oxidation in the RV was increased, while glucose oxidation was decreased. When fatty acid oxidation was reduced by partial inhibition with rimetazidine or ranolazine, glucose oxidation was restored, and cardiac output and exercise capacity were increased.⁹⁶

Earlier, it was shown that the glycolytic shift in the myocyte was caused by activation of pyruvate dehydrogenase kinase (PDK),⁹⁷ probably induced by hypoxia.⁹⁸ This has been studied in two rat models of RV hypertrophy, one induced by monocrotaline and another induced by pulmonary artery banding. Inhibition of PDK with chronic dichloroacetate improved RV function; larger effects were seen in the monocrotaline model suggesting that regression of vascular disease may have occurred. Additionally, RV hypertrophy regressed by enhancing glucose oxidation.

Hypoxia and PDK inhibition may increase mitochondrial ROS production.⁹⁸ Therefore, protecting mitochondria by the use of specific radical scavengers like SS31 may be an additional or alternative treatment.⁹⁹

3.3 Neurohumoral modulation

In patients with PH, the sympathetic nervous system is overactive.³¹ Sympathetic activation may be needed as first response to keep the RV coupled to the increased load. However, in the long run it is unfavourable.¹⁰⁰ With sympathetic overload the beta-adrenergic receptor density and activation will become reduced.^{101,102} The beta-adrenergic receptor is important for the response to inotropes and regulation of the contractile apparatus of the cardiomyocytes.¹⁰³ Therefore, the impaired contractile performance of the RV may be a consequence of chronic increased neurohormonal activation and reduced receptor density.¹⁰⁴ This is supported by the finding that, in patients with PH, the RV is unable to increase contractility during exercise,¹⁰⁵ most likely since the beta-adrenergic receptor density is reduced, and catecholamine-induced activation of the contractile elements is prevented.^{101,102,106}

3.3.1 Beta-adrenergic blockade

Currently, the use of beta-blockers is contraindicated for clinical use, often with reference to the study of Provencher et al.,¹⁰⁷ who showed functional improvement after withdrawal of beta-blockers in a small series of patients with porto-pulmonary hypertension. Additionally, acute administration of beta-blockers can lead to ventriculo-arterial uncoupling, probably due to its negative inotropic influence.¹⁰⁸ Selective beta-blockers and slow up-titration could help in avoiding this temporary effect.²¹

In contrast, beta-blockers reduce the heart rate and with it, myocardial O₂ demand. Moreover, the effect of the adrenergic receptor blocker carvedilol on the pulmonary circulation and RV was assessed in experimental PH in rats demonstrating improved survival. Treatment resulted in an increased cardiac output and improved exercise endurance and RV function compared with control animals. RV afterload was not affected by carvedilol; capillary rarefaction and fibrosis in the RV were reduced. Thus, blockade of adrenergic receptor improved RV function and indeed reversed RV remodelling while experimental PH persisted.¹⁰⁹

Bisoprolol treatment in a rat model of PH improved intrinsic properties of RV cardiomyocytes as determined by increased RV contractility (normalized for hypertrophy) and filling, while partially restoring cardiac output and ventriculo-arterial coupling. It also delayed the progression toward RV failure.¹¹⁰

After the promising effects of bisoprolol in rats, this beta-blocker was also investigated in patients with optimally treated, stable idiopathic PAH (NYHA 2/3) in a crossover design.¹¹¹ A limited number of patients was included; heart rate was lowered but RV ejection fraction remained unchanged. Cardiac output was slightly reduced and 6-min walking distance tended to decrease. Therefore, in this group of idiopathic PAH patients, no benefit of treatment with bisoprolol in iPAH could be demonstrated.¹¹¹

3.3.2 Renin–angiotensin–aldosterone system

Next to increased sympathetic nervous system activation the renin–angiotensin–aldosterone system is implicated in the progression of PH.^{104,112,113} In a recent proof-of-concept study, the effects of renal denervation were investigated in two well-established experimental models of PH.¹¹⁴ Denervation delayed disease progression; pulmonary vascular remodelling and RV afterload were reduced, as was RV diastolic stiffness. It appears that renal denervation may have caused these effects by suppressing the activation of the renin–angiotensin–aldosterone system.¹¹⁴

3.3.3 Parasympathetic activation

As opposed to reducing sympathetic activation, parasympathetic activation could be stimulated. Recently, chronic treatment of PAH rats with pyridostigmine, which stimulates parasympathetic activity through acetylcholinesterase inhibition, was shown to increase RV contractility, reduce RV stiffness, RV hypertrophy, fibrosis and inflammation.¹¹⁵ Also, pulmonary vascular resistance and pulmonary vascular remodelling were reduced. Spectral analysis (of pulse interval and systolic arterial pressure variations) in a subgroup indicated increased parasympathetic activity and baroreflex sensitivity. Most importantly, survival was improved in the treated rats.¹¹⁵

4. Summary

We reviewed treatment strategies for the RV in PH. RV wall stress plays a central role in the progression of the RV towards failure. Therefore, first we focussed on treatment strategies aimed at lowering wall stress; some of those well-accepted, while others are not. Second, we reviewed potential strategies to reverse or least halt the detrimental effects of high RV wall stress. In Table 1, the discussed treatment strategies are listed with the references to the supporting studies.

First and foremost, lowering the afterload is crucial in decreasing wall stress. Additionally, volume overload should be reduced by diuretics, or by perhaps by septostomy or with a mechanical-assist device. Although

Table 1 Treatment strategies for the right heart in pulmonary hypertension

	Theoretical/ mathematical modelling	Animal studies	Clinical studies
2. Targeting RV wall stress			
2.1. PH treatment			11–15
2.2. Atrial septostomy			28–30
2.3. Diuretics	14		34
2.4. RV-assist devices	49	46,47	44,45
3. Targeting the consequences of RV wall stress			
3.1. Cardiac resynchronisation therapy	56,57	53	57,58
3.2. Supporting myocardial oxygen delivery			
3.2.1. Restoring myoglobin content		74,87	85,86
3.2.2. Increasing capillary density		88	
3.2.3. Targeting the mitochondria		96–99	
3.3. Neurohumoral modulation			
3.3.1. Beta-adrenergic blockade		109,110	107,111
3.3.2. Renin angiotensin-aldosterone system		114	
3.3.3. Parasympathetic activation		115	

targeting the detrimental effects of abnormal increased wall stress holds promise, robust data are currently lacking.

In conclusion, many treatment strategies for the right heart are available but need to be further investigated and advanced towards clinical application. Successful treatment of the RV failure would have a positive impact on the lives of patients suffering from PH.

Conflict of interest: none declared.

Funding

Dr A. Vonk Noordegraaf was supported by the Netherlands CardioVascular Research Initiative: the Dutch Heart Foundation, Dutch Federation of University Medical Centers, the Netherlands Organization for Health Research and Development, the Royal Netherlands Academy of Sciences and NWO-VICI (2002406). Dr B.E. Westerhof was supported by NWO-VICI (2002406).

References

- Dias CA, Assad RS, Caneo LF, Abduch MC, Aiello VD, Dias AR, Marcial MB, Oliveira SA. Reversible pulmonary trunk banding. II. An experimental model for rapid pulmonary ventricular hypertrophy. *J Thorac Cardiovasc Surg* 2002;**124**: 999–1006.
- Segers P, Stergiopulos N, Schreuder JJ, Westerhof BE, Westerhof N. Left ventricular wall stress normalization in chronic pressure-overloaded heart: a mathematical model study. *Am J Physiol Heart Circ Physiol* 2000;**279**:H1120–H1127.
- Vonk-Noordegraaf A, Haddad F, Chin KM, Forfia PR, Kawut SM, Lumens J, Naeije R, Newman J, Oudiz RJ, Provencher S, Torbicki A, Voelkel NF, Hassoun PM. Right heart adaptation to pulmonary arterial hypertension: physiology and pathobiology. *J Am Coll Cardiol* 2013;**62**:D22–D33.
- Trip P, Rain S, Handoko ML, van der Bruggen C, Bogaard HJ, Marcus JT, Boonstra A, Westerhof N, Vonk-Noordegraaf A, de Man FS. Clinical relevance of right ventricular diastolic stiffness in pulmonary hypertension. *Eur Respir J* 2015;**45**: 1603–1612.

5. Rain S, Handoko ML, Vonk Noordegraaf A, Bogaard HJ, van der Velden J, de Man FS. Pressure-overload-induced right heart failure. *Pflugers Arch* 2014;**466**:1055–1063.
6. Vonk Noordegraaf A, Westerhof BE, Westerhof N. The relationship between the right ventricle and its load in pulmonary hypertension. *J Am Coll Cardiol* 2017;**69**:236–243.
7. Hsu S, Houston BA, Tampakakis E, Bacher AC, Rhodes PS, Mathai SC, Damico RL, Kolb TM, Hummers LK, Shah AA, McMahan Z, Corona-Villalobos CP, Zimmerman SL, Wigley FM, Hassoun PM, Kass DA, Tedford RJ. Right ventricular functional reserve in pulmonary arterial hypertension. *Circulation* 2016;**133**:2413–2422.
8. Sarnoff SJ, Braunwald E, Welch GH Jr, Case RB, Stainsby WN, Macruz R. Hemodynamic determinants of oxygen consumption of the heart with special reference to the tension-time index. *Am J Physiol* 1958;**192**:148–156.
9. Wong YY, Ruiters G, Lubberink M, Rajmakers PG, Knaapen P, Marcus JT, Boonstra A, Lammertsma AA, Westerhof N, van der Laarse WJ, Vonk-Noordegraaf A. Right ventricular failure in idiopathic pulmonary arterial hypertension is associated with inefficient myocardial oxygen utilization. *Circ Heart Fail* 2011;**4**:700–706.
10. van Wolferen SA, Marcus JT, Westerhof N, Spreeuwenberg MD, Marques KM, Bronzwaer JG, Henkens IR, Gan CT, Boonstra A, Postmus PE, Vonk-Noordegraaf A. Right coronary artery flow impairment in patients with pulmonary hypertension. *Eur Heart J* 2007;**29**:120–127.
11. Kiely DG, Elliot CA, Sabroe I, Condliffe R. Pulmonary hypertension: diagnosis and management. *BMJ* 2013;**346**:f2028.
12. Hoepfer MM, Lam CS, Vachiery JL, Bauersachs J, Gerges C, Lang IM, Bonderman D, Olsson KM, Gibbs JS, Dorfmueller P, Guazzi M, Galie N, Manes A, Handoko ML, Vonk-Noordegraaf A, Lankeit M, Konstantinides S, Wachter R, Opitz C, Rosenkranz S. Pulmonary hypertension in heart failure with preserved ejection fraction: a plea for proper phenotyping and further research. *Eur Heart J* 2016; doi: 10.1093/eurheartj/ehw597.
13. Vonk Noordegraaf A, Groeneveldt JA, Bogaard HJ. Pulmonary hypertension. *Eur Respir Rev* 2016;**25**:4–11.
14. Galie N, Humbert M, Vachiery JL, Gibbs S, Lang I, Torbicki A, Simonneau G, Peacock A, Vonk Noordegraaf A, Beghetti M, Ghofrani A, Gomez Sanchez MA, Hansmann G, Klepetko W, Lancellotti P, Matucci M, McDonagh T, Pierard LA, Trindade PT, Zompatori M, Hoepfer M, Abovans V, Vaz CA, Achenbach S, Agewall S, Allanore Y, Asteggiano R, Paolo BL, Albert BJ, Bouvaist H, Bueno H, Byrne RA, Carerj S, Castro G, Erol C, Falk V, Funck BC, Gorenflo M, Granton J, lung B, Kiely DG, Kirchhof P, Kjellstrom B, Landmesser U, Lekakis J, Lionis C, Lip GY, Orfanos SE, Park MH, Piepoli MF, Ponikowski P, Revel MP, Rigau D, Rosenkranz S, Voller H, Luis Zamorano J. 2015 ESC/ERS Guidelines for the diagnosis and treatment of pulmonary hypertension: The Joint Task Force for the Diagnosis and Treatment of Pulmonary Hypertension of the European Society of Cardiology (ESC) and the European Respiratory Society (ERS): *Endorsed by: Association for European Paediatric and Congenital Cardiology (AEPC), International Society for Heart and Lung Transplantation (ISHLT). *Eur Heart J* 2016;**37**:67–119.
15. McLaughlin VV, Archer SL, Badesch DB, Barst RJ, Farber HW, Lindner JR, Mathier MA, McGoon MD, Park MH, Rosenson RS, Rubin LJ, Tapson VF, Varga J. American College of Cardiology Foundation Task Force on Expert Consensus D, American Heart A, American College of Chest P, American Thoracic Society I, Pulmonary Hypertension A. ACCF/AHA 2009 expert consensus document on pulmonary hypertension a report of the American College of Cardiology Foundation Task Force on Expert Consensus Documents and the American Heart Association developed in collaboration with the American College of Chest Physicians; American Thoracic Society, Inc.; and the Pulmonary Hypertension Association. *J Am Coll Cardiol* 2009;**53**:1573–1619.
16. van de Veerdonk MC, Kind T, Marcus JT, Mauritz GJ, Heymans MW, Bogaard HJ, Boonstra A, Marques KM, Westerhof N, Vonk-Noordegraaf A. Progressive right ventricular dysfunction in patients with pulmonary arterial hypertension responding to therapy. *J Am Coll Cardiol* 2011;**58**:2511–2519.
17. van Wolferen SA, Marcus JT, Boonstra A, Marques KM, Bronzwaer JG, Spreeuwenberg MD, Postmus PE, Vonk-Noordegraaf A. Prognostic value of right ventricular mass, volume, and function in idiopathic pulmonary arterial hypertension. *Eur Heart J* 2007;**28**:1250–1257.
18. D'Alonzo GE, Barst RJ, Ayres SM, Bergofsky EH, Brundage BH, Detre KM, Fishman AP, Goldring RM, Groves BM, Kernis JT. Survival in patients with primary pulmonary hypertension. Results from a national prospective registry. *Ann Intern Med* 1991; **115**:343–349.
19. McLaughlin VV, Sitbon O, Badesch DB, Barst RJ, Black C, Galie N, Rainisio M, Simonneau G, Rubin LJ. Survival with first-line bosentan in patients with primary pulmonary hypertension. *Eur Respir J* 2005;**25**:244–249.
20. Sandoval J, Bauerle O, Palomar A, Gomez A, Martinez-Guerra ML, Beltran M, Guerrero ML. Survival in primary pulmonary hypertension. Validation of a prognostic equation. *Circulation* 1994;**89**:1733–1744.
21. Handoko ML, de Man FS, Allaart CP, Paulus WJ, Westerhof N, Vonk-Noordegraaf A. Perspectives on novel therapeutic strategies for right heart failure in pulmonary arterial hypertension: lessons from the left heart. *Eur Respir Rev* 2010;**19**:72–82.
22. Reesink HJ, Marcus JT, Tulevski II, Jamieson S, Kloek JJ, Vonk Noordegraaf A, Bresser P. Reverse right ventricular remodeling after pulmonary endarterectomy in patients with chronic thromboembolic pulmonary hypertension: utility of magnetic resonance imaging to demonstrate restoration of the right ventricle. *J Thorac Cardiovasc Surg* 2007;**133**:58–64.
23. Gorter TM, Verschuuren EAM, van Veldhuisen DJ, Hoendermis ES, Erasmus ME, Bogaard HJ, Vonk Noordegraaf A, Berger RMF, van Melle JP, Willems TP. Right ventricular recovery after bilateral lung transplantation for pulmonary arterial hypertension. *Interact Cardiovasc Thorac Surg* 2017;**24**:890–897.
24. Galie N, Barbera JA, Frost AE, Ghofrani HA, Hoepfer MM, McLaughlin VV, Peacock AJ, Simonneau G, Vachiery JL, Grunig E, Oudiz RJ, Vonk-Noordegraaf A, White RJ, Blair C, Gillies H, Miller KL, Harris JH, Langley J, Rubin LJ, Investigators A. Initial use of Ambrisentan plus Tadalafil in pulmonary arterial hypertension. *N Engl J Med* 2015;**373**:834–844.
25. Sitbon O, Jais X, Savale L, Cottin V, Bergot E, Macari EA, Bouvaist H, Dauphin C, Picard F, Bulfon S, Montani D, Humbert M, Simonneau G. Upfront triple combination therapy in pulmonary arterial hypertension: a pilot study. *Eur Respir J* 2014;**43**:1691–1697.
26. van de Veerdonk MC, Huis In T Veld AE, Marcus JT, Westerhof N, Heymans MW, Bogaard HJ, Vonk-Noordegraaf A. Upfront combination therapy reduces right ventricular volumes in pulmonary arterial hypertension. *Eur Respir J* 2017;**49**. doi: 10.1183/13993003.00007-2017.
27. Rashkind WJ, Miller WW. Creation of an atrial septal defect without thoracotomy. A palliative approach to complete transposition of the great arteries. *JAMA* 1966; **196**:991–992.
28. Rich S, Lam W. Atrial septostomy as palliative therapy for refractory primary pulmonary hypertension. *Am J Cardiol* 1983;**51**:1560–1561.
29. Al Maluli H, DeStephan CM, Alvarez RJ Jr, Sandoval J. Atrial septostomy: a contemporary review. *Clin Cardiol* 2015;**38**:395–400.
30. Sandoval J, Rothman A, Pulido T. Atrial septostomy for pulmonary hypertension. *Clin Chest Med* 2001;**22**:547–560.
31. Velez-Roa S, Ciarka A, Najem B, Vachiery JL, Naeije R, van de Borne P. Increased sympathetic nerve activity in pulmonary artery hypertension. *Circulation* 2004;**110**:1308–1312.
32. Ciarka A, Vachiery JL, Houssiere A, Gujic M, Stoupele E, Velez-Roa S, Naeije R, van de Borne P. Atrial septostomy decreases sympathetic overactivity in pulmonary arterial hypertension. *Chest* 2007;**131**:1831–1837.
33. Berger R, Moertl D, Peter S, Ahmadi R, Huelsmann M, Yamuti S, Wagner B, Pacher R. N-terminal pro-B-type natriuretic peptide-guided, intensive patient management in addition to multidisciplinary care in chronic heart failure a 3-arm, prospective, randomized pilot study. *J Am Coll Cardiol* 2010;**55**:645–653.
34. Tamura Y, Kimura M, Takei M, Ono T, Kuwana M, Satoh T, Fukuda K, Humbert M. Oral vasopressin receptor antagonist tolvaptan in right heart failure due to pulmonary hypertension. *Eur Respir J* 2015;**46**:283–286.
35. Schumer EM, Black MC, Monreal G, Slaughter MS. Left ventricular assist devices: current controversies and future directions. *Eur Heart J* 2016;**37**:3434–3439.
36. Machuca TN, de Perrot M. Mechanical support for the failing right ventricle in patients with precapillary pulmonary hypertension. *Circulation* 2015;**132**:526–536.
37. Burkhoff D, Sayer G, Doshi D, Uriel N. Hemodynamics of mechanical circulatory support. *J Am Coll Cardiol* 2015;**66**:2663–2674.
38. Krabatsch T, Potapov E, Stepanenko A, Schweiger M, Kukucka M, Huebler M, Hennig E, Hetzer R. Biventricular circulatory support with two miniaturized implantable assist devices. *Circulation* 2011;**124**:S179–S186.
39. Houston BA, Kalathiya RJ, Hsu S, Loungani R, Davis ME, Coffin ST, Haglund N, Maltais S, Keebler ME, Leary PJ, Judge DP, Stevens GR, Rickard J, Sciortino CM, Whitman GJ, Shah AS, Russell SD, Tedford RJ. Right ventricular afterload sensitivity dramatically increases after left ventricular assist device implantation: a multi-center hemodynamic analysis. *J Heart Lung Transplant* 2016;**35**:868–876.
40. Koitabashi N, Kass DA. Reverse remodeling in heart failure—mechanisms and therapeutic opportunities. *Nat Rev Cardiol* 2011;**9**:147–157.
41. Zafeiridis A, Jeevanandam V, Houser SR, Margulies KB. Regression of cellular hypertrophy after left ventricular assist device support. *Circulation* 1998;**98**:656–662.
42. Delgado R 3rd, Radovancevic B, Massin EK, Frazier OH, Benedict C. Neurohormonal changes after implantation of a left ventricular assist system. *Asaio J* 1998;**44**:299–302.
43. Barbone A, Holmes JW, Heerd PM, The AH, Naka Y, Joshi N, Daines M, Marks AR, Oz MC, Burkhoff D. Comparison of right and left ventricular responses to left ventricular assist device support in patients with severe heart failure: a primary role of mechanical unloading underlying reverse remodeling. *Circulation* 2001;**104**:670–675.
44. Bernhardt AM, De By TM, Reichenspurner H, Deuse T. Isolated permanent right ventricular assist device implantation with the HeartWare continuous-flow ventricular assist device: first results from the European Registry for Patients with Mechanical Circulatory Support. *Eur J Cardiothorac Surg* 2015;**48**:158–162.
45. Deuse T, Schirmer J, Kubik M, Reichenspurner H. Isolated permanent right ventricular assistance using the HVAD continuous-flow pump. *Ann Thorac Surg* 2013;**95**:1434–1436.
46. Verbelen T, Verhoeven J, Goda M, Burkhoff D, Delcroix M, Rega F, Meyns B. Mechanical support of the pressure overloaded right ventricle: an acute feasibility study comparing low and high flow support. *Am J Physiol Heart Circ Physiol* 2015;**309**:H615–H624.

47. Verbelen T, Burkhoff D, Kasama K, Delcroix M, Rega F, Meyns B. Systolic and diastolic unloading by mechanical support of the acute vs the chronic pressure overloaded right ventricle. *J Heart Lung Transplant* 2017;**36**:457–465.
48. Suga H. Ventricular energetics. *Physiol Rev* 1990;**70**:247–277.
49. Punnoose L, Burkhoff D, Rich S, Horn EM. Right ventricular assist device in end-stage pulmonary arterial hypertension: insights from a computational model of the cardiovascular system. *Prog Cardiovasc Dis* 2012;**55**:234–243 e232.
50. Dong SJ, Smith ER, Tyberg JV. Changes in the radius of curvature of the ventricular septum at end diastole during pulmonary arterial and aortic constrictions in the dog. *Circulation* 1992;**86**:1280–1290.
51. Tei C. New non-invasive index for combined systolic and diastolic ventricular function. *J Cardiol* 1995;**26**:135–136.
52. Marcus JT, Gan CT, Zwanenburg JJ, Boonstra A, Allaart CP, Gotte MJ, Vonk-Noordegraaf A. Interventricular mechanical asynchrony in pulmonary arterial hypertension: left-to-right delay in peak shortening is related to right ventricular overload and left ventricular underfilling. *J Am Coll Cardiol* 2008;**51**:750–757.
53. Handoko ML, Lamberts RR, Redout EM, de Man FS, Boer C, Simonides WS, Paulus WJ, Westerhof N, Allaart CP, Vonk-Noordegraaf A. Right ventricular pacing improves right heart function in experimental pulmonary arterial hypertension: a study in the isolated heart. *Am J Physiol Heart Circ Physiol* 2009;**297**:H1752–H1759.
54. Mauritz GJ, Marcus JT, Westerhof N, Postmus PE, Vonk-Noordegraaf A. Prolonged right ventricular post-systolic isovolumic period in pulmonary arterial hypertension is not a reflection of diastolic dysfunction. *Heart* 2011;**97**:473–478.
55. Gan C, Lankhaar JW, Marcus JT, Westerhof N, Marques KM, Bronzwaer JG, Boonstra A, Postmus PE, Vonk-Noordegraaf A. Impaired left ventricular filling due to right-to-left ventricular interaction in patients with pulmonary arterial hypertension. *Am J Physiol Heart Circ Physiol* 2006;**290**:H1528–H1533.
56. Lumens J, Arts T, Broers B, Boomars KA, van Paassen P, Prinzen FW, Delhaas T. Right ventricular free wall pacing improves cardiac pump function in severe pulmonary arterial hypertension: a computer simulation analysis. *Am J Physiol Heart Circ Physiol* 2009;**297**:H2196–H2205.
57. Lumens J, Ploux S, Strik M, Gorcsan J 3rd, Cochet H, Derval N, Strom M, Ramanathan C, Ritter P, Haissaguerre M, Jais P, Arts T, Delhaas T, Prinzen FW, Bordachar P. Comparative electromechanical and hemodynamic effects of left ventricular and biventricular pacing in dyssynchronous heart failure: electrical resynchronization versus left-right ventricular interaction. *J Am Coll Cardiol* 2013;**62**:2395–2403.
58. Hardziyenka M, Surie S, de Groot JR, de Bruin-Bon HA, Knops RE, Rimmelink M, Yong ZY, Baan J Jr, Bouma BJ, Bresser P, Tan HL. Right ventricular pacing improves haemodynamics in right ventricular failure from pressure overload: an open observational proof-of-principle study in patients with chronic thromboembolic pulmonary hypertension. *Europace* 2011;**13**:1753–1759.
59. Chow GV, Silverman MG, Tunin RS, Lardo AC, Nazarian S, Kass DA. Efficacy of cardiac resynchronization in acutely infarcted canine hearts with electromechanical dyssynchrony. *Heart Rhythm* 2014;**11**:1819–1826.
60. Kass DA, Chen CH, Curry C, Talbot M, Berger R, Fetits B, Nevo E. Improved left ventricular mechanics from acute VDD pacing in patients with dilated cardiomyopathy and ventricular conduction delay. *Circulation* 1999;**99**:1567–1573.
61. Bristow MR, Saxon LA, Boehmer J, Krueger S, Kass DA, De Marco T, Carson P, DiCarlo L, DeMets D, White BG, DeVries DW, Feldman AM, Comparison Of M, Therapy P, Defibrillation In Heart Failure I. Cardiac-resynchronization therapy with or without an implantable defibrillator in advanced chronic heart failure. *N Engl J Med* 2004;**350**:2140–2150.
62. Chirinos JA, Segers P, Gupta AK, Swillens A, Rietzschel ER, De Buyzere ML, Kirkpatrick JN, Gillette TC, Wang Y, Keane MG, Townsend R, Ferrari VA, Wieggers SE, St John Sutton M. Time-varying myocardial stress and systolic pressure–stress relationship: role in myocardial-arterial coupling in hypertension. *Circulation* 2009;**119**:2798–2807.
63. Sano M, Minamino T, Toko H, Miyachi H, Orimo M, Qin Y, Akazawa H, Tateno K, Kayama Y, Harada M, Shimizu I, Asahara T, Hamada H, Tomita S, Molkenin JD, Zou Y, Komuro I. p53-induced inhibition of Hif-1 causes cardiac dysfunction during pressure overload. *Nature* 2007;**446**:444–448.
64. Des Tombe AL, Van Beek-Harmsen BJ, Lee-De Groot MB, Van Der Laarse WJ. Calibrated histochemistry applied to oxygen supply and demand in hypertrophied rat myocardium. *Microsc Res Tech* 2002;**58**:412–420.
65. Redout EM, Wagner MJ, Zuidwijk MJ, Boer C, Musters RJ, van Hardeveld C, Paulus WJ, Simonides WS. Right-ventricular failure is associated with increased mitochondrial complex II activity and production of reactive oxygen species. *Cardiovasc Res* 2007;**75**:770–781.
66. Simonides WS, Mulcahey MA, Redout EM, Muller A, Zuidwijk MJ, Visser TJ, Wassen FW, Crescenzi A, da-Silva WS, Harney J, Engel FB, Obregon MJ, Larsen PR, Bianco AC, Huang SA. Hypoxia-inducible factor induces local thyroid hormone inactivation during hypoxic-ischemic disease in rats. *J Clin Invest* 2008;**118**:975–983.
67. Sutendra G, Dromparis P, Paulin R, Zervopoulos S, Haromy A, Nagendran J, Michelakis ED. A metabolic remodeling in right ventricular hypertrophy is associated with decreased angiogenesis and a transition from a compensated to a decompensated state in pulmonary hypertension. *J Mol Med* 2013;**91**:1315–1327.
68. Wong YY, Westerhof N, Rüter G, Lubberink M, Raijmakers P, Knaepen P, Marcus JT, Boonstra A, Lammertsma AA, van der Laarse WJ, Vonk-Noordegraaf A. Systolic pulmonary artery pressure and heart rate are main determinants of oxygen consumption in the right ventricular myocardium of patients with idiopathic pulmonary arterial hypertension. *Eur J Heart Fail* 2011;**13**:1290–1295.
69. Westerhof N, Boer C, Lamberts RR, Sipkema P. Cross-talk between cardiac muscle and coronary vasculature. *Physiol Rev* 2006;**86**:1263–1308.
70. Gomez A, Bialostozky D, Zajarías A, Santos E, Palomar A, Martínez ML, Sandoval J. Right ventricular ischemia in patients with primary pulmonary hypertension. *J Am Coll Cardiol* 2001;**38**:1137–1142.
71. Saito D, Uchida S, Obayashi N, Maekawa K, Mizuo K, Kobayashi H, Tani H, Haraoka S. Relationship between pressure-rate product and myocardial oxygen consumption of normal and hypertrophic right ventricles in open-chest dogs. *Jpn Circ J* 1993;**57**:533–542.
72. van der Laarse WJ, Des Tombe AL, van Beek-Harmsen BJ, Lee-de Groot MB, Jaspers RT. Krogh's diffusion coefficient for oxygen in isolated *Xenopus* skeletal muscle fibers and rat myocardial trabeculae at maximum rates of oxygen consumption. *J Appl Physiol* (1985) 2005;**99**:2173–2180.
73. Vogel-Claussen J, Skrok J, Shehata ML, Singh S, Sibley CT, Boyce DM, Lechtzin N, Girgis RE, Mathai SC, Goldstein TA, Zheng J, Lima JA, Bluemke DA, Hassoun PM. Right and left ventricular myocardial perfusion reserves correlate with right ventricular function and pulmonary hemodynamics in patients with pulmonary arterial hypertension. *Radiology* 2011;**258**:119–127.
74. Rüter G, Ying Wong Y, de Man FS, Louis Handoko M, Jaspers RT, Postmus PE, Westerhof N, Niessen HW, van der Laarse WJ, Vonk-Noordegraaf A. Right ventricular oxygen supply parameters are decreased in human and experimental pulmonary hypertension. *J Heart Lung Transplant* 2013;**32**:231–240.
75. Archer SL, Fang YH, Ryan JJ, Piao L. Metabolism and bioenergetics in the right ventricle and pulmonary vasculature in pulmonary hypertension. *Pulm Circ* 2013;**3**:144–152.
76. Wong YY, Handoko ML, Mouchaers KT, de Man FS, Vonk-Noordegraaf A, van der Laarse WJ. Reduced mechanical efficiency of rat papillary muscle related to degree of hypertrophy of cardiomyocytes. *Am J Physiol Heart Circ Physiol* 2010;**298**:H1190–H1197.
77. Maarman G, Blackhurst D, Thienemann F, Blauwet L, Butrous G, Davies N, Sliwa K, Lecour S. Melatonin as a preventive and curative therapy against pulmonary hypertension. *J Pineal Res* 2015;**59**:343–353.
78. Farahmand F, Hill MF, Singal PK. Antioxidant and oxidative stress changes in experimental cor pulmonale. *Mol Cell Biochem* 2004;**260**:21–29.
79. Redout EM, van der Toorn A, Zuidwijk MJ, van de Kolk CW, van Echteld CJ, Musters RJ, van Hardeveld C, Paulus WJ, Simonides WS. Antioxidant treatment attenuates pulmonary arterial hypertension-induced heart failure. *Am J Physiol Heart Circ Physiol* 2010;**298**:H1038–H1047.
80. Chaumais MC, Ranceh B, Montani D, Dorfmueller P, Tu L, Lecerf F, Raymond N, Guignabert C, Price L, Simonneau G, Cohen-Kaminsky S, Humbert M, Perros F. N-Acetylcysteine improves established monocrotaline-induced pulmonary hypertension in rats. *Respir Res* 2014;**15**:65.
81. Kollí MB, Manne ND, Para R, Nalabotu SK, Nandyala G, Shokuhfar T, He K, Hamlekhan A, Ma JY, Wehner PS, Dornon L, Arvapalli R, Rice KM, Blough ER. Cerium oxide nanoparticles attenuate monocrotaline induced right ventricular hypertrophy following pulmonary arterial hypertension. *Biomaterials* 2014;**35**:9951–9962.
82. Murphy E, Ardehali H, Balaban RS, DiLisa F, Dorn GW 2nd, Kitsis RN, Otsu K, Ping P, Rizzuto R, Sack MN, Wallace D, Youle RJ. American Heart Association Council on Basic Cardiovascular Sciences CoCC, Council on Functional G, Translational B. Mitochondrial Function, Biology, and Role in Disease: A Scientific Statement From the American Heart Association. *Circ Res* 2016;**118**:1960–1991.
83. van Beek-Harmsen BJ, van der Laarse WJ. Immunohistochemical determination of cytosolic cytochrome C concentration in cardiomyocytes. *J Histochem Cytochem* 2005;**53**:803–807.
84. van Eif VV, Bogaards SJ, van der Laarse WJ. Intrinsic cardiac adrenergic (ICA) cell density and MAO-A activity in failing rat hearts. *J Muscle Res Cell Motil* 2014;**35**:47–53.
85. Rüter G, Lankhorst S, Boonstra A, Postmus PE, Zweegman S, Westerhof N, van der Laarse WJ, Vonk-Noordegraaf A. Iron deficiency is common in idiopathic pulmonary arterial hypertension. *Eur Respir J* 2011;**37**:1386–1391.
86. Rüter G, Manders E, Happe CM, Schali J, Groepenhoff H, Howard LS, Wilkins MR, Bogaard HJ, Westerhof N, van der Laarse WJ, de Man FS, Vonk-Noordegraaf A. Intravenous iron therapy in patients with idiopathic pulmonary arterial hypertension and iron deficiency. *Pulm Circ* 2015;**5**:466–472.
87. Peters EL, Offringa C, Kos D, Van der Laarse WJ, Jaspers RT. Regulation of myoglobin in hypertrophied rat cardiomyocytes in experimental pulmonary hypertension. *Pflugers Arch – Eur J Physiol* 2016;**468**:1697–1707.
88. Potus F, Ruffenach G, Dahou A, Thebault C, Breuils-Bonnet S, Tremblay E, Nadeau V, Paradis R, Graydon C, Wong R, Johnson I, Paulin R, Lajoie AC, Perron J, Charbonneau E, Joubert P, Pibarot P, Michelakis ED, Provencher S, Bonnet S. Downregulation of MicroRNA-126 contributes to the failing right ventricle in pulmonary arterial hypertension. *Circulation* 2015;**132**:932–943.
89. Hall AR, Burke N, Dongworth RK, Hausenloy DJ. Mitochondrial fusion and fission proteins: novel therapeutic targets for combating cardiovascular disease. *Br J Pharmacol* 2014;**171**:1890–1906.

90. Youle RJ, van der Blik AM. Mitochondrial fission, fusion, and stress. *Science* 2012;**337**:1062–1065.
91. Longo DL, Archer SL. Mitochondrial dynamics – mitochondrial fission and fusion in human diseases. *N Engl J Med* 2013;**369**:2236–2251.
92. Tian L, Neuber-Hess M, Mewburn J, Dasgupta A, Dunham-Snary K, Wu D, Chen KH, Hong Z, Sharp WW, Kutty S, Archer SL. Ischemia-induced Drp1 and Fis1-mediated mitochondrial fission and right ventricular dysfunction in pulmonary hypertension. *J Mol Med* 2017;**95**:381–393.
93. Sutendra G, Michelakis ED. The metabolic basis of pulmonary arterial hypertension. *Cell Metab* 2014;**19**:558–573.
94. Paulin R, Michelakis ED. The metabolic theory of pulmonary arterial hypertension. *Circ Res* 2014;**115**:148–164.
95. Ryan JJ, Archer SL. Emerging concepts in the molecular basis of pulmonary arterial hypertension: Part I: metabolic plasticity and mitochondrial dynamics in the pulmonary circulation and right ventricle in pulmonary arterial hypertension. *Circulation* 2015;**131**:1691–1702.
96. Fang YH, Piao L, Hong Z, Toth PT, Marsboom G, Bache-Wiig P, Rehman J, Archer SL. Therapeutic inhibition of fatty acid oxidation in right ventricular hypertrophy: exploiting Randle's cycle. *J Mol Med* 2012;**90**:31–43.
97. Piao L, Fang YH, Cadete VJ, Wietholt C, Urboniene D, Toth PT, Marsboom G, Zhang HJ, Haber I, Rehman J, Lopaschuk GD, Archer SL. The inhibition of pyruvate dehydrogenase kinase improves impaired cardiac function and electrical remodeling in two models of right ventricular hypertrophy: resuscitating the hibernating right ventricle. *J Mol Med* 2010;**88**:47–60.
98. Kim JW, Tchernyshyov I, Semenza GL, Dang CV. HIF-1-mediated expression of pyruvate dehydrogenase kinase: a metabolic switch required for cellular adaptation to hypoxia. *Cell Metab* 2006;**3**:177–185.
99. Dai DF, Chen T, Szeto H, Nieves-Cintrón M, Kuttyavin V, Santana LF, Rabinovitch PS. Mitochondrial targeted antioxidant peptide ameliorates hypertensive cardiomyopathy. *J Am Coll Cardiol* 2011;**58**:73–82.
100. Ciarka A, Doan V, Velez-Roa S, Naeije R, van de Borne P. Prognostic significance of sympathetic nervous system activation in pulmonary arterial hypertension. *Am J Respir Crit Care Med* 2010;**181**:1269–1275.
101. Bristow MR, Ginsburg R, Umans V, Fowler M, Minobe W, Rasmussen R, Zera P, Menlove R, Shah P, Jamieson S. Beta 1- and beta 2-adrenergic-receptor subpopulations in nonfailing and failing human ventricular myocardium: coupling of both receptor subtypes to muscle contraction and selective beta 1-receptor down-regulation in heart failure. *Circ Res* 1986;**59**:297–309.
102. Rain S, Bos D, Handoko ML, Westerhof N, Stienen G, Ottenheijm C, Goebel M, Dorfmueller P, Guignabert C, Humbert M, Bogaard H-J, Remedios CD, Saripalli C, Hidalgo CG, Granzier HL, Vonk-Noordegraaf A, van der Velden J, de Man FS. Protein changes contributing to right ventricular cardiomyocyte diastolic dysfunction in pulmonary arterial hypertension. *J Am Heart Assoc* 2014;**3**:e000716.
103. van der Velden J, de Jong JW, Owen VJ, Burton PB, Stienen GJ. Effect of protein kinase A on calcium sensitivity of force and its sarcomere length dependence in human cardiomyocytes. *Cardiovasc Res* 2000;**46**:487–495.
104. de Man FS, Handoko ML, Guignabert C, Bogaard HJ, Vonk-Noordegraaf A. Neurohormonal axis in patients with pulmonary arterial hypertension: friend or foe? *Am J Respir Crit Care Med* 2013;**187**:14–19.
105. Spruijt OA, de Man FS, Groepenhoff H, Oosterveer F, Westerhof N, Vonk-Noordegraaf A, Bogaard HJ. The effects of exercise on right ventricular contractility and right ventricular-arterial coupling in pulmonary hypertension. *Am J Respir Crit Care Med* 2015;**191**:1050–1057.
106. Rain S, Handoko ML, Trip P, Gan CT, Westerhof N, Stienen GJ, Paulus WJ, Ottenheijm CA, Marcus JT, Dorfmueller P, Guignabert C, Humbert M, Macdonald P, Dos Remedios C, Postmus PE, Saripalli C, Hidalgo CG, Granzier HL, Vonk-Noordegraaf A, van der Velden J, de Man FS. Right ventricular diastolic impairment in patients with pulmonary arterial hypertension. *Circulation* 2013;**128**:2016–2025. 2011–2010.
107. Provencher S, Herve P, Jais X, Lebrec D, Humbert M, Simonneau G, Sitbon O. Deleterious effects of beta-blockers on exercise capacity and hemodynamics in patients with portopulmonary hypertension. *Gastroenterology* 2006;**130**:120–126.
108. Brimiouille S, Wauthy P, Ewalenko P, Rondelet B, Vermeulen F, Kerbaul F, Naeije R. Single-beat estimation of right ventricular end-systolic pressure–volume relationship. *Am J Physiol Heart Circ Physiol* 2003;**284**:H1625–H1630.
109. Bogaard HJ, Natarajan R, Mizuno S, Abbate A, Chang PJ, Chau VQ, Hoke NN, Kraskauskas D, Kasper M, Salloum FN, Voelkel NF. Adrenergic receptor blockade reverses right heart remodeling and dysfunction in pulmonary hypertensive rats. *Am J Respir Crit Care Med* 2010;**182**:652–660.
110. de Man FS, Handoko ML, van Ballegoij JJ, Schlij I, Bogaards SJ, Postmus PE, van der Velden J, Westerhof N, Paulus WJ, Vonk-Noordegraaf A. Bisoprolol delays progression towards right heart failure in experimental pulmonary hypertension. *Circ Heart Fail* 2012;**5**:97–105.
111. van Campen JS, de Boer K, van de Veerdonk MC, van der Bruggen CE, Allaart CP, Raijmakers PG, Heymans MW, Marcus JT, Harms HJ, Handoko ML, de Man FS, Vonk-Noordegraaf A, Bogaard HJ. Bisoprolol in idiopathic pulmonary arterial hypertension: an explorative study. *Eur Respir J* 2016;**48**:787–796.
112. de Man FS, Tu L, Handoko ML, Rain S, Ruiter G, Francois C, Schlij I, Dorfmueller P, Simonneau G, Fadel E, Perros F, Boonstra A, Postmus PE, van der Velden J, Vonk-Noordegraaf A, Humbert M, Eddahibi S, Guignabert C. Dysregulated renin–angiotensin–aldosterone system contributes to pulmonary arterial hypertension. *Am J Respir Crit Care Med* 2012;**186**:780–789.
113. Maron BA, Leopold JA. Emerging concepts in the molecular basis of pulmonary arterial hypertension: Part II: neurohormonal signaling contributes to the pulmonary vascular and right ventricular pathophenotype of pulmonary arterial hypertension. *Circulation* 2015;**131**:2079–2091.
114. da Silva Gonçalves Bos D, Happé C, Schlij I, Pijacka W, Paton JFR, Guignabert C, Tu L, Thuillet R, Bogaard H-J, van Rossum AC, Vonk-Noordegraaf A, de Man FS, Handoko ML. Renal denervation reduces pulmonary vascular remodeling and right ventricular diastolic stiffness in experimental pulmonary hypertension. *JACC: Basic Transl Sci* 2017;**2**:22.
115. da Silva Gonçalves Bos D, Sun X-Q, Vonk-Noordegraaf A, de Man FS, Handoko ML. Parasympathetic nervous stimulation by pyridostigmine improves survival and cardiac function in experimental pulmonary arterial hypertension. American Thoracic Society 2016 International Conference. San Francisco, CA, 2016.