



Myofascial-entheseal dysfunction in chronic whiplash injury: an observational study

QMK Bismil¹ • MSK Bismil²

¹Consultant Orthopaedic Surgeon, The Wellington Hospital, London NW8 9LE, UK

²Consultant Orthopaedic Surgeon, ExpertOrthopaedics.Com, Boston, Lincolnshire PE21 9DP, UK

Correspondence to: QMK Bismil. Email: enquiries@expertorthopaedics.com

DECLARATION

Competing interests

None declared

Funding

None

Ethical approval

This is an observational study of a longstanding medicolegal practice, and clearly neither the medicolegal process nor patient management has been affected in any way by this study: hence no ethical approval has been sought

Guarantor

QMKB

Contributorship

Both authors have assessed all participants in this study; hence all listed authors are contributors. Both authors have contributed equally to this paper and have given

Summary

Objectives To document any consistent clinical findings in a large cohort of patients with whiplash associated disorder.

Design Four-year observational study.

Setting Large orthopaedic medicolegal practice in the UK.

Participants 1025 consecutive cases of chronic whiplash associated disorder.

Main outcome measures Observational study of the clinical features of whiplash associated disorder: detailed examination

Results Three consistent clinical features: neck pain; reduced cervical spine range of motion; and myofascial-entheseal dysfunction. With regards to the myofascial-entheseal dysfunction there were trigger points in the upper, middle or lower trapezius; with or without enthesopathy in the lower or middle trapezius.

Conclusions On the basis of this large observational experience we propose a clinically-based definition of chronic whiplash associated disorder: a painful syndrome following acceleration-deceleration injury with neck stiffness; and myofascial-entheseal dysfunction.

Introduction

Chronic whiplash associated disorder is a challenging and apparently heterogeneous entity. In 1995 the Quebec Task Force published their systematic review of whiplash injuries and defined whiplash associated disorder mechanistically as an acceleration-deceleration mechanism of energy transfer to the neck.¹ One of the problems is that the clinical findings in whiplash injuries do not appear consistent. The question is whether this is because this is a heterogeneous group of patients and problems; or because as

clinicians we have thus far been unable to fully characterize the condition.

Increasingly, the role of enthesopathy, myofascial pain and trigger points in musculoskeletal pain generation is being recognized; and are presently the subject of a great deal of clinical and basic science study: both in terms of the general and specific (regional) issues. Thus far, a Pubmed search does not reveal any clinical investigation of the role of myofascial-entheseal dysfunction in whiplash injury: hence initially the general concepts of myofascial-entheseal dysfunction and parallels with regional myofascial-entheseal

permission for their names to be included as co-authors.

Acknowledgments
Annamma Bismil,
Nursing Sister,
ExpertOrthopaedics.
Com

Reviewer
Kamran Abbasi

dysfunction which had been characterized were necessary.

We have previously elucidated the role of enthesopathy and dysfunction of the musculo-fascial unit in chronic sporting soft-tissue problems.^{2,3} The basic science work of Benjamin *et al.*⁴ on the enthesis has enabled clinicians to better characterize chronic soft-tissue problems which have previously been largely misunderstood. Thus, dysfunction of the enthesal-myofascial unit is now recognized as key in conditions that were previously considered to have an acute inflammatory component, such as tennis elbow (lateral epicondylitis),⁴ golfer's elbow (medial epicondylitis)⁴ and in chronic athletic groin pain (osteitis pubis).³ It is now clear that enthesopathy has a role in all of these conditions. Entheses are specialized attachments of myofascial units to bone and are sites of stress concentration, and hence are prone to microtrauma and chronic inflammation:⁴ this is termed enthesopathy (Table 1). Enthesopathy can sometimes be visualized on gadolinium enhanced MRI scanning once the correct protocol has been devised,^{2,3} and MRI-positive enthesopathy is usually seen in more severely affected cases.^{2,3}

The trapezius muscle is a large diamond-shaped superficial muscle which attaches in the midline from the occiput through to the mid-thoracic spine, and laterally to the scapula and lateral clavicle; and with upper, middle and lower components. The muscle is the commonest site of myofascial dysfunction with trigger points in the human body;⁵ and enthesopathy is also known to be a clinical issue. Whilst there have been, as far as we are aware, no clinical studies of the trapezius in a large series of whiplash patients: trapezius abnormalities in this patient group are well-documented.^{6,7} This observational study aimed initially only to document any totally consistent

clinical findings in whiplash injury; but in the second phase of the study we then sought to characterize the ubiquitous myofascial-enthesal dysfunction which was documented in the first phase; and indeed which has been observed by others on a basic science level.^{6,7}

Methods

Between 2009 and 2012, the authors examined 1000 patients with whiplash injury, according to the Quebec Task force mechanistic definition, with chronic symptoms (over six months duration) (Table 2). We documented the circumstances of the accident, progression of symptoms and treatment and clinical features.

In the 1000 patients examined, there were indeed consistent findings, of reduced range of cervical spine movement; and myofascial-enthesal dysfunction. For the second phase of the study we sought to document the nature of the myofascial-enthesal dysfunction in 25 consecutive cases.

There were three solely consistent features in all 1025 patients: acceleration-deceleration injury to cervical spine; reduced range of cervical spine movement; and dysfunction of the trapezius muscle with or without enthesopathy.

In 2012 we then documented the specifics of the myofascial-enthesal dysfunction in twenty-five consecutive cases, specifically with regards to myo-fascial dysfunction of the trapezius; the presence or absence of enthesopathy; and the site of the problem (upper, middle or lower trapezius).

Results for case series

- Mean age 42 years
- 44% male, 56% female

Table 1
Enthesopathy clinical features

- Tender 'enthesis'
 - Attachment of myofascial unit to bone
 - Site of stress concentration
 - Prone to microtrauma and chronic inflammation
- Pain on passive stretching
- Pain on resisted movement

Table 2
Inclusion criteria for 1000 cases

- Medium or low delta V indirect injury with energy transfer to the neck including shoulders but no direct impact.
- Quebec grade II
 - No neurological deficit
- Pain for more than six months after index accident
- Pain within 1 week of accident
- Consulted doctor within 3 weeks of accident

- Mean range of global cervical spine movement restriction 9.2 %
 - Range 5–15%
- Myofascial-enthesal dysfunction in all patients (Figure 1):
 - Table 3
 - Bilateral 60%; unilateral 40%
- Enthesopathy (see Table 1)
 - middle and lower parts of trapezius
 - At scapular attachment
 - 48%

Discussion

The Quebec Task force mechanistic definition of whiplash associated disorder is useful, simple but also clinically ambiguous. Chronic whiplash injuries are difficult to treat and assess for many reasons, but we suggest the lack of a consistent and all-encompassing clinically-based definition is a major factor. The trapezius muscle has been implicated in basic science work on whiplash injury^{6–7} but appears thus far to have been overlooked from a clinical perspective. The muscle is known to be the commonest site of myofascial dysfunction,⁵ and its anatomy correlates with the symptoms of whiplash: neck pain/headaches-upper part; shoulder/scapular pain-middle part; and scapular/thoracic radiation-lower part.

The authors Yoganandan and Pintar and colleagues have extensively researched the

Table 3

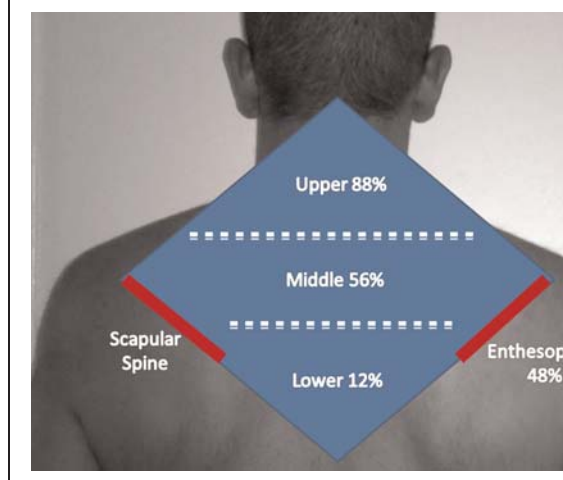
Myofascial-enthesal dysfunction site	
Upper	88%
Middle	56%
Lower	12%

kinematics and biomechanics of this injury.^{8,9} Their biomechanical, cadaveric and computer-model research has provided an important biomechanical insight into the nature of whiplash injury. Thus, in the first phase of a whiplash injury the upper cervical spine-head undergoes flexion while the lower cervical spine is in extension, and there is a reverse curvature of the head-neck complex. Initially the head lags behind and then 'catches up' with the neck. In the second phase of whiplash injury, the entirety of the head and neck is under an extension force, with a resultant single extension curvature. The lower cervical facet joints undergo compression and sliding: such that there is generalized sliding; with more compression posteriorly; resulting in a 'pinching' mechanism. It is our impression that the cervical facet joint injury is at least in part responsible for the neck stiffness that we have consistently observed in these patients.

The trapezius muscle has upper, middle and lower components; and all three areas are a relatively common source of myofascial pain with trigger points.⁵ Enthesopathy may affect the middle and lower parts of the muscle.⁵ Clinically, enthesopathy may be defined as: tender enthesis; pain on passive stretching; and pain on resisted muscle movement.^{2,3} The present study demonstrates that myofascial-enthesal dysfunction and enthesopathy is a consistent clinical features in chronic whiplash injuries. On the basis of our re-analysis of the available evidence of whiplash kinematics in light of the present study, we hypothesize that during the whiplash mechanism there is eccentric loading of the trapezius unit with microtrauma to the trapezius unit; and it is our impression that the trapezius is especially vulnerable during the transition between the first and second phases of the whiplash mechanism.

In the current paper, we have sought to document the consistent clinical findings in a large consecutive series of chronic whiplash cases; and the only totally consistent findings are reduced range of motion and dysfunction of the trapezius muscle. It appears that the role of the trapezius muscle has, thus far, largely been overlooked by

Figure 1
Myofascial-enthesal dysfunction in chronic whiplash injury



clinicians in the whiplash syndrome. We suggest that this may be partly due to the relatively recent identification of enthesopathy and myofascial dysfunction as common sources of musculoskeletal pain. However, from a basic science perspective, trapezius abnormalities have been clearly demonstrated in whiplash patients.^{6,7} Clearly there are a multitude of other potential pain sources in whiplash injuries, but we suggest that logical treatment of chronic whiplash injuries should in the first instance target the neck stiffness and myofascial-enthesal dysfunction which appears to be ubiquitous.

The detailed analysis of the myofascial-enthesal dysfunction documents that the combination of myofascial dysfunction with trigger points and enthesopathy is a consistent finding in whiplash injuries. In our analysis, the upper trapezius is the usual site of myofascial dysfunction, with or without dysfunction in the lower and middle parts of the muscle. Trapezius enthesopathy was present in the middle and lower parts of the muscle at the scapular insertion in almost half of the whiplash patients. Interestingly, we did not observe any cases of enthesopathy of the attachment of the upper trapezius into the lateral clavicle in this patient cohort. Neither were we able to disintermidline trapezius enthesopathy from myofascial or facet joint dysfunction. The last decade has seen great advances in the understanding of the entheses and enthesopathy,²⁻⁴ but the trapezius entheses have not been fully characterized. It is our hypothesis that the 'entheses organ'⁴ of the middle and lower trapezius at the scapular attachment is damaged during eccentric loading of the trapezius; and that the scapular attachment is particularly prone to stress concentration. This hypothesis can be tested in the future through basic science and imaging studies.

Whilst the present observational study demonstrates that myofascial-enthesal dysfunction is ubiquitous in chronic whiplash injury, it is clear that there are a range of potential pain sources in these patients. Other factors may include changes in cerebral blood flow,¹⁰ biopsychosocial factors¹¹ and altered nociception.

We suggest the following clinical definition of chronic whiplash injury: a syndrome of pain following acceleration-deceleration injury, with reduced range of cervical spine movement and myofascial-enthesal dysfunction. Moreover, we suggest that rehabilitation should target these clinical abnormalities.

References

- 1 Spitzer WO, Skovron ML, Salmi LR, *et al*. Scientific monograph of the Quebec Task Force on whiplash-associated disorders: redefining 'whiplash' and its management. *Spine* 1995;**20**(8 Suppl):1S-73S
- 2 Schilders E, Bismil Q, Robinson P, O'Connor PJ, Gibbon WW, Talbot JC. Adductor-related groin pain in competitive athletes: the role of MRI and enthesal pubic cleft injections. *The Journal of Bone and Joint Surgery (American)* 2007;**89**:2173-2178
- 3 Schilders E, Talbot JC, Robinson P, Dimitrakopoulou A, Gibbon WW, Bismil Q. Adductor-related groin pain in recreational athletes: role of the adductor entheses, magnetic resonance imaging, and enthesal pubic cleft injections. *J Bone Joint Surg Am* 2009;**91**:2455-60
- 4 Benjamin M, Toumi H, Ralphs JR, Bydder G, Best TM, Milz S. Where tendons and ligaments meet bone: attachment sites ('entheses') in relation to exercise and/or mechanical load. *Journal of Anatomy* 2006;**208**:471-490. doi: 10.1111/j.1469-7580.2006.00540.x
- 5 Travell JG, Simons DG. Myofascial Pain and Dysfunction. *The Trigger Point Manual*. Vol 2. Baltimore, Md: Williams & Wilkins; 1992:168-185
- 6 Nederhand MJ, IJzerman MJ, Hermens HJ, Baten CT, Zilvold G. Cervical muscle dysfunction in the chronic whiplash associated disorder grade II (WAD-II). *Spine (Phila Pa 1976)* 2000;**25**:1938-43
- 7 Gerdle B, Lemming D, Kristiansen J, Larsson B, Peolsson M, Rosendal L. Biochemical alterations in the trapezius muscle of patients with chronic whiplash associated disorders (WAD)—a microdialysis study. *Eur J Pain* 2008;**12**:82-93 Epub 2007 Apr 24
- 8 Stemper BD, Yoganandan N, Gennarelli TA, Pintar FA. Localized cervical facet joint kinematics under physiological and whiplash loading. *J Neurosurg Spine* 2005;**3**:471-6
- 9 Cusick JF, Pintar FA, Yoganandan N. Whiplash syndrome: kinematic factors influencing pain patterns. *Spine (Phila Pa 1976)* 2001;**26**:1252-8
- 10 Linnman C, Appel L, Söderlund A, *et al*. 'Chronic whiplash symptoms are related to altered regional cerebral blood flow in the resting state'. *Eur J Pain* 2009;**12**:65-70
- 11 Ferrari R, Schrader H. 'The late whiplash syndrome: a biopsychosocial approach'. *J Neurol Neurosurg Psychiatr* 2001;**70**:722-6. doi:10.1136/jnnp.70.6.722. PMC 1737376. PMID 11385003

© 2012 Royal Society of Medicine Press

This is an open-access article distributed under the terms of the Creative Commons Attribution License (<http://creativecommons.org/licenses/by-nc/2.0/>), which permits non-commercial use, distribution and reproduction in any medium, provided the original work is properly cited.