

Comparing the Pemberton osteotomy and modified San Diego acetabuloplasty in developmental dysplasia of the hip

R. Badrinath^{1,2}
J. D. Bomar²
D. R. Wenger^{1,2}
S. J. Mubarak^{1,2}
V. V. Upasani^{1,2}

Abstract

Purpose Patients with developmental dysplasia of the hip (DDH) may require a pelvic osteotomy to treat acetabular dysplasia. The Pemberton osteotomy and modified San Diego acetabuloplasty are two options available when surgically treating DDH. The purpose of this study was to compare outcomes following the Pemberton and modified San Diego when treating patients with acetabular dysplasia in typical DDH.

Methods We included 45 hips in the modified San Diego group and 38 hips in the Pemberton group. Hips with less than two years follow-up and patients with a neuromuscular diagnosis were excluded. Clinical outcomes were rated using the modified McKay criteria with radiographic outcomes graded using the Severin score. Avascular necrosis (AVN) was assessed using the Kalamchi and MacEwen criteria.

Results Mean follow-up was 4.9 years (2.1 to 11.2). Both procedures produced similar decreases in the acetabular index (modified San Diego: 17.0° versus Pemberton: 15.2°; $p = 0.846$). Most hips had good/excellent results using the modified McKay criteria (modified San Diego: 78%, Pemberton: 94%; $p = 0.055$). Most hips were rated as good/excellent on the Severin scale (modified San Diego: 100%, Pemberton: 97%, $p = 0.485$). The proportion of hips with AVN grade 2 or higher were similar between groups (modified San Diego: 0%, Pemberton: 3%; $p = 0.458$).

Conclusion The modified San Diego acetabuloplasty is a safe and effective alternative to treat acetabular dysplasia in patients with typical DDH. By maintaining an intact medial cor-

tex, acetabular reshaping can be customized to address each patient's specific acetabular deficiency.

Level of evidence: Level III retrospective comparison

Cite this article: Badrinath R, Bomar JD, Wenger DR, Mubarak SJ, Upasani VV. Comparing the Pemberton osteotomy and modified San Diego acetabuloplasty in developmental dysplasia of the hip. *J Child Orthop* 2019;13:172-179. DOI: 10.1302/1863-2548.13.190004

Keywords: hip dysplasia; Pemberton osteotomy; San Diego acetabuloplasty

Introduction

Acetabular dysplasia past infancy often requires surgical treatment to increase acetabular coverage and improve hip congruence.¹ The choice of treatment is dependent on patient age. In infants, concentric reduction of the femoral head into the acetabulum, through closed or open reduction, and maintained hip abduction, is generally sufficient to encourage reciprocal remodelling and development of a congruent and well covered hip. In older children, most orthopaedic surgeons agree that treatment with a pelvic osteotomy, with or without a concomitant femoral procedure, is warranted to ensure adequate femoral head coverage.^{2,3} When successful, this redirects shear forces on cartilage to better tolerated compressive forces, resulting in decreased chondral damage and increased survivability of the hip.

Reshaping osteotomies such as the Pemberton pericapsular osteotomy rely on an open triradiate cartilage hinge and alter the shape of the acetabulum to better cover the femoral head. Specifically, the Pemberton osteotomy uses an incomplete cut through the ilium extending through both the medial and lateral tables of the ilium, and hinges on the posterior limb of the triradiate cartilage to provide increased anterior and lateral coverage^{4,5} (Fig. 1). The sciatic notch is not cut. The incomplete cut through the ilium maintains inherent stability and does not usually require supplementary internal fixation (in contrast to complete osteotomies such as the Salter innominate osteotomy).

The San Diego acetabuloplasty was originally designed to address the acetabular deficiency in patients with hip dysplasia secondary to neuromuscular disease. Early

¹University of California, San Diego Medical Center, San Diego, California, USA

²Rady Children's Hospital, San Diego, California, USA

Correspondence should be sent to Vidyadhar V. Upasani, MD, Rady Children's Hospital, San Diego, 3020 Children's Way, Mail Code 5062, San Diego, CA 92123, USA.

E-mail: vupasani@rchsd.org

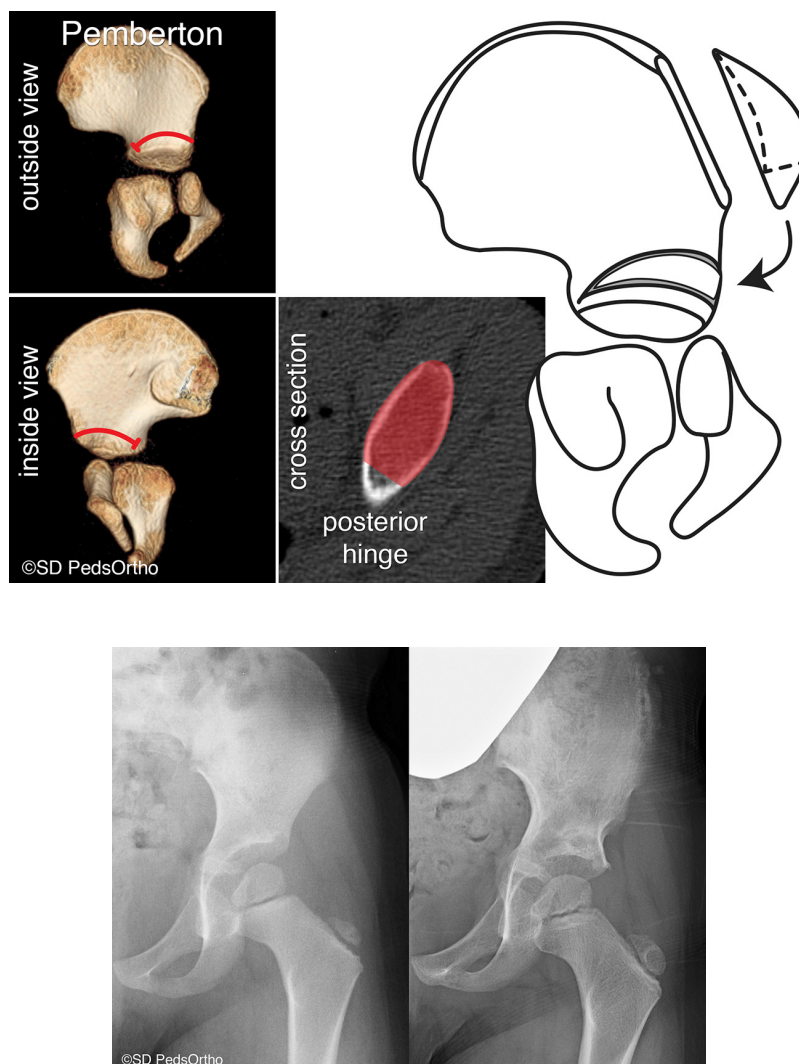


Fig. 1 (a) Illustration of the Pemberton acetabuloplasty; (b) pre- and postoperative radiographs of Pemberton acetabuloplasty.

studies identified predominantly posterosuperior or direct lateral undercoverage in these patients, *versus* the anterolateral deficiency which is common in developmental dysplasia of the hip (DDH).^{6,7} As originally described, the San Diego acetabuloplasty utilizes a cut through the anterior inferior iliac spine anteriorly and the sciatic notch posteriorly. This is extended through the outer cortex of the ilium, however, the medial cortex of the ilium remains intact. The acetabulum is hinged on the anterior and posterior limbs of the triradiate cartilage, and autologous bone grafts are utilized to wedge the osteotomy open. The unicortical osteotomy allows the surgeon to alter the shape of the acetabulum specifically to address the deficiency simply by changing the size and placement of the bone grafts.^{8,9} Figure 2 illustrates the San Diego acetabuloplasty.

Analysis of acetabular morphology using 3D CT scans demonstrates that the acetabular deficiency in develop-

mental hip dysplasia can occasionally be directly lateral, anterior superior or posterior superior, even in children without neuromuscular disease.^{10,11} We have consequently expanded use of the San Diego acetabuloplasty (Fig. 3) beyond patients with neuromuscular disease, to specifically address the under-covered region in typically developing patients with acetabular dysplasia. We also began to use the modified San Diego acetabuloplasty instead of the Pemberton osteotomy for acetabular dysplasia in typical DDH because we found it easier to conceptualize and teach to orthopaedic staff, residents and fellows.

This study aims to retrospectively compare early outcomes between the Pemberton osteotomy and the modified San Diego acetabuloplasty (modified San Diego) performed in children with typical DDH at our institution. In particular, we assessed clinical outcomes, pre- and postoperative radiographic outcomes, as well as complications including the presence of avascular necrosis (AVN).

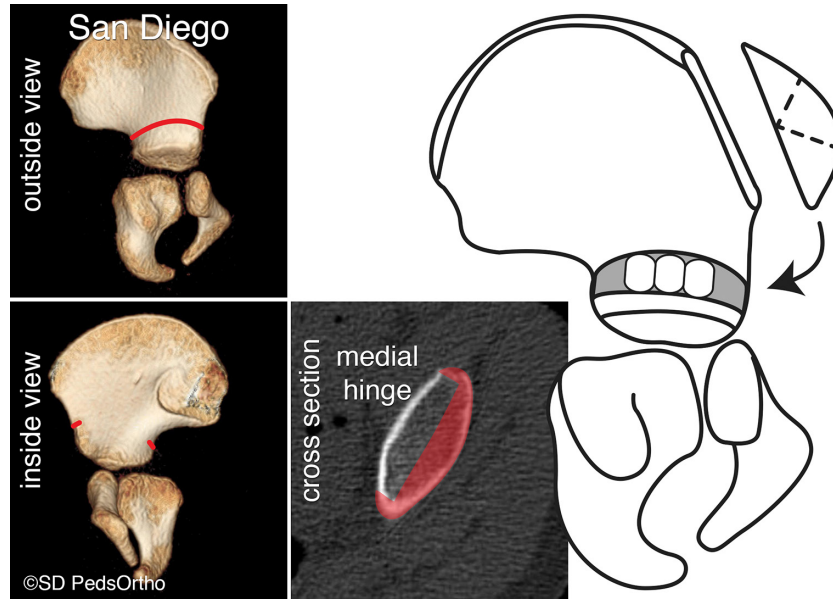


Fig. 2 Illustration of the original San Diego acetabuloplasty (designed to treat neuromuscular hip dysplasia – three equally sized triangular bone wedges are used).

Modified San Diego

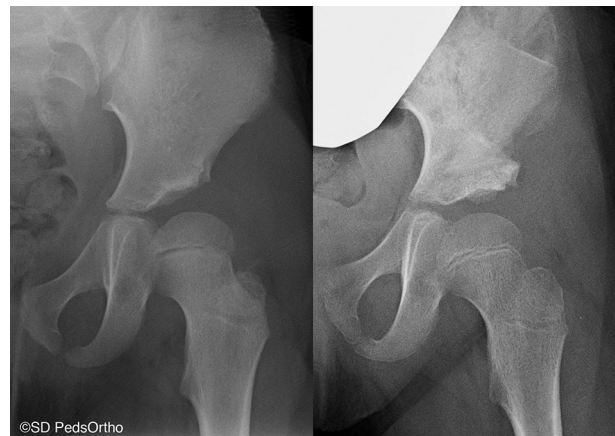
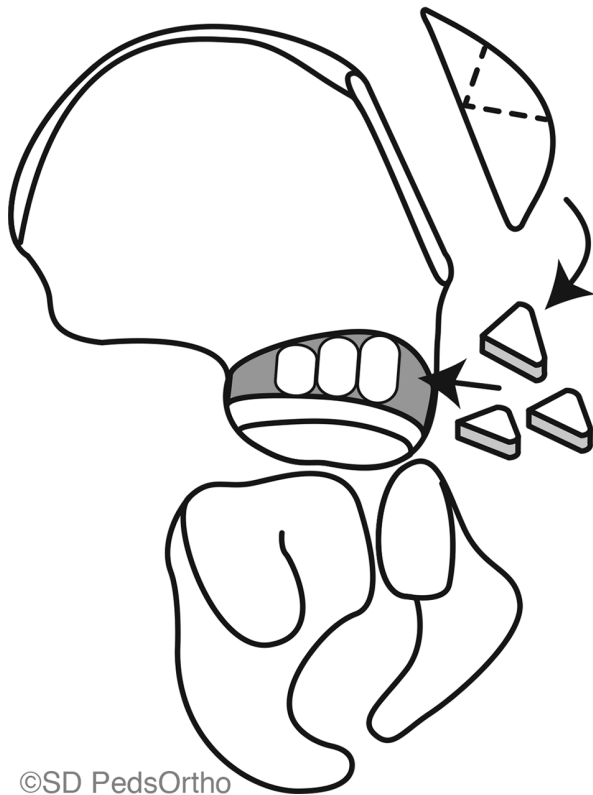


Fig. 3 (a) modified San Diego acetabuloplasty (designed to treat typical hip dysplasia with anterolateral deficiency – three unequal sized triangular bone wedges are used, with the largest wedge placed anterior to the other two); (b) pre- and postoperative radiographs of the modified San Diego acetabuloplasty in a patient with typical hip dysplasia.

Materials and methods

After obtaining institutional review board approval, we selected all patients who underwent either a Pemberton or modified San Diego osteotomy for hip dysplasia at our institution between 2006 and 2015. Hips were treated with either the Pemberton or modified San Diego based on surgeon preference. The primary indication for surgery was acetabular dysplasia, which was determined based on a variety of variables including increased acetabular index, decreased lateral centre-edge angle (LCEA), subluxation of the hip or a blunted lateral edge of the acetabulum. Four late presenting hips were dislocated at the time of initial visit and underwent a concomitant open reduction.

Patients were excluded if they had a diagnosis of neuromuscular disease, other concomitant bony procedures

in the pelvis or less than two years of follow-up. Overall, 83 hips in 59 patients met these inclusion criteria. Exclusions can be found in Figure 4. Variables studied included age at surgery, recurrent subluxation or dislocations, presence of AVN and return to the operating room. Operative reports were reviewed to identify intra-operative complications. Clinical outcome was measured by the modified McKay criteria.¹² Preoperative, postoperative and final radiographs were assessed and hips were graded using the Severin score. Retroversion was evaluated using the cross-over and ischial spine signs, and acetabular index and lateral centre-edge angle were recorded. AVN, if present, was graded using the Kalamchi and MacEwen criteria.¹³

Radiographic measurements were made using the Merge picture and archiving communication system

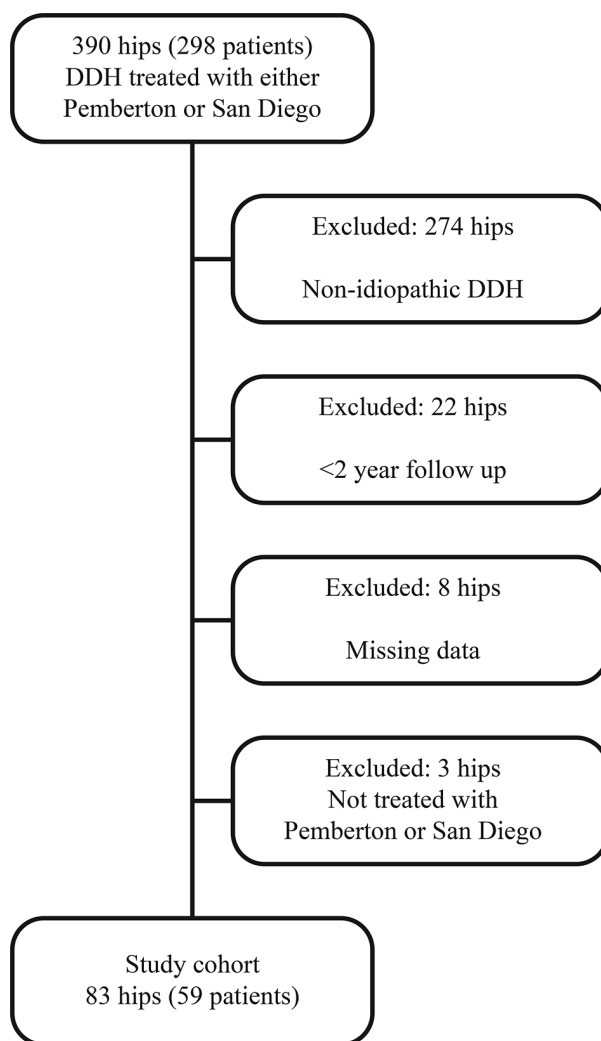


Fig. 4 Diagram of our exclusion criteria. Three patients had one hip included and the other hip excluded due to follow-up; one patient had one hip included and the contralateral hip excluded because that side was treated with a surgical procedure that was not a Pemberton acetabuloplasty or San Diego acetabuloplasty (DDH, developmental dysplasia of the hip).

(Merge Healthcare, Chicago, Illinois). The Shapiro-Wilk test of normality and Levene's test of homogeneity of variances was performed on all continuous data. Normally distributed data were analyzed with analysis of variance (ANOVA) and non-normal data were analyzed with the Mann-Whitney test. Categorical data were analyzed with the Pearson chi-squared test or Fisher's exact test. Basic descriptive statistics and odds ratios are reported. No a priori power analysis was performed. Statistical analysis was conducted using SPSS (version 25; IBM, New York, New York) with significance set at a p-value of < 0.05.

Results

Cohort description

In all, 83 hips were included in this study. A total of 55 hips were treated at one or less years of age. Three of these hips were treated with an open reduction at age one year. The remaining 52 hips were treated with a brace; eight of these failed brace treatment and required a closed or open reduction. The remaining 28 hips presented at over one year of age and had an acetabular osteotomy as their initial treatment. Additional cohort characteristics can be found in Table 1.

There were 32 patients (45 hips) in the modified San Diego group and 29 patients (38 hips) in the Pemberton

group. Two patients had a Pemberton on one hip and a modified San Diego on the contralateral hip. Average age at the time of procedure was not different between groups ($p = 0.229$). Average length of follow-up was 4.9 years (2.1 to 11.2). Four hips (two in the modified San Diego group, two in the Pemberton group) were dislocated at the time of surgery and underwent a concomitant open reduction. Three hips required a revision procedure, two were secondarily treated with a periacetabular osteotomy (PAO) and one was treated with a reverse PAO.

Clinical outcomes

No statistically significant clinical differences were observed between the two groups. In all, 53% of hips treated with the modified San Diego were found to be excellent using the modified McKay criteria, compared with 63% of hips in the Pemberton group. Mild pain was noted in nine hips at the most recent follow-up; seven of these were treated with a modified San Diego acetabuloplasty and two were treated with a Pemberton osteotomy ($p = 0.17$). There were no subsequent dislocations or subluxations in either group. Two hips (4.4%) treated with a modified San Diego procedure required a revision acetabuloplasty compared with one hip (2.6%) in the Pemberton group ($p = 0.318$). Table 2 illustrates the clinical outcomes compared between groups.

Table 1 Cohort characteristics

		San Diego (n = 45)	Pemberton (n = 38)	p-value
Age at surgery (yrs)	Mean (SD)	6.0 (2.8)	5.2 (2.1)	0.229
	Median	5.4	4.7	
	Range	1.5 to 9.9	1.9 to 12.2	
Follow-up (yrs)	Mean (SD)	4.5 (1.8)	5.4 (2.6)	0.179
	Median	4.5	4.6	
	Range	2.1 to 8.5	2.2 to 11.2	

p-values determined using Mann-Whitney test.

Table 2 Clinical outcomes of interest

		San Diego (n = 45), n (%)	Pemberton (n = 38), (%)	p-value
Modified McKay score	Excellent	24 (53)	24 (63)	0.222
	Good	8 (18)	9 (24)	
	Fair	2 (4)	0 (0)	
	Poor	7 (16)	2 (5)	
	Not enough data to compute	4 (9)	3 (8)	
Pain at follow-up		7 (16)	2 (5)	0.17
Limp at follow-up		5 (11)	1 (3)	0.212
Revision surgery		2 (4)	1 (3)	0.659

*subjects without a modified McKay score were excluded from this analysis

p-values determined using the following tests: Modified McKay, revision – Pearson Chi square; pain, limp – Fisher's exact test

Radiographic outcomes

The primary radiographic outcome was the Severin score. The proportion of hips graded good or excellent on the Severin scale were statistically similar between groups (100% in the modified San Diego *versus* 97% Pemberton; $p = 0.458$). AVN was identified in 8% of hips in the Pemberton group, and 13% of hips in the modified San Diego group ($p = 0.498$). The rate of clinically significant AVN (Kalamchi and MacEwen grade II or higher) was 3% in the Pemberton group and 0% in the modified San Diego group ($p = 0.458$). Retroversion using the cross-over sign was difficult to assess as many hips did not have a fully ossified posterior wall at final follow-up. The ischial spine sign was more reliably recognizable, and was similar between groups (18% modified San Diego *versus* 26% Pemberton; $p = 0.386$). Mean LCEA (30.2° SD 8.2° modified San Diego *versus* 33.9° SD 8.6° Pemberton; $p = 0.05$) and mean acetabular index (12.1° SD 5.9° modified San Diego *versus* 10.1° SD 4.0° Pemberton; $p = 0.141$) at follow-up were comparable. On average, acetabular index decreased by a similar amount after both procedures (17.0° SD 9.2° modified San Diego *versus* 15.2° SD 6.2° Pemberton; $p = 0.846$). Table 3 demonstrates radiographic outcomes measured and comparisons between groups.

Discussion

DDH is the most common paediatric hip disorder, and is best treated in infancy with a Pavlik harness (or other

dynamic brace) or closed/open reduction and spica casting. However, either due to delayed presentation or despite early treatment, some patients have acetabular dysplasia after two years of age.¹⁴ Three patients (four hips) in this study were treated with an acetabular osteotomy prior to age two, two hips were dislocated (International Hip Dysplasia Institute (IHDI) grade IV) and two hips were subluxated (IHDI grade II). Lalonde et al² demonstrated improved outcomes with surgical treatment of hips in this younger age group, specifically with the Pemberton osteotomy. The Pemberton osteotomy is one of the first described acetabular reshaping osteotomies in North America. Using the posterior wing of the tri-radiate cartilage as a hinge, the osteotomy increases anterolateral coverage. Additionally, as with other reshaping osteotomies, because the cut made through the pelvis is incomplete, implants to stabilize the osteotomy are not usually required.⁵ The procedure, with a single triangular bone graft, improved anterolateral coverage. Multiple recent studies have demonstrated good outcomes following the Pemberton osteotomy.¹⁵⁻¹⁸

The San Diego acetabuloplasty extends the osteotomy to the sciatic notch, thereby allowing for increased posterior coverage. With this procedure, coverage can be increased in the desired direction by varying the size and placement of the wedging iliac crest bone blocks.^{8,9,19} The San Diego acetabuloplasty was originally described for use in patients with hip dysplasia secondary to neuromuscular disease, which are typically thought to lack ade-

Table 3 Radiographic outcomes of interest

		San Diego (n = 45)	Pemberton (n = 38)	p-value
Severin score, n (%)	Excellent	39 (87)	35 (92)	0.267
	Good	6 (13)	2 (5)	
	Fair	0 (0)	1 (3)	
	Poor	0 (0)	0 (0)	
Avascular necrosis (Kalamchi and MacEwen), n (%)	None	39 (87)	35 (92)	0.402
	Grade 1	5 (11)	2 (5)	
	Grade 2	1 (2)	0 (0)	
	Grade 3	0 (0)	1 (3)	
	Grade 4	0 (0)	0 (0)	
Intact Shenton's line, n (%)		39 (87)	36 (95)	0.279
Retroversion	Cross-over sign (n = 66)	7 of 33 (21%)	8 of 33 (24%)	0.769
	Ischial spine sign (n = 75)	7 of 10 (18%)	9 of 35 (26%)	0.386
Final lateral centre-edge angle (n = 81)	Mean (SD)	30.2° (8.2°)	33.9° (8.6°)	0.05
	Range	16° to 53°	16° to 50°	
Acetabular index prior to treatment (n = 76)	Mean (SD)	27.6° (7.5°)	24.3° (5.9°)	0.161
	Range	15° to 51°	8° to 33°	
Final acetabular index (n = 59)	Mean (SD)	12.1° (5.9°)	10.1 (4.0°)	0.141
	Range	-3° to 28°	1° to 18°	

p-values determined using the following tests: Severin, AVN, Retroversion – Pearson Chi square; Shenton's line – Fisher's exact test; Final LCEA, Final AI – ANOVA; AI prior to treatment – Mann-Whitney

quate superior-posterior coverage. This is in contrast to hips with typical DDH, which were traditionally thought to primarily lack anterolateral coverage. The San Diego acetabuloplasty is similar to, and often confused with the Dega acetabuloplasty. The Dega goes through the medial and lateral cortex of the ilium stopping short of the sciatic notch while the San Diego goes primarily through the lateral cortex of the ilium and disrupts the medial and lateral cortices at only the anterior inferior iliac spine and sciatic notch. The Dega hinges down anteriorly on an intact sciatic notch and the San Diego hinges laterally through the posterior limb of the tri-radiate cartilage.

Multiple recent studies have demonstrated that the acetabular morphology in patients with typical DDH is more varied than previously thought. Even as early as 1988, Klaue et al²⁰ used axial CT cuts and found a number of patients with DDH who demonstrated primarily posterolateral undercoverage. Wenger and Kim,¹⁰ using 3D CT scans, found no cases of posterior undercoverage, but a significant proportion of patients with primarily direct lateral deficiency. Anteversion of the acetabulum also varies considerably in patients with DDH. Studies have shown similar average acetabular anteversion in normal hips and hips with DDH, with a wide range of values in both groups.^{11,21,22} This wide range of anteversion in DDH perhaps reveals why the Pemberton and other osteotomies have been thought to produce acetabular retroversion in some cases.^{23,24}

The modified San Diego osteotomy allows the surgeon to accommodate these variations in acetabular morphology in typical DDH by increasing coverage in the desired direction. Our study demonstrates comparable radiographic outcomes between the two procedures. Both groups had similar degrees of correction, and the majority were rated as excellent on the Severin scale. There was a trend towards superior clinical results in the Pemberton group due to a higher number of patients with reports of mild pain in the modified San Diego group, but this did not reach statistical significance. We did find that subjects reporting mild pain at final follow-up tended to have a higher LCEA at final follow-up. Subjects without pain had a mean LCEA of 31.1° SD 8.2° (16° TO 50°) compared with subjects that did report pain who had a mean LCEA of 39.0° SD 9.6° (25° to 53°) ($p = 0.021$). Rates of AVN were similar between groups, and lower than that recently reported in the literature²⁵. Although the Pemberton osteotomy has been suggested as producing acetabular retroversion, this was not borne out in our data.^{23,24}

Advantages to the modified San Diego for typical DDH are:

- Because many paediatric orthopaedic surgeons use the San Diego acetabuloplasty to treat dysplastic hips in cerebral palsy, they can apply that experience when

using its modified form in typical DDH.

- In rare cases, the Pemberton graft is unstable and may require fixation with a Kirschner (K)-wire. This occurred 39% of the time in our series. With the medial wall intact, the modified San Diego may be more stable and pin fixation is not needed. However, the addition of a stabilizing K-wire does not seem to affect clinical or radiographic outcomes.
- Finally, understanding the versatility of using different sized triangular grafts allows the experienced surgeon to 'customize' acetabular correction in any hip dysplasia case in which advanced imaging studies have localized the location of the most severe acetabular deficiency.

The primary limitation of this study is its retrospective nature. The choice of procedure on individual patients was entirely based on combined decision-making between the surgeon and family. Additionally, the inherent nature of chart review relies on accurate and complete documentation, which sometimes led to missing data points. All surgeries were performed at a single institution but patients were treated by five different surgeons. Differing experience and surgical skill were not accounted for in this analysis. This study is likely underpowered to find a statistically significant difference among our two groups. A *post hoc* power analysis using the observed proportion of AVN in each group demonstrated that a sample size of 1078 hips are required to have an 80% chance of detecting a difference in proportions of significant AVN between our two groups at the $p < 0.05$ level.

Advanced imaging studies allow orthopaedists to better define each patient's acetabular deficiency in 3D. With more attention being paid to the specific area of acetabular undercoverage, there is a need for acetabular procedures that can be customized to the individual hip. The modified San Diego osteotomy affords the surgeon increased flexibility in reshaping the acetabulum to address the specific deficits. Future studies are necessary to identify the patients best suited for this type of correction based on preoperative imaging, and to describe long-term outcomes from the procedure.

Received 11 January 2019; accepted after revision 22 February 2019.

COMPLIANCE WITH ETHICAL STANDARDS

FUNDING STATEMENT

This study was supported by Rady Children's Orthopedic Research and Education.

OA LICENCE TEXT

This article is distributed under the terms of the Creative Commons Attribution-Non Commercial 4.0 International (CC BY-NC 4.0) licence (<https://creativecommons.org/licenses/by-nc/4.0/>) which permits non-commercial use, reproduction and

distribution of the work without further permission provided the original work is attributed.

ETHICAL STATEMENT

Ethical approval: This study involved human participants and all procedures were performed in accordance with the ethical standards of the institutional and/or national research committee and with the 1964 Helsinki declaration and its later amendments or comparable ethical standards.

Informed consent: This study was reviewed and approved by our institutional review board who determined that formal consent was not required.

ICMJE CONFLICT OF INTEREST STATEMENT

None of the authors have conflicts of interest related to this study.

AUTHOR CONTRIBUTIONS

RB: contributed to the design of the study, data acquisition, and the drafting and critical revision of the manuscript.

JDB: contributed to data acquisition, data analysis, and the drafting and critical revision of the manuscript.

DRW: contributed to the design of the study, interpretation of data, and critical revision of the manuscript.

SJM: contributed to the design of the study, interpretation of data, and critical revision of the manuscript.

VVU: contributed to the design of the study, interpretation of data, and the drafting and critical revision of the manuscript.

REFERENCES

1. **Wenger DR, Bomar JD.** Human hip dysplasia: evolution of current treatment concepts. *J Orthop Sci* 2003;8:264-271.
2. **Lalonde FD, Frick SL, Wenger DR.** Surgical correction of residual hip dysplasia in two pediatric age-groups. *J Bone Joint Surg [Am]* 2002;84-A:1148-1156.
3. **Huang SC, Wang JH.** A comparative study of nonoperative versus operative treatment of developmental dysplasia of the hip in patients of walking age. *J Pediatr Orthop* 1997;17:181-188.
4. **Huang S-C, Wang T-M, Wu K-W, Fang C-F, Kuo KN.** Pemberton osteotomy for acetabular dysplasia. *JBJS Essent Surg Tech.* 2011;1:e2.
5. **Pemberton PA.** Pericapsular osteotomy of the ilium for treatment of congenital subluxation and dislocation of the hip. *J Bone Joint Surg [Am]* 1965;47:65-86.
6. **Kim HT, Wenger DR.** Location of acetabular deficiency and associated hip dislocation in neuromuscular hip dysplasia: three-dimensional computed tomographic analysis. *J Pediatr Orthop* 1997;17:143-151.
7. **Abel MF, Wenger DR, Mubarak SJ, Sutherland DH.** Quantitative analysis of hip dysplasia in cerebral palsy: a study of radiographs and 3-D reformatted images. *J Pediatr Orthop* 1994;14:283-289.
8. **McNerney NP, Mubarak SJ, Wenger DR.** One-stage correction of the dysplastic hip in cerebral palsy with the San Diego acetabuloplasty: results and complications in 104 hips. *J Pediatr Orthop* 2000;20:93-103.
9. **Mubarak SJ, Valencia FG, Wenger DR.** One-stage correction of the spastic dislocated hip. Use of pericapsular acetabuloplasty to improve coverage. *J Bone Joint Surg [Am]* 1992;74-A:1347-1357.
10. **Kim HT, Wenger DR.** The morphology of residual acetabular deficiency in childhood hip dysplasia: three-dimensional computed tomographic analysis. *J Pediatr Orthop* 1997;17:637-647.
11. **Kim SS, Frick SL, Wenger DR.** Anteversion of the acetabulum in developmental dysplasia of the hip: analysis with computed tomography. *J Pediatr Orthop* 1999;19:438-442.
12. **Vallamshetla VR, Mughal E, O'Hara JN.** Congenital dislocation of the hip. A re-appraisal of the upper age limit for treatment. *J Bone Joint Surg [Br]* 2006;88-B:1076-1081.
13. **Kalamchi A, MacEwen GD.** Avascular necrosis following treatment of congenital dislocation of the hip. *J Bone Joint Surg [Am]* 1980;62-A:876-888.
14. **Murphy RF, Kim YJ.** Surgical management of pediatric developmental dysplasia of the hip. *J Am Acad Orthop Surg* 2016;24:615-624.
15. **Aydin A, Kalali F, Yildiz V, et al.** The results of Pemberton's pericapsular osteotomy in patients with developmental hip dysplasia. *Acta Orthop Traumatol Turc* 2012;46:35-41.
16. **Ertürk C, Altay MA, Işikan UE.** A radiological comparison of Salter and Pemberton osteotomies to improve acetabular deformations in developmental dysplasia of the hip. *J Pediatr Orthop B* 2013;22:527-532.
17. **Wada A, Fujii T, Takamura K, et al.** Pemberton osteotomy for developmental dysplasia of the hip in older children. *J Pediatr Orthop* 2003;23:508-513.
18. **Wang C-W, Wu K-W, Wang T-M, Huang S-C, Kuo KN.** Comparison of acetabular anterior coverage after Salter osteotomy and Pemberton acetabuloplasty: a long-term followup. *Clin Orthop Relat Res* 2014;472:1001-1009.
19. **Mallet C, Ilharreborde B, Presedo A, et al.** One-stage hip reconstruction in children with cerebral palsy: long-term results at skeletal maturity. *J Child Orthop* 2014;8:221-228.
20. **Klaue K, Wallin A, Ganz R.** CT evaluation of coverage and congruency of the hip prior to osteotomy. *Clin Orthop Relat Res* 1988;232:15-25.
21. **Jia J, Zhang L, Zhao Q, Li L, Liu X.** Does medial rotational deformity of the whole pelvis universally exist in unilateral DDH? *Arch Orthop Trauma Surg* 2011;131:1383-1388.
22. **Omeroğlu H, Ağuş H, Biçimoğlu A, Tümer Y.** Analysis of a radiographic assessment method of acetabular cover in developmental dysplasia of the hip. *Arch Orthop Trauma Surg* 2002;122:334-337.
23. **Akiyama M, Nakashima Y, Oishi M, et al.** Risk factors for acetabular retroversion in developmental dysplasia of the hip: does the Pemberton osteotomy contribute? *J Orthop Sci* 2014;19:90-96.
24. **Tannast M, Pfander G, Steppacher SD, Mast JW, Ganz R.** Total acetabular retroversion following pelvic osteotomy: presentation, management, and outcome. *Hip Int* 2013;23:S14-S26.
25. **Wu K-W, Wang T-M, Huang S-C, Kuo KN, Chen CW.** Analysis of osteonecrosis following Pemberton acetabuloplasty in developmental dysplasia of the hip: long-term results. *J Bone Joint Surg [Am]* 2010;92-A:2083-2094.