



## Case Report

## A stomach like a utility room: Case report

Xiubing Chen<sup>a</sup>, Aihua Huang<sup>b</sup>, Lijian Yang<sup>b,\*</sup>, Shanyu Qin<sup>a,\*\*</sup><sup>a</sup> Department of Gastroenterology, The First Affiliated Hospital of Guangxi Medical University, Nanning, 530021, China<sup>b</sup> Department of Paediatric Surgery, The Tenth Affiliated Hospital of Guangxi Medical University, Qinzhou, 535000, China

## ARTICLE INFO

## Keywords:

Foreign bodies  
Pica  
Endoscopy  
Case report

## ABSTRACT

**Background:** Foreign body (FB) ingestion is an emergency that is more common in children and adults with mental disorders. A wide array of FBs can be ingested, and most of them do not need to be treated. However, if the FB blocks the digestive tract or causes damage, it needs to be removed by endoscopy or even surgery.

We describe here a stomach full of FBs, but these FBs did not cause serious damage.

**Case presentation:** A 9-year-old male child with mental retardation suffered abdominal pain after swallowing FBs. X-ray and computed tomography (CT) found a large number of FBs of different shapes. We tried to remove them under endoscopy but failed; we then changed to laparotomy and removed a large number of FBs. The patient started normal feeding on the 4th day and was discharged home.

**Conclusions:** FB ingestion is very common. Symptoms are used to determine whether further treatment, which is usually feasible, is required. However, for patients who cannot accurately describe the ingestion of FBs, such as children, patients with mental disorders, and patients who are inebriated, FBs should still be treated with caution, especially when the clinical symptoms and related examinations are not typical, and adequate plans should be made, as shown in this case. There may be unexpected discoveries.

## 1. Introduction

Foreign body (FB) ingestion is a common emergency that can occur at any age, but it most often occurs in children and adults with mental disorders [1]. FBs vary and can include food bones, metal and plastic parts, and hair. Most of them do not receive treatment. However, if the oesophagus or stomach is blocked, it needs to be removed by endoscopy or surgery; otherwise, the FB may cause gastrointestinal bleeding, infection, blockage, corrosive damage and even serious perforation complications [2]. Here, we describe a stomach full of FBs. However, no complications or serious injuries occurred, and the symptoms were mild.

This report is in line with the SCARE 2020 criteria [3].

## 2. Case presentation

A 9-year-old male child presented to the Paediatric Surgery Clinic due to abdominal pain after ingesting FBs for 3 days. The pain was irregular and intermittent, confined to the upper abdomen, and not serious. Eating was not obstructed, and no symptoms, such as nausea, vomiting, or bloody stool, was noted. The child's intelligence was

significantly lower than that of his peers. His grandfather suspected that the child had eaten a FB before. However, because the patient did not complain of discomfort, he did not pay attention to it. The patient has a negative history of surgery and drug allergy, and his family history was nothing special.

X-ray examination was immediately performed. In addition to a few metal objects in the stomach, several metal filaments were also found (Fig. 1a). These findings were inconsistent with what the patient's family had stated, but it was certain that the patient had no perforation of the digestive tract because mediastinal gas and pneumoperitoneum were not observed, which was consistent with the patient's mild symptoms. We tried again to determine exactly what the patient had eaten but failed. Therefore, computed tomography (CT) examination was necessary.

After the CT scan, we were slightly confused because the metal samples observed on CT images were larger and more abundant than those in X-rays, and more contents were found in the stomach (Fig. 1b). However, the patient was asked to fast the day before coming to our hospital.

Regardless, the FBs in the child's stomach had to be removed. Considering the complexity of the FBs in the stomach, the medical team

\* Corresponding author.

\*\* Corresponding author.

E-mail addresses: [chenxiubing@stu.gxmu.edu.cn](mailto:chenxiubing@stu.gxmu.edu.cn) (X. Chen), [yjxcb@163.com](mailto:yjxcb@163.com) (L. Yang).<https://doi.org/10.1016/j.amsu.2021.102979>

Received 30 September 2021; Received in revised form 18 October 2021; Accepted 28 October 2021

Available online 30 October 2021

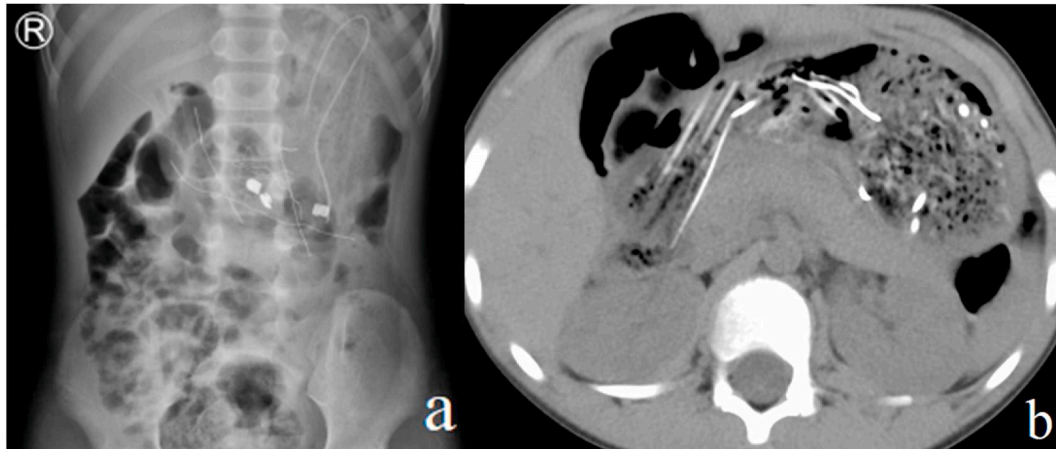
2049-0801/© 2021 The Authors. Published by Elsevier Ltd on behalf of IJS Publishing Group Ltd. This is an open access article under the CC BY-NC-ND license

<http://creativecommons.org/licenses/by-nc-nd/4.0/>.

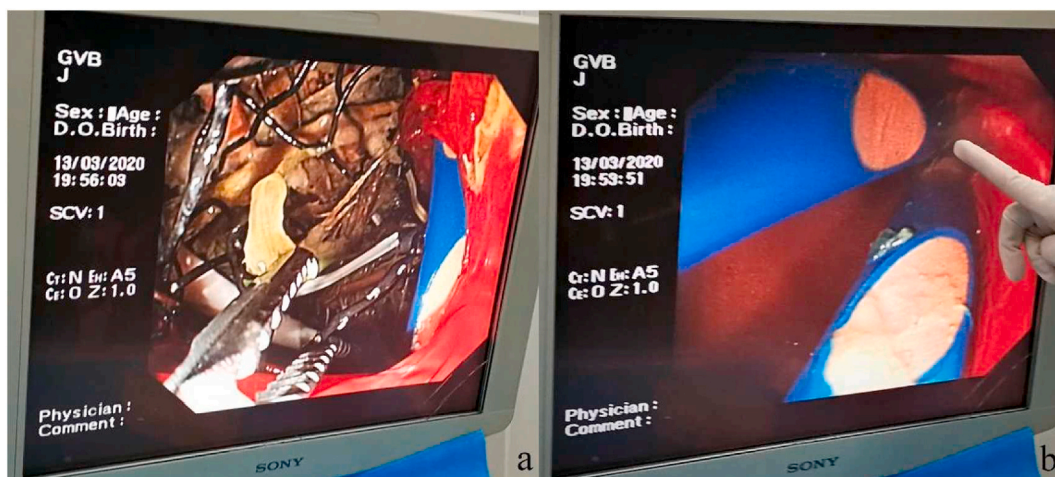**Abbreviations**

CT      Computed tomography

stomach, the pencil was removed through an incision in the stomach wall incision. Then, the stomach wall and abdominal wall were sutured layer by layer to complete the operation. Omeprazole and antibiotics were injected postoperatively, and oral intake was started on the 3rd day. The patient was discharged on the 7th day with no discomfort or complications and was recommended for psychiatric treatment. After a



**Fig. 1.** X-ray showing several metal objects in the stomach (a); CT scan showing a large number of foreign bodies with different densities mixed with some metal samples in the stomach (b).



**Fig. 2.** Gastroscopy showed a large number of foreign bodies in the stomach (a), and two pencils blocked the pylorus (b).

decided to perform gastroscopy first under anaesthesia. If the FBs could not be removed, open surgery was performed to remove the FBs. We found no FBs or injury in the oesophagus based on gastroscopy. However, a large number of FBs were found in the stomach with two pencils blocking the pylorus (Fig. 2). The two pencils were successfully removed. However, when we tried to remove the FBs in the stomach, we found that these FBs were tightly entangled and could not be removed. Therefore, we decided to perform a laparotomy at the midline of the abdomen to remove the FBs. One hour later, we removed a large number of various FBs, including pencils, toothpicks, cotton swabs, plastic tubes, plastic bags, silk threads, and wires, that weighed more than 500 g (Fig. 3). The surgical team was stunned. The surgeon explored and confirmed that there were no FBs in the stomach and intestines and was starting to suture the incision when, fortunately, we performed gastroscopy again for further confirmation. A pencil was located at the lower end of the oesophagus, which was likely squeezed up into the oesophagus during the operation. After pushing forceps into the

month, a follow-up call was made, indicating that the patient recovered well (Fig. 4).

### 3. Discussion

Children are prone to ingest FBs because most children eat FBs unconsciously, and anything that can be put in the mouth may become an FB in the digestive tract [4]. Their inability to express FBs makes them more difficult to find and diagnose in the digestive tract. Thus, these objects are typically not removed in a timely manner, which delays resolution of the condition [5]. Most FBs are removed within 24 hours, but some of them, such as button batteries and sharp or pointed FBs, must be removed in a timely manner or will cause serious damage to the digestive tract [2,6,7]. In this case, the child ingested a large number of sharp and long FBs, such as toothpicks and pencils, that did not cause serious damage. This puzzling result might be due to several factors. First, the patient swallowed soft FBs, such as plastic bags and silk

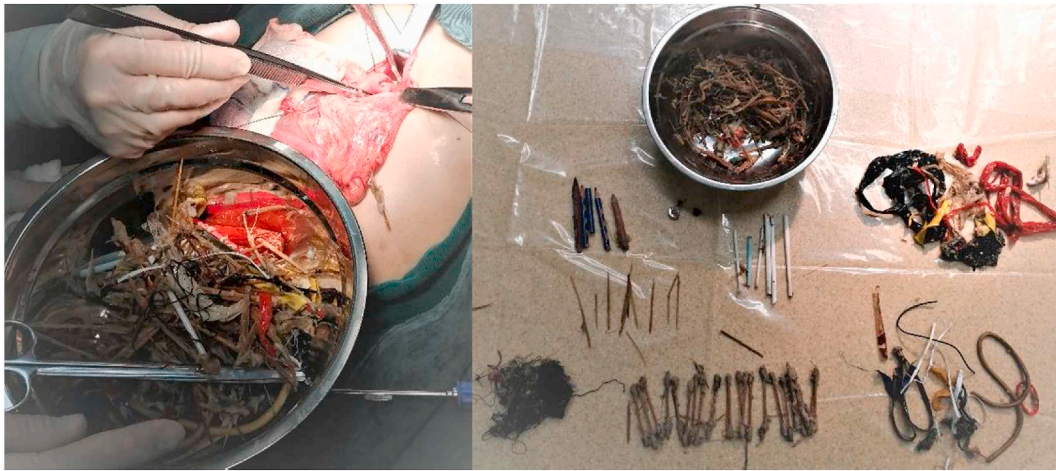

Fig. 3. Various foreign bodies removed from the stomach.

threads, at the same time. These soft FBs potentially isolated and wrapped other sharp FBs and reduced the damage to the digestive tract. Second, the patient actively swallowed FBs, and swallowing an FB by mistake caused more obvious nerve reflexes and muscle contractions. Third, children exhibit a strong ability to repair gastrointestinal mucosa.

Usually, only one FB is present in the digestive tract because its ingestion will produce a sensation throughout the throat, which will be transmitted to the nerve centre to prevent continued ingestion of FBs. In this case, the child was 9 years old and ingested numerous FBs; therefore, we consider that the child may have pica. Pica can be caused by in vivo iron deficiency, autism spectrum disorder (ASD), or intellectual disability (ID) [8,9]. The patient did not have anaemia, and his serum iron level was normal. Therefore, we recommended that the family send the child to the psychiatric department for further diagnosis and treatment to help prevent repeated instances of FB ingestion.

Studies have shown that most patients ingesting FBs do not require treatment, 10–20% require gastroscopic intervention, and <1% require surgical treatment [1]. For patients who can accurately describe the FB, it is easy to determine treatment. However, for young children and patients with special mental conditions, such as mental retardation and delirious patients, detailed guidelines are not available [10,11]. Some people advocate the use of CT instead of X-ray to identify radiolucent FBs [12] but also suggest that even if the CT scan provides limited findings, emergency gastroscopy should be performed if possible, and the patients should be prepared for laparotomy [13]. However, it is necessary to carefully consider the type of FB ingested, the patient's age, expected complications, and emergency situations [7].

Considering that gastroscopy is the simplest, quickest and most effective method for removing FBs in the upper gastrointestinal tract and is less invasive [7,14], we planned to remove the FBs using this technique. However, because the child and family members were unable to accurately express the type and quantity of FBs, we also prepared to perform laparotomy. Therefore, the operation was performed in the operating room instead of the endoscopy centre. The FBs present in the child truly exceeded our prediction and could not be completely removed without laparotomy, which is the most undesirable method.

#### 4. Conclusion

FB ingestion is very common. However, for patients who cannot accurately describe the ingestion of FBs, it is unreliable to judge the ingestion of an FB based on symptoms alone, and the patient needs to be carefully evaluated by X-ray or CT scans while making adequate treatment plans. However, regardless of which approach is taken, close follow-up and the prevention of another swallowing event is very important.

#### Ethical approval

Not applicable (The case report does not describe a medical experiment).

#### Sources of funding

There is no source of funds.

#### Author contribution

The patient was operated by YANG Lijian and Gastroscopy was performed by CHEN Xiubing. All data (and images) was collected by HUANG Aihua. CHEN Xiubing and QIN Shanyu drafted the case presentation and edited the manuscript. All authors read and approved the final manuscript.

#### Consent

Written informed consent was obtained from the patient's father for publication of this case report and accompanying images. A copy of the written consent is available for review by the Editor-in-Chief of this journal on request.

#### Registration of research studies

Not applicable (registration is not required for case reports).

1. Name of the registry:
2. Unique Identifying number or registration ID:
3. Hyperlink to your specific registration (must be publicly accessible and will be checked):

#### Guarantor

Dr. Xiubing Chen is the guarantor and principal investigator.

#### Declaration of competing interest

The author has no conflicts of interest to declare.

#### Appendix A. Supplementary data

Supplementary data to this article can be found online at <https://doi.org/10.1016/j.amsu.2021.102979>.

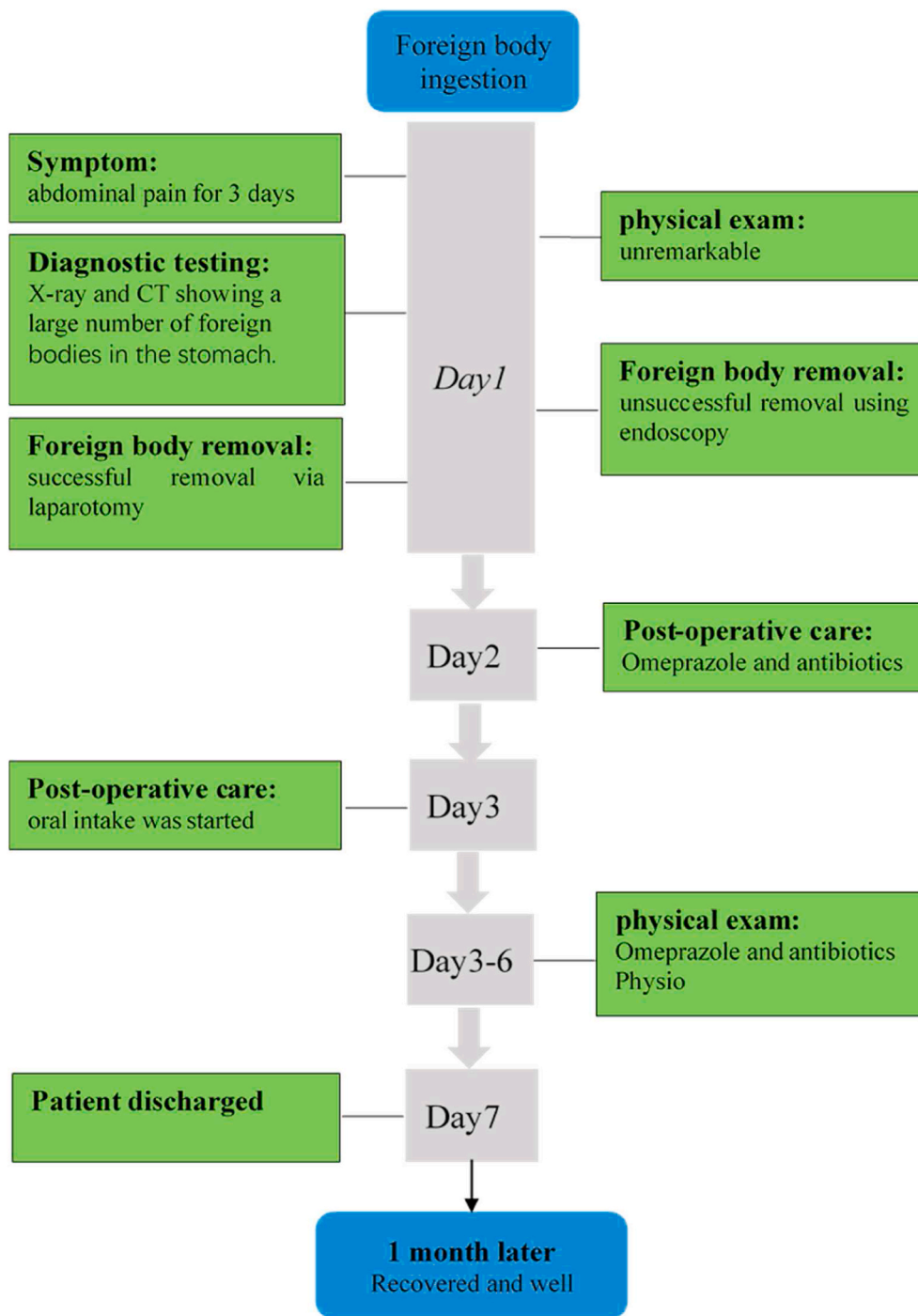


Fig. 4. Timeline.

References

- [1] X. Wang, S. Su, Y. Chen, et al., The removal of foreign body ingestion in the upper gastrointestinal tract: a retrospective study of 1,182 adult cases[J], *Ann. Transl. Med.* 9 (6) (2021) 502.
- [2] J.R. Esparaz, S.R. Carter, M.S. Mathis, et al., Esophageal foreign body management in children: can it wait?[J], *J. Laparoendosc. Adv. Surg. Tech.* 30 (12) (2020) 1286–1288.
- [3] R.A. Agha, T. Franchi, C. Sohrabi, G. Mathew, for the SCARE Group, The SCARE 2020 guideline: updating consensus surgical CAse REport (SCARE) guidelines, *Int. J. Surg.* 84 (2020) 226–230.
- [4] A.J. Speidel, L. Wolfle, B. Mayer, et al., Increase in foreign body and harmful substance ingestion and associated complications in children: a retrospective study of 1199 cases from 2005 to 2017[J], *BMC Pediatr.* 20 (1) (2020) 560.
- [5] J. Saltiel, R. Molinsky, B. Lebowitz, Predictors of outcomes in endoscopies for foreign body ingestion: a cross-sectional study[J], *Dig. Dis. Sci.* 65 (9) (2020) 2637–2643.
- [6] J. Leskova, R. Stichhauer, J. Preis, et al., Foreign body ingestion in children[J], *Rozhl Chir* 98 (9) (2019) 370–374.
- [7] J.H. Lee, Foreign body ingestion in children[J], *Clin. Endosc.* 51 (2) (2018) 129–136.
- [8] V.L. Fields, G.N. Soke, A. Reynolds, et al., Pica, autism, and other disabilities[J], *Pediatrics* 147 (2) (2021).
- [9] A.K.C. Leung, K.L. Hon, Pica: A common condition that is commonly missed - an update review, *Curr. Pediatr. Rev.* 15 (3) (2019) 164–169.
- [10] M. Birk, P. Bauerfeind, P.H. Deprez, et al., Removal of foreign bodies in the upper gastrointestinal tract in adults: European Society of Gastrointestinal Endoscopy (ESGE) Clinical Guideline, *Endoscopy* 48 (5) (2016) 489–496.
- [11] S. Oliva, C. Romano, P. De Angelis, et al., Foreign body and caustic ingestions in children: a clinical practice guideline, *Dig. Liver Dis.* 52 (11) (2020) 1266–1281.

- [12] J. Takahashi, Shigat, H. Funakoshi, Oesophageal coins invisible on chest radiography: a case report, *Int. J. Emerg. Med.* 10 (1) (2017) 27.
- [13] K. Ziaja, J. Chudek, A. Chlubek, et al., Esophagogastric polyurethane bezoar complicated by stomach wall microperforation and acute peritonitis: case report, *BMC Surg.* 20 (1) (2020) 281. Published 2020 Nov 12.
- [14] D. Libanio, M. Garrido, F. Jacome, et al., Foreign body ingestion and food impaction in adults: better to scope than to wait[J], *United European Gastroenterol. J.* 6 (7) (2018) 974–980.