

Spontaneous Pneumomediastinum with Concurrent Pneumorrhachis

Hanna Jung, M.D., Sang Cjeol Lee, M.D., Deok Heon Lee, M.D., Gun-Jik Kim, M.D.

Spontaneous pneumomediastinum is a very uncommon entity that is defined as the presence of free air in the mediastinum without an obvious etiology. The presence of air in the spinal canal, known as concurrent pneumorrhachis, is an extremely rare epiphenomenon of spontaneous pneumomediastinum. We report a rare case of spontaneous pneumomediastinum with pneumorrhachis associated with influenza. The patient was diagnosed without invasive procedures, was managed with supportive treatment, and recovered without any complications.

Key words: 1. Mediastinum
2. Mediastinal emphysema
3. Pneumorrhachis

CASE REPORT

A 17-year-old adolescent male patient visited a primary care clinic for cough, sputum, and chills. Medication was administered, and he was discharged that night. The next day, he returned to the hospital with intractable cough, fever, and pleuritic left chest pain. He was referred to emergency Department of Kyungpook National University Hospital for suspected pneumonia. His initial vital signs were as follows: blood pressure, 120/60 mmHg; pulse rate, 92 beats/min; body temperature, 38.3°C; and respiration rate, 36 breaths/min. He was alert and cooperative on physical examination without any neurological deficits. He had a history of asthma, but was not asthmatic at presentation. In addition, he had not experienced any traumatic injuries. There were no abnormal laboratory findings except for a C-reactive protein level of 4.94 mg/dL. Chest radiography revealed pneumomediastinum with a slight pneumonic infiltration in the left lower lung

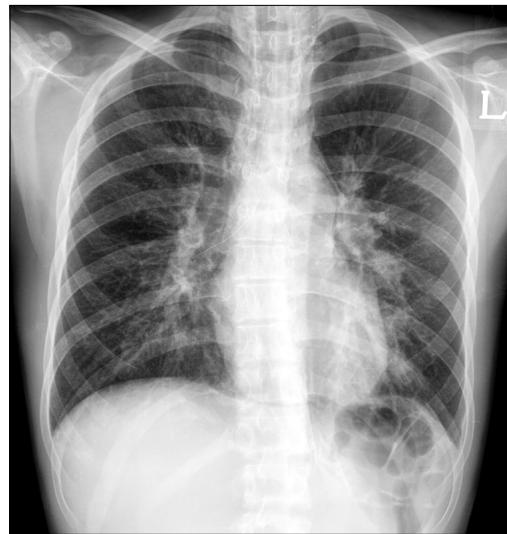


Fig. 1. Chest radiograph revealing air streaks in the mediastinum.

Department of Thoracic and Cardiovascular Surgery, Kyungpook National University Hospital, Kyungpook National University School of Medicine
Received: January 21, 2014, Revised: June 24, 2014, Accepted: June 25, 2014, Published online: December 5, 2014

Corresponding author: Sang Cjeol Lee, Department of Thoracic and Cardiovascular Surgery, Kyungpook National University Hospital, Kyungpook National University School of Medicine, 130 Dongdeok-ro, Jung-gu, Daegu 700-721, Korea
(Tel) 82-53-200-5665 (Fax) 82-53-426-4765 (E-mail) sfelee@hanmail.net

© The Korean Society for Thoracic and Cardiovascular Surgery. 2014. All right reserved.

© This is an open access article distributed under the terms of the Creative Commons Attribution Non-Commercial License (<http://creativecommons.org/licenses/by-nc/3.0>) which permits unrestricted non-commercial use, distribution, and reproduction in any medium, provided the original work is properly cited.

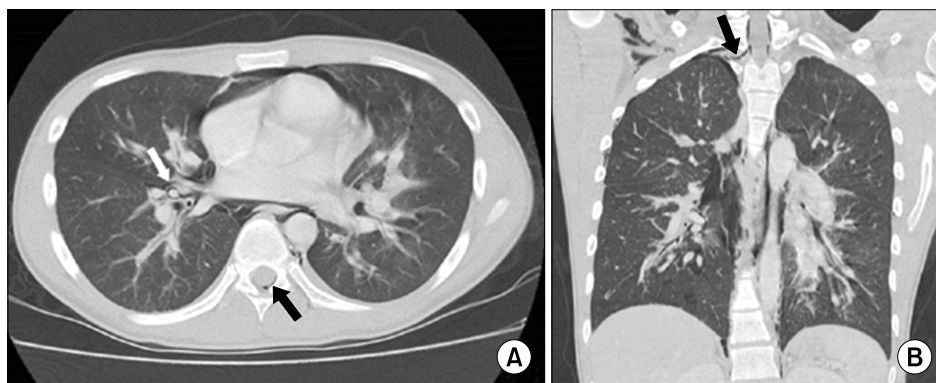


Fig. 2. Computed tomography of the chest confirming pneumomediastinum with concurrent pneumorrhachis. (A) Computed tomography of the chest demonstrating air dissection along the bronchovascular sheath (white arrow) and the presence of air in the dorsum of the spinal canal (black arrow). (B) Coronal view of the computed tomography image showing air entering the spinal canal through the neural foramen (arrow) combined with right pneumothorax and subcutaneous emphysema.

field (Fig. 1). Subsequent computed tomography of the chest confirmed the pneumomediastinum and identified concurrent pneumorrhachis (Fig. 2). The patient's initial treatment was supportive care including no oral intake, antibiotics, antipyretics, and fluid therapy. Three days after admission, an esophagography was performed and revealed no injury to the digestive organs; thus, the patient was permitted to begin oral intake. He was eventually diagnosed with influenza by serology and an antiviral agent was administered. Thereafter, his symptoms improved, and his pneumomediastinum and pneumorrhachis simultaneously resolved. The patient was discharged on the seventh day of hospitalization, and he appeared well without sequelae in the outpatient clinic one week later.

DISCUSSION

Spontaneous pneumomediastinum (SPM) is defined as the presence of free air in the mediastinum without an apparent cause. This infrequent condition has been reported to occur in 1 in 30,000 emergency department referrals [1]. The combination of SPM and the presence of intraspinal air, known as pneumorrhachis, is an extremely rare presentation, and only a few reports of the concomitant occurrence of SPM and pneumorrhachis have previously been published [2-4].

SPM is associated with clinical circumstances in which the transalveolar pressure gradient increases abruptly, and is usu-

ally triggered by a Valsalva maneuver, violent coughing, or intense physical exertion. The leaked air from the ruptured alveoli dissects through the bronchovascular sheath to the hilum and then extends along fascial planes [5]. Further migration from the posterior mediastinum may result in the air passing through the neural foramina and entering the epidural space [6]. In the present case, pneumomediastinum coincided with pneumothorax, subcutaneous emphysema, and pneumorrhachis in the cervical and thoracic regions. This pattern is highly exceptional but still possible because air freely passes between body compartments along fascial planes (Fig. 2).

The clinical presentation of SPM is largely benign and self-limiting. The two most common presenting symptoms are chest pain and dyspnea. Computed tomography of the chest is considered the gold standard for diagnosing SPM [5]. When the possibility of aerodigestive tract perforation is a concern, a barium swallow, esophagoscopy, or bronchoscopy can be performed in highly suspicious cases. However, the routine use of such invasive procedures is no longer recommended. The management of patients with SPM consists mainly of conservative measures including rest, analgesics, and close observation. The utility of antibiotics, oxygen therapy, and restriction of oral intake is debatable.

Pneumorrhachis, which is also known as intraspinal pneumocele, epidural pneumatosis, or spinal emphysema, is usually an asymptomatic radiologic finding [6]. In trauma victims, it may be a marker of spinal fracture or hidden severe

injuries, but non-traumatic or spontaneous pneumorrhachis has a favorable clinical outcome, resolving spontaneously when the underlying etiology is controlled. The most reliable diagnostic tool for pneumorrhachis is computed tomography of the spine. However, owing to its rarity and asymptomatic nature, targeted evaluation for early detection is difficult, although symptomatic pneumorrhachis has been reported [7]. Spontaneous pneumorrhachis is not harmful per se and does not require a specific medication or intervention, but a spine specialist should be consulted to evaluate the patient's neurological status and rule out any associated concealed pathologies.

In our patient, SPM accompanied by pneumorrhachis was associated with influenza. The patient was diagnosed without invasive procedures, and supportive care was successfully administered.

CONFLICT OF INTEREST

No potential conflict of interest relevant to this article was reported.

REFERENCES

1. Newcomb AE, Clarke CP. *Spontaneous pneumomediastinum: a benign curiosity or a significant problem?* Chest 2005;128:3298-302.
2. Carolan PL, Wright SL, Jha V. *Spontaneous pneumorrhachis.* Pediatr Emerg Care 2013;29:508-9.
3. Karaoglan A, Cal MA, Orki A, Arpaozu BM, Colak A. *Pneumorrhachis associated with bronchial asthma, subcutaneous emphysema and pneumomediastinum.* Turk Neurosurg 2011;21:666-8.
4. Manden PK, Siddiqui AH. *Pneumorrhachis, pneumomediastinum, pneumopericardium and subcutaneous emphysema as complications of bronchial asthma.* Ann Thorac Med 2009;4:143-5.
5. Macia I, Moya J, Ramos R, et al. *Spontaneous pneumomediastinum: 41 cases.* Eur J Cardiothorac Surg 2007;31:1110-4.
6. Oertel MF, Korinth MC, Reinges MH, Krings T, Terbeck S, Gilsbach JM. *Pathogenesis, diagnosis and management of pneumorrhachis.* Eur Spine J 2006;15 Suppl 5:636-43.
7. Park JS, Kim H, Lee SW, Min JH, Kim SW, Lee KW. *Symptomatic pneumorrhachis after chest tube insertion for spontaneous pneumothorax.* Am J Emerg Med 2010;28:846.e1-2.