

Treatment of Intractable Pneumothorax with Emphysema Using Endobronchial Watanabe Spigots

Doo Yun Lee, M.D.¹, Yu Rim Shin, M.D.¹, Jee Won Suh, M.D.¹, Seok Jin Haam, M.D.¹,
Yoon Soo Chang, M.D.², Yoichi Watanabe, M.D.³

Prolonged air leakage is a major cause of morbidity in pneumothorax. When conservative management is not effective, surgery should be performed. However, surgery is not appropriate in patients with low pulmonary function. In these patients, occlusion of the airway with endobronchial blockers may be attempted under bronchoscopy. We treated two patients with prolonged air leakage using endobronchial Watanabe spigots under fibrobronchoscopy.

Key words: 1. Pneumothorax
2. Pulmonary emphysema
3. Endoscopy

CASE REPORT 1

A 53-year-old male patient underwent closed thoracostomy due to left pneumothorax at an outside hospital. Due to prolonged air leakage, he was transferred to Gangnam Severance Hospital for further evaluation and management. Chest computed tomography (CT) demonstrated diffuse lung emphysema with large bullae in both upper lobes and the superior segments of both lower lobes (Fig. 1). A pulmonary function test (PFT) revealed a forced vital capacity (FVC) of 2.69 L (69% of the normal range), a forced expiratory volume in one second (FEV₁) of 1.65 L (56% of the normal range), a FEV₁/FVC of 61%, and a diffusion capacity of the lung for carbon monoxide (DLCO) of 11.1 mL/mmHg/min (57% of the normal range). Arterial blood gas analysis showed a pH of 7.438, PO₂ of 59.4 mmHg, and PCO₂ of 33.2 mmHg in room air.

We concluded that a wedge resection of the ruptured bullae under general anesthesia would be a risky management option due to the patient's severe emphysema. Therefore, he underwent endobronchial occlusion with endobronchial Watanabe spigots (EWS; Novatech, Grasse, France) in the affected left subsegmental bronchi under fibrobronchoscopy.

Air leakage ceased on the second day after insertion of the EWS. The chest tube was removed on the fourth day after air leakage ceased. He was discharged in good condition one day after removal of the chest tube and was followed up in Gangnam Severance Hospital outpatient clinic. The patient had no pneumothorax during a follow-up period of 7 months.

CASE REPORT 2

A 66-year-old male patient underwent closed thoracostomy due to a right pneumothorax at an outside hospital; however,

Departments of ¹Thoracic and Cardiovascular Surgery and ²Internal Medicine, Gangnam Severance Hospital, Yonsei University College of Medicine, ³Department of Pulmonary Disease, Japanese Red Cross Okayama Hospital

Received: October 12, 2012, Revised: December 13, 2012, Accepted: December 18, 2012

Corresponding author: Doo Yun Lee, Department of Thoracic and Cardiovascular Surgery, Gangnam Severance Hospital, Yonsei University College of Medicine, 211 Eonju-ro, Gangnam-gu, Seoul 135-720, Korea
(Tel) 82-2-2019-3380 (Fax) 82-2-3461-8282 (E-mail) dylee@yuhs.ac

© The Korean Society for Thoracic and Cardiovascular Surgery. 2013. All right reserved.

© This is an open access article distributed under the terms of the Creative Commons Attribution Non-Commercial License (<http://creativecommons.org/licenses/by-nc/3.0>) which permits unrestricted non-commercial use, distribution, and reproduction in any medium, provided the original work is properly cited.

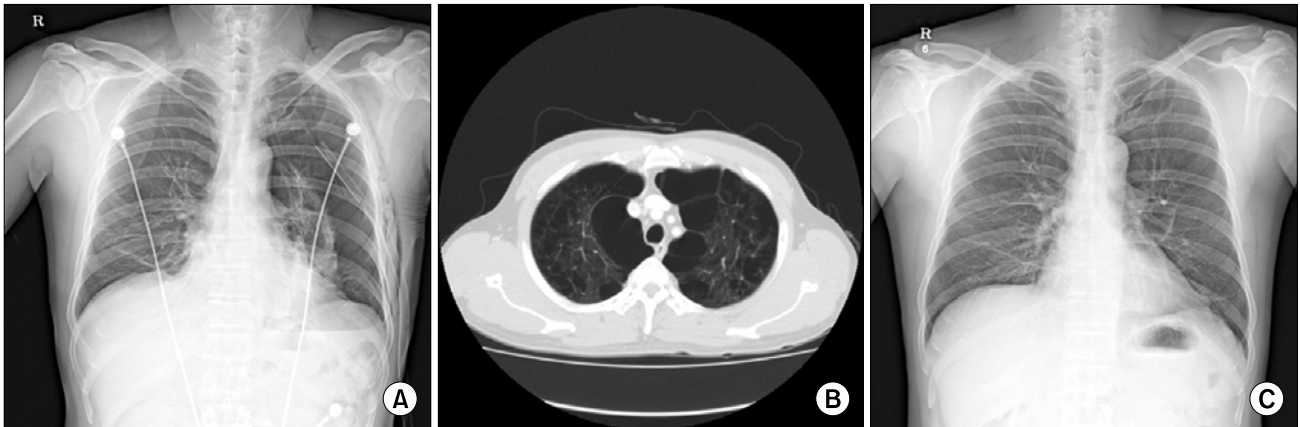


Fig. 1. (A) Chest X-ray on admission demonstrated a left pneumothorax in spite of chest tube insertion. (B) Diffuse lung emphysema with multiple bullae in both upper lobes was seen on chest computed tomography on admission. (C) After insertion of the endobronchial Watanabe spigot, air leakage stopped and the pneumothorax improved.

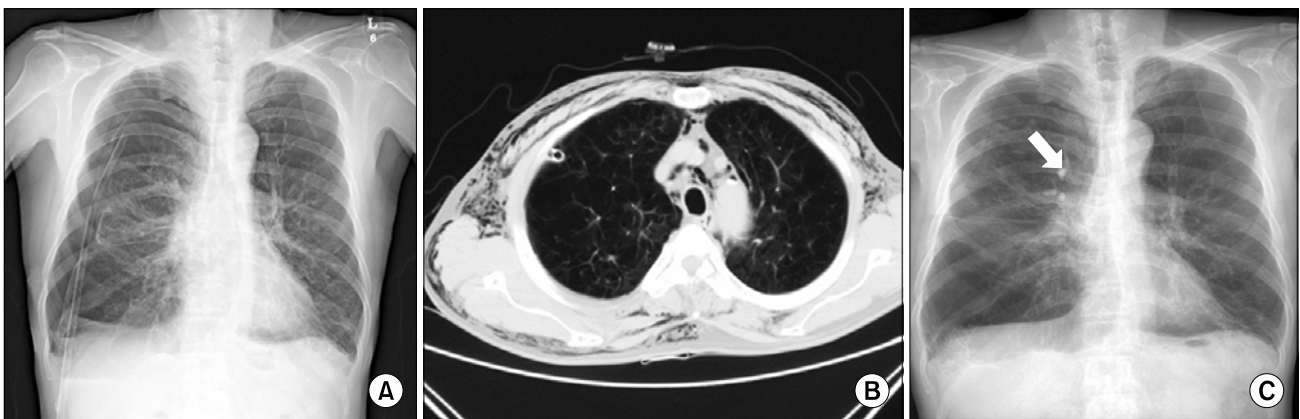


Fig. 2. (A) A right pneumothorax was seen on admission chest X-ray. (B) Chest computed tomography revealed diffuse emphysema in both lungs. (C) The right pneumothorax was successfully treated, but the emphysema in the right lower lungs remained on chest X-ray after endobronchial Watanabe spigot (EWS) insertion. The arrow indicates the inserted EWS.

air leakage continued for more than 30 days. He was then transferred to Gangnam Severance Hospital for further evaluation and management. A chest X-ray and CT revealed diffuse lung emphysema and bullous change of the bilateral lungs, pneumomediastinum, and subcutaneous emphysema (Fig. 2). PFT demonstrated a FVC of 2.24 L (60% of the normal range), a FEV₁ of 0.75 L (29% of the normal range), a FEV₁/FVC of 33%, and a DLCO of 8.2 mL/mmHg/min (54% of the normal range). Arterial blood gas analysis showed a pH of 7.439, PO₂ of 91.8 mmHg, and PCO₂ of 32.2 mmHg in room air.

The patient's status was thought to be unsuitable for wedge

resection under general anesthesia due to poor pulmonary function. Therefore, he was treated with EWS into the apical anterior and posterior segmental bronchi under fibrobronchoscopy.

The EWS dislodged spontaneously on the first day after the procedure, necessitating EWS reinsertion. The EWS was successfully reinserted to the apical segmental bronchi of the right upper lobe, but the EWS could not be inserted into the posterior segmental bronchi of the right upper lobe due to mucosal bleeding and severe coughing during the bronchoscopic procedure. However, air leakage stopped 2 days after EWS reinsertion. The chest tube was removed on the 4th day

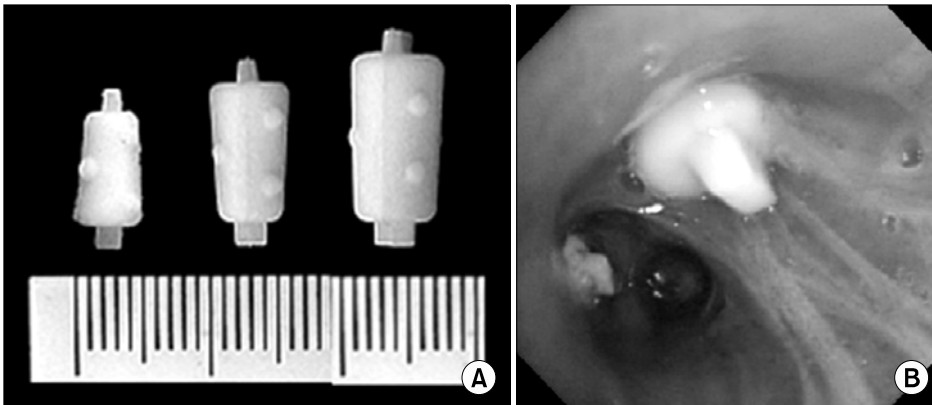


Fig. 3. (A) The endobronchial Watanabe spigot (EWS) is made of high quality silicone. It comes in three diameters: 5, 6, and 7 mm. Because the EWS is spigot-shaped and has studs on the surface, it may not migrate easily. (B) EWSs have been inserted into the segmental bronchus under bronchoscopy.

after reinsertion of the EWS.

The patient was discharged without complications and was followed. PFT on the fifteenth day after reinsertion of the EWS demonstrated improved pulmonary function as follows: a FVC of 2.90 L (78%), a FEV₁ of 1.06 L (41%), a FEV₁/FVC of 37%, and a DLCO of 6.5 mL/ mmHg/min (43%). There was no recurrence of pneumothorax during a follow-up period of 5 months. The patient will be on the list for lung transplantation in the near future.

DISCUSSION

Pneumothorax with prolonged air leakage is a major cause of morbidity and reduces quality of life. Usually, a pneumothorax is curable with chest tube insertion; however, additional treatments, such as pleurodesis, may be required in intractable cases. If conservative management does not successfully treat pneumothorax, surgery, such as a wedge resection, should be performed [1]. However, surgical treatment may not be appropriate in patients with low pulmonary function. In these patients, occlusion of the airway with endobronchial blockers may be attempted under fibrobronchoscopy. Metallic coils [2], endobronchial stents [3], and valves [4] are used as blockers.

Watanabe developed an endobronchial blocker, the endobronchial Watanabe spigot, and reported occlusion of the bronchus using EWS in patients with intractable pneumothorax, pyothorax with bronchial fistula, pulmonary fistula, bronchial fistula, or bronchobiliary fistula [5]. The EWS has an advantage in that it can easily be inserted or removed

without specific instruments under bronchoscopy (Fig. 3B). In the current cases, we confirmed that bronchial occlusion with EWS is an effective treatment option for secondary pneumothorax associated with severe pulmonary emphysema in patients with low pulmonary function.

The most common complication of EWS insertion is migration, which occurred in one of the current cases. To prevent migration, an EWS should be inserted as firmly as possible. Proper medications and patient education to reduce coughing are also required. Three sizes of EWS are available, and a properly sized EWS should be selected to help prevent migration (Fig. 3A). Another complication is atelectasis, which can be treated by removal of the EWS [6].

There is controversy as to whether the EWS should be inserted temporarily or permanently. Because permanent insertion may lead to infection, such as a lung abscess, temporary insertion would be preferable in patients with a current lung infection or risk factors that predispose them to infection.

The balloon occlusion test can be used for the selection of target bronchi. After a Swan-Ganz or Fogarty catheter is positioned into the suspected bronchi, the balloon is insufflated. An EWS can then be inserted into the bronchi if air leakage stops when the target bronchi is occluded. In our cases, we did not perform the balloon occlusion test. Instead, we predicted the suspicious segment using chest CT, and inserted the EWS into the target bronchi. If there was no air leakage when the patients coughed several times, we concluded that the EWS was inserted into the proper bronchi.

Although air leakage did not stop immediately after occlu-

sion, reduction in air leakage aids in the healing of bronchopleural fistula. In the present cases, air leakage stopped on the second day after the procedures. We concluded that bronchial occlusion with the EWS is a useful and safe treatment for cases of intractable pneumothorax with severe emphysema and poor pulmonary function.

CONFLICT OF INTEREST

No potential conflict of interest relevant to this article was reported.

REFERENCES

1. Puskas JD, Mathisen DJ, Grillo HC, Wain JC, Wright CD, Moncure AC. *Treatment strategies for bronchopleural fistula.* J Thorac Cardiovasc Surg 1995;109:989-95.
2. Ponn RB, D'Agostino RS, Stern H, Westcott JL. *Treatment of peripheral bronchopleural fistulas with endobronchial occlusion coils.* Ann Thorac Surg 1993;56:1343-7.
3. Singh SS, Pyragius MD, Shah PJ, Stubberfield J, Jurisevic CA, Chalooob S. *Management of a large bronchopleural fistula using a tracheobronchial stent.* Heart Lung Circ 2007; 16:57-9.
4. Travaline JM, McKenna RJ Jr, De Giacomo T, et al. *Treatment of persistent pulmonary air leaks using endobronchial valves.* Chest 2009;136:355-60.
5. Watanabe Y, Matsuo K, Tamaoki A, Hiraki S, Moriyama S. *Bronchial embolization using an endobronchial Watanabe spigot for intractable pneumothorax and bronchial fistula.* J Jpn Soc Bronchol 2001;23:510-5.
6. Sasada S, Tamura K, Chang YS, et al. *Clinical evaluation of endoscopic bronchial occlusion with silicone spigots for the management of persistent pulmonary air leaks.* Intern Med 2011;50:1169-73.