



Case report

Descemet Membrane Endothelial Keratoplasty for corneal decompensation due to migrating metallic intracorneal foreign bodies in an aphakic eye following a 39-year-old blast injury: A case report

Sina Elahi^a, Alain Saad^{a,b,*}, Damien Gatinel^a^a Fondation Ophtalmologique Adolphe de Rothschild, Rue Manin, Paris, France^b American University of Beirut - Medical Center Beirut, Lebanon

ARTICLE INFO

Keywords:

Descemet membrane endothelial keratoplasty
DMEK
IOFB
Foreign body
Aphakia
Vitrectomy

ABSTRACT

Purpose: To report the use of Descemet Membrane Endothelial Keratoplasty (DMEK) for secondary surgical removal of intraocular foreign bodies (IOFB) years after the trauma as migration occurred through the endothelium, damaging the endothelium, and causing corneal edema.

Observations: We report the case of a blast injury in 1972, that led to left eye traumatic cataract managed with vitrectomy and lensectomy. Although thorough removal was attempted, some corneal and conjunctival foreign bodies remained.

Despite aphakia, the patient maintained acceptable best corrected visual acuity (BCVA) (0.30 LogMAR) but >30 years later, experienced visual deterioration. IOFB protruding through the Descemet membrane (DM) were seen, with extensive edema. Descemet Membrane Endothelial Keratoplasty was performed in an attempt to treat the endothelium and remove the foreign bodies protruding through the DM. The procedure was done uneventfully under sulfur hexafluoride gas (SF₆) and the patient improved. Four years after the surgery, BCVA was 0.63, however, 6 years later, a new episode of migrating intracorneal foreign bodies with corneal edema reduced BCVA to 0.40. The decision was made to observe the patient, and delay a second DMEK.

Conclusions and importance: Corneal decompensation caused by IOFB breaching the Descemet membrane can safely be managed with a DMEK. DMEK is feasible even in complex cases and should be attempted due to its lower risk of graft rejection and likely benefits, while saving the option of more aggressive transplantation techniques, such as penetrating keratoplasty, in cases of failure.

1. Introduction

When possible, an intracorneal foreign body should be immediately removed to prevent further injuries, inflammation, or even infection, but after the immediate period, it has been well documented that foreign material remnants may remain for years without causing any complications.¹ Secondary surgical removal years after the original trauma might be performed when complications such as edema, inflammation, astigmatism, or corneal opacities occur, due to the migration of the intracorneal foreign body.²⁻⁴ Closed-globe blast injuries are poorly documented but studies reported corneal and ocular surface involvement in up to 25% with Descemet Membrane (DM) rupture in 6 out of 65 eyes, accompanied by endothelial cell loss.^{5,6} If the damage to the cornea and DM is extensive, endothelial cell loss may lead to corneal

decompensation warranting corneal transplant. We report the case of a blast injury resulting in multiple intracorneal foreign bodies and secondary corneal decompensation after migration through the Descemet membrane 39 years after the trauma, successfully treated with Descemet Membrane Endothelial Keratoplasty.

2. Case report

A 63-year-old male patient with blast injury caused by an explosive mine in 1972 suffered from right eye exenteration and left eye traumatic cataract. At the time, the left eye underwent vitrectomy and lensectomy, and was later diagnosed with glaucoma treated by topical betablockers. Despite left eye aphakia, the patient maintained acceptable best corrected visual acuity (BCVA) (0.30 LogMAR). In the recent years, the

* Corresponding author. Rothschild Foundation, Paris, France.

E-mail address: dralainsaad@gmail.com (A. Saad).

<https://doi.org/10.1016/j.ajoc.2021.101162>

Received 20 November 2020; Received in revised form 6 April 2021; Accepted 5 July 2021

Available online 9 July 2021

2451-9936/© 2021 The Authors.

Published by Elsevier Inc.

This is an open access article under the CC BY-NC-ND license

(<http://creativecommons.org/licenses/by-nc-nd/4.0/>).

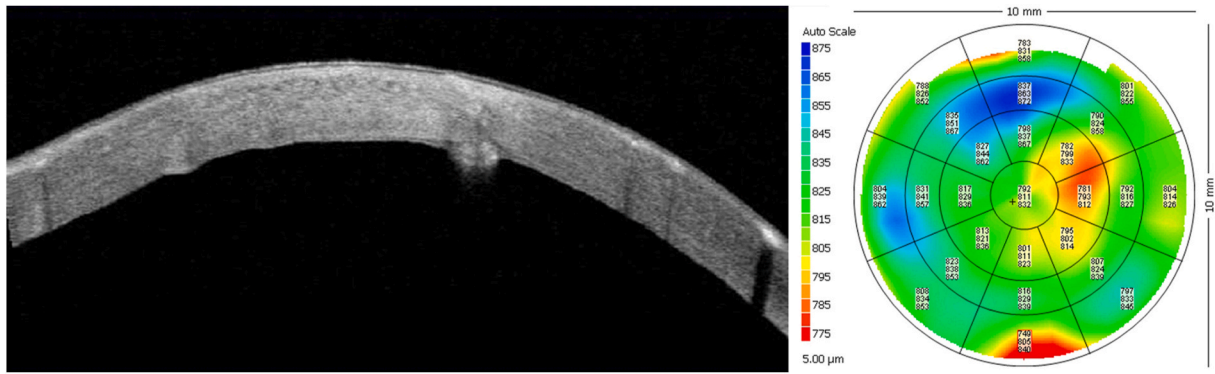


Fig. 1. Preoperative investigations. Corneal OCT and pachymetry map demonstrating diffuse edema, with transdecemetic foreign bodies protruding into the anterior chamber.

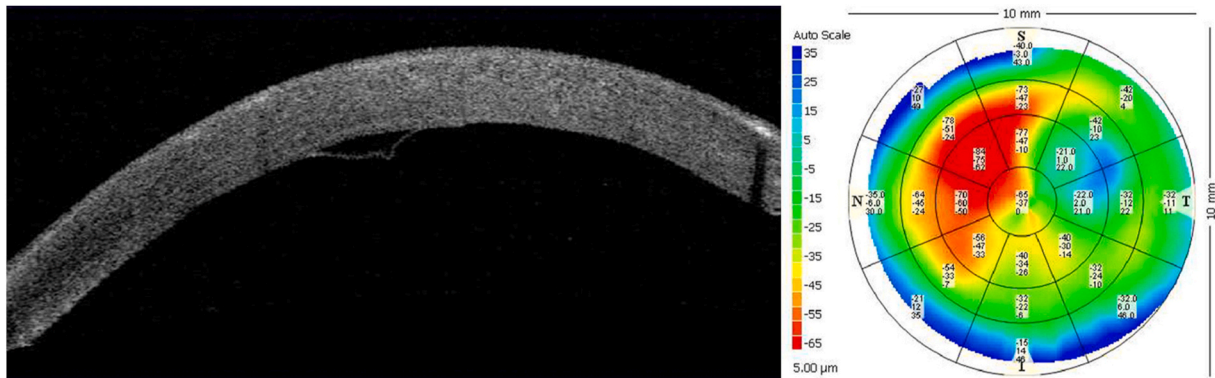


Fig. 2. Day one after DMEK surgery. Uneventful DMEK surgery with an apposed graft and already diminished corneal thickness. DMEK: Descemet Membrane Endothelial Keratoplasty.

patient was experiencing left eye visual deterioration, which was worse in the morning, attributed to corneal edema, and was referred to our tertiary center for second opinion, 39 years after the initial blast injury.

At presentation, left eye BCVA was 0.90 LogMAR (+2.50, -2.75 at 150°) with an intraocular pressure (IOP) of 14 mmHg. On slit-lamp examination, multiple (about 20) inframillimetric intracorneal (ICFB) and intraconjunctival foreign bodies were seen, with corneal decompensation and edema. In the anterior chamber, remnants of vitreous were noted. Gonioscopy did not reveal any angle foreign bodies. Detailed examination of the rest of the eye was not possible due to poor

visibility and transparency, gross fundus examination seemed to exclude important posterior segment pathologies. B-Ultrasound ruled out retinal pathologies, including detachment. The patient wore a prosthesis in the right eye.

Investigations at presentation are displayed in Fig. 1 and revealed extensive corneal edema with central corneal thickness (CCT) at 832 μm (Visante®, Zeiss), and intracorneal foreign bodies protruding through the DM at various levels on corneal optical coherence topography (OCT, Visante®, Zeiss). No preoperative endothelial cell count was obtainable due to the massive corneal edema.

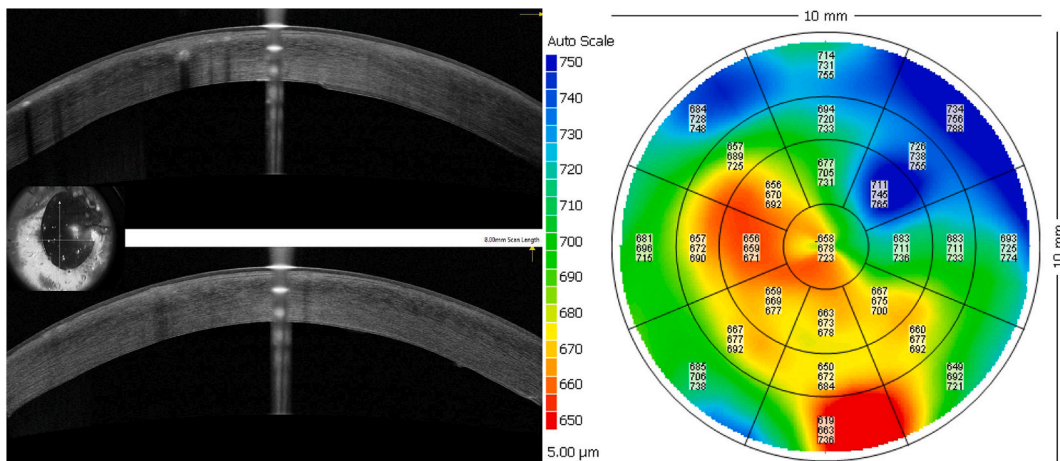


Fig. 3a. Year 4 after DMEK surgery. Successful DMEK at year 4 with excellent results both on corneal OCT showing good graft apposition, and on pachymetry maps showing corneal edema resolution.

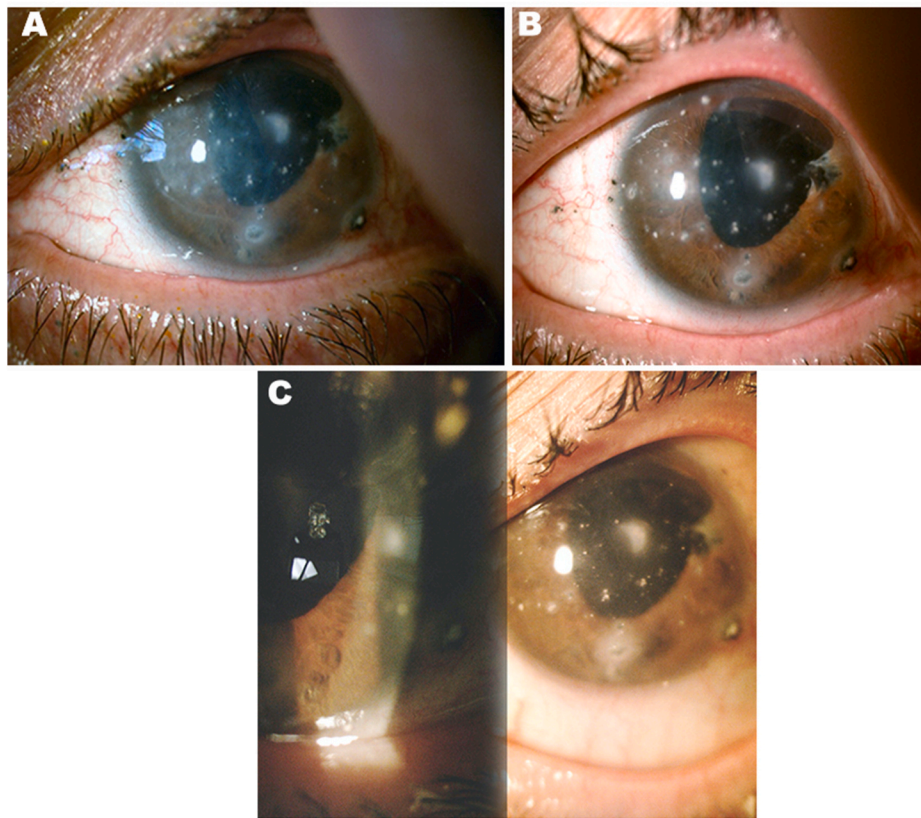


Fig. 3b. Intracorneal and intraconjunctival foreign bodies preoperatively (A-upper left), one year (B – upper right), and 4 years after surgery (C - below). Persisting foreign bodies which will likely keep migrating in the coming years.

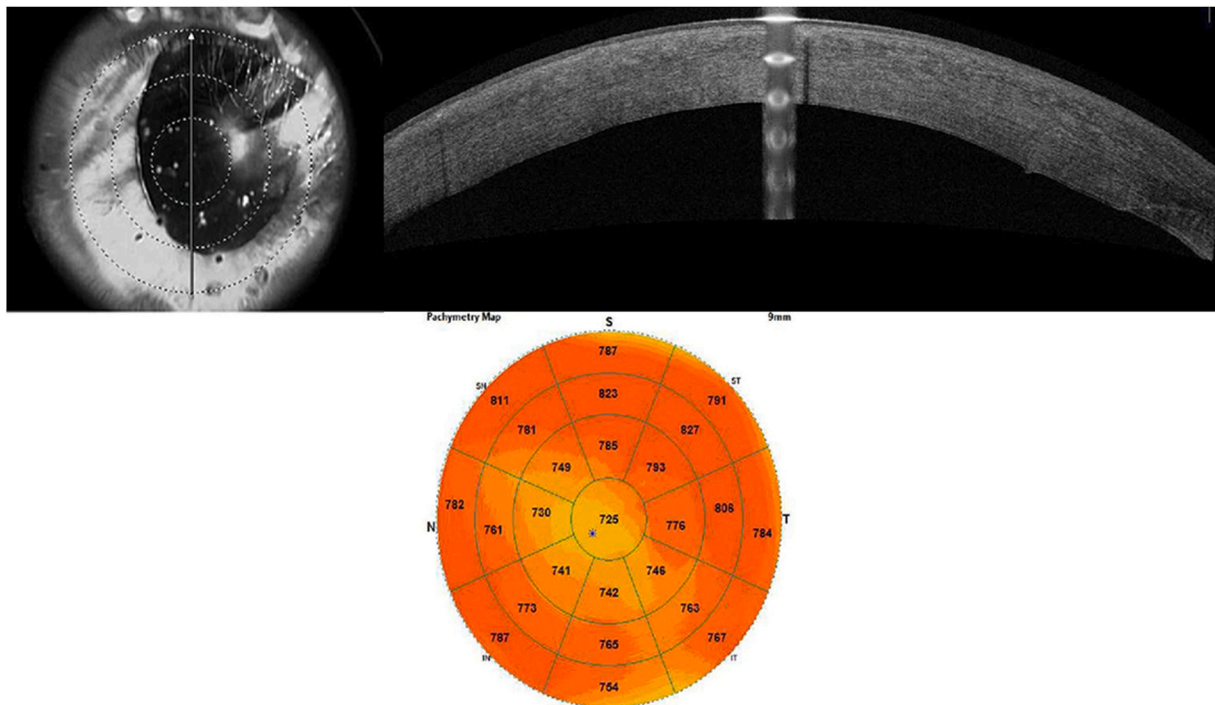


Fig. 4. Last follow-up 6 years after surgery.

The decision was taken to perform a Descemet Membrane Endothelial Keratoplasty (DMEK) in an attempt to treat the endothelial decompensation, and remove the foreign bodies protruding through the

DM.

The procedure was done uneventfully as previously described,^{7,8} and was performed with sulfur hexafluoride gas (SF6). The foreign bodies

were mainly of metallic origin with other hardly defined material, probably ceramic. Only the ones easily accessible during the surgery were removed, no attempts were done to remove the deep intrastromal ones. On day one (Fig. 2), the DM was correctly apposed with an IOP of 12. The patient was prescribed topical corticoid medication (4/day), and antibiotics (4/day) (for one week only) and corneal transparency was achieved at the 3-weeks-follow-up, where BCVA improved to 0.40 LogMAR (+3.00, -0.50 at 120°). Postoperative pachymetry and corneal OCTs showed gradual CCT diminution reduced to $645\ \mu\text{m}$. The patient was referred back to their primary ophthalmologist for the routine follow-ups.

Four years after surgery the patient was on twice-daily fluorometholone, with a BCVA of 0.63 (+2.75, -1.25 at 110°), an IOP of 16.0 mmHg and an apposed graft. Intracorneal foreign bodies remained on slit-lamp examination (Fig. 3b). CCT was estimated at $623\ \mu\text{m}$ (Fig. 3a).

At the latest follow-up, 6 years after the DMEK, treatment included topical betablockers and once-daily fluorometholone, and BCVA was reduced to 0.40 LogMAR (+2.50, -1.25 at 110°). Examination showed a mild corneal edema and CCT was increased to $725\ \mu\text{m}$ probably in the context of migrating intracorneal foreign bodies. As the BCVA remained acceptable and satisfactory, the decision was made to observe the patient, in an attempt to delay a second DMEK in the coming years (Fig. 4).

3. Discussion

Studies reported the use of various techniques to remove intracorneal foreign bodies such as femtosecond laser,⁹ corneal pockets¹⁰ or lamellar keratoplasty.¹¹ However, this case is to the best of the authors' knowledge, the first to describe migrating intracorneal foreign bodies through the DM, causing corneal decompensation, warranting a DMEK both as an endothelial keratoplasty as well as a mean for access and surgical removal of the foreign bodies.^{12,13} Studies analysing blast-related ocular injuries reported about 70% corneal involvement with 0.8% requiring corneal transplantation, most likely penetrating keratoplasties.^{14,15}

The BCVA prior to corneal decompensation was 0.30 LogMAR and the patient noted drastic improvement of his vision after surgery, which has lasted for 6 years. It is likely that, due to the constant migration of the multiple foreign bodies and resulting DM's breach, the patient may need further surgeries and even DMEKs. Indeed, in our case, there seemed to be a discrete but progressive deterioration starting at year 4. This case however shows that DMEK is possible in cases of intracorneal foreign bodies both as a treatment option, and as a mean to access and remove foreign bodies.

Of note, as intracorneal foreign bodies are known to constantly migrate anteriorly or posteriorly,^{4,16} heroic attempts to remove deeply encapsulated ones should be reserved for complications such as infections or important vision loss. In this case, only the ones directly approaching the corneal epithelium or endothelium and believed to cause visual impairment due to optical aberrations, edema, or loss of transparency, were removed. Following the same logic of minimizing risks in this aphakic monocular eye with a history of retinal tear, vitrectomy, glaucoma, and corneal edema, no attempts were made to implant a secondary IOL and the eye was left aphakic. The refractive status was close enough to plano despite the aphakia.

The feasibility of DMEK in aphakic and previously vitrectomized eyes, has been seldom described. In these eyes, the lack of a stable iris-lens diaphragm and vitreous humour creates anatomical instability of the anterior chamber and technical challenges especially during the touchless manipulation of the graft in the anterior chamber. Moreover, the surgery can be complicated by a posterior dislocation of the graft, or an inability to form an effective air or gas tamponade.¹⁷ Reports of DMEK in aphakic and vitrectomized eyes included the use of air,¹⁸ challenging double-bubble techniques¹⁹ or techniques involving temporary posterior pseudo-barriers created by donor's stromal tissue.^{17,20}

C-Press technique was also described for vitrectomized eyes but should be used with caution in the context of aphakia.²¹ These various techniques developed for complex cases of DMEK are neither comparable between each other, nor are they sufficiently studied yet to help evaluate any superiority among them, the choice should be left to the appreciation of each surgeon. A DSAEK (Descemet Stripping Automated Endothelial Keratoplasty) with a thicker stroma could have helped also this patient, probably providing a more robust barrier to further migration to the endothelium. However this would have been at the cost of increased rejection risk and decreased visual potential. There is sufficient evidence to suggest DMEK is feasible even in complex cases and should be attempted due to its lower risk of graft rejection and likely benefits, while saving the option of more aggressive transplantation techniques, such as penetrating keratoplasty, in cases of failure.

4. Conclusion

Corneal decompensation caused by intraocular foreign bodies breaching the Descemet membrane can safely be managed with a DMEK. DMEK is feasible even in complex cases and should be attempted due to its lower risk of graft rejection and likely benefits, while saving the option of more aggressive transplantation techniques, such as penetrating keratoplasty, in cases of failure.

Corneal subclinical edema is noted despite apposed graft. Observation is offered but a second DMEK might be needed.

Patient consent

Consent to publish the case report was not necessary as it does not contain any personal identifying information.

Funding

No funding or grant support.

Authorship

All authors attest that they meet the current ICMJE criteria for Authorship.

Declaration of competing interest

Saad A: Consultant Zeiss, Nidek, Baush and Lomb, Gatinel D: Consultant Physiol, Nidek, Baush and Lomb, The following authors have no financial disclosures: Elahi S.

Acknowledgements

None.

References

- Covert DJ, Henry CR, Sheth BP. Well-tolerated intracorneal wood foreign body of 40-year duration. *Cornea*. 2009;28(5):597–598. <https://doi.org/10.1097/ICO.0b013e3181901e1f>.
- Ray S, Friberg TA, Beatty RR, Loewenstein J. Late posterior migration of glass intraocular foreign bodies. *Arch Ophthalmol*. 2004;122(6):923–926. <https://doi.org/10.1001/archophth.122.6.923>.
- Bhaduri G, Ghosh A. Vegetative intraocular foreign body of 25 years' duration. *Indian J Ophthalmol*. 2003;51(2):184–185.
- Saar I, Raniel J, Neumann E. Recurrent corneal oedema following late migration of intraocular glass. *Br J Ophthalmol*. 1991;75(3):188–189. <https://doi.org/10.1136/bjo.75.3.188>.
- Cockerham GC, Lemke S, Rice TA, et al. Closed-globe injuries of the ocular surface associated with combat blast exposure. *Ophthalmology*. 2014;121(11):2165–2172. <https://doi.org/10.1016/j.ophtha.2014.06.009>.
- Alam M, Iqbal M, Khan A, Khan SA. Ocular injuries in blast victims. *J Pakistan Med Assoc*. 2012;62(2):138–142.

7. Saad A, Guilbert E, Grise-Dulac A, Sabatier P, Gatinel D. Intraoperative OCT-assisted DMEK: 14 consecutive cases. *Cornea*. 2015;34(7):802–807. <https://doi.org/10.1097/ICO.0000000000000462>.
8. Pierné K, Panthier C, Courtin R, et al. Descemet membrane endothelial keratoplasty after failed penetrating keratoplasty. *Cornea*. 2019;38(3):280–284. <https://doi.org/10.1097/ICO.0000000000001834>.
9. Qin YJ, Zeng J, Lin HL, et al. Femtosecond laser-assisted removal of an intracorneal chestnut, a case report. *BMC Ophthalmol*. 2018;18(1):210. <https://doi.org/10.1186/s12886-018-0875-2>.
10. Au YK, Libby C, Patel JS. Removal of a corneal foreign body through a lamellar corneal pocket. *Ophthalmic Surg Laser*. 1996;27(6):471–472.
11. Taneja M, Rathi VM, Bagga B. One-stage femtolaser-assisted lamellar keratoplasty and foreign body removal. *Optom Vis Sci*. 2015;92(2):e42–45. <https://doi.org/10.1097/OPX.0000000000000469>.
12. Davis-Boozer D, Terry M, Straiko M, Talajic J, Alqudah A, Greiner M. How close are we to achieving emmetropia?. *DSAEK & DMEK Triples Invest Ophthalmol Vis Sci*. 2013;54(15):3081–3081.
13. Stuart AJ, Romano V, Virgili G, Shortt AJ. Descemet's membrane endothelial keratoplasty (DMEK) versus Descemet's stripping automated endothelial keratoplasty (DSAEK) for corneal endothelial failure. *Cochrane Database Syst Rev*. 2018;6:CD012097. <https://doi.org/10.1002/14651858.CD012097.pub2>.
14. Kong Y, Tang X, Kong B, Jiang H, Chen Y. Six-year clinical study of firework-related eye injuries in North China. *Postgrad Med*. 2015;91(1071):26–29. <https://doi.org/10.1136/postgradmedj-2014-132837>.
15. Sorrentino S, Marsella LT, Feola A, Marino V, Billi B. Penetrating ocular trauma with retained intraocular foreign body: management, follow-up and medico-legal evaluation. *W Indian Med J*. 2015;65(2):391–394. <https://doi.org/10.7727/wimj.2014.142>.
16. Jastaneiah SS. Long-term corneal complication of retained anterior chamber-angle foreign body. *Saudi J Ophthalmol*. 2010;24(3):105–108. <https://doi.org/10.1016/j.sjopt.2010.04.002>.
17. Karadag R, Aykut V, Esen F, Oguz H, Demirok A. Descemet's membrane endothelial keratoplasty in aphakic and vitrectomized eye. *GMS Ophthalmol Cases*. 2020;10. <https://doi.org/10.3205/oc000129>.
18. Ozmen MC, Ozdemir E. Descemet membrane endothelial keratoplasty in an aphakic vitrectomized eye with a large iris defect. *JCRS Online Case Rep*. 2018;6(1):1–3. <https://doi.org/10.1016/j.jcro.2017.10.003>.
19. Hayashi T, Kobayashi A. Double-bubble technique in Descemet membrane endothelial keratoplasty for vitrectomized eyes: a Caseseries. *Cornea*. 2018;37(9):1185–1188. <https://doi.org/10.1097/ICO.0000000000001606>.
20. Woo JH, Htoon HM, Tan D. Hybrid Descemet Membrane Endothelial Keratoplasty (H-DMEK): results of a donor insertion pull-through technique using donor stroma as carrier. Published online January *Br J Ophthalmol*. 2020;16. <https://doi.org/10.1136/bjophthalmol-2019-314932>.
21. Saad A, Awwad ST, El Salloukh NA, Panthier C, Bashur Z, Gatinel D. C-press technique to facilitate Descemet membrane endothelial keratoplasty surgery in vitrectomized patients: a case series. *Cornea*. 2019;38(9):1198–1201. <https://doi.org/10.1097/ICO.0000000000002024>.