



Case Report

The new onset of dysphagia four years after anterior cervical discectomy and fusion: Case report and literature review

Darius Ansari^{1,2}, Halle E. K. Burley^{1,3}, Alexander von Glinski^{1,4,5,6}, Christopher Elia^{4,7}, Jens R. Chapman⁴, Rod J. Oskouian^{1,4}

¹Seattle Science Foundation, Seattle, Washington, ⁴Swedish Medical Center, Swedish Neuroscience Institute, ⁶Hansjörg Wyss Hip and Pelvic Center, Swedish Hospital, Seattle, Washington, ²Department of Medicine, University of Illinois College of Medicine, Chicago, Illinois, ³Department of Medicine, Western University of Health Sciences College of Osteopathic Medicine of the Pacific-Northwest, Lebanon, Oregon, ⁷Riverside University Health System Medical Center, Moreno Valley, California, United States, ⁵Department of Trauma Surgery, BG University Hospital Bergmannsheil, Ruhr University Bochum, Bochum, Germany.

E-mail: *Darius Ansari - dansari2@uic.edu; Halle E. K. Burley - halle.burley@westernu.edu; Alexander von Glinski - alexandervonglinski@icloud.com; Christopher Elia - eliachr1@gmail.com; Jens R. Chapman - jens.chapman@swedish.org; Rod J. Oskouian - rod.oskouian@swedish.org



*Corresponding author:

Darius Ansari,
Seattle Science Foundation,
550 17th Avenue, Suite 600,
Seattle, Washington, United States.
dansari2@uic.edu

Received : 02 February 20
Accepted : 13 February 20
Published : 28 February 20

DOI
10.25259/SNI_46_2020

Videos available on:
www.surgicalneurologyint.com

Quick Response Code:



ABSTRACT

Background: Dysphagia is a common complication immediately following anterior cervical spine surgery. However, its onset more than 1-year postoperatively is rare.

Case Description: A 45-year-old male initially underwent a C3-4 and C5-6 anterior cervical discectomy and fusion (ACDF). At age 49, 4 years later, he presented with worsening dysphagia accompanied by neck and right upper extremity pain. Radiographs demonstrated an extruded left C3 screw, which had migrated into the prevertebral soft tissues at the C4-C5 level; there was also loosening of the right C3 screw. The subsequent barium swallow study revealed that the screw was embedded in the pharyngeal wall. The patient required a two-stage operation; first, to remove the anterior instrumentation, and second, to perform a posterior instrumented C2-T2 fusion.

Conclusion: A barium swallow study and other dynamic imaging are a valuable component of the diagnostic workup and therapeutic intervention to evaluate the delayed onset dysphagia following an ACDF.

Keywords: Anterior cervical discectomy and fusion, Complications, Delayed onset dysphagia, Hardware failure

INTRODUCTION

Anterior cervical discectomy and fusions (ACDF) complications, include dysphagia (most common), followed by recurrent laryngeal nerve injury, Horner syndrome, esophageal perforation, infection, and graft extrusion. The prevalence of dysphagia 1–6 weeks postoperatively ranges from 28% to 57%.^[1] Although the majority of symptoms resolve spontaneously, some complaints may last up to two postoperative years.^[1]

Here, we present the new-onset dysphagia in a 49-year-old male, 4 years following a 2-level C3-C4/C5-C6 ACDF. Symptoms were attributed to a left C3 screw extrusion into the posterior pharyngeal soft tissue with the loosening of the right C3 screw. The patient required anterior resection of instrumentation followed by a posterior C2T2 fusion. The point of this study was to highlight that the new-onset dysphagia occurring even years after an ACDF should be carefully

This is an open-access article distributed under the terms of the Creative Commons Attribution-Non Commercial-Share Alike 4.0 License, which allows others to remix, tweak, and build upon the work non-commercially, as long as the author is credited and the new creations are licensed under the identical terms.

©2020 Published by Scientific Scholar on behalf of Surgical Neurology International

evaluated for instrumentation failure (e.g., perforation of the pharyngeal wall).

CASE REPORT

At age 45, the patient with a history of renal insufficiency, had a C3-4 and C5-6 ACDF. Four years later, he prior presented with neck/right upper extremity pain, and worsening dysphagia. The physical exam revealed 3/5 deltoid strength on the right side, but was otherwise unremarkable.

Diagnostic studies

Lateral radiographs of the cervical spine revealed an extruded left C3 screw, which had migrated into the prevertebral soft tissues at the C4-5 level, as well as loosening of the right C3 screw [Figure 1]. A barium swallow confirmed screw migration superiorly with swallowing, indicating it was embedded in the posterior soft tissue of the pharyngeal wall [Video 1].

Surgery

With the help of an otolaryngologist ear, nose, and throat specialist, the left C3 screw was removed from within the left lateral pharyngeal wall; scar tissue on the posterior aspect of the screw pocket was opened, and the inflammatory capsule surrounding it was excised without evidence of esophageal perforation. Next, the spine surgeons removed the anterior instrumentation (e.g., plate C3-C4/C5-C6), followed by placement of a new interbody structural allograft at C4-5 with a new plate, and posteriorly, and instrumented fusion from C2-T2. The patient was discharged without complaints.

DISCUSSION

Following anterior-approach cervical operations, many patients experience some degree of dysphagia, which is almost always self-limiting and may take up to 2 years to resolve.^[4,6,7] It usually appears 2–7 days after surgery but may begin up to a month after surgery in 8–25% of patients;

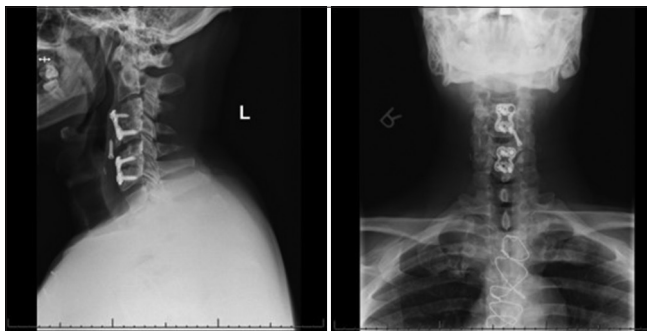


Figure 1: Lateral (left) and anterior-posterior (right) X-ray views reveal an extruded left C3 screw within the prevertebral tissue.

estimates of the incidence of dysphagia in the literature range from 3.6% to 83%.^[5,8]

To assess dysphagia, dynamic imaging studies include modified barium swallow study and fiberoptic endoscopic evaluation of swallowing.

Delayed-onset dysphagia may be variously attributed to: mass effect exerted on the posterior laryngeal wall by an abscess, delayed instrumentation failure with pharyngeal versus esophageal defect,^[2] Fryer *et al.* recently reported a case of hardware failure post-ACDF associated with dysphagia;^[3] our case had clear ventral screw migration.

Radiographic recommendations to evaluate delayed onset dysphagia

We recommend preoperative dynamic imaging and intraoperative fluoroscopy for all cases of delayed postoperative dysphagia, especially those with potential for or known screw migration/instrumentation failure. A multidisciplinary approach with an otolaryngologist may be valuable to ensure safe instrumentation mobilization and removal, as well as to prepare for a possible esophageal repair.^[2]

CONCLUSION

Anterior cervical instrumentation failure should be considered when patients who previously underwent an ACDF newly present with dysphagia months to years later; the preoperative workup should include X-rays, magnetic resonance imaging, computed tomography, and videofluoroscopic swallowing studies.

Declaration of patient consent

The authors certify that they have obtained all appropriate patient consent.

Financial support and sponsorship

Nil.

Conflicts of interest

There are no conflicts of interest.

REFERENCES

1. Anderson KK, Arnold PM. Oropharyngeal dysphagia after anterior cervical spine surgery: A review. *Global Spine J* 2013;3:273-86.
2. Christiano LD, Goldstein IM. Late prevertebral abscess after anterior cervical fusion. *Spine (Phila Pa 1976)* 2011;36:E798-802.
3. Fryer C, Tan HE, Bakmeedeniya R, Friedland PL. Late-onset

dysphagia from hardware migration after anterior cervical discectomy and fusion: An unusual cause and review of literature. *Clin Med Insights Ear Nose Throat* 2019;12:1179550619881131.

4. Lee MJ, Bazaz R, Furey CG, Yoo J. Risk factors for dysphagia after anterior cervical spine surgery: A two-year prospective cohort study. *Spine J* 2007;7:141-7.
5. Min Y, Kim WS, Kang SS, Choi JM, Yeom JS, Paik NJ. Incidence of dysphagia and serial videofluoroscopic swallow study findings after anterior cervical discectomy and fusion: A prospective study. *Clin Spine Surg* 2016;29:E177-81.
6. Smith-Hammond CA, New KC, Pietrobon R, Curtis DJ, Scharver CH, Turner DA. Prospective analysis of incidence and risk factors of dysphagia in spine surgery patients: Comparison

of anterior cervical, posterior cervical, and lumbar procedures. *Spine (Phila Pa 1976)* 2004;29:1441-6.

7. Vanderveldt HS, Young MF. The evaluation of dysphagia after anterior cervical spine surgery: A case report. *Dysphagia* 2003;18:301-4.
8. Winslow CP, Winslow TJ, Wax MK. Dysphonia and dysphagia following the anterior approach to the cervical spine. *Arch Otolaryngol Head Neck Surg* 2001;127:51-5.

How to cite this article: Ansari D, Burley HE, von Glinski A, Elia C, Chapman JR, Oskouian RJ. The new onset of dysphagia four years after anterior cervical discectomy and fusion: Case report and literature review. *Surg Neurol Int* 2020;11:32.