

## CASE REPORT

# A diffuse large B-cell thyroid lymphoma presented as a compressive goiter in a young woman with no evidence of Hashimoto's thyroiditis

Ibtissem Oueslati  | Hiba-Allah Chatti | Meriem Yazidi  | Fatma Chaker | Melika Chihaoui

Department of Endocrinology, La Rabta University Hospital, Faculty of Medicine, University of Tunis El Manar, Tunis, Tunisia

## Correspondence

Ibtissem Oueslati, Rue Jbel Lakhdar, La Rabta Jebbari 1007, Tunis, Tunisia.  
Email: ouesibtissem@gmail.com

## Abstract

Thyroid lymphoma should be suspected in case of rapid enlargement of the thyroid gland even in a young patient with no history of Hashimoto thyroiditis. The confirmation is based on histopathology and immunohistochemistry.

## KEYWORDS

compressive goiter, Hashimoto's thyroiditis, hypothyroidism, immunohistochemistry, thyroid lymphoma

## 1 | INTRODUCTION

Thyroid cancer represents the most common endocrine malignancy.<sup>1</sup> Its prevalence varies between 5% and 15%.<sup>2</sup> Papillary thyroid carcinoma is the most common form of thyroid cancer. Thyroid lymphoma is a rare histological form with a prevalence of 1%–5% of all thyroid cancers and 2% of extranodal lymphomas. It tends to affect elderly patients with a long history of Hashimoto thyroiditis.<sup>3</sup> The diagnosis and the treatment of thyroid lymphoma are challenging.

Herein, we report the case of a thyroid lymphoma revealed by a rapidly compressive goiter in a young woman with no evidence of Hashimoto's thyroiditis.

## 2 | PRESENTATION OF CASE

A 22-year-old woman presented with suddenly rapid enlargement of a cervical mass with compressive symptoms. Her past medical history was unremarkable. There was no history of radiation exposure or tobacco smoking and no family history of thyroid cancer. She was complaining of dysphagia

for solids, dyspnea, hoarseness, hot flashes, sweating, and weight loss for the last 20 days.

On physical examination, she had a normal body temperature, a body weight of 44 kg, a body mass index of 17.8 kg/m<sup>2</sup>, a blood pressure of 100/60 mmHg, a regular pulse of 85 beats/min, and a respiratory rate of 24 breaths/min. Cervical examination revealed a voluminous, plunging, heterogeneous, firm, and painless goiter with a bilateral jugular turgescence. Other systemic and regional examinations did not show any abnormalities.

The results of biological investigations are shown in Table 1. The thyroid function tests disclosed subclinical hypothyroidism. Thyroid peroxidase antibodies were negative.

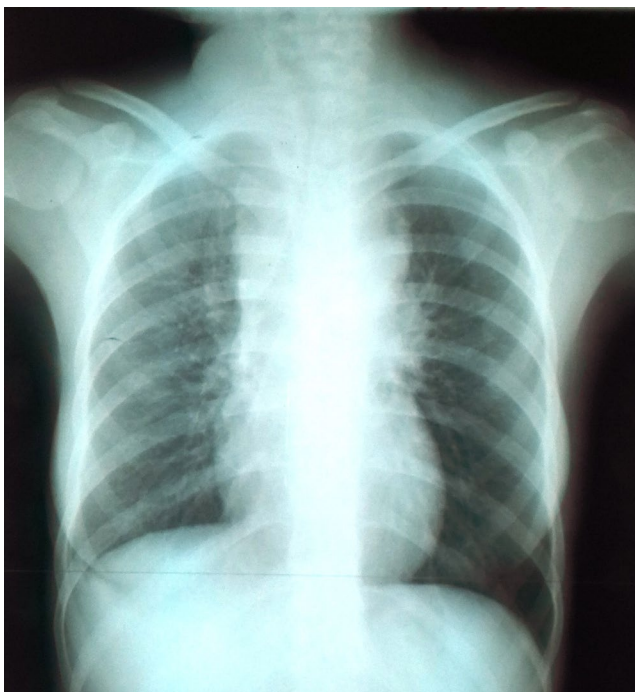
The chest x-ray showed an enlarged upper mediastinum with tracheal deviation, and a right pleural effusion (Figure 1). The computed tomography (CT) scan of the neck, chest, and abdomen revealed a heterogeneous cervical and mediastinal mass measuring 84 × 73 mm (Figure 2), compressing the trachea and the superior vena cava with a bilateral thrombosis of the jugular veins, pericardial and right pleural effusions, and retroperitoneal lymph nodes. A CT-guided biopsy of the goiter was performed via a right

This is an open access article under the terms of the Creative Commons Attribution NonCommercial NoDerivs License, which permits use and distribution in any medium, provided the original work is properly cited, the use is non commercial and no modifications or adaptations are made.

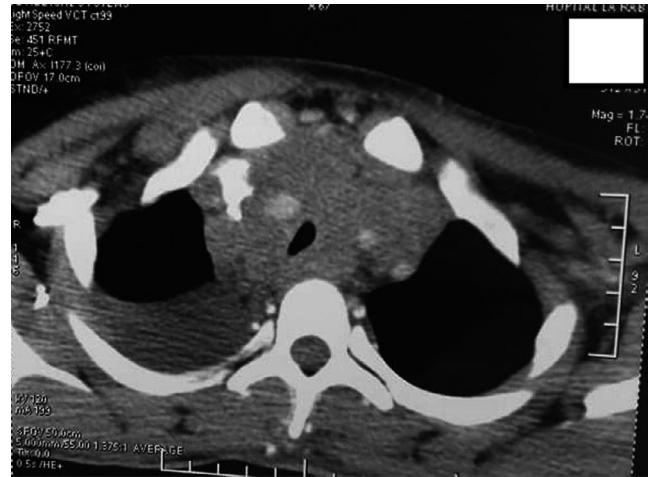
© 2021 The Authors. *Clinical Case Reports* published by John Wiley & Sons Ltd.

TABLE 1 Patient's biological parameters

	Patient's results	Reference ranges
Fasting blood glucose (g/L)	0.75	0.75–0.99
Cholesterol total (g/L)	1.28	1.2–2.00
Triglycerides (g/L)	0.62	0.50–1.5
Plasma creatinine ( $\mu\text{mol/L}$ )	70.4	4–13
Natremia (mmol/L)	135	135–145
Kalemia (mmol/L)	3.8	3.6–5.0
Aspartate aminotransferase (IU/L)	22	4–38
Alanine aminotransferase (IU/L)	11	4–41
Creatine phosphokinase (IU/L)	45	2–190
Alkaline phosphatase (IU/L)	193	5–270
White blood cells/mm <sup>2</sup>	4760	4000–10,000
Neutrophils/mm <sup>2</sup>	2430	1500–7000
Lymphocytes/mm <sup>3</sup>	1441	1500–4000
Red blood cells/mm <sup>3</sup>	$4.95 \times 10^6$	$4.0\text{--}5.3 \times 10^6$
Hemoglobin (g/dL)	11.5	12–16
Erythrocyte-sedimentation rate (mm/1st hour)	19	0–29
Thyroid-stimulating hormone (TSH) ( $\mu\text{IU/mL}$ )	5.05	0.12–3.4
Free thyroxin (FT4) (ng/dL)	1.41	0.71–1.85
Calcitonin (ng/L)	<2	<10



**FIGURE 1** The chest x-ray showed an enlarged upper mediastinum with tracheal deviation and a right pleural effusion



**FIGURE 2** CT scan showed a heterogeneous and compressive goiter with a right pleural effusion

parasternal approach with an 18G Tru-Cut needle. The histopathological examination showed a tumor proliferation of pleomorphic, undifferentiated, large cells with abundant eosinophilic cytoplasm and large irregular nuclei. There was no evidence of lymphocytic thyroiditis. The immunohistochemistry on paraffin-embedded specimens revealed a diffuse and intense cytoplasmic positivity of tumor cells to CD20 and their negativity to cytokeratin. Hence, the diagnosis of a diffuse large B-cell thyroid lymphoma, CD20 + was established. The patient was treated with corticosteroids and low molecular weight heparin and referred to oncology for additional treatment. However, the patient was lost to follow-up.

### 3 | DISCUSSION

Primary thyroid lymphoma is a rare tumor. It generally affects middle- to older-aged women in the 6–7th decade of life.<sup>4,5</sup> Primary thyroid lymphoma in patients younger than 50 years old is extremely rare. Young cases were reported in thyroid Hodgkin's lymphoma at a median age of 42 years.<sup>5</sup>

Most primary thyroid lymphomas are non-Hodgkin lymphomas of B-cell origin of either marginal zone lymphoma of mucosa-associated lymphoid tissue (MALT) or diffuse large B-cell lymphoma (DLBCL). The latter represents the most common subtype accounting for approximately two-thirds of cases of primary thyroid lymphomas.<sup>5,6</sup> Primary thyroid lymphoma typically arises in the setting of chronic lymphocytic thyroiditis. Hashimoto's thyroiditis is a well-established risk factor for primary thyroid lymphoma, especially the MALT subtype.<sup>7,8</sup> The risk of thyroid lymphoma in patients with Hashimoto's thyroiditis is at least 60 times higher than in patients without Hashimoto's thyroiditis.<sup>9</sup> This association may be explained by a chronic antigenic stimulation leading to a malignant transformation.<sup>10</sup> No other factors were associated with thyroid lymphoma.

Given the rarity and the nontypical clinical presentation of this disease, setting up an early diagnosis can be challenging. DLBCL and MALT lymphomas are two separate clinicopathological entities. Up to 10%–20% of patients with thyroid lymphomas present with typical 'B' symptoms such as fever, nocturnal sweating, and weight loss.<sup>4,8</sup> However, these symptoms are not specific and may also be observed in other conditions such as tuberculosis. The first aspect that should raise the suspicion of thyroid lymphoma should be the presence of a rapidly growing goiter or nodule (usually within 1–3 months), painless thyroid enlargement causing compressive symptoms (dysphagia, hoarseness, or dyspnea).<sup>9,11</sup> Our patient presented with typical 'B' symptoms and a rapidly growing and painless goiter accompanied by compressive symptoms.

Primary thyroid lymphoma is associated with normal or reduced thyroid function. Hypothyroidism is reported in 10% of cases.<sup>12</sup> It can result from a coexisting Hashimoto's thyroiditis or a diffuse thyroid gland infiltration by the tumor cells. Rarely, patients may present with hyperthyroidism.<sup>13</sup> This condition may be due to the destruction of the thyroid follicles and the release of the thyroid hormones into the circulation. In our case, subclinical hypothyroidism was noticed. Thyroid peroxidase antibodies were negative. This could not rule out the diagnosis of a coexisting Hashimoto's thyroiditis since cases of serum-negative-chronic-autoimmune-thyroiditis were reported and are considered a milder variant of classic Hashimoto's thyroiditis.<sup>14</sup> However, in our patient, histopathological features of Hashimoto's thyroiditis were not observed either.

Primary thyroid lymphomas are associated with a widespread expression of B-cell antigens.<sup>15</sup> Cytokines, particularly interleukin 7 (IL-7), play a key role in the pathophysiology of lymphoma.<sup>15</sup> The high expression of IL-7 may be used in differentiating thyroid lymphoma from lymphocytic thyroiditis.<sup>16</sup> Cytokines were not tested in our patient.

Primary thyroid lymphomas have no specific imaging features. Thus, it is difficult to differentiate them from other thyroid diseases. Ultrasound examination is the initial diagnostic tool for morphological thyroid abnormalities. Three different patterns can be observed: well-defined nodular lesions with hypoechoic and homogeneous internal echoes, bilateral diffuse hypoechoic lesions with indistinct borders, or multiple irregular hypoechoic lesions.<sup>17</sup> Lesion size, echotexture, margin, shape, cystic change, and local invasion were not specific features for the differential diagnosis.<sup>18</sup> In contrast, the presence of enhanced posterior echoes and/or a central blood flow pattern highly suggest the diagnosis of primary thyroid lymphoma.<sup>17,19</sup> Our patient ultrasound data were unavailable.

On CT scan, primary thyroid lymphoma often presents as a homogeneous and symmetric enlargement of the thyroid gland with a density lower than the adjacent

muscles.<sup>20</sup> In our patient, cervical CT scan revealed a large compressive heterogeneous goiter with a bilateral thrombosis of the jugular veins. The invasion of the cervical vascular structures is an extremely rare condition that may result from a tumor invasion and thrombosis or extrinsic compression.<sup>21</sup>

Pericardial and right pleural effusions were also noticed in our case. Serous effusions are a common complication of lymphomas. Although the frequency of pleural effusion is 20%–30% in lymphomas, the involvement of peritoneal and pericardial cavities is uncommon.<sup>22</sup> Pleural effusion due to lymphomas may adversely influence the patient's overall survival and it represents a predictor of disease relapse after chemotherapy. They are usually exudates resulting from four possible mechanisms: a tumor thoracic duct obstruction, direct pleural involvement of the lymphoma, an obstructed lymphatic return due to enlarged hilar or mediastinal lymph nodes, and infections.<sup>22</sup> The examination of the pleural fluid can be used to determine the mechanism of the pleural effusion. Pleural fluid cytology examination can also help to establish the diagnosis of DLBCL in case of a pleural involvement by lymphoma. However, it cannot replace biopsy because of possible negative findings.<sup>23</sup>

The diagnosis of primary thyroid lymphoma is often held on histopathology after thyroidectomy. In 50%–90% of cases, the diagnosis is made by fine-needle aspiration cytology.<sup>15,24</sup> Similarities may be observed between thyroid lymphoma, Hashimoto's thyroiditis, anaplastic carcinoma, and Riedel's thyroiditis which represent the principal differential diagnosis on cytology. Therefore, lobectomy and core biopsy are the preferred diagnostic approaches. In our case, a CT-guided biopsy of the goiter allowed the histopathological examination with immunohistochemistry that concluded to a diffuse large B-cell thyroid lymphoma, CD20 +.

The primary thyroid lymphoma staging is necessary before treatment and is based according to the Ann Arbor classification. A total body CT scan is needed to complete this staging. Besides, the standard staging of diffuse large B-cell lymphoma includes measurement of the serum Beta-2 microglobulin level which helps to predict the prognosis. The bone marrow studies are also important as part of the staging evaluation. Currently, 18F-2-fluoro-2-deoxy-D-glucose (18F-FDG) positron emission tomography (PET/CT) is being successfully used for both staging and follow-up of Hodgkin's and non-Hodgkin's lymphoma.<sup>25</sup>

At the time of presentation, approximately 56% of primary thyroid lymphomas are confined to the gland (stage IE), 32% involve the gland and regional lymph nodes (stage IIE), 2% involve the thyroid, the lymph nodes on both sides of the diaphragm, and/or the spleen (stage IIIE), and 11% of cases are disseminated (stage IVE).<sup>26</sup> Body CT scan of our patient revealed pericardial and right pleural effusions, and retroperitoneal lymph nodes (stage IIIE).

The treatment of primary thyroid lymphoma depends on the histological subtype and the stage of the disease. The usual approach is surgical excision for the localized forms of the disease, followed by radiotherapy and chemotherapy for disseminated forms. The gold standard for the management of DLBCL is based on a combination of the monoclonal antibody rituximab, chemotherapy (a combination of cyclophosphamide, doxorubicin, vincristine, and prednisone), and radiotherapy.<sup>27</sup> Due to the rarity of primary thyroid lymphoma and the lack of larger randomized controlled studies, definitive guidelines for the treatment and follow-up are awaited. Our patient was put on corticosteroids and referred to the department of oncology for additional treatment.

The overall prognosis of primary thyroid lymphoma depends on the age, the stage of the disease, and the histological grade. The main clinical prognostic factors include tumor size, adherence, extra-capsular extension, and retrosternal involvement.<sup>28</sup> Diffuse large B-cell lymphoma has a poorer prognosis compared to localized primary MALToma.<sup>8</sup> The prognosis is very poor for stages IIIE and IVE with a 5-year survival rate of 15%–35%.<sup>29</sup> Patients presenting with enlarging tumors or symptoms of compression or vascular thrombosis as in our case have poorer prognosis.<sup>21,30</sup>

## 4 | CONCLUSION

Primary thyroid lymphoma is a rare disease with no specific clinical manifestations. It should be suspected in case of rapid enlargement of the thyroid gland even in a young patient with no history of Hashimoto's thyroiditis. The confirmation relies on histopathology and immunohistochemistry.

## ACKNOWLEDGMENT

Published with written consent of the patient.

## CONFLICT OF INTEREST

None declared.

## AUTHOR CONTRIBUTIONS

IO: involved in conception and design, acquisition and interpretation of data, manuscript creation and drafting; HC: involved in acquisition of data and manuscript drafting; MC: involved in critically revision of the article for important intellectual content; all authors were involved in the management of this patient and the revision of the manuscript and approved the final version.

## ETHICAL APPROVAL

Ethical approval for this case report was not required. A written informed consent was obtained from the patient for the publication of this report.

## DATA AVAILABILITY STATEMENT

No data available.

## ORCID

Ibtissem Oueslati  <https://orcid.org/0000-0002-4278-9447>

Meriem Yazidi  <https://orcid.org/0000-0002-4239-5229>

## REFERENCES

- Monson JP. The epidemiology of endocrine tumours. *Endocr Relat Cancer*. 2000;7(1):29-36.
- Hadjisavva IS, Dina R, Talias MA, et al. Prevalence of cancer in patients with thyroid nodules in the island of cyprus: predictive value of ultrasound features and thyroid autoimmune status. *Eur Thyroid J*. 2015;4(Suppl 2):123-128.
- Liu XM, Ma DL, Yuan G, et al. Progressively enlarging goiter: case reports of primary thyroid lymphoma and literature review. *Curr Med Sci*. 2020;40(Suppl 3):518-522.
- Katna R, Shet T, Sengar M, et al. Clinicopathologic study and outcome analysis of thyroid lymphomas: experience from a tertiary cancer center. *Head Neck*. 2013;35(Suppl 2):165-171.
- Wang SA, Rahemtullah A, Faquin WC, et al. Hodgkin's lymphoma of the thyroid: a clinicopathologic study of five cases and review of the literature. *Mod Pathol*. 2005;18(Suppl 12):1577-1584.
- Mishra P, Banerjee D, Gujral S. T-cell lymphoma of thyroid gland with lennt type of morphology: a case report and review of the literature. *Head Neck Pathol*. 2016;10(Suppl 3):321-326.
- Wei L, Zhao N, Li Y, et al. Down syndrome with primary thyroid diffuse large B-cell lymphoma and Hashimoto thyroiditis: a CARE compliant case report. *Medicine*. 2019;98(Suppl 35):e16994.
- Shrestha P, Aderhold K, Swierczynski S, et al. Primary thyroid MALToma- a rare diagnosis of an unassuming thyroid nodule. *J Community Hosp Intern Med Perspect*. 2018;8(Suppl 1):42-45.
- Pedersen RK, Pedersen NT. Primary non-Hodgkin's lymphoma of the thyroid gland: a population based study. *Histopathology*. 1996;28(Suppl 1):25-32.
- Kossv P, Livolsi V. Lymphoid lesions of the thyroid: review in light of the revised European-American lymphoma classification and upcoming World Health Organization classification. *Thyroid*. 1999;9:1273-1280.
- Hedhilia F, Kedousa S, Jbalia S, et al. Primary thyroid lymphoma: case report and review of the literature. *Egypt J Ear Nose Throat Allied Sci*. 2015;16:171-173.
- Peixoto R, Correia Pinto J, Soares V, et al. Primary thyroid lymphoma: a case report and review of the literature. *Ann Med Surg*. 2016;13:29-33.
- Jennings AS, Saberi M. Thyroid lymphoma in a patient with hyperthyroidism. *Am J Med*. 1984;76(Suppl 3):551-552.
- Croce L, De Martinis L, Pinto S, et al. Compared with classic Hashimoto's thyroiditis, chronic autoimmune serum-negative thyroiditis requires a lower substitution dose of L-thyroxine to correct hypothyroidism. *J Endocrinol Invest*. 2020;43(11):1631-1636. <https://doi.org/10.1007/s40618-020-01249-x>
- Wang JH, Chen L, Ren K. Identification of primary thyroid lymphoma with medical imaging: a case report and review of the literature. *Oncol Lett*. 2014;8(Suppl 6):2505-2508.



16. Takakuwa T, Nomura S, Matsuzuka F, et al. Expression of interleukin-7 and its receptor in thyroid lymphoma. *Lab Invest.* 2000;80:1483-1490.
17. Ota H, Ito Y, Matsuzuka F, et al. Usefulness of ultrasonography for diagnosis of malignant lymphoma of the thyroid. *Thyroid.* 2006;16:983-987.
18. Gu LS, Cui NY, Wang Y, et al. Comparison of sonographic characteristics of primary thyroid lymphoma and anaplastic thyroid carcinoma. *J Thorac Dis.* 2017;9(Suppl 11):4774-4784.
19. Wang Z, Fu B, Xiao Y, et al. Primary thyroid lymphoma has different sonographic and color Doppler features compared to nodular goiter. *J Ultrasound Med.* 2015;34:317-323.
20. Kim HC, Han MH, Kim KH, et al. Primary thyroid lymphoma: CT findings. *Eur J Radiol.* 2003;46:233-239.
21. Dikici AS, Yıldırım O, Er ME, et al. A rare complication of the thyroid malignancies: jugular vein invasion. *Pol J Radiol.* 2015;80:360-363.
22. Bambaravanage A, Nelatur V. Lymphoma presenting with spontaneous internal jugular and subclavian venous thrombosis and a large pleural effusion. *Clin Med.* 2019;19(Suppl 2):15.
23. Vega F, Padula A, Valbuena JR, et al. Lymphomas involving the pleura: a clinicopathologic study of 34 cases diagnosed by pleural biopsy. *Arch Pathol Lab Med.* 2006;130(Suppl 10):1497-1502.
24. Acar N, Acar T, Avcı A, et al. Approach to primary thyroid lymphoma: case series. *Turk J Surg.* 2019;35(Suppl 2):142-145.
25. Öner AO, Sürer Budak E, Aydın F, et al. Efficacy of <sup>18</sup>F-2-fluoro-2-deoxy-D-glucose positron emission tomography/computerized tomography for bone marrow infiltration assessment in the initial staging of lymphoma. *Mol Imaging Radionucl Ther.* 2017;26(Suppl 2):69-75.
26. Graff-Baker A, Roman SA, Thomas DC, et al. Prognosis of primary thyroid lymphoma: demographic, clinical, and pathologic predictors of survival in 1,408 cases. *Surgery.* 2009;146:110-115.
27. Walsh S, Lowery AJ, Evoy D, et al. Thyroid lymphoma: recent advances in diagnosis and optimal management strategies. *Oncologist.* 2013;18(Suppl 9):994-1003.
28. Tupchong L, Hughes F, Harmer CL. Primary lymphoma of the thyroid: clinical features, prognostic factors, and results of treatment. *Int J Rad Oncol Biol Phys.* 1986;12:1813-1821.
29. Avenia N, Ragusa M, Cirocchi R, et al. Surgical treatment of primitive thyroid lymphoma. *Tumori.* 2009;95(Suppl 6):712-719.
30. Mack LA, Pasiaka JL. An evidence-based approach to the treatment of thyroid lymphoma. *World J Surg.* 2007;31(Suppl 5):978-986.

**How to cite this article:** Oueslati I, Chatti H-A, Yazidi M, Chaker F, Chihaoui M. A diffuse large B-cell thyroid lymphoma presented as a compressive goiter in a young woman with no evidence of Hashimoto's thyroiditis. *Clin Case Rep.* 2021;9:e04436. <https://doi.org/10.1002/ccr3.4436>