



Current and future funding streams for paediatric postmortem imaging: European Society of Paediatric Radiology survey results

Greg Chambers¹ · Susan C. Shelmerdine^{2,3,4} · Michael Aertsen⁵ · Martha Dohna⁶ · Stacy K. Goergen^{7,8} · Karl Johnson⁹ · Willemijn M. Klein¹⁰ · Elka Miller¹¹ · Gerald Pärtan¹² · David Perry¹³ · Padma Rao¹⁴ · Claire Robinson¹⁵ · Joachim Stegmann¹⁶ · Ajay Taranath^{17,18} · Elspeth Whitby¹⁹ · Rick R. van Rijn²⁰ · Owen J. Arthurs^{2,3,4}

Received: 28 March 2022 / Revised: 11 July 2022 / Accepted: 16 August 2022
© The Author(s), under exclusive licence to Springer-Verlag GmbH Germany, part of Springer Nature 2022

Abstract

Background Perinatal and childhood postmortem imaging has been accepted as a noninvasive alternative or adjunct to autopsy. However, the variation in funding models from institution to institution is a major factor prohibiting uniform provision of this service. **Objective** To describe current funding models employed in European and non-European institutions offering paediatric postmortem imaging services and to discuss the perceived barriers to future postmortem imaging service provision. **Materials and methods** A web-based 16-question survey was distributed to members of the European Society of Paediatric Radiology (ESPR) and ESPR postmortem imaging task force over a 6-month period (March–August 2021). Survey questions related to the radiologic and autopsy services being offered and how each was funded within the respondent's institute. **Results** Eighteen individual responses were received (13/18, 72.2% from Europe). Only one-third of the institutions (6/18, 33.3%) have fully funded postmortem imaging services, with the remainder receiving partial (6/18, 33.3%) or no funding (5/18, 27.8%). Funding (full or partial) was more commonly available for forensic work (13/18, 72%), particularly where this was nationally provided. Where funding was not provided, the imaging and reporting costs were absorbed by the institute. **Conclusion** Increased access is required for the expansion of postmortem imaging into routine clinical use. This can only be achieved with formal funding on a national level, potentially through health care commissioning and acknowledgement by health care policy makers and pathology services of the value the service provides following the death of a fetus or child. Funding should include the costs involved in training, equipment, reporting and image acquisition.

Keywords Autopsy · Children · Computed tomography · Funding · Magnetic resonance imaging · Perinatal · Postmortem · Survey

Introduction

Perinatal and childhood postmortem imaging has been accepted by parents and health care institutions as an alternative or adjunct to traditional autopsy [1–5]. Nonetheless, there is marked variation among institutions in the provision of, and support for, postmortem imaging services, both in terms of the modalities offered and the volume and nature of the work conducted.

Whilst many institutions provide conventional radiography, cross-sectional imaging techniques (e.g., computer tomography [CT] and magnetic resonance imaging [MRI]) are more often

only available in larger paediatric tertiary institutions. A previous European Society of Paediatric Radiology (ESPR) survey found that whilst 72% of institutions performing postmortem imaging had standardised protocols for acquiring radiographs, only 27–32% of institutions had protocols for postmortem CT and MRI [6]. More advanced techniques including micro-CT, high-field strength MRI and postmortem ultrasound (US) are almost exclusively available in paediatric tertiary referral or research institutions.

Despite the decline in parental consent for conventional (invasive) autopsies and support for noninvasive methods, anecdotal evidence suggests that a major barrier to postmortem imaging services is a lack of a dedicated funding stream that may be entirely lacking, partially supported or only available through research grants, rather than being centrally, nationally or government funded [7–10].

✉ Greg Chambers
g.chambers@nhs.net

Extended author information available on the last page of the article

In this study, we sought to identify and describe the variation in funding models reported by postmortem imaging providers and to identify barriers and facilitators to changing practice. The authors define a model as the product of a funding stream (e.g., national, insurance, research, etc.) plus the degree of reimbursement from this stream (e.g., full, partial, etc.).

Materials and methods

All survey participation was entirely voluntary and the personal identities of survey respondents were not collected. Institutional ethical review board approval was not required as no patient data were shared or accessed.

Study design

The lead (G.C.) and senior authors (S.C.S., O.J.A.), all radiologists with 8, 12 and 16 years of experience, respectively, developed a survey containing 16 questions relating to local paediatric postmortem imaging services and funding streams (See Online Supplementary Material 1 for the full list of questions). The wording and content of individual survey items were discussed at an ESPR Post-mortem Imaging Taskforce meeting to achieve clarity, readability and internal validity and draft items were refined accordingly, resulting in the final survey design. Participants were asked to provide separate responses regarding funding for postmortem imaging for medical (i.e. non-forensic) and forensic cases. Both multiple choice and free text answers were included in the survey. One response was accepted from each institution and multiple practitioners from the same institute were able to submit a joint response.

Survey distribution

The survey was created within Google Forms and distributed via an online link through an email distributed to all members of the ESPR Post-mortem Imaging Taskforce, as well as to all general ESPR members via a newsletter. The survey link was also made available on Twitter via the official ESPR and Junior ESPR accounts.

The survey was distributed on 1 March 2021 and closed on 31 August 2021. Results were collated and analysed in a descriptive manner and preliminary findings presented at an ESPR Post-Mortem Imaging Taskforce meeting.

Results

Respondents

A single email was sent to the 22 members of the taskforce (representing 26 institutions in 8 countries). In total, 19

responses were received, with duplicate responses from one institution leaving 18 individual responses for final analysis. These results came exclusively from the coauthors on this paper, who are all members of the ESPR Post-Mortem Imaging Taskforce.

Responses were received from the following continents and countries:

- Europe 13/18 (72.2%): Austria (1), Belgium (1), Germany (2), Hungary (1), Netherlands (2), United Kingdom (6).
- Oceania 4/18 (22.2%): Australia (3), New Zealand (1).
- North America 1/18 (5.6%): Canada (1).

Of these, the majority 17/18 (94.4%) described themselves as a “university/teaching hospital” and the remaining participant as a “district general/community hospital.” The term “institution(s)” will be used for the remainder of the article to encompass these.

Postmortem imaging practice

In both the medical and forensic settings, all age groups of paediatric patients were imaged (Tables 1 and 2). The modalities used to perform medical (i.e. non-forensic) post-mortem imaging included:

- Radiography/X-ray: 18/18 (100% of respondents).
- Conventional CT: 16/18 (88.9%).
- Conventional MRI: 11/18 (61.1%).
- Ultrasound: 5/18 (27.8%).
- “Non-conventional CT/MR,” i.e. micro-CT or high field strength MR (FH-MRI): 2/18 (11.1%).

The modalities used to perform forensic postmortem imaging included:

- Radiography/X-ray: 14/14 (100% of respondents).
- Conventional CT: 12/14 (85.7%).
- Conventional MRI: 5/14 (35.7%).

Table 1 The table shows the paediatric age groups for patients the respondents provide medical (i.e. non-forensic) postmortem imaging services for ($n=17$)

Paediatric age group	Response (n)	Percentage (%)
Fetal	13	76.5
Neonate (0–28 days)	14	82.4
Infant (1–12 months)	14	82.4
Child (1–12 years)	10	58.8
Adolescent (13–18 years)	9	52.9

One respondent left the question blank

Table 2 The table shows the paediatric age groups for whom forensic postmortem imaging services are provided ($n = 14$)

Paediatric age group	Response (n)	Percentage (%)
Fetal	6	42.9
Neonate (0–28 days)	13	92.9
Infant (1–12 months)	13	92.9
Child (1–12 years)	13	92.9
Adolescent (13–18 years)	12	85.7

Four institutions did not provide forensic postmortem imaging services

- “Non-conventional CT/MR,” i.e. micro-CT or high field strength MR (FH-MRI): 1/14 (7.1%).

Postmortem US was being provided by one institution (7.1%) in the research setting.

Postmortem imaging referrals

Most institutions (17/18, 94.4%) received referrals for medical postmortem imaging from their local clinicians or pathologists, whilst over a third (7/18, 38.9%) accepted referrals from outside their institution. In most cases (16/18, 88.9%), reporting of the locally acquired imaging was also performed and 11/18 (61.1%) institutions reported externally performed examinations.

Fourteen institutions (77.8%) carried out some form of postmortem imaging in the forensic setting. This included acquisition of imaging for local referrals in 11/14 (78.6%) and acquisition of imaging for externally referred patients in 8/14 (57.1%) institutions. In 11 institutions (78.6%), there was reporting of the locally performed imaging and in 10/14 (71.4%) institutions reporting was provided for externally performed imaging.

Five institutions (27.8%) used postmortem imaging for research purposes. Four institutions (80%) acquired imaging for local/outside referrals. The remaining institution only undertook reporting of postmortem imaging research studies. It is not clear where these images were acquired.

Promoting postmortem imaging services

Most respondents (13/18, 72.2%) said other health care services/users were aware of their postmortem imaging services, 2/18 (11.1%) did not think they were and 3/18 (16.7%) were unsure.

Respondents were asked to highlight by which means referrers were made aware of the postmortem imaging services. Multiple options were available for selection. Three respondents did not answer the question. The most common responses were:

- Through loco-regional pathways: 7/15 (46.7% of respondents).
- Ad hoc/unofficial referrals: 7/15 (46.7%).
- Personal/private referrals: 6/15 (40%).
- National referral pathways: 3/15 (20%).

Reimbursement for postmortem imaging

There was marked variation between countries regarding reimbursement streams and the degree to which this covers incurred costs. Figures 1 and 2 show which funding streams are employed per modality in medical postmortem imaging

Current reimbursement streams for medical PMI by modality

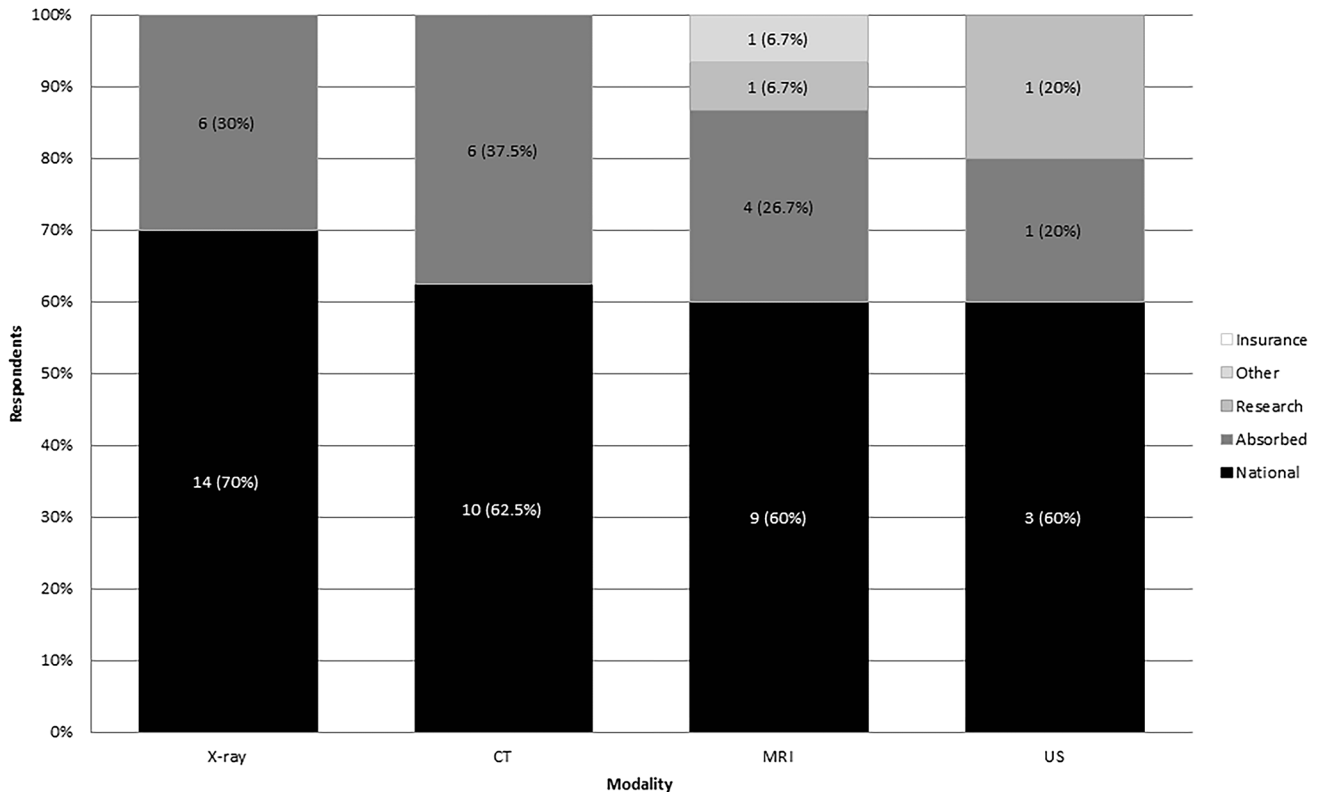


Fig. 1 Current reimbursement streams for medical (i.e. non-forensic) postmortem imaging (PMI) by modality. Other=cost paid by referring hospital. Total responses: X-ray 20; computed tomography (CT) 16, magnetic resonance imaging (MRI) 15 and ultrasound (US) 5

and forensic postmortem imaging, respectively. The majority of institutions reported single-stream reimbursement for each modality, but two reported some X-ray and MRI examinations were reimbursed nationally and/or absorbed by the department in the medical setting (Fig. 1). In the forensic setting, all institutions reported single streams of reimbursement (Fig. 2).

Insurance-based systems did not reimburse forensic postmortem imaging in the institutions surveyed.

Overall, medical (non-forensic) postmortem imaging was reimbursed fully in 6/18 (33.3%) institutes, partially in 6/18 (33.3%) and not at all in 5/18 (27.8%). One respondent was unsure. Forensic postmortem imaging was reimbursed fully in 8/14 sites (57.1%), partially in 5/14 (35.7%) and not at all in 1/14 (7.1%).

The preferred funding models reported by respondents for medical postmortem imaging were full reimbursement via national/state funding streams in 15/18 (83.3%) and insurance in 3/18 (16.7%) within countries with established insurance-based models. For forensic postmortem imaging, this was via national/state funding streams in 15/16 (93.8%) and other in 1/16 (6.3%) (no change from current model where the forensic institution pays, as entered in the free text box).

When combining “more of a priority/absolute priority” responses regarding what imaging modalities should be prioritised for funding - conventional MRI (72.2%), conventional CT (66.7%) and X-ray (38.9%) were the most prioritised modalities, whilst US (16.7%), micro-CT (22.3%) and high-field strength MRI (16.7%) were the least prioritised (Fig. 3).

Reimbursement for postmortem autopsy

Reimbursement for conventional autopsy occurred in 12/18 (66.7%) responding institutions. In the remaining six institutions, three were unsure and three did not believe autopsy was reimbursed or it occurred in a separate institute. Where funded, this was from national/state funding streams in 9/12 (75%), absorbed into departmental costs in 1/12 (8.3%), paid by the police/coroner in 1/12 (8.3%) and by research grants in the remaining site (8.3%). The cost for autopsies ranged from between £500–£1,400 in the United Kingdom (approx. €600–€1,700), up to €2000 in Europe and \$2,500 in Australia (approx. €1,600).

Current reimbursement streams for forensic PMI by modality

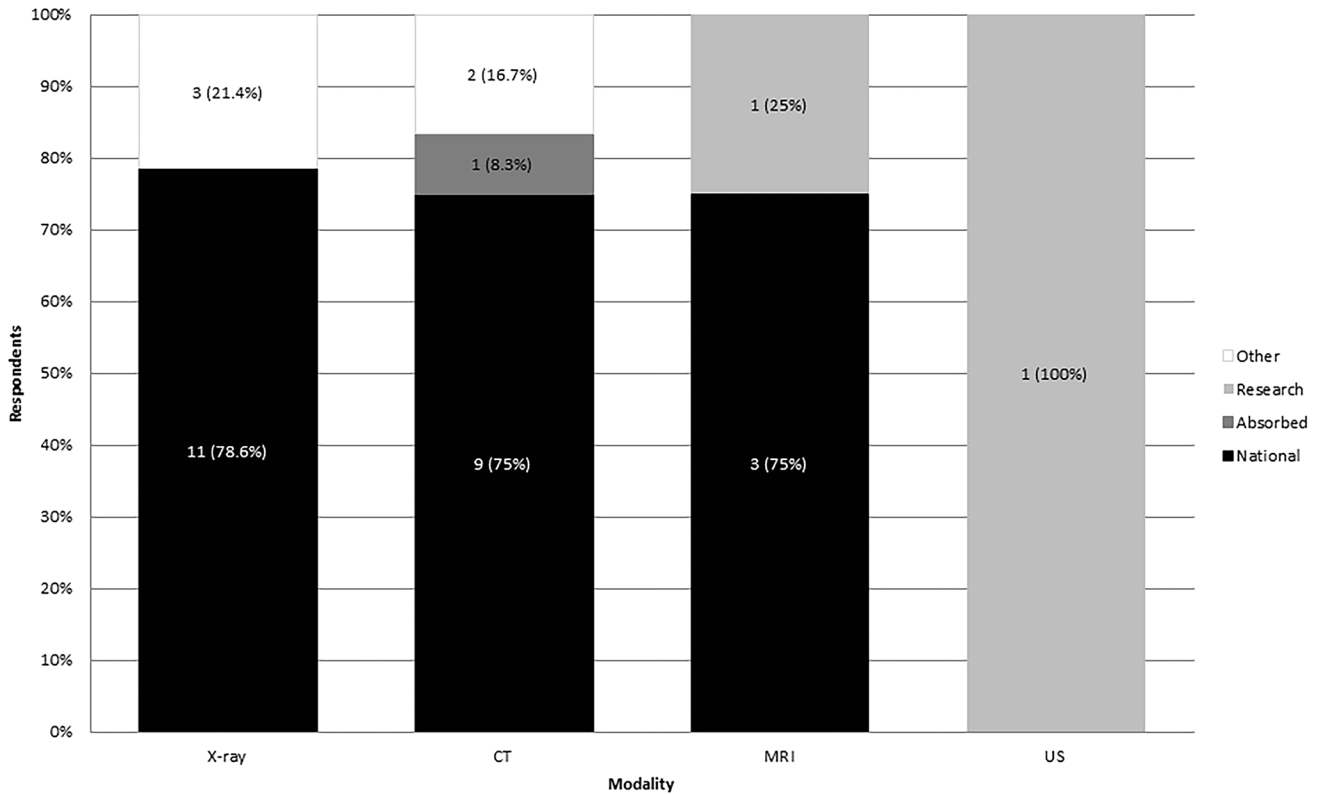


Fig. 2 Current reimbursement streams for forensic postmortem imaging (PMI) by modality. Other = forensic institute/police/coroner. Total responses: X-ray 14; computed tomography (CT) 12, magnetic resonance imaging (MRI) 4 and ultrasound (US) 1. One “not sure” response not shown

Barriers to postmortem imaging

The range of barriers reported by respondents to performing postmortem imaging are listed in Table 3. One of the 18 institutions (5.6%) did not perceive any barriers. In the remaining 17 institutions, the most frequent barriers were:

- Scanner/equipment availability (70.6%).
- Organisation/administration issues (58.8%).
- Lack of local/national guidance (52.9%).
- Lack of radiologist availability (52.9%).

Free text answers provided by respondents highlighted further barriers including:

- Lack of clarity over reimbursement.
- Cultural choices of families.
- Clinicians being unfamiliar with postmortem imaging and thus not referring.
- Lack of pathologist support.

Future suggested developments

Figure 4 outlines the areas for future prioritisation for post-mortem imaging services with local/national guidance being selected as the greatest priority and considered “extremely/very important” by 67.7% of respondents. Radiographer training, radiologist availability, radiographer availability, equipment availability and support staff availability were believed to be “extremely/very important” in more than 50% of responses.

Additional free text answers included:

- Development of specific CT protocols.
- Increasing awareness of virtual biopsy.
- Further information for parents/guardians in explaining the role of postmortem imaging.
- Equal prioritisation of postmortem imaging alongside clinical work.
- Increased reporting time.
- Clear funding streams.

Future priorities for modality funding in PMI

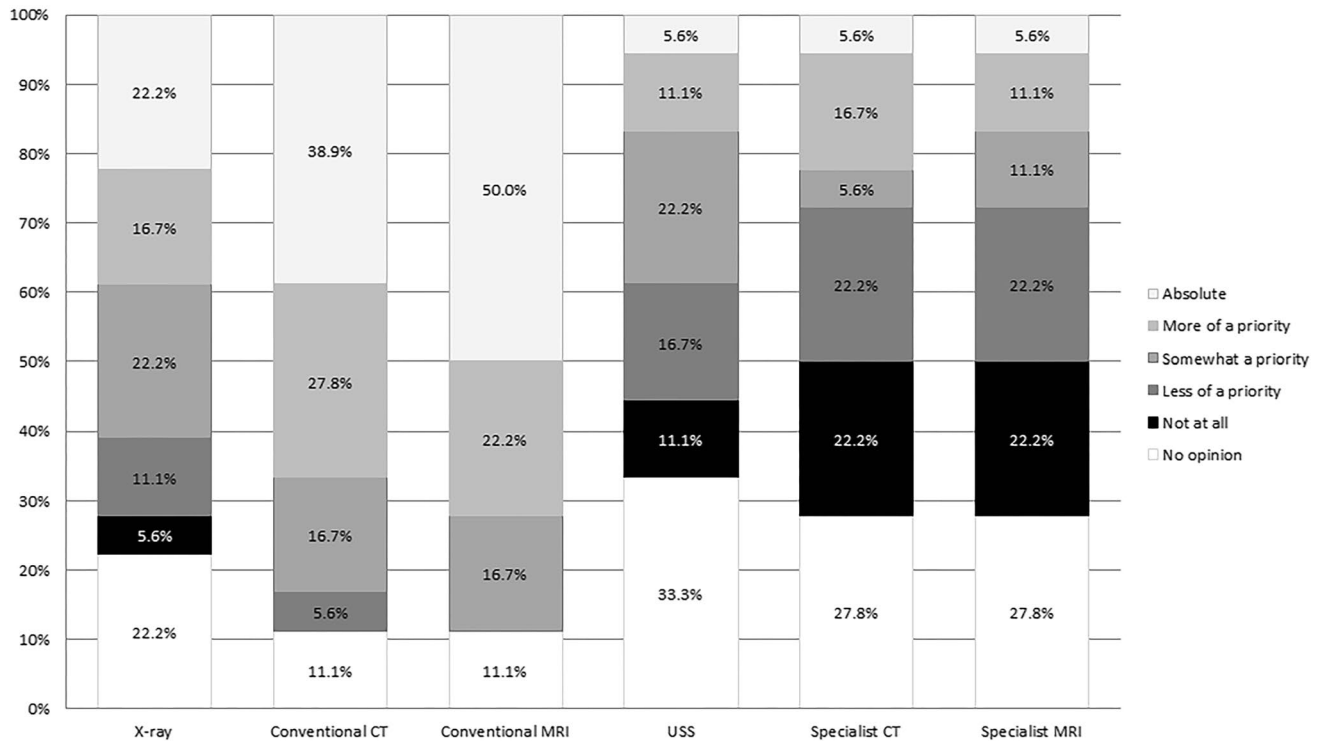


Fig. 3 Respondent opinions regarding how and where future funding should be prioritised in terms of acquisition modality for postmortem imaging (PMI). Respondent number = 18. *CT* computed tomography, *MRI* magnetic resonance imaging, *USS* ultrasound scan

Table 3 Perceived barriers to performing postmortem imaging (*n* = 17)

Perceived barrier	Response (<i>n</i>)	Percentage (%)
Scanner/equipment availability	12	70.6
Organisation/admin	10	58.8
Lack of guidance	9	52.9
Radiologist availability	9	52.9
Radiologist training	8	47.1
Radiographer availability	7	41.2
Support staff availability	5	29.4
Radiographer training	3	17.6
Other	8	47.1

One respondent did not declare any perceived barriers in their centre

In terms of the ways in which postmortem imaging has been successfully facilitated and implemented, responses included:

- Using a research-to-clinical practice approach.
- Increasing radiologist access to the mortuary.
- Installation of a dedicated on-site cold storage facility in the radiology department for the deceased, facilitating imaging in non-dedicated time slots.

- Two institutions have formal funding from government/pathology institutes to acquire and report postmortem imaging and this arrangement has led to the service being routinely available.

Discussion

Our survey shows that only a third of responding specialist institutions receive full funding for their current postmortem imaging practice. The main source of this funding is via national/state funding streams. When funding is not provided, then the cost is absorbed by their institution. Most respondents believe that national/state funding or an insurance-based stream would be the preferred method for funding postmortem imaging services.

Our results also show the ongoing multifactorial barriers to facilitating paediatric postmortem imaging, which continue to be problematic, even in large teaching/university hospitals. Not only do these institutes acquire and report local studies, but act as referral institutions for loco-regional hospitals for both medical and forensic cases, which require financial support and an established infrastructure to facilitate this increasing workload. Where cross-sectional postmortem imaging has shifted from research to accepted clinical practice, mainstream

Future priority areas for facilitating the performance of PMI

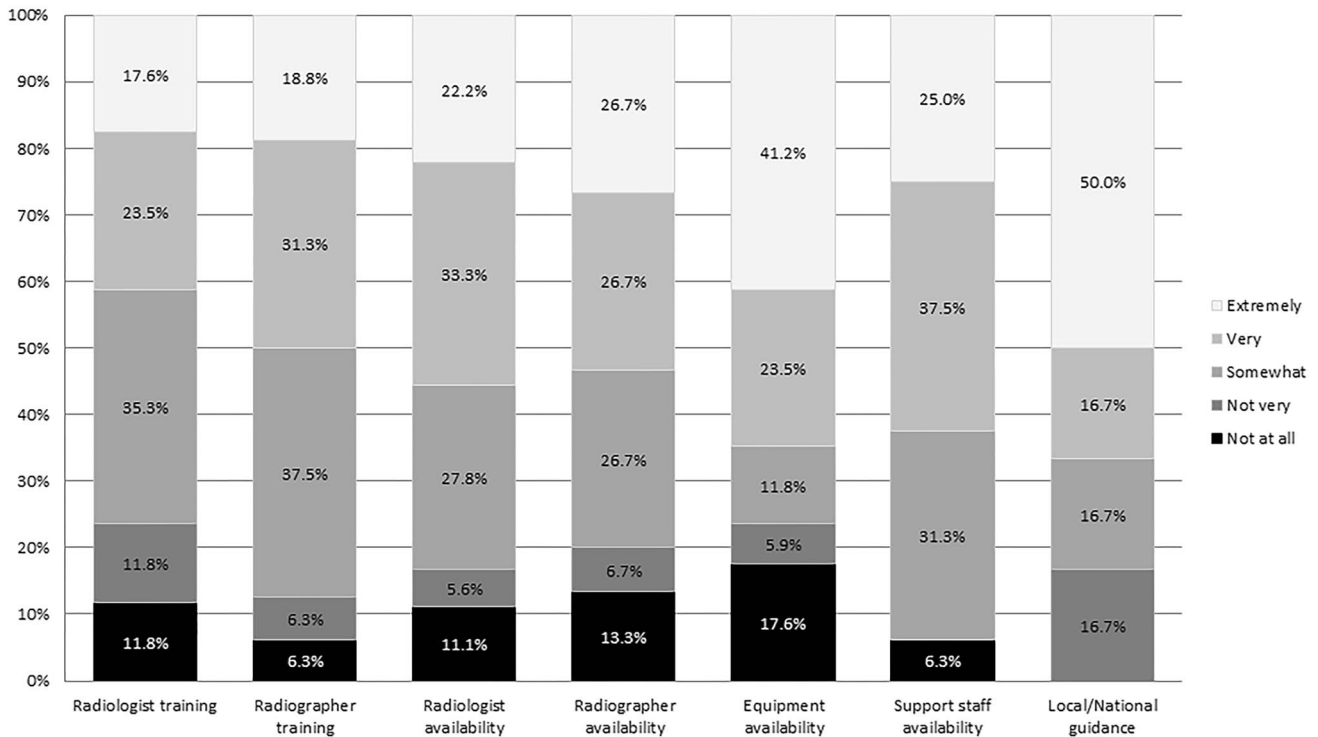


Fig. 4 Respondent opinions regarding priority areas for future funding of postmortem imaging (PMI). Respondent number: radiologist training = 17; radiographer training = 16; radiologist availability = 18;

radiographer availability = 15; equipment availability = 17, support staff availability = 16 and local/national guidance = 12. *CT* computed tomography, *MRI* magnetic resonance imaging, *US* ultrasound

funding has not followed. This could be aided by the adoption of national/international guidelines for postmortem imaging, which the ESPR postmortem task force has advocated [2, 11, 12]. There is a growing acceptance of its utility, especially given the increasing evidence for its diagnostic accuracy, ability to demonstrate a variety of abnormal pathologies and increasing refusal by families for conventional autopsy. Previous research has led to embedding of postmortem imaging recommendations within paediatric specific autopsy protocols from the Royal College of Pathologists in the UK [13–16]. With endorsement of such guidance from major European and international bodies, clinicians will have evidence to support the creation of national or loco-regional referral pathways incorporating postmortem imaging. Furthermore, this approach would go some way in highlighting the availability of postmortem imaging in the almost 30% of institutions whose respondents said there was a general lack of awareness of the existence of their postmortem imaging service by other health care services and referrers.

This is supported by the fact that almost half of institutions reported ad hoc referrals and 40% still rely on personal/direct/private referrals suggesting a word-of-mouth referral process. This ad hoc approach may be a consequence of a lack of agreed

national/loco-regional referral pathways and guidelines, which may contribute to an inability to attract appropriate funding to support service provision. A model of referral from an independent pathology institution appears to be successful in two countries (Netherlands [for forensic cases] and Australia), with potential for image acquisition and reporting being separated. This approach could relieve some of the burden on scanner and storage time but may not be feasible in many health care systems without robust imaging networks and teleradiology facilities to allow this type of working. In addition, MRI facilities continue to be unusual in pathology departments and even forensic medicine facilities, meaning that busy clinical scanners are generally used for postmortem MRI.

It was interesting to note in our study that for medical (non-forensic) postmortem imaging, all but 2 institutions use conventional CT (89%) and approximately 60% use conventional MRI in their service; however, for forensic cases 50% use conventional CT and 35% use conventional MRI. Whilst in countries such as the Netherlands and Germany, postmortem CT is an integral part of the forensic pathway, this is not universal and is not routine in the medical postmortem setting. Although the reasons are not clear from the survey itself, this could be due to delays in updating guidelines,

tight turnaround times, lack of reporting expertise, lack of scanner availability and/or increased reporting times, which are not conducive to performing more than simple radiography. Nonetheless, conventional CT and MRI are modalities where respondents believe the future of funding should be concentrated. Conventional scanners are widely available in large hospitals, so additional infrastructure costs would be negligible compared to specialist CT and MRI, i.e. micro-CT and high-field strength MRI, although the benefit of these more specialised techniques is recognised for early gestational losses and pathology specimen imaging [17, 18].

It is important to recognise that funding for postmortem imaging would not be purely for remuneration of radiologist's reporting time (which may also involve contributing to a formal postmortem report for families), but would also cover several hidden costs to the service such as training appropriate staff (radiographers, administration and radiologists), provision of scanner time and purchasing of additional equipment to facilitate expedition of the imaging process, i.e. mortuary space/refrigeration. With long hospital and radiology waiting lists for clinically emergent and non-emergent live cases (potentially exacerbated by the COVID-19 pandemic [19]), it is likely that funding for postmortem imaging may not be viewed as a priority investment area for hospitals and health care insurance companies. Health economic impact assessments have yet to be conducted and will provide useful evidence for how and where postmortem imaging may provide opportunities for cost-saving and time efficiencies within the pathology/mortuary services (i.e. a minimum cost threshold), as well as providing closure and aiding in the grieving process for parents (potentially reducing the burden of future mental health issues and recurrent pregnancy losses in the case of genetic disorders).

There are several limitations to the study, including a clear selection bias. We targeted those already practising postmortem imaging from a paediatric radiology perspective mostly from Western Europe (with a large UK cohort) with some responses from North America and Oceania. We recognise that this potentially excludes health care professionals from most of America (North and South), Africa and Asia; however, an excellent study of the state of postmortem imaging services in North America has recently been published [20]. We also did not survey professionals working in forensic adult radiology, forensic physicians or specialist pathologists as it is common practice for paediatric medical imaging to be reported by trained radiologists. We assumed most clinical practitioners are in contact with imaging colleagues through multidisciplinary meetings, and thus we are likely to have captured data from most relevant institutions. We did not survey health care managers, funding specialists or commissioners, although there is clearly a need to seek out these opinions in future. Finally, we did not receive responses from any institutions that are unable to perform any postmortem imaging, and therefore these specific barriers to entry have not been evaluated.

Conclusion

To improve and sustain routine access to paediatric and fetal postmortem imaging, formalising jurisdictional referral pathways and funding mechanisms is clearly required. This will require advocacy by radiologists and pathologists working with policymakers and funders, as well as an acceptance that postmortem imaging has an important investigative role following the unexpected death of a fetus or child. Funding needs to extend beyond provision of the imaging service to include training, equipment and reporting.

Supplementary Information The online version contains supplementary material available at <https://doi.org/10.1007/s00247-022-05485-6>.

Acknowledgements Susan C. Shelmerdine is funded by a National Institute for Health Research (NIHR) Advanced Fellowship Award (NIHR-301322). Owen J. Arthurs is funded by a NIHR Career Development Fellowship (NIHRCDF-2017-10-037). The views expressed are those of the authors and not necessarily those of the NHS, the NIHR or the Department of Health and Social Care.

Declarations

Conflicts of interest None

References

1. Cohen MC, Whitby E, Fink MA et al (2015) Running a post-mortem service—a business case and clinical experience. *Pediatr Radiol* 45:501–508
2. Sonnemans LJP, Vester MEM, Kolsteren EEM et al (2018) Dutch guideline for clinical foetal-neonatal and paediatric post-mortem radiology, including a review of literature. *Eur J Pediatr* 177:791–803
3. Addison S, Arthurs OJ, Thayyil S (2014) Post-mortem MRI as an alternative to non-forensic autopsy in foetuses and children: from research into clinical practice. *Br J Radiol* 87:20130621
4. Cannie M, Votino C, Moerman Ph et al (2012) Acceptance, reliability and confidence of diagnosis of fetal and neonatal virtuopsy compared with conventional autopsy: a prospective study. *Ultrasound Obstet Gynecol* 39:659–665
5. Kang X, Cos T, Guizani M et al (2014) Parental acceptance of minimally invasive fetal and neonatal autopsy compared with conventional autopsy. *Prenat Diagn* 34:1106–1110
6. Arthurs OJ, van Rijn RR, Sebire NJ (2014) Current status of paediatric post-mortem imaging: an ESPR questionnaire-based survey. *Pediatr Radiol* 44:244–251
7. Hatch GM (2015) What are the greatest challenges or barriers to applying post-mortem imaging in pediatric radiology? *Pediatr Radiol* 45:480
8. Cain TM (2015) What are the greatest challenges or barriers to applying postmortem imaging in paediatric radiology? *Pediatr Radiol* 45:481
9. Chapman S (2015) What are the greatest challenges and/or barriers to applying postmortem imaging in paediatric radiology? *Pediatr Radiol* 45:478
10. Ruder TD (2015) What are the greatest challenges or barriers to applying post-mortem imaging in pediatric radiology? *Pediatr Radiol* 45:479
11. Whitby E, Offiah AC, Shelmerdine SC et al (2021) Current state of perinatal postmortem magnetic resonance imaging: European

- Society of Paediatric Radiology questionnaire-based survey and recommendations. *Pediatr Radiol* 51:792–799
12. Shelmerdine SC, Gerrard CY, Rao P et al (2019) Joint European Society of Paediatric Radiology (ESPR) and International Society for Forensic Radiology and Imaging (ISFRI) guidelines: paediatric postmortem computed tomography imaging protocol. *Pediatr Radiol* 49:694–701
 13. The Royal College of Pathologists (2016) Royal College of Pathologists (RCPath) Guidelines for the investigation of sudden unexplained death in infancy <https://www.rcpath.org/uploads/assets/874ae50e-c754-4933-995a804e0ef728a4/Sudden-unexpected-death-in-infancy-and-childhood-2e.pdf>. Last accessed 24/03/2022
 14. Cox P, Hargitai B, Marton T (2017) Guidelines on autopsy practice: Fetal autopsy (2nd trimester fetal loss and termination of pregnancy for congenital anomaly). In: Osborn M, Lowe J (eds), The Royal College of Pathologists
 15. Cox P, Hargitai B, Marton T (2018) Guidelines on autopsy practice: Neonatal death. In: Osborn M (ed) The Royal College of Pathologists
 16. Cox P, Hargitai B, Marton T (2017) Guidelines on autopsy practice: Third trimester antepartum and intrapartum stillbirth. In: Osborn M, Lowe J (eds), The Royal College of Pathologists
 17. Shelmerdine SC, Simcock IC, Hutchinson JC et al (2020) Post-mortem microfocus computed tomography for noninvasive autopsies: experience in > 250 human fetuses. *Am J Obstet Gynecol* 224:103.e1-103.e15
 18. Dawood Y, Strijkers GJ, Limpens J et al (2020) Novel imaging techniques to study postmortem human fetal anatomy: a systematic review on microfocus-CT and ultra-high-field MRI. *Eur Radiol* 30:2280–2292
 19. Langan D, Shelmerdine S, Taylor A et al (2021) Impact of the COVID-19 pandemic on radiology appointments in a tertiary children's hospital: a retrospective study. *BMJ Paediatr Open* 5:e001210
 20. Harty MP, Gould SW, Harcke HT (2021) Navigating the perils and pitfalls of pediatric forensic postmortem imaging in the United States. *Pediatr Radiol* 51:1051–1060

Publisher's note Springer Nature remains neutral with regard to jurisdictional claims in published maps and institutional affiliations.

Springer Nature or its licensor holds exclusive rights to this article under a publishing agreement with the author(s) or other rightsholder(s); author self-archiving of the accepted manuscript version of this article is solely governed by the terms of such publishing agreement and applicable law.

Authors and Affiliations

Greg Chambers¹  · Susan C. Shelmerdine^{2,3,4}  · Michael Aertsen⁵  · Martha Dohna⁶  · Stacy K. Goergen^{7,8}  · Karl Johnson⁹ · Willemijn M. Klein¹⁰  · Elka Miller¹¹  · Gerald Pärtan¹²  · David Perry¹³ · Padma Rao¹⁴ · Claire Robinson¹⁵  · Joachim Stegmann¹⁶ · Ajay Taranath^{17,18}  · Elspeth Whitby¹⁹  · Rick R. van Rijn²⁰  · Owen J. Arthurs^{2,3,4} 

¹ Department of Radiology, Clarindon Wing, B Floor, Leeds General Infirmary, Leeds Teaching Hospital Trust, Leeds LS1 3EX, UK

² Great Ormond Street Hospital for Children NHS Foundation Trust, London, UK

³ UCL Great Ormond Street Institute of Child Health, London, UK

⁴ NIHR Great Ormond Street Hospital Biomedical Research Centre, London, UK

⁵ Department of Radiology, University Hospitals KU Leuven, Leuven, Belgium

⁶ Department of Paediatric Radiology, Hannover Medical School, Hannover, Germany

⁷ Monash Health Imaging, Clayton, VIC, Australia

⁸ Department of Imaging, School of Clinical Sciences, Monash University, Clayton, VIC, Australia

⁹ Radiology Department, Birmingham Women's and Children's Hospital NHS Foundation Trust, Birmingham, UK

¹⁰ Department of Medical Imaging, Radboud University Medical Centre, Nijmegen, The Netherlands

¹¹ Department of Medical Imaging, Children's Hospital of Eastern Ontario, University of Ottawa, Ottawa, ON, Canada

¹² Department of Radiology, Danube Hospital, Vienna, Austria

¹³ Radiology Department, National Women's Health and Starship Children's Hospital, Auckland City Hospital, Auckland, New Zealand

¹⁴ Department of Medical Imaging, Royal Children's Hospital, Melbourne, Australia

¹⁵ Department of Imaging, University Hospitals of Leicester NHS Trust, Leicester, UK

¹⁶ Department of Radiology, Children's Hospital Wilhelmstift gGmbH, Hamburg, Germany

¹⁷ Department of Medical Imaging, Women's and Children's Hospital, North Adelaide, South Australia

¹⁸ Faculty of Health and Medical Sciences, University of Adelaide, South Adelaide, Adelaide, Australia

¹⁹ University of Sheffield and Sheffield Teaching Hospitals Foundation Trust, Sheffield, UK

²⁰ Department of Radiology and Nuclear Medicine, Amsterdam UMC, Amsterdam, The Netherlands