

Received: 2020.10.09

Accepted: 2020.10.14

Available online: 2020.10.23

Published: 2020.12.18

Usefulness of a Balloon Catheter for Intraoperative Cholangiography During Living Donor Hepatectomy: A Product Investigation

Authors' Contribution:

Study Design A
Data Collection B
Statistical Analysis C
Data Interpretation D
Manuscript Preparation E
Literature Search F
Funds Collection G

ABCDEF **Katsunori Sakamoto**AB **Kohei Ogawa**BC **Kei Tamura**B **Miku Iwata**B **Akimasa Sakamoto**B **Takashi Matsui**B **Yusuke Nishi**B **Tomoyuki Nagaoka**B **Naotake Funamizu**B **Akihiro Takai**A **Yasutsugu Takada**

Department of Hepato-Biliary-Pancreatic and Breast Surgery, Ehime University
Graduate School of Medicine, Toon, Ehime, Japan

Corresponding Author: Katsunori Sakamoto, e-mail: sakamoto.katsunori.gq@ehime-u.ac.jp**Source of support:** Departmental sources

Background: Intraoperative cholangiography (IOC) during living donor liver procurement for liver transplantation is an essential procedure to avoid biliary complications in the donor and to assess the details of the biliary anatomy of the graft liver for the recipient. There are limitations to IOC using conventional methods, including that the contrast medium often passes immediately to the duodenum, making continuous enhancement of the peripheral biliary tree difficult. The usefulness of a thin balloon catheter with side holes located proximal to the balloon for IOC was evaluated.

Material/Methods: A pediatric angiography balloon catheter was used for IOC.

Results: The device was used in 2 living donors, and high-quality continuous images were easily achieved. There were no perioperative biliary complications in either donor.

Conclusions: A thin balloon catheter with side holes located proximal to the balloon catheter is useful in operations for both the donor and recipient because it allows more accurate division of the bile duct because of the clear IOC images.

MeSH Keywords: Cholangiography • Liver Transplantation • Living Donors

Full-text PDF: <https://www.annalsoftransplantation.com/abstract/index/idArt/929062>



673



1



6



6



Background

Living donor liver transplants are relatively common in Japan due to the scarcity of deceased donors [1]. Intraoperative cholangiography (IOC) during living donor liver procurement for liver transplantation is an essential procedure to avoid biliary complications in the donor and to assess the details of the biliary anatomy of the graft liver for the recipient [2]. However, there are limitations to IOC using conventional methods, including that the contrast medium often passes immediately to the duodenum, making continuous enhancement of the peripheral biliary tree difficult. Therefore, we considered the use of a balloon catheter with side holes located proximal to the balloon to be the best device for use in IOC. A pediatric angiography catheter appears to be suitable, and its usefulness for IOC was evaluated.

Material and Methods

Conventionally, we use a 4-Fr Atom utility tube (Atom Medical Corp., Saitama, Japan) for IOC, which is a simple single-lumen

catheter. On the other hand, a pediatric angiography catheter [Arrow Berman Angiographic Catheter, length 50 cm, external diameter 1.4 mm (4 Fr), Teleflex Incorporated, Wayne, PA, USA] (Figure 1A, 1B), which is a thin, radio-opaque, balloon catheter with side holes located proximal to the balloon, was evaluated for IOC.

In the procedure for IOC, the catheter was inserted from the cystic duct following cholecystectomy, and the tip of the catheter was placed in the common bile duct under radiographic guidance. IOC was performed after balloon dilation. The balloon catheter was also useful for the bile leak test after suturing of the stump of the remnant hepatic duct.

Results

This device was used in 2 living liver donors: 1 posterior sector graft donor and 1 right lobe graft donor. The insertion and positioning of the tip of the catheter were easily performed, and high-quality continuous images were achieved in both

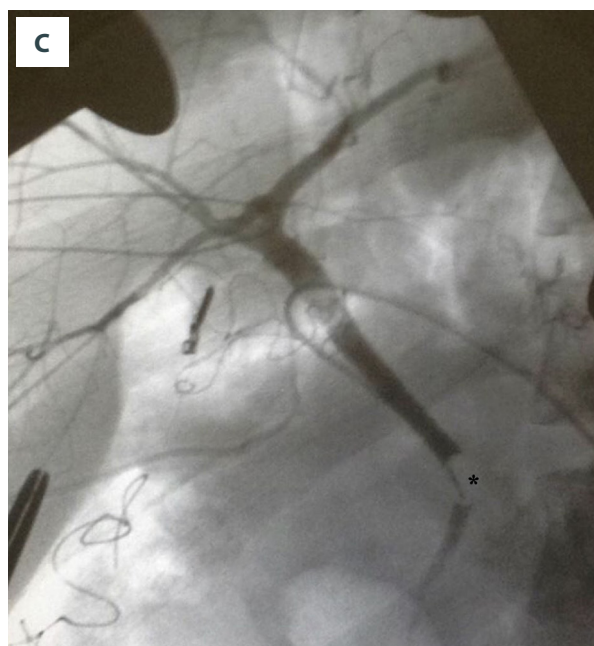
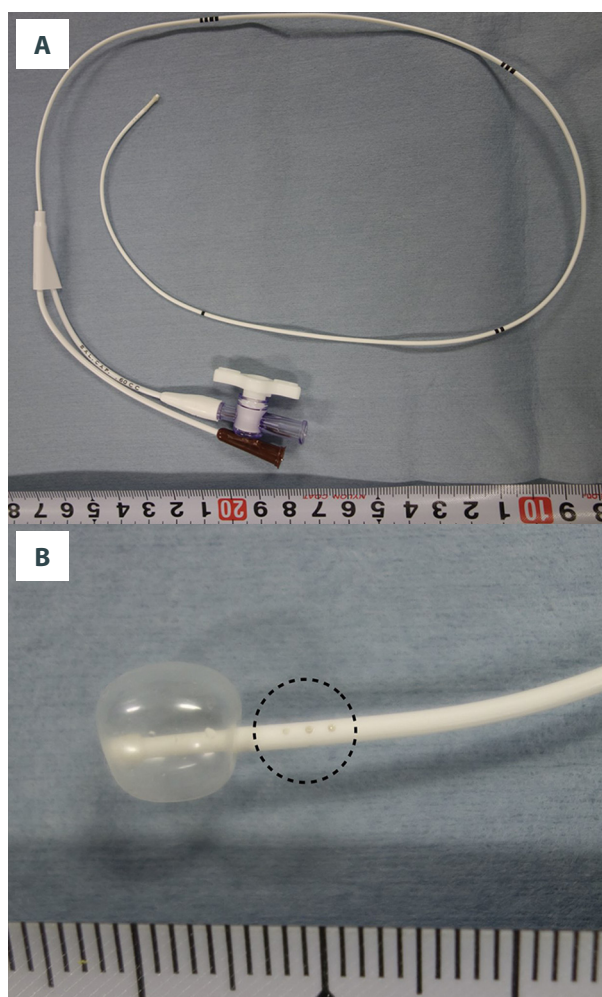


Figure 1. (A) Arrow Berman Angiographic Catheter, length 50 cm, external diameter 1.4 mm (4 Fr). The catheter is marked every 10 cm from the tip of the catheter. The air inlet to inflate the balloon has a stopcock. (B) Enlarged view of the tip of the catheter with the balloon inflated. The 3 side holes located at the proximal end of the balloon are circled with a dashed line. The balloon is inflated with 0.6 mL of air. (C) Intraoperative cholangiography of the living donor liver. The balloon is inflated in the distal bile duct (*). The biliary tree is peripherally enhanced.

donors (Figure 1C). The hepatic duct for graft liver was divided appropriately in both donors. There were no perioperative biliary complications in either donor.

Discussion

The use of a conventional, simple, single-lumen catheter for IOC has a major limitation in that the contrast medium often passes immediately to the duodenum, and clear biliary tree images are difficult to obtain. Although clamping of the distal bile duct may resolve the issue, it is not always useful in all donors, such as in those with a low-confluence cystic duct. In addition, minimal dissection of the remnant bile duct is recommended for living donors to avoid biliary ischemia. The Trendelenburg position during IOC also does not always provide enough information. A balloon catheter with side holes located proximal to the balloon may be useful for IOC because it resolves all of the above problems.

Balloon catheter use for IOC for liver surgery or common bile duct exploration has been reported previously [3], but the reported smallest conventional size catheter was 6 Fr (external diameter 2 mm), which is too large to cannulate healthy donors whose cystic ducts are very thin. Actually, a 6-Fr IOC balloon catheter could not be cannulated to the cystic duct during donor operations in our experience.

References:

1. Ogawa K, Takada Y: Living vs. deceased-donor liver transplantation for patients with hepatocellular carcinoma. *Transl Gastroenterol Hepatol*, 2016; 1: 35
2. Nakamura T, Tanaka K, Kiuchi T et al: Anatomical variations and surgical strategies in right lobe living donor liver transplantation: Lessons from 120 cases. *Transplantation*, 2002; 73(12): 1896–903
3. Kubo S, Sakai K, Kinoshita H, Hirohashi K: Intraoperative cholangiography using a balloon catheter in liver surgery. *World J Surg*, 1986; 10(5): 844–50
4. Ishizawa T, Saiura A, Kokudo N: Clinical application of indocyanine green-fluorescence imaging during hepatectomy. *Hepatobiliary Surg Nutr*, 2016; 5(4): 322–28
5. Kawaguchi Y, Ishizawa T, Masuda K et al: Hepato-biliary surgery guided by a novel fluorescent imaging technique for visualizing hepatic arteries, bile ducts, and liver cancers on color images. *J Am Coll Surg*, 2011; 212: e33–39
6. Hasegawa Y, Nitta H, Takahara T et al: Pure laparoscopic living donor hepatectomy using the Glissonean pedicle approach (with video). *Surg Endosc*, 2019; 33(8): 2704–9

The use of balloon catheters does, however, have some limitations. The catheter requires careful intraoperative positioning to avoid cystic duct or papilla of Vater injury secondary to balloon inflation. However, the pediatric angiography balloon catheter may also be useful in fluorescent cholangiography in which indocyanine green is injected into the cystic duct [4,5], since it may be retained in the bile duct when the balloon is inflated. Therefore, the balloon catheter may also be useful for laparoscopic donor hepatectomy in which the bile duct is often divided under fluorescent cholangiographic guidance [6]. Of course, it may also be useful for conventional liver and biliary surgery, not only for donor surgery, and it is expected to be made as a new low-cost device for IOC.

Conclusions

A thin balloon catheter with side holes located proximal to the balloon is useful in operations for both the donor and recipient because it allows more accurate division of the bile duct because of the clear IOC images.

Conflict of interest

None.