

Distribution of Different Sized Ocular Surface Vessels in Diabetics and Normal Individuals

Touka Banaee^{1,2}, MD; Hamidreza Pourreza³, MD; Hassan Doosti⁴, MD; Mojtaba Abrishami¹, MD
Asieh Ehsaei^{5,6}, PhD; Mohsen Basiry¹, MD; Reza Pourreza⁷, MD

¹Retina Research Center, Mashhad University of Medical Sciences, Mashhad, Iran

²Department of Ophthalmology, School of Medicine, Mashhad University of Medical Sciences, Mashhad, Iran

³Computer Engineering Department, School of Engineering, Ferdowsi University of Mashhad, Mashhad, Iran

⁴Department of Biostatistics and Epidemiology, School of Health, Mashhad University of Medical Sciences, Mashhad, Iran

⁵Refractive Error Research Center, Mashhad University of Medical Sciences, Mashhad, Iran

⁶Department of Optometry, School of Paramedical Sciences, Mashhad University of Medical Sciences, Mashhad, Iran

⁷Department of Electrical Engineering, University of Texas at Dallas, Richardson, USA

Abstract

Purpose: To compare the distribution of different sized vessels using digital photographs of the ocular surface of diabetic and normal individuals.

Methods: In this cross-sectional study, red-free conjunctival photographs of diabetic and normal individuals, aged 30-60 years, were taken under defined conditions and analyzed using a Radon transform-based algorithm for vascular segmentation. The image areas occupied by vessels (AOV) of different diameters were calculated. The main outcome measure was the distribution curve of mean AOV of different sized vessels. Secondary outcome measures included total AOV and standard deviation (SD) of AOV of different sized vessels.

Results: Two hundred and sixty-eight diabetic patients and 297 normal (control) individuals were included, differing in age (45.50 ± 5.19 vs. 40.38 ± 6.19 years, $P < 0.001$), systolic (126.37 ± 20.25 vs. 119.21 ± 15.81 mmHg, $P < 0.001$) and diastolic (78.14 ± 14.21 vs. 67.54 ± 11.46 mmHg, $P < 0.001$) blood pressures. The distribution curves of mean AOV differed between patients and controls (smaller AOV for larger vessels in patients; $P < 0.001$) as well as between patients without retinopathy and those with non-proliferative diabetic retinopathy (NPDR); with larger AOV for smaller vessels in NPDR ($P < 0.001$). Controlling for the effect of confounders, patients had a smaller total AOV, larger total SD of AOV, and a more skewed distribution curve of vessels compared to controls.

Conclusion: Presence of diabetes mellitus is associated with contraction of larger vessels in the conjunctiva. Smaller vessels dilate with diabetic retinopathy. These findings may be useful in the photographic screening of diabetes mellitus and retinopathy.

Keywords: Computer-assisted Image Processing; Conjunctiva; Diabetes Mellitus Type 2; Eye

J Ophthalmic Vis Res 2017; 12 (4): 361-7

Correspondence to:

Touka Banaee, MD. Eye Research Center,
Khatam-Al-Anbia Hospital, Abutaleb Junction, Ghareni
Blvd., 91959 Mashhad, Iran.
E-mail: tkbanaee@gmail.com

Received: 02-12-2016

Accepted: 10-05-2017

INTRODUCTION

Diabetes mellitus (DM) is a metabolic systemic disease with microvascular and macrovascular complications.

This is an open access article distributed under the terms of the Creative Commons Attribution-NonCommercial-ShareAlike 3.0 License, which allows others to remix, tweak, and build upon the work non-commercially, as long as the author is credited and the new creations are licensed under the identical terms.

For reprints contact: reprints@medknow.com

How to cite this article: Banaee T, Pourreza H, Doosti H, Abrishami M, Ehsaei A, Basiry M, *et al.* Distribution of different sized ocular surface vessels in diabetics and normal individuals. *J Ophthalmic Vis Res* 2017;12:361-7.

Access this article online

Quick Response Code:



Website:

www.jovr.org

DOI:

10.4103/jovr.jovr_238_16

The most prominent well-known ocular complication of DM is retinopathy. The presence of retinopathy is associated with diabetic nephropathy and cardiopathy, and the microvascular complications of diabetes seem to progress in parallel in different tissues.^[1,2] Of the various body organs and tissues affected by microangiopathy, retina is the major site where microvasculature can be seen and studied clinically. However, this examination requires utilization of expensive and complicated instruments, along with sufficient expertise to perform ophthalmoscopy and fundus photography. Microvasculature is also readily visible to study in the conjunctiva, which is easily accessible, and changes in conjunctival vasculature in diabetes mellitus have previously been reported.^[3-7]

Studying conjunctival vessels is difficult, given the fast response of the vessels to irritations and the diversity of diseases and irritants that affect them. Recently, with the advent of digital photography and image processing, there has been a resurgence of interest in the study of conjunctival vessels.^[6-13] We previously described an algorithm for vessel extraction and used it to assess the distribution of different sized vessels in the normal ocular surface.^[8] In the current study, we sought to compare a relatively large number of ocular surface images from diabetic patients with those from normal individuals, to assess the effect of diabetes and stage of diabetic retinopathy (DR) on the distribution of different sized vessels in the ocular surface.

METHODS

In this cross-sectional case-control study, successive diabetic patients, aged 30-60 years, presenting to our outpatient clinics of Khatam-Al-Anbia eye hospital between March 2009 and March 2011, were enrolled. Diabetes type was not specifically ascertained by the treating physicians, but was classified by the study researchers based on the patient's age at the disease onset. Normal individuals, in the same age range, seeking corrective glasses or accompanying ophthalmic patients, were enrolled as controls. Potential participants were excluded if they had previously undergone intraocular surgeries involving manipulation of the conjunctiva, such as extra-capsular cataract extraction or scleral buckling. Potential participants were also excluded if they had the following: severe blepharitis, large pterygium, conjunctivitis, episcleritis, scleritis, uveitis, any condition causing red-eye or if they used contact lenses. Mild lid crusting was allowed. Potential participants were also excluded if they had a history of anemia, dysthyroidism, rheumatic disorder, allergy, presence of hypertension (including high blood pressure measurement during examination), or abnormal fasting blood sugar (FBS). Written informed consent was obtained from all participants. The study

was approved by the ethics committee of Mashhad University of Medical Sciences, and followed the tenets of the Declaration of Helsinki.

After taking a complete medical history, all participants underwent measurement of height, weight, and blood pressure. Conjunctiva photography was performed afterwards, followed by a complete ophthalmic examination, including funduscopy with dilated pupils. Stage of diabetic retinopathy in diabetic patients was determined by vitreoretinal specialists. A panel of laboratory tests were performed, including FBS measurement and complete blood count (CBC) in controls, and CBC as well as measurement of FBS, Hemoglobin A1C (HbA1C), blood urea nitrogen (BUN), and creatinine levels in patients.

Digital red-free conjunctival images of the superior conjunctiva of the right eye were taken with a YZ5S digital slit lamp microscope (Suzhou 66 Vision-Tech Co., Ltd., Suzhou, Jiangsu, P.R. China) by a trained photographer. The photography settings were as follows: ambient light condition; five-volt slit-lamp input; red-free filter and diffuser; illumination arm at 45 degrees to the microscope; diffuse illumination (8 mm circle); 25× magnification. Patients were instructed to take an extreme down gaze. Lids were pulled apart with minimum pressure by the photographer. Photography was performed as quickly as possible to avoid dryness and irritation to the conjunctiva.

Photographs were reviewed by one of the researchers (TB), and poor quality images (images that were unfocused, with motion artifacts or excessive light reflex) were excluded. Photographs were 3456 × 2304 pixels in size, in PNG format, and were not cropped for image analysis.

Algorithm

A previously described algorithm was used for vessel extraction in the conjunctival images.^[14] This local Radon transform-based algorithm extracts blood vessels. In this algorithm, the input image is first divided into overlapping windows, after which the Radon transform of each window is computed. Vessel shape in each window is determined, based on the process of Radon space. The result is a binary image as a vessel map in which white vessels are shown on a black background. Measurements of the vessel diameters and computation of vessel density statistics for different diameters are based on a consequent morphological erosion process. This method lacks sufficient resolution when measuring diameters, as vessels with $2n$ - and $2n + 1$ -pixel widths are detected as having the same diameter. Therefore, changes were made to this step of the algorithm. In the new version, an algorithm based on Maurer's distance transform^[15] was developed. This transformation computes Euclidean distance of vessel pixels from

backgrounds in the vessel map image. Analyses of these distances easily provide vessel diameters. Several tests on synthetic images consisting of lines of different diameters in various directions indicated an accuracy of 98.5% for this algorithm. Area occupied by vessels (AOV) of different sizes is the output of the algorithm; AOV represents a ratio of the image pixels occupied by vessels of different diameters to the total pixels in the picture. Based on our previous findings, a conversion factor of 18 μm is required for each pixel within each photograph.^[4]

Statistical Analysis

Participants were classified by condition (i.e., diabetes status and diabetic retinopathy status; DM/DR) into four groups as follows: group 0, controls; group 1, diabetic patients without diabetic retinopathy (no DR); group 2, diabetic patients with non-proliferative diabetic retinopathy (NPDR); group 3, diabetic patients with proliferative diabetic retinopathy (PDR).

Numerical variables, including age, FBS, systolic blood pressure (SBP), diastolic blood pressure (DBP), hematocrit (Hct), weight, height, and BMI, were compared using Student's *t*-test. Gender was treated as a categorical variable and was compared using the Chi-square test. Normality of data was evaluated using Shapiro-Wilks *W* test.

For all tests, *P* values of less than 0.05 were considered statistically significant. For *post hoc* tests, *P* values of less than 0.0125 were accepted as statistically significant. IBM SPSS Statistics for Windows version 21 (IBM Corp. Armonk, NY) was used for statistical analyses.

Per-group Analysis

The mean AOV of each pixel size was calculated for each group, and distributions were compared across the groups using Kruskal-Wallis test. Pairwise comparison of distributions was evaluated using the two independent sample Kolmogorov-Smirnov test.

Per-case Analysis

As the AOV of different pixels for each person were not normally distributed, we calculated the Pearson's second coefficient of skewness to represent the degree of skewness of data distribution for each participant using the formula: $[3(\text{mean} - \text{median})/\text{standard deviation (SD)}]$.

Total AOV, representative of the ratio of each image occupied by vessels, was calculated as the sum of AOV of different sized pixels in each individual.

A multiple linear regression model, including age, SBP, and DBP (confounding factors), and stage of DM/DR of the worst eye (normal=0, no DR=1, NPDR=2, PDR=3) as predictor variable was constructed, and

Pearson's second coefficient of skewness, total AOV, and the SD of total AOV were successively placed as dependent variables. A backward elimination method was used in each regression model.

In the model with Pearson's second coefficient of skewness as the dependent variable, only the stage of DM/DR remained significant. Thus, this parameter was compared across the four groups by ANOVA and *post hoc* Tukey's tests.

As age remained a significant confounder, in the regression models with total AOV and SD of total AOV as dependent variables, pairwise comparisons across the four groups was conducted using a linear regression model.

To explore the effects of HbA1C on total AOV, and SD of total AOV, a linear regression model was constructed including only diabetic patients (groups 1-3). Total AOV and SD of total AOV were successively placed in the model as dependent variables. Age, SBP, DBP, and HbA1C were entered as confounders, and stage of DR (no DR, NPDR, and PDR) was entered as the predictor variable.

RESULTS

Three hundred and thirty-four diabetic patients and 343 normal individuals, aged 30-60 years, were enrolled. Two hundred and sixty eight patients and 297 controls had good-quality photographs for analysis. The 268 patients included, 15 (5.59%) type 1 and 253 (94.4%) type 2 diabetes mellitus patients. Demographic data of participants are presented in [Table 1]. There were significant differences between patients and controls in terms of age, SBP, arterial blood pressure, DBP, and FBS levels. The algorithm detected vessel diameters from 4-53 pixels (72-954 μm), and the corresponding AOV were obtained.

Results of Per-group Analysis

The distribution curve of mean AOV of pixels in controls (group 0) vs. diabetic patients (groups 1-3 cumulatively), and of diabetic patients with different stages of diabetic retinopathy (groups 1-3), are shown in [Figures 1 and 2] respectively.

The distribution of mean AOV of pixels was significantly different between the four groups. ($P < 0.001$ [Kruskal-Wallis test]). Differences were observed between controls and diabetic patients (groups 1-3 cumulatively; $P < 0.001$ [Kolmogorov-Smirnov test]), controls and diabetic patients without DR (group 1; $P < 0.001$), as well as diabetic patients without DR (group 1) and those affected by NPDR (group 2; $P < 0.001$). There was no significant difference between diabetic patients with NPDR and those with PDR (groups 2 and 3; $P = 1.0$).

Table 1. Demographic and biometric characteristics of patients and controls

	Controls	Diabetes Patients	P ¹	No DR	P ²	NPDR	P ³	PDR	P ⁴
Number	297	268		160		100		44	
Age (years)	40.38±6.194	45.50±5.193	<0.001	44.64±5.356	<0.001	46.21±5.033	0.23	47.39±4.108	1.00
Female (%)	160 (53.87)	189 (70.52)	0.354	115 (71.87%)	0.005	53 (53%)	0.002	21 (47.72%)	0.591
Systolic Blood Pressure (mmHg)	119.21±15.81	126.37±20.25	<0.001	123.31±21.14	0.142	127.95±19.77	0.27	133.86±15.51	0.43
Diastolic Blood Pressure (mmHg)	67.54±11.46	78.14±14.21	<0.001	76.96±14.83	<0.001	79.4±13.47	0.84	79.54±13.46	1.00
Mean arterial blood pressure (mmHg)	84.76±10.80	94.22±13.84	<0.001	92.41±14.35	<0.001	95.58±13.49	0.28	97.65±11.90	1.00
Height (cm)	163.31±10.09	164.14±8.04	0.28	163.16±7.96	1.00	165.18±8.34	0.49	165.32±7.29	1.00
Weight (kg)	71.50±15.32	72.26±11.96	0.5	71.95±13.38	1.00	71.52±10.02	1.00	75.07±10.32	0.9
BMI (kg/m ²)	27.21±10.04	26.88±4.45	0.60	27.03±4.79	1.00	26.29±3.68	1.00	27.64±4.7	1.00
Hemoglobin (g/dl)	13.42±1.25	13.36±1.33	0.613	13.50±1.19	1.00	13.28±1.51	1.00	12.98±1.35	1.00
FBS (mg/dl)	77.96±18.25	166.37±61.17	<0.001	158.25±58.2	<0.001	173.14±59.45	0.14	181.91±73.5	1.00
Serum Creatinine (mg/dl)	NA	1.18±1.00	NA	1.14±1.08	N/A	1.12±0.27	0.30	1.23±0.48	0.26
HbA1C (%)	NA	8.65±1.87	NA	8.09±2.00	N/A	9.4±1.68	<0.001	8.89±1.82	1.00

DR, diabetic retinopathy; FBS, fasting blood sugar; HbA1C, hemoglobin A1C; NPDR, non-proliferative diabetic retinopathy; PDR, proliferative diabetic retinopathy. P¹: P value of difference between controls and diabetic patients. P²: P value of difference between controls and patients without DR. P³: P value of difference between patients without DR and patients with NPDR. P⁴: P value of difference between patients with NPDR and patients with PDR

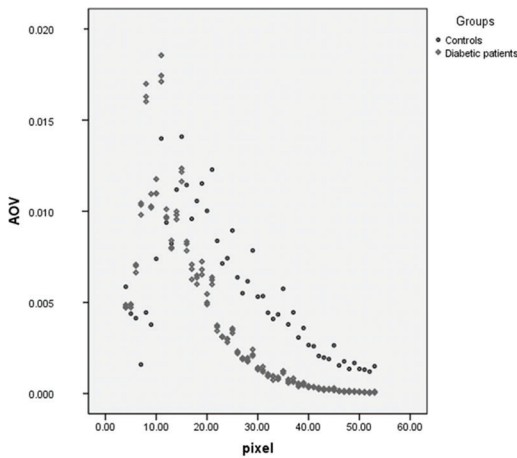


Figure 1. Distribution curve of mean area occupied by vessels (AOV) of different pixels in normal individuals and diabetic patients.

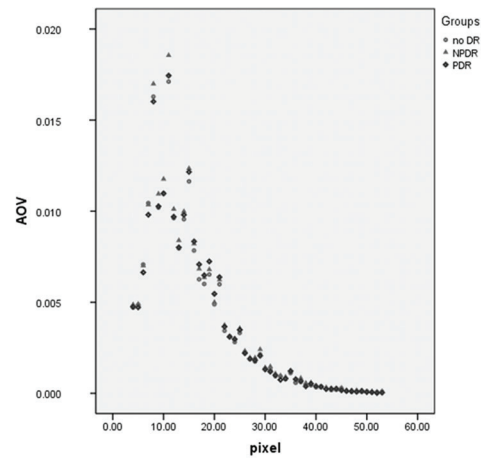


Figure 2. Distribution curve of mean areas occupied by vessels (AOV) of different pixels in diabetic patients with different stages of diabetic retinopathy (groups 1, 2, and 3).

Results of Per-case Analysis

Total AOV, SD of total AOV, and Pearson’s second coefficient of skewness for the four groups are presented in [Table 2].

A multiple linear regression model was constructed including age, SBP, and DBP as confounders, stage of DM/DR of the worst eye as the predictor variable, and Pearson’s second coefficient of skewness as the dependent variable. The results showed that only stage of DM/DR remained a significant factor. Backward elimination confirmed this finding ($P < 0.001$, lack of fit = 0.246, $R^2 = 0.477$).

ANOVA test showed that the second coefficient of skewness of Pearson was significantly different across the 4 groups of DM/DR ($P < 0.001$). It was smaller in the control group (group 0) than all 3 other groups of diabetic patients with different stages of DR (groups 1-3) ($P < 0.001$, Tukey *post hoc* test) but was similar between diabetic patients with or without DR (groups 1-3).

In a similar regression model with total AOV as the dependent variable, after backward elimination, age ($P = 0.01$) and stage of DM/DR ($P < 0.001$) remained

Table 2. Total areas occupied by vessels, standard deviation of areas occupied by vessels, and Pearson's second coefficient of skewness for the distribution of different sized pixels in the groups of participants

	Controls	Diabetic patients (Total)	Diabetic patients without DR	Diabetic patients with NPDR	Diabetic patients with PDR
Total AOV	5564.66×10 ⁻⁶ ±1053.60×10 ⁻⁶	3893.22×10 ⁻⁶ ±694.26×10 ⁻⁶	3789.59×10 ⁻⁶ ±722.31×10 ⁻⁶	4010.62×10 ⁻⁶ ±662.35×10 ⁻⁶	3916.95×10 ⁻⁶ ±660.66×10 ⁻⁶
SD of AOV	4009.42×10 ⁻⁶ ±1114.12×10 ⁻⁶	4628.25×10 ⁻⁶ ±854.92×10 ⁻⁶	4546.14×10 ⁻⁶ ±857.38×10 ⁻⁶	4884.36×10 ⁻⁶ ±927.97×10 ⁻⁶	4545.33×10 ⁻⁶ ±775.62×10 ⁻⁶
Pearson's second coefficient of skewness	552.96×10 ⁻³ ±413.56×10 ⁻³	1263.88×10 ⁻³ ±403.67×10 ⁻³	1270.33×10 ⁻³ ±405.16×10 ⁻³	1315.59×10 ⁻³ ±382.71×10 ⁻³	1235.45×10 ⁻³ ±383.33×10 ⁻³

AOV, areas occupied by vessels; DR, diabetic retinopathy; NPDR, non-proliferative diabetic retinopathy; PDR, proliferative diabetic retinopathy; Data presented as mean±standard deviation (SD)

significant (lack of fitness = 0.883, R² = 0.504). Given the effect of age, the regression model revealed significant difference between all groups; between controls and diabetic patients without DR (*P* < 0.001); between diabetic patients without DR and those with NPDR (*P* < 0.001); between diabetic patients with NPDR and those with PDR (*P* = 0.001). As the estimation coefficient of age was negative, it can be deduced that if the state of DM/DR is fixed, increase in age is associated with a decrease in mean total AOV (*P* = 0.010).

In a similar regression model with SD of total AOV as the dependent variable, after backward elimination, age (*P* = 0.005) and stage of DM/DR (*P* < 0.001) remained significant (lack of fitness = 0.972, R² = 0.114). Given the effect of age, the regression model revealed significant difference between controls and diabetic patients without DR (*P* < 0.001) and between diabetic patients without DR and with NPDR (*P* = 0.001), but not between diabetic patients with NPDR and with PDR (*P* = 0.259).

As total AOV and SD of total AOV were different between various stages of DR, to determine the effect of HbA1C on these two parameters, linear logistic regression with backward elimination was performed on diabetic patients only (groups 1-3). This step was limited to diabetic patients because HbA1C levels were not available for normal participants. In this model, including age, SBP, DBP, Hct, and HbA1C as confounders, and stage of DR as the predictor variable, total AOV and SD of total AOV were placed successively as dependent variables. None of the confounders had any significant effect on the dependent variables in addition to stage of DR, in any of these models (*P* > 0.05).

DISCUSSION

The results of the current study show that vessels on the ocular surface of diabetic eyes are different compared to normal eyes. The distribution curve of AOV of different sized vessels in normal individuals is less skewed toward smaller vessels compared to diabetic patients. It seems that development of diabetes is associated with the contraction of large-sized vessels, and an abundance of small-sized vessels (which may either be due to dilation of small-sized vessels, or the contraction of larger vessels reducing their diameter). The net result is a smaller total AOV of pixels in diabetic patients (groups 1-3), relative to normal individuals.

Another finding of the current study is that the distribution curve of vessels in conjunctiva is different between diabetic patients without and with retinopathy (either NPDR or PDR). Patients with NPDR have a significantly larger total AOV relative to diabetic patients without DR. Based on the data in [Figure 2], it appears that this difference is caused by dilation of small-sized vessels 10-20 pixels in diameter; as there is an overlap of the curves in areas of larger vessels, the

abundance of smaller vessels does not seem to be due to contraction of larger vessels.

Total AOV in patients with PDR is smaller than that in patients with NPDR [Figure 2]. The differences seem to be in the region of small-sized vessels, with AOV of vessels 9-15 pixels in diameter being smaller in PDR patients relative to NPDR patients. The reverse is true for vessels 16-23 pixels in diameter (i.e., larger AOV of these sizes of vessels in PDR cases). With progression of DR to the proliferative stage, there may be a loss of very small vessels along with dilation of small- to medium-sized vessels, with the magnitude of the former being larger than the latter (i.e., a smaller total AOV in PDR patients relative to NPDR cases). Despite the significant difference between total AOV of diabetic patients with NPDR and PDR ($P = 0.001$), the distribution curve of mean AOV of pixels was not significantly different between these two groups ([Kolmogorov-Smirnov test]). No systemic factors, including HbA1C, played a role in producing the difference between total AOV at different stages of DR.

These results reconfirm our previous study on the conjunctiva of normal individuals, showing that medium-sized vessels are the most abundant in the conjunctiva. However, contrary to our previous findings, all participants of this study showed an age-related decrease in total AOV.^[8] This correlation was not found considering only diabetic individuals either and may be due to the larger number of cases included in the cumulative analysis. With the new algorithm settings, accuracy for detection of vessel walls and curvatures increased; thus, the plots of distribution of AOV of different sized vessels, both in patients and controls, are skewed to the left, somewhat different from the curves in the previous study.

The Pearson's second coefficient of skewness is an index of the degree of skewness of the data. It was significantly smaller in the ocular surface of normal individuals, relative to the same index in diabetic patients, and there was a leftward shift of the distribution curve in diabetic ocular surfaces relative to the normal conjunctiva. This means that smaller vessels are more abundant and larger vessels are less frequent in the diabetic conjunctiva. As previously stated, this may be due to contraction of larger vessels resulting in larger AOV for smaller vessels; as contracted vessels have smaller diameters and are counted as small vessels by the algorithm. Dilation of small vessels themselves may or may not have occurred. These changes only correlated with the presence of diabetes in a logistic regression model. Thus, development of diabetes is accompanied by contraction of larger conjunctival vessels, which translates into a smaller total area occupied by vessels in the diabetic conjunctiva. This finding is consistent with the finding of lower vascular density in the conjunctiva of diabetic patients relative to normal individuals, in the study by Owen and colleagues.^[3] A larger SD of

total AOV in diabetic patients may be indicative of the heterogeneous nature of this group of patients, relative to normal individuals.

There are few studies reporting changes in the microcirculation of conjunctiva in diabetic patients. Some of these studies used conjunctival images,^[3,6] and some used videos of the conjunctiva, mainly with the aim of studying the hemodynamics of conjunctival blood flow.^[4,5,7,13] Khansari et al used an algorithm for fine structural analysis of conjunctival microvasculature in images, based on ordinary least square regression and Fisher's linear discriminant analysis, and reported very good discriminatory power for the method for classifying images into groups based on the level of retinopathy. The authors stated that there are more than 10^6 features in the image that may be used by the algorithm for classification.^[6] Although very impressive, and possibly practical for use in future instruments, their method does not provide data regarding the changes that occur in diabetes in the conjunctival microvasculature. Owen et al not only found lower vascular densities and higher mean diameters of vessels in the diabetic compared to normal conjunctiva,^[3] but also decreased tortuosity of larger vessels and increased tortuosity of smaller vessels in diabetic conjunctiva.^[16]

Some studies were performed with the use of computer-assisted intravital microscopy (CAIM) to evaluate the shape and diameter of conjunctival vessels, as well as the hemodynamics of conjunctival microcirculation in diabetic eyes.^[4,5,7] They found a higher severity index of previously described vessel abnormalities in patients with diabetes, relative to controls. These abnormalities were associated with HgA1C, but not duration of diabetes. There was a correlation between conjunctival vessel abnormalities and severity of diabetic retinopathy in patients with type 2 diabetes.^[5,7] However, the results of studies with CAIM cannot directly be compared with the results of the current study, as the outputs are completely different.

In a case report, Stuebiger et al reported the use of a retina function imager, an instrument for imaging the hemodynamics of the retinal circulation, to explore conjunctival hemodynamics in diabetic patients.^[17] This study showed feasibility of obtaining a noninvasive capillary perfusion map of the conjunctiva with this machine.

Aside from different methods, the area of conjunctiva studied also differs in various studies, so their results cannot be directly compared. Most studies used temporal conjunctiva for imaging. We imaged the superior conjunctiva, because it seems that superior conjunctiva is less affected by conditions such as irritations and dry eye syndrome, which is common in diabetes.^[18] Presence of subclinical dry eye may have a confounding effect on the results of studies sampling the exposed areas of the conjunctiva.

The Conjunctiva of the right eye was photographed to make the imaging condition the same for all participants. But to determine the state of DM/DR, the condition of eye with more advanced retinopathy was considered, because progression of retinopathy is the result of longstanding hyperglycemia and the eye with more advanced retinopathy is a better representative of the degree of this chronic insult.

The large number of cases and the quantitative method of evaluation are the strengths of the current study. However, inherent difficulties with conjunctival imaging, including blur incurred by a curved surface, light reflections, and eye irritation, caused inaccuracies which may be corrected by refining the method of photography and image analysis. Another major weakness of the study is that we did not consider duration of diabetes and its effect on the distribution curves. This was due to inaccuracies related to patient recall, and we did not have access to more dependable data. This important factor should be considered in future studies. Another weakness of the current study was the difference in age between the control and diabetic groups. Moreover, simple clinical evaluation for absence of dry eye and lack of sufficient objective testing are other important limitations of the current study.

This study confirmed the results of previous studies; we found a difference between the vascular structures of diabetic and normal conjunctivae. However, results of relevant studies conducted to date are not directly comparable and are somewhat inconsistent. Additional studies are required to clarify the changes in conjunctival vessels that occur with development of diabetes. Use of optical coherence tomography angiography (OCT-A) and adaptive optics scanning laser ophthalmoscopy angiography may enhance the accuracy of studies on conjunctival vessels, but the curvature of the globe surface remains a large obstacle that mandates the use of customized instruments.

In summary, it appears that presence of diabetes is accompanied by contraction of larger conjunctival vessels. With development of diabetic retinopathy, dilation of smaller vessels of conjunctiva occurs. These findings may have implications in the future photographic screening of diabetes mellitus and diabetic retinopathy.

Financial Support and Sponsorship

Nil.

Conflicts of Interest

There are no conflicts of interest.

REFERENCES

1. Kotlarsky P, Bolotin A, Dorfman K, Knyazer B, Lifshitz T, Levy J. Link between retinopathy and nephropathy caused by complications of diabetes mellitus type 2. *Int Ophthalmol* 2015;35:59-66.
2. Mottl AK, Pajewski N, Fonseca V, Ismail-Beigi F, Chew E, Ambrosius WT, et al. The degree of retinopathy is equally predictive for renal and macrovascular outcomes in the ACCORD Trial. *J Diabetes Complications* 2014;28:874-879.
3. Owen CG, Newsom RS, Rudnicka AR, Ellis TJ, Woodward EG. Vascular response of the bulbar conjunctiva to diabetes and elevated blood pressure. *Ophthalmology* 2005;112:1801-1808.
4. Cheung AT, Price AR, Duong PL, Ramanujam S, Gut J, Larkin EC, et al. Microvascular abnormalities in pediatric diabetic patients. *Microvasc Res* 2002;63:252-258.
5. Cheung AT, Ramanujam S, Greer DA, Kumagai LF, Aoki TT. Microvascular abnormalities in the bulbar conjunctiva of patients with type 2 diabetes mellitus. *Endocr Pract* 2001;7:358-363.
6. Khansari MM, O'Neill W, Penn R, Chau F, Blair NP, Shahidi M. Automated fine structure image analysis method for discrimination of diabetic retinopathy stage using conjunctival microvasculature images. *Biomed Opt Express* 2016;7:2597-2606.
7. To WJ, Telander DG, Lloyd ME, Chen PC, Cheung AT. Correlation of conjunctival microangiopathy with retinopathy in type-2 diabetes mellitus (T2DM) patients. *Clin Hemorheol Microcirc* 2011;47:131-141.
8. Banaee T, Ehsaei A, Pourreza H, Khajedaluae M, Abrishami M, Basiri M, et al. Distribution of normal superficial ocular vessels in digital images. *Cont Lens Anterior Eye* 2014;37:11-15.
9. Fukushima A, Tomita T. Image analyses of the kinetic changes of conjunctival hyperemia in histamine-induced conjunctivitis in Guinea pigs. *Cornea* 2009;28:694-698.
10. Koutsiaris AG, Tachmitzi SV, Batis N, Kotoula MG, Karabatsas CH, Tsironi E, et al. Volume flow and wall shear stress quantification in the human conjunctival capillaries and post-capillary venules *in vivo*. *Biorheology* 2007;44:375-386.
11. Koutsiaris AG, Tachmitzi SV, Papavasileiou P, Batis N, Kotoula MG, Giannoukas AD, et al. Blood velocity pulse quantification in the human conjunctival pre-capillary arterioles. *Microvasc Res* 2010;80:202-208.
12. Nagel E, Vilser W, Lanzl I. Online human conjunctival vessel diameter analysis. A clinical-methodical study. *Clin Hemorheol Microcirc* 2003;28:221-227.
13. Jiang H, Zhong J, DeBuc DC, Tao A, Xu Z, Lam BL, et al. Functional slit lamp biomicroscopy for imaging bulbar conjunctival microvasculature in contact lens wearers. *Microvasc Res* 2014;92:62-71.
14. Pourreza R, Banaee T, Pourreza H, Kakhki R, Gelbukh A, Morales E. A radon transform based approach for extraction of blood vessels in conjunctival images MICAI 2008: Advances in Artificial Intelligence. *Berlin Heidelberg: Springer*; 2008. p. 948-956.
15. Maurer Jr CR, Qi R, Raghavan V. A linear time algorithm for computing exact Euclidean distance transforms of binary images in arbitrary dimensions. *Pattern Analysis and Machine Intelligence* 2003;25:265-270.
16. Owen CG, Newsom RS, Rudnicka AR, Barman SA, Woodward EG, Ellis TJ. Diabetes and the tortuosity of vessels of the bulbar conjunctiva. *Ophthalmology* 2008;115:e27-32.
17. Stuebiger N, Smiddy W, Wang J, Jiang H, DeBuc DC. Assessment of conjunctival microangiopathy in a patient with diabetes mellitus using the retinal function imager. *J Clin Exp Ophthalmol* 2015;6.
18. Zhang X, Zhao L, Deng S, Sun X, Wang N. Dry Eye Syndrome in patients with diabetes mellitus: Prevalence, etiology, and clinical characteristics. *J Ophthalmol* 2016;2016:8201053.