

Research Article

Analysis of Clinical Manifestations and Imaging of COVID-19 Patients in Intensive Care

Lihong Li,¹ Yongwei Yao,² Xiaofei Feng,³ Lingling Chen,³ Rui Wu,⁴ Yuejin Chang,¹ Qiaoqin Lou,¹ Jinbo Pan ,⁵ and Zhangli Wang ⁶

¹The Second Affiliated Hospital of Zhejiang Chinese Medical University, Xinhua Hospital of Zhejiang Province, Hangzhou 310005, China

²Oncology Department, Hangzhou Third Hospital, Hangzhou 310009, China

³Emergency Department, Hangzhou Third Hospital, Hangzhou 310009, China

⁴Nephropathy Department, Hangzhou Third Hospital, Hangzhou 310009, China

⁵ICU, Hangzhou Third Hospital, Hangzhou 310009, China

⁶Hebei Yanda Hospital, Langfang 065200, China

Correspondence should be addressed to Jinbo Pan; panjinbo19830726@163.com and Zhangli Wang; hbydsjkwzwl@163.com

Received 30 March 2022; Revised 13 May 2022; Accepted 18 May 2022; Published 23 June 2022

Academic Editor: Mohammad Farukh Hashmi

Copyright © 2022 Lihong Li et al. This is an open access article distributed under the Creative Commons Attribution License, which permits unrestricted use, distribution, and reproduction in any medium, provided the original work is properly cited.

Objective. The study aims to summarize and analyze the clinical and CT findings of severe COVID-19 patients. **Methods.** From February 11 to March 31, 2020, 61 COVID-19 patients in intensive care in the E1-3 ward of Tongji Hospital were analyzed retrospectively. **Results.** The main clinical manifestations were cough, expectoration in 56 cases (91.8%), shortness of breath, chest tightness in 48 cases (78.7%), fever in 61 cases (100%), muscle ache and weakness in 40 cases (65.6%), diarrhea or vomiting in 8 cases (13.1%), and headache in 4 cases (6.6%). After admission, the leukocyte count was normal in 40 cases (57.7%), higher in 9 cases (15.4%), and lower in 12 cases (26.9%). The lymphocyte count decreased in 53 cases (86.9%). CRP was increased in 29 cases (47.5%); PCT was increased in 15 cases (24.6%); ESR was increased in 38 cases (62.3%); D-dimer increased in 39 cases (63.9%); ALT/AST increased in 40 cases (65.6%); CK/CK-MB increased in 8 cases (13.1%); troponin I increased in 6 cases (9.8%); NT-proBNP increased in 35 cases (57.4%); IL-1 increased in 5 cases (8.2%); IL-2 receptor increased in 28 cases (45.9%); IL-6 increased in 23 cases (37.7%); IL-8 increased in 15 cases (24.6%); IL-10 increased in 12 cases (19.7%); and NTF increased in 22 cases (36.1%). The chest CT images showed that 38 cases (65.5%) of right lung lesions were more extensive than those of left lung lesions, 20 cases (34.5%) of left lung lesions were more extensive than those of right lung lesions, 42 cases (72.5%) of lower lobe lesions were more extensive than those of upper lobe lesions, 6 cases (10.3%) of upper lobe lesions were more extensive than those of lower lobe lesions, and 10 cases (17.2%) of upper and lower part lesions were roughly the same. Ground-glass opacity (GGO) was found in 12 cases (20.7%); GGO with focal consolidation in 38 cases (65.5%); small patchy edge fuzzy density increased in 24 cases (41.4%); large consolidation in 20 cases (34.5%); reticular or fibrous cord in 54 cases (93.1%); and air bronchogram in 8 cases (13.8%). **Conclusions.** COVID-19 patients in intensive care have no specific clinical manifestation and CT findings. However, analysis and summary of relevant data can help us assess the severity of the disease, decide the timing of treatment, and predict prognosis.

1. Introduction

As of April 14, 2020, coronavirus disease 2019 (COVID-19) has spread across 185 countries/regions, infected more than 1.9 million people, and killed 120 thousands of people. To this day, COVID-19, which is “not very impressive,” can cause such a great “lethality” in the progress of science and

technology and the highly developed medical science. The reason is that we do not know enough about the “little virus” or have enough imagination about its impact. All we can do now is to know as much as we can about it. COVID-19 is a new type of severe pneumonia. We have collected clinical manifestations and CT imaging findings of 61 COVID-19 cases in intensive care.

2. Materials and Methods

2.1. Objects. From February 11, 2020 to March 31, 2020, 61 adult patients in intensive care were admitted to the ward E1-3 of Tongji Hospital. Forty-five patients were selected from community isolation clinic and hospital fever clinic on February 11, 2020, and the rest 16 cases were transferred from the designated hospital. Sixty-one patients were confirmed by diagnostic criteria of China COVID-19 treatment (fifth, sixth, and seventh Edition). Detection novel coronavirus nucleic acid positive by RT-PCR in specimens (mouth/nasopharyngeal swabs), and/or COVID-19 specific anti-IgM and anti-IgG were positive in serum samples. At the same time, all patients at the time of admission have any of the following conditions: (1) shortness of breath and respiratory rate (RR) ≥ 30 times/min; (2) at rest, refers to oxygen saturation $\leq 93\%$; and (3) arterial blood oxygen partial pressure (PaO₂)/oxygen concentration (FiO₂) ≤ 300 mmHg, which are the COVID-19 cases in intensive care unit. Among them, 6 patients had one of the following conditions during hospitalization: (1) respiratory failure, and mechanical ventilation was required; (2) shock occurred; and (3) combining other organ failures required ICU monitoring treatment, and the diagnosis was severe COVID-19. Of the 61 patients included in the study, male 32 and female 29, aged 24–83, mean age (58.52 ± 1.67), 18 patients with hypertension, 11 patients with diabetes or stress hyperglycemia, and chronic heart disease 9 cases, COPD 3 cases, gout 3 cases, chronic kidney disease 2 cases, and hematological malignancy 1 case.

2.2. Treatment Plan. Treatment mainly covers six aspects: First, choose the appropriate oxygen therapy according to the degree of dyspnea of the patient. Most patients use a dual-cavity nasal catheter to inhale oxygen. The oxygen flow is 3–5 L/min. The target refers to oxygen saturation $\geq 93\%$, and a noninvasive ventilator is immediately used when unable to meet the needs. Second, the antiviral treatment plan is determined and Abidor 200 mg, 3 times a day or lopinavir/ritonavir 200 mg/50 mg/capsule, 2 capsules each time, 2 times a day. Two critically ill patients used 5 million units of α -interferon in combination with daily nebulized inhalation, ribavirin 500 mg, and intravenous infusion twice daily. The duration of antiviral treatment is 10 days. Third, based on the patient's respiratory symptoms and changes in CT imaging, we decide whether to use glucocorticoids. If the patient has shortness of breath and the respiratory rate is greater than 30 breaths per minute, when the CT imaging shows that the exudation is the main change, you can optionally use methylprednisolone 40–80 mg intravenous drip and evaluate it again after 5 days. It should either be used or stopped directly. Fourth, based on the treatment of the patient's symptoms, acetaminophen is administered when the body temperature (frontal temperature) is $\geq 102.2^\circ\text{C}$, bronchial spasm relief drugs and acetylcysteine tablets 0.6 g orally, 2 times a day, and when the cough and sputum are obvious 0.3 g of acetylcysteine solution is used for inhalation or 3 times a day. Fifth, nutrition support is strengthened to

ensure that the daily calorie intake of the patient is greater than 35 Kcal/kg and infusion of 20% human serum albumin solution makes the patient's serum albumin level greater than 30 g/L. Sixth, the possibility of secondary bacterial or fungal infections is assessed.

2.3. Observation Indicators. Onset time, primary symptoms, epidemic history, nucleic acid testing (NAT) results, CT imaging results, and medicine treatment were taken into account before admission. Blood routine, CRP, PCT, ESR, liver enzyme, myocardial enzyme spectrum and troponin I, NT-proBNP, D-dimer, inflammatory factors, and chest CT imaging were detected irregularly.

3. Results

3.1. Prognosis. Of the 61 patients, 3 died after tracheal intubation and treated with a ventilator and 1 patient with acute hematological malignancies died of secondary multidrug resistant bacteria (CRE) bloodstream infection. The symptoms of the remaining patients disappeared or were significantly alleviated. The chest CT scan showed obvious absorption of the lesion, and the patient was discharged after retesting negative NAT.

3.2. Clinical Features. Sixty-one patients were local Wuhan personnel, and most of them had a clear history of epidemiological contact (77%), with 61 cases of fever (100%) as the first symptom, 56 cases of cough and expectoration (91.8%), 48 cases of shortness of breath and chest tightness (78.7%), muscle soreness and fatigue in 40 cases (65.6%), diarrhea or vomiting in 8 cases (13.1%), and headache in 4 cases (6.6%). At admission, 15 patients had a course of ≤ 7 d, 23 patients from 8–14 d, and 23 patients >14 d. Before admission, all patients underwent different degrees of medicine treatment, including 3 cases of Abidor, 8 cases of ribavirin, 15 cases of oseltamivir, 10 cases of glucocorticoids, 28 cases of antibiotics, 57 cases of antipyretics and, 61 cases of Chinese herbal medicine preparation.

After admission, 40 cases of normal white blood cell count (57.7%) were checked, 9 cases (15.4%) were higher than normal, and 12 cases (26.9%) were lower than normal. The lymphocyte count decreased in 53 cases (38.5%). CRP increased in 29 cases (57.7%); PCT increased in 15 cases (24.6%); the erythrocyte sedimentation rate increased in 38 cases (62.3%); the D-dimer test increased in 39 cases (63.9%); ALT/AST increased in 40 cases (65.6%); CK/CK-MB increased in 8 cases (13.1%); troponin I increased in 6 cases (9.8%); NT-proBNP increased in 35 cases (57.4%); IL-1 increased in 5 cases (8.2%); IL-2 increased in 28 cases (45.9%); IL-6 increased in 23 cases (37.7%); IL-8 increased in 15 cases (24.6%); IL-10 increased in 12 cases (19.7%); and NTF increased in 22 cases (36.1%), which are shown in Table 1.

3.3. Imaging Features. Of 61 COVID-19 patients, 3 patients were in critical condition after admission, unable to

TABLE 1: Clinical feature analysis results of 61 COVID-19 patients.

| Characteristics | | n | Ratio (%) |
|------------------------|--------------------------|------|-----------|
| Symptoms | Epidemiological exposure | 47 | 77.0 |
| | Fever | 61 | 100.0 |
| | Cough | 56 | 91.8 |
| | Shortness of breath | 48 | 78.7 |
| | Muscle soreness | 40 | 65.6 |
| | Diarrhea/vomiting | 8 | 13.1 |
| | Headache | 4 | 6.6 |
| Course of disease | ≤7 d | 15 | 24.6 |
| | 8–14 d | 23 | 37.7 |
| | >14 d | 23 | 37.7 |
| Medicine treatment | Chinese herb | 61 | 100.0 |
| | Abidor | 3 | 4.9 |
| | Ribavirin | 8 | 13.0 |
| | Glucocorticoids | 10 | 16.0 |
| | Antipyretics | 57 | 93.0 |
| | Antibiotics | 28 | 45.9 |
| | Oseltamivir | 15 | 115.8 |
| Laboratory examination | WBC count | | |
| | Normal | 40 | 57.7 |
| | Higher | 9 | 15.4 |
| | Lower | 12 | 26.9 |
| | Lymphocyte count | | |
| | Decreased | 53 | 86.9 |
| | CRP | | |
| | Increased | 29 | 47.5 |
| | PCT | | |
| | Increased | 15 | 24.6 |
| | ESR | | |
| | Increased | 38 | 62.3 |
| | D-dimer | 39 | 63.9 |
| | ALT/AST | 40 | 65.6 |
| | CK/CK-MB | | |
| | Increased | 8 | 13.1 |
| | Troponin I | | |
| | Increased | 6 | 9.8 |
| | NT-proBNP | 35 | 57.4 |
| | IL-1 | | |
| | Increased | 5 | 8.2 |
| | IL-2 | | |
| Increased | 28 | 45.9 | |
| IL-6 | | | |
| Increased | 23 | 37.7 | |
| IL-8 | | | |
| Increased | 15 | 24.6 | |
| IL-10 | | | |
| Increased | 12 | 19.7 | |
| NTF | | | |
| Increased | 22 | 36.1 | |

complete chest CT examination, and died after being transferred to ICU. The remaining 58 patients completed chest CT examination. There were 38 cases (65.5%) with a wider range of right lung lesions than left lung lesions and 20 cases (34.5%) with a wider range of left lung lesions than right lung lesions. There were 42 cases (72.5%) with lower lobe lesions than upper lobe lesions, and 6 cases (10.3%) with upper lobe lesions than lower lobe lesions are shown in Table 2.

TABLE 2: Chest CT examination analysis results of 61 COVID-19 patients.

| Characteristics | | n | Ratio (%) |
|-----------------|-----------------------------|-----|-----------|
| CT scan | Performed | 58 | 95.1 |
| | Not performed | 3 | 4.9 |
| Affected lobe | Right | 38 | 65.5 |
| | Left | 20 | 34.5 |
| | Lower | 42 | 72.5 |
| | Upper | 6 | 10.3 |
| Signs | GGO | 12 | 20.7 |
| | Focal consolidation | 38 | 65.5 |
| | Lung consolidation | 20 | 34.5 |
| | Grid-like or fibrous strips | 54% | 93.1 |
| | Air bronchial signs | 8 | 13.8 |

From the picture, 58 COVID-19 patients showed one or more of the following signs: ground-glass opacity (GGO) was found in 12 cases, with subpleural distribution (Figures 1(a) and 1(b)); GGO merger in 38 cases of focal consolidation (Figures 1(c) and 1(d)); 24 cases with increased patch density of small patchy edges (Figures 1(c) and 1(f)); large consolidation of sheets in 20 cases (Figures 1(e) and 1(g)); 54 cases with grid-like or fibrous strips (Figures 1(c)–1(e)); and 8 cases with air bronchial signs (Figure 1(c)).

4. Discussion

COVID-19 is caused by the severe acute respiratory syndrome coronavirus-2 (SARS-CoV-2) [1], and it is obviously different from severe acute respiratory syndrome (SARS) and the Middle East respiratory syndrome (MERS) that were popular several years ago [2]. Similarly, it is different from viral pneumonia such as influenza virus pneumonia, parainfluenza virus pneumonia, influenza A virus pneumonia, avian influenza virus pneumonia, adenovirus pneumonia, respiratory syncytial virus pneumonia, and cytomegalovirus pneumonia [3–6]. At the beginning of the epidemic in Wuhan, everyone could only think of it as an unexplained pneumonia. At present, it is known that COVID-19 is mainly spread through respiratory droplets and close contact and there is a possibility of aerosol transmission when exposed to a high concentration of aerosol for a long time in a relatively closed environment. Most CoVs share a similar viral structure and infection pathway [7–10]. COVID-19 is highly contagious and long-term latent, and the population is generally susceptible, which makes it difficult to control once it breaks out. Moreover, in the early stage of the disease, there is no effective treatment, and there is a considerable possibility that it will progress to severe disease, affecting whether it is elderly or young [11, 12]. Of the 61 cases of severe new coronary pneumonia we treated, only 27 were older than 60 years, but 46 patients had a disease course of more than 7 days. Although they all received medical treatment, they were treated based on their lack of understanding of the disease at that time. Owing to limited medical resources, the effect of treatment is not ideal. This situation was very common in the early days of the outbreak in each country, and a large number of serious patients

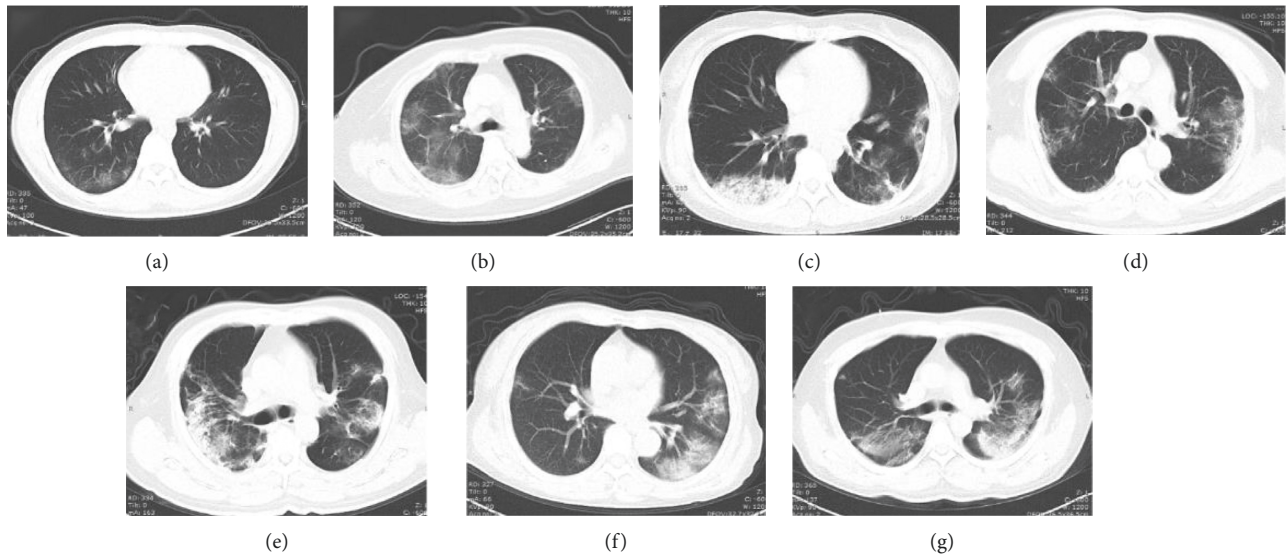


FIGURE 1: Characteristics of lung CT manifestations in patients with COVID-19.

requiring hospitalization appeared, including many young people. The clinical manifestations of these people with severe new coronary pneumonia are actually not specific. We cannot identify COVID-19 by symptoms such as fever, cough, shortness of breath, chest tightness, muscle aches, fatigue, and diarrhea. We also did not observe symptoms of loss of smell or taste. However, some of these symptoms are important in determining the severity and prognosis of the disease. The 61 patients included in the study had symptoms of fever at the beginning of the disease, but after a long period of time, 11 patients still had symptoms of fever at admission. These people included all 6 patients who required noninvasive ventilator treatment, including 3 of them who died after being transferred to ICU. Similarly, shortness of breath or the increased breathing rate and feeling chest tightness are also an important red flag. Therefore, 38 of the 61 patients we admitted had shortness of breath and chest tightness. When the symptoms of shortness of breath cannot be alleviated by oxygen therapy or symptomatic treatment, special vigilance is required. Our experience is to intervene early and actively intervene. There are 2 critically ill patients who passed the most difficult stage through our early-rising noninvasive ventilator treatment and avoided being transferred to ICU. Some of these patients did take Chinese herbal medicine. However, because the patients were in the early stage of emergency treatment, we were unable to take it regularly, nor did we carry out the role of Chinese herbal medicine in the treatment of critically ill patients. Temperature and respiratory rate, or fever, and shortness of breath are very easy to get, and they are very useful clinical manifestations. The rest of the symptoms are of limited significance.

The total number of peripheral blood leukocytes in patients with COVID-19 is normal or reduced, and the lymphocyte count is reduced. In some patients, ALT/AST, CRP, ESR, D-dimer, NT-proBNP, IL-1, IL-2 receptor, IL-6, IL-8, IL-10, and NTF increased. In critically ill patients, troponin, IL-2 receptors, IL-6, and NTF will increase

significantly, which means the advent of inflammatory storm. This is an important time point for us to start some special treatments, including the use of glucocorticoids, infusion recovery period plasma, and CRRT. White blood cell count, CRP, and PCT of patients with severe new coronary pneumonia can increase simultaneously as one of the basis for judging secondary bacterial infection.

We must recognize that chest CT imaging plays an important role in the diagnosis, treatment, and follow-up of COVID-19. Imaging examination revealed that most patients showed bilateral GGO on CT scans [13, 14]. CT is a sensitive examination method, which can be applied to make an early diagnosis and for evaluation of progression, with a diagnostic sensitivity and accuracy better than that of nucleic acid detection [15]. Therefore, we try to complete the patient's CT scan as much as possible. Sixty-one cases of COVID-19 were admitted to the intensive care, and we can only get the results of the CT image before the admission and lack of its imaging data. After admission, we improved the chest CT examination of 58 patients. Based on the results of chest CT scans of 58 patients with severe COVID-19 included in the study, the CT imaging findings were summarized as follows: the lesions have multiple lung segments and lobes, involving both sides, with a wider range. It is more common under the pleura; most of the lesions are grid or fibrous cord shadow, patchy density increase shadow, GGO with consolidation shadow, and segmental or subsegmental GGO lesions can also be seen, and air bronchial signs can be seen in the lesion or thickened blood vessels. These imaging findings are basically consistent with the pathological anatomical results of COVID-19. The bronchi are covered with mucus and bleeding exudates. Histological examination revealed bilateral diffuse alveolar injury with mucous exudation of cell fibers and a large amount of pulmonary interstitial fibrosis with part transparent degeneration, and pulmonary hemorrhagic infarction. But we found two interesting phenomena. The severity of the disease in the right

lung and lower lobe of patients with severe COVID-19 is more serious, which may be related to the different proportions of ventilated blood flow in different parts.

5. Conclusion

In summary, the clinical manifestations of patients with severe COVID-19 are not specific to the chest CT manifestations. The assessment of the disease requires a comprehensive analysis of relevant symptoms, signs, and laboratory data so as to help us judge the severity of the disease and decide timing of treatment and assess the prognosis.

Abbreviations

| | |
|-----------|--------------------------|
| COVID-19: | Coronavirus disease 2019 |
| CT: | Computed tomography |
| GGO: | Ground-glass opacity |
| ICU: | Intensive care unit |
| NAT: | Nucleic acid testing. |

Data Availability

The datasets used and/or analyzed during the current study are available from the corresponding author on reasonable request.

Conflicts of Interest

The authors declare that they have no conflicts of interest..

Authors' Contributions

This is a retrospective study. Dr. Lihong Li wrote the manuscript, Yongwei Yao, Xiaofei Feng, Lingling Chen, Rui Wu, Yuejin Chang, and Qiaoqin Lou were involved in data collection, and Jinbo Pan and Zhangli Wang wrote and translated the manuscript.

Acknowledgments

The authors are grateful to the National Rescue Team for giving them the opportunity to participate in the fight against the COVID-19 epidemic in Wuhan, which makes them cherish life more, awe of nature, and a deeper understanding of the unity of the country. The authors are thankful to the people of Wuhan for their strength and patience in the case of the city closure and thankful to their family for their support.

References

- [1] E. Driggin, M. V. Madhavan, B. Bikdeli et al., "Cardiovascular considerations for patients, health care workers, and health systems during the COVID-19 pandemic," *Journal of the American College of Cardiology*, vol. 75, no. 18, pp. 2352–2371, 2020.
- [2] V. M. Corman, O. Landt, M. Kaiser et al., "Detection of 2019 novel coronavirus (2019-nCoV) by real-time RT-PCR," *Euro Surveillance: bulletin Europeen sur les maladies transmissibles = European communicable disease bulletin*, vol. 25, no. 3, 2020.
- [3] Z. Lv, Z. Yu, S. Xie, and A. Alamri, "Deep learning-based smart predictive evaluation for interactive multimedia-enabled smart healthcare," *ACM Transactions on Multimedia Computing, Communications, and Applications*, vol. 18, no. 1s, pp. 1–20, 2022.
- [4] Z. Lv, D. Chen, H. Feng, H. Zhu, and H. Lv, "Digital twins in unmanned aerial vehicles for rapid medical resource delivery in epidemics," *IEEE Transactions on Intelligent Transportation Systems*, pp. 1–9, 2021.
- [5] J. Yan, Y. Yao, S. Yan, R. Gao, W. Lu, and W. He, "Chiral protein supraparticles for tumor suppression and synergistic immunotherapy: an enabling strategy for bioactive supra-molecular chirality construction," *Nano Letters*, vol. 20, no. 8, pp. 5844–5852, 2020.
- [6] Q. Xu, Y. Zeng, W. Tang et al., "Multi-Task joint learning model for segmenting and classifying tongue images using a deep neural network," *IEEE journal of biomedical and health informatics*, vol. 24, no. 9, pp. 2481–2489, 2020.
- [7] Y. Yuan, D. Cao, Y. Zhang et al., "Cryo-EM structures of MERS-CoV and SARS-CoV spike glycoproteins reveal the dynamic receptor binding domains," *Nature Communications*, vol. 8, no. 1, Article ID 15092, 2017.
- [8] R. J. Hulswit, C. A. de Haan, and B. J. Bosch, "Coronavirus spike protein and tropism changes," *Coronaviruses*, vol. 96, pp. 29–57, 2016.
- [9] A. Al-Hazmi, "Challenges presented by MERS corona virus, and SARS corona virus to global health," *Saudi Journal of Biological Sciences*, vol. 23, no. 4, pp. 507–511, 2016.
- [10] S. A. Eifan, I. Nour, A. Hanif, A. M. Zamzam, and S. M. AlJohani, "A pandemic risk assessment of middle east respiratory syndrome coronavirus (MERS-CoV) in Saudi Arabia," *Saudi Journal of Biological Sciences*, vol. 24, no. 7, pp. 1631–1638, 2017.
- [11] M. Zhang, Y. Chen, and W. Susilo, "PPO-CPQ: a privacy-preserving optimization of clinical pathway query for E-healthcare systems," *IEEE Internet of Things Journal*, vol. 7, no. 10, pp. 10660–10672, 2020.
- [12] M. Zhang, Y. Chen, and J. Lin, "A privacy-preserving optimization of neighborhood-based recommendation for medical-aided diagnosis and treatment," *IEEE Internet of Things Journal*, vol. 8, no. 13, pp. 10830–10842, 2021.
- [13] N. Chen, M. Zhou, X. Dong et al., "Epidemiological and clinical characteristics of 99 cases of 2019 novel coronavirus pneumonia in Wuhan, China: a descriptive study," *The Lancet*, vol. 395, no. 10223, pp. 507–513, 2020.
- [14] H. Liu, J. Liu, S. Hou, T. Tao, and J. Han, "Perception consistency ultrasound image super-resolution via self-supervised cycleGAN," *Neural Computing and Applications*, 2021.
- [15] K. Wang, S. Kang, R. Tian, X. Zhang, X. Zhang, and Y. Wang, "Imaging manifestations and diagnostic value of chest CT of coronavirus disease 2019 (COVID-19) in the Xiaogan area," *Clinical Radiology*, vol. 75, no. 5, pp. 341–347, 2020.