

Transcatheter retrieval of Amplatzer Septal Occluder device embolized into the abdominal aorta

SAGE Open Medical Case Reports
Volume 7: 1–5
© The Author(s) 2019
Article reuse guidelines:
sagepub.com/journals-permissions
DOI: 10.1177/2050313X19842462
journals.sagepub.com/home/sco



Gianfranco Filippone^{id}, Gaetano La Barbera, Fabrizio Valentino, Salvatore Ocello and Francesco Talarico

Abstract

The use of Amplatzer Septal Occluder device has become an alternative to surgical procedure in selected group of patients affected by atrial septal defect. Percutaneous closure of atrial septal defect has emerged as a low morbidity procedure but, at the same time, showed various complications associated to the device itself. Although embolization to the abdominal aorta is only sporadic reported, it could represent a potential vascular disaster and usually is treated by surgery. Herein, we report on the fourth, in English literature, successfully total transcatheter retrieval of an Amplatzer Septal Occluder device complicated by acute embolization into the abdominal aorta and propose a practical endovascular manoeuvre to address disc removal.

Keywords

Atrial Septal Defect, percutaneous transcatheter management, Amplatzer septal occluder device, complications, embolization, abdominal aorta, emergent endovascular intervention, snare

Date received: 30 January 2019; accepted: 11 March 2019

Introduction

The protocol and informed consent were approved by the Institutional Review Board, and the subject agreed for her case to be published.

The percutaneous closure of atrial septal defect (ASD) using Amplatzer Septal Occluder (ASO) device is a procedure with low rate of morbidity showing, in the meantime, various complications related to the device itself such as malposition, embolization up to the perforation of the cardiac chambers.^{1,2}

Embolization, despite quite rare and reported with a range from 0.5% up to 1.6% of cases, could become a potential fatal complication.^{2,3}

The most common site of migration is the main pulmonary artery (89% of cases) whereas the embolization to the aorta, as aforementioned, is only sporadic reported and usually is treated by surgery or, rarely, by conservative management.^{2,4–6}

Herein we report on a successfully total transcatheter retrieval of ASO device complicated, during ASD closure procedure, by acute embolization into the infrarenal abdominal aorta.

Case report

A Caucasian woman was referred to us, in emergency, from other Institution, because the interventional cardiologists, attempting a transcatheter closure of ASD, observed, few minutes after the device deployment, the migration of a 28.5/28.5 mm ASO into the infrarenal abdominal aorta (Figure 1(a)–(e)). Several attempts to retrieve the vascular plug failed and they decided to airborne transfer the patient.

At arrival in our department, the patient, with sinus rhythm (96 bpm) with arterial blood pressure measuring 90/60 mmHg in upper limbs and O₂ saturation of 99%, was asymptomatic but showed the absence of peripheral pulse in lower limbs. In order to avoid onset of catastrophic vas-

Unit of Vascular and Endovascular Surgery, Ospedale Civico, Palermo, Italy

Corresponding author:

Gianfranco Filippone, Unit of Vascular and Endovascular Surgery, Ospedale Civico, Via Giuseppe Giusti, 3, 90144 Palermo, Italy.
Email: g.filippone@virgilio.it



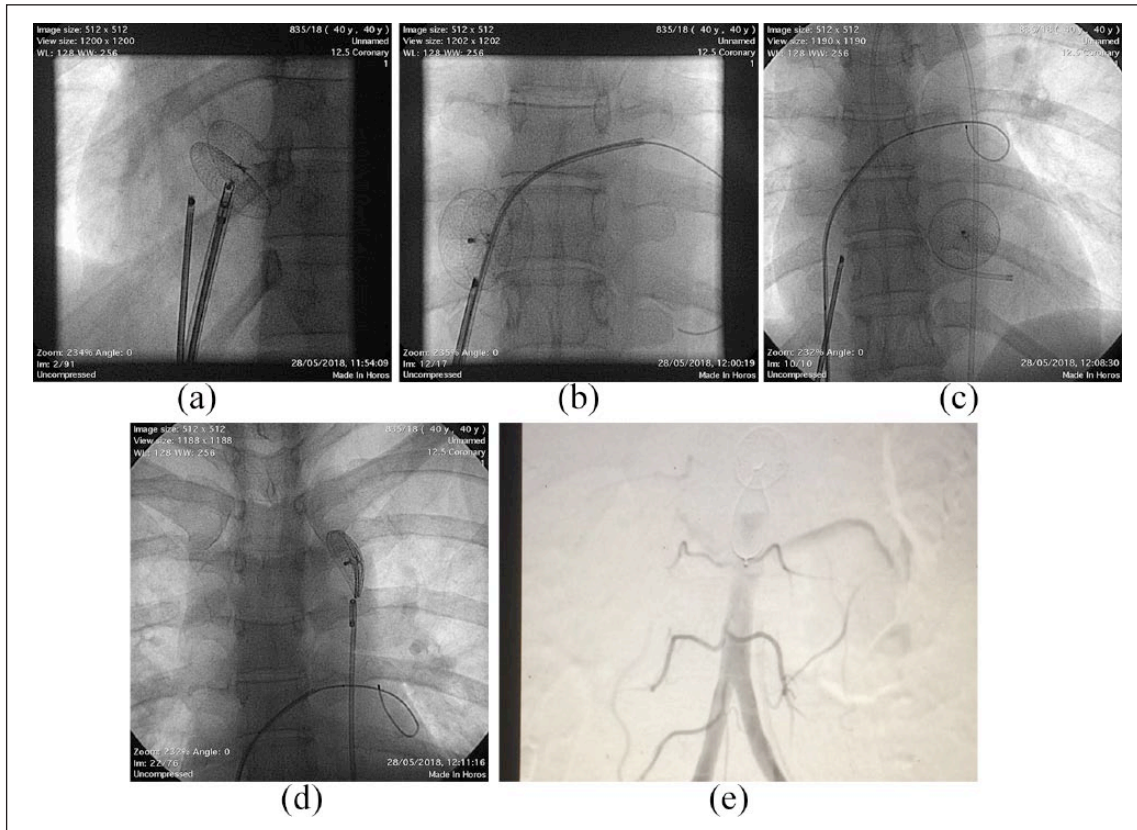


Figure 1. Aortogram sequence shows (a) the deployment of the Amplatzer Septal Occluder, (b) the migration of the ASO in the left atrium, (c) the migration of the ASO in the left ventricle, (d) the embolization of the ASO in the thoracic aorta and (e) the embolization of the ASO into the abdominal aorta that is occluded below the level of renal arteries.

cular complications, the patient was immediately transferred to the hybrid operating room.

The previously inserted 7F sheath in right femoral artery was replaced with a 11F sheath (Cordis, Johnson-Johnson, Ireland). A 0.035 in, 260 cm long, angled guidewire (Terumo, Leuven, Belgium, Europe) was introduced up to the descending thoracic aorta. The guidewire in the right femoral artery was replaced with a 5F, 100-cm long, pigtail catheter (Super Torque, Cordis, Johnson-Johnson, Ireland), and an angiography was performed confirming abdominal aorta occlusion below the level of the renal arteries; through this pigtail, a 0.035-in angled, 260 cm long, guidewire (Terumo, Leuven, Belgium, Europe) was introduced and passed through the nitinol wire mesh of the occluder (Figure 2(a)). One more 0.035-in, 260-cm long, buddy wire (Terumo, Leuven, Belgium, Europe) was positioned and passed between the ASO occluder and the inner lumen of the aorta, above the renal arteries up to the aortic valve plane (Figure 2(b)); the pigtail and the 11F sheath were replaced with a 24F sheath (33 cm) Dryseal Flex (Gore, USA), including both guidewires, that was placed just below the vascular plug (Figure 2(c)). A 6F goose-neck Snare Merit Medical of 35 mm (Utah, USA) was advanced along the guidewire previously positioned (Figure 2(d)); therefore, this guidewire was withdrawn and the

goose-neck advanced permitting to snare the guidewire passing through the ASO mesh (Figure 2(e)). The entire device was slenderized and pulled into the large 24F sheath and successfully retrieved (Figures 3 and 4). At the end of the procedure, new clinical reappraisal confirmed the presence of peripheral pulses in the lower limbs.

The procedure run-time last 120 min while the fluoroscopy run-time last 30 min. Post-operative course was uneventful and the patient was discharged to home on third postoperative day (POD) addressed to the cardiac surgery division.

Discussion

The ASO device is widely used for percutaneous closure of ASD appearing as an effective alternative to open surgical repair because of the low complication rates and the shorter in-hospital stay.^{7,8}

ASO device is a cylindrical vascular plug made of self-expanding nitinol wire mesh that are tightly woven into two flat buttons; the device is available from 4 to 38 mm. There are radiopaque bands at each end of the plug; the proximal end has a stainless steel micro-screw that keeps the plug attached to the stainless steel delivery cable. The delivery

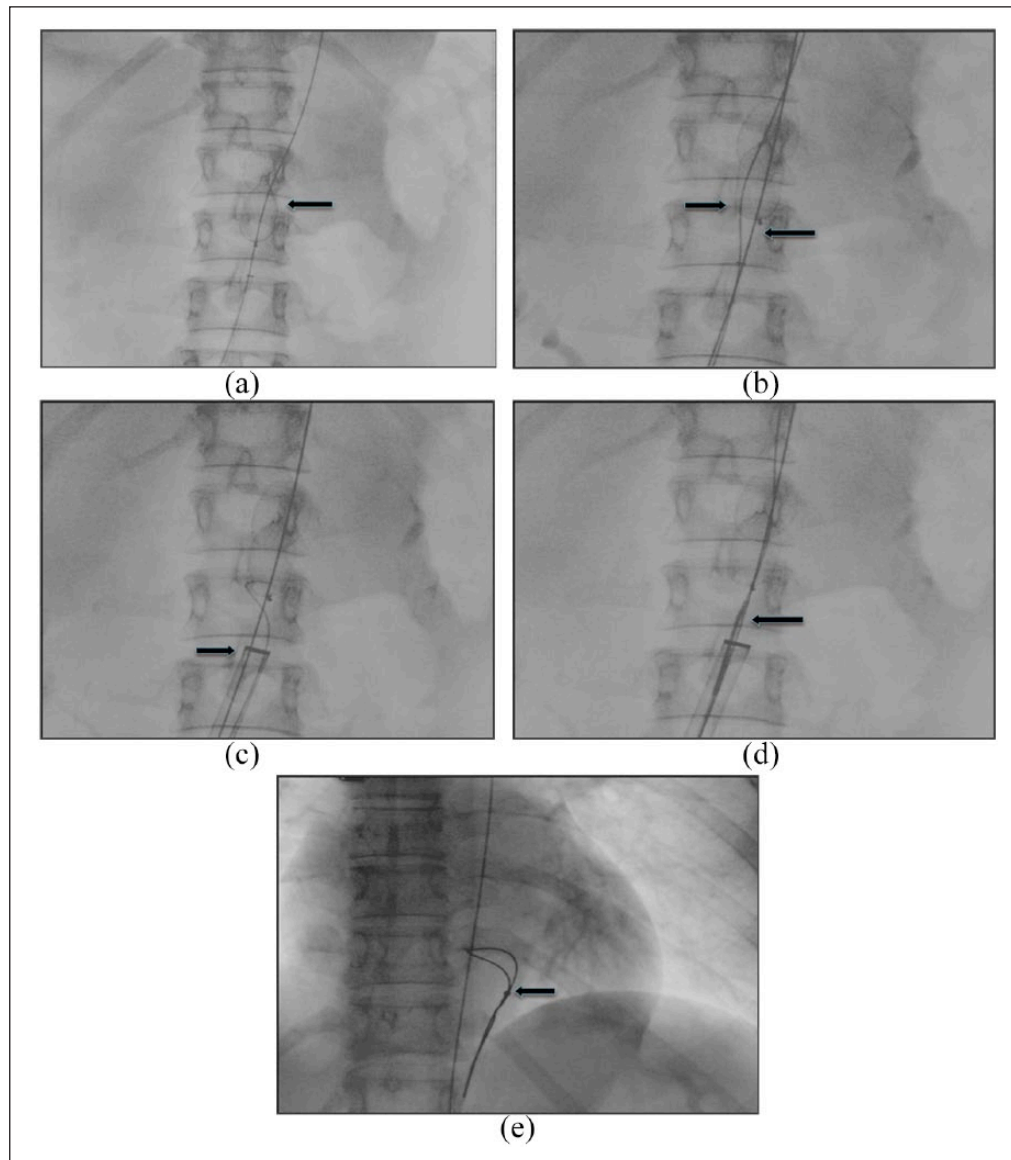


Figure 2. Aortogram shows (a) a 0.035 guidewire passing through the nitinol mesh of the Amplatzer Septal Occluder (black arrow), (b) a 0.035 buddy wire (black arrow) passing between the inner lumen of the aorta and ASO, (c) the 24F sheath (black arrow) including both guidewires just below the ASO, (d) the introduction of 6F goose-neck snare (black arrow) and (e) the goose-neck snaring the guidewire (black arrow) previously passed through the ASO.

cable with the plug attached comes preloaded within an introducer sheath. The device can be then introduced into the deliver catheter. The plug can be withdrawn and repositioned through the catheter before its detachment.⁸

Whereas the device embolization represent a rare event, reported in up to 1.67% of cases, due to the self-expanding design that exerts a radially directed force on the vessel wall to maintain its position, furthermore, it may result in a potential fatal complication such perforation and/or aortic dissection.^{2,9}

Divekar et al.,¹⁰ reviewing all the 29 reported complications of ASO devices, found that embolization occur when

the aortic rim was insufficient or when an improper sizing or a malposition of the device was done.

In a survey of the ASO company-designated proctors, the incidence of ASO embolization was 0.55% (21 embolizations in 3824 device placements) with a wide range of patient demographics, ASD sizes, and device sizes; 15 of the embolized devices were retrieved percutaneously with a goose-neck snare without morbidity or mortality and 6 were retrieved by surgery.³

The dislocated device can migrate to the main pulmonary artery, left ventricle, left atrium, ascending aorta, aortic arch or descending thoracic aorta.^{2,5,10-12}

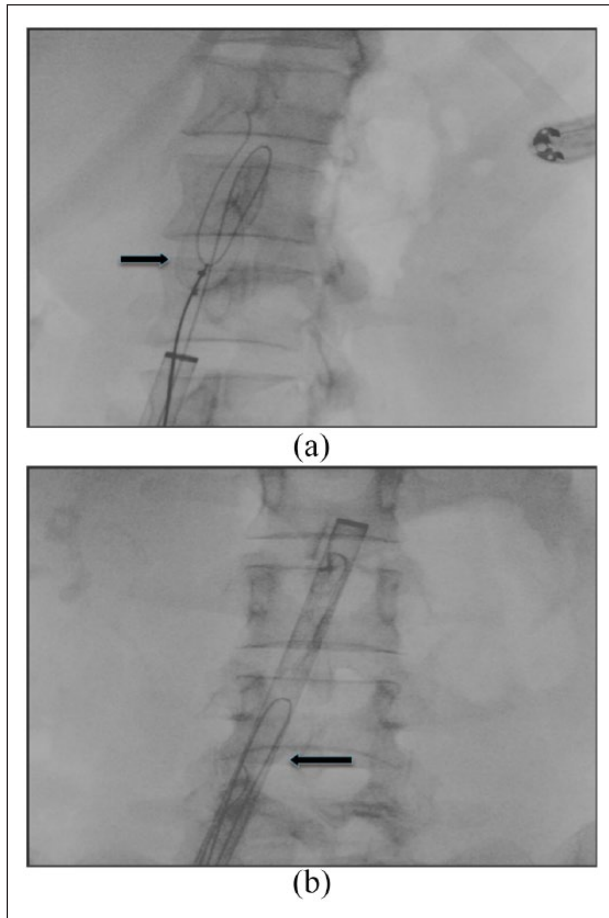


Figure 3. Aortogram shows (a) the ASO device slenderized into the 24F sheath (black arrow) and (b) complete retrieval of the device (black arrow).

In the majority of the cases, the ASO device embolize into the main pulmonary artery (89%).^{9,13}

Most of the migrations (67%) are detected within the first 24h while migration to the descending thoracic aorta in the late postoperative period (>1year) is an extremely rare occurrence.^{11,13,14}

Surgical retrieval of ASO usually is required in 77% of patients immediately after device dislocation.^{2,15,16} Moreover, noteworthy is that the endovascular retrieval of a migrated device could be difficult with a success rate ranging from 5% to 75% of cases, and in this regard, some author, even experienced, claims as irretrievable an embolized atrial septal occluder.^{1,2}

Only one report described migration of an ASO into the abdominal aorta for which conservative management was elected.¹⁰

Several aspects of transcatheter retrieval technique have been described including the use of goose-neck snare, pigtail catheter to stabilize the device or bioptome to grasp it. Technical key-points of our procedure have been (1) the stabilization of the embolized device achieved by a stiff

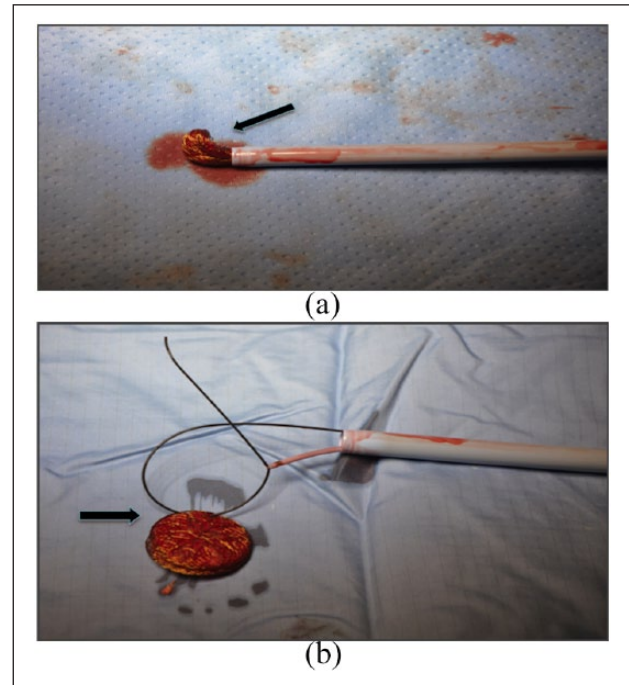


Figure 4. Gross specimen shows (a) the 24F sheath including the ASO device (black arrow) and (b) the guidewire passing through the mesh of the device out of the large sheath (black arrow).

guidewire passed through the nitinol wire mesh and, after snared it and (2) the use of an oversized sheath (24F) to allow an easier entry of the slenderized device during the pull-back manoeuvre.

Ferrero and colleagues, reviewing the English language reports and including their own, have found only six case reports of ASO migration within the abdominal aorta and only one into the iliac artery, all without limb ischemia; in two cases, after surgical exposure of the common femoral artery, a sheath (18F and 20F, respectively) was positioned close to the ASO device, it was grabbed and pulled partially inside the sheath and then down to the arteriotomy site; in one case, owing to total incorporation of the device, endoluminal retrieval was not possible; thus, the device was surgically removed through a medial laparotomy approach; finally in two cases, the ASO device was retrieved from the descending aorta by making a horizontal cut in the ascending aorta.¹⁷

Crawford et al.,¹⁴ more recently, added the third case of endovascular retrieval of ASO embolized into the abdominal aorta.

Conclusion

The ASO device is widely used for percutaneous treatment of ASD but the procedure, even in rare case, may be complicated by acute embolization of the vascular plug that could represent a potential fatal threat. Only sporadic case reports described

the abdominal aorta as the site of migration, and only in the minority of the reported cases, the retrieval of the device has been performed by percutaneous procedure because open surgery was preferred. In our opinion, totally endovascular retrieval of the ASO device from the abdominal aorta appears a safe and effective treatment and it has to be always attempted before to address the patient for open surgery.

Declaration of conflicting interests

The author(s) declared no potential conflicts of interest with respect to the research, authorship, and/or publication of this article.

Ethics approval

Our institution does not require ethical approval for reporting individual cases or case series.

Funding

The author(s) received no financial support for the research, authorship, and/or publication of this article.

Informed consent

Written informed consent was obtained from the patient(s) for their anonymized information to be published in this article.

ORCID iD

Gianfranco Filippone  <https://orcid.org/0000-0001-6938-3570>

References

1. Goel PK, Kapoor A, Batra A, et al. Transcatheter retrieval of embolized AMPLATZER Septal Occluder. *Tex Heart Inst J* 2012; 39(5): 653–656.
2. Chessa M, Carminati M, Butera G, et al. Early and late complications associated with transcatheter occlusion of secundum atrial septal defect. *J Am Coll Cardiol* 2002; 39(6): 1061–1065.
3. Levi DS and Moore JW. Embolization and retrieval of the Amplatzer septal occluder. *Catheter Cardiovasc Interv* 2004; 61: 543–547.
4. Truong QA, Gupta V, Bezerra HG, et al. The travelling Amplatzer: rare of complication of atrial septal occlude device embolism. *Circulation* 2008; 118: e93–e96.
5. Teoh K, Wilton E, Brecker S, et al. Simultaneous removal of an Amplatzer device from an atrial septal defect and the descending aorta. *J Thorac Cardiovasc Surg* 2006; 131(4): 909–910.
6. Maleux G, Rega F, Heye S, et al. Asymptomatic migration of a first-generation AMPLATZER vascular plug into the abdominal aorta: conservative management may be an option. *J Vasc Interv Radiol* 2011; 22(4): 569–570.
7. Chan KC, Godman MJ, Walsh K, et al. Transcatheter closure of atrial septal defect and interatrial communications with a new self expanding nitinol double disc device (Amplatzer septal occluder): multicentre UK experience 1999; 82(3): 300–306.
8. Tresley J, Bhatia S, Kably I, et al. Amplatzer vascular plug as an embolic agent in different vascular pathologies: a pictorial essay. *Indian J Radiol Imaging* 2016; 26(2): 254–261.
9. Deser SB and Demirag MK. Migration of an atrial septal occlude device with formation of abdominal aortic dissection. *Ann Thorac Surg* 2017; 103: e343–e334.
10. Divekar A, Gaamangwe T, Shaikh N, et al. Cardiac perforation after device closure of atrial septal defects with the Amplatzer septal occluder. *J Am Coll Cardiol* 2005; 45(8): 1213–1218.
11. Yetkin U, Yurekli I, Akyildiz ZI, et al. Emergency surgical approach to device emboli due to migration of the atrial septal defect occluder. *Arch Med Sci* 2014; 10(3): 464–469.
12. Tsilimingas NB, Reiter B, Kodolitsch YV, et al. Surgical revision of an uncommonly dislocated self-expanding Amplatzer septal occluder device. *Ann Thorac Surg* 2004; 78(2): 686–687.
13. Kim HH, Yin GJ and Song SW. Late migration of amplatzer septal occlude device to the descending thoracic aorta. *Korean J Thorac Cardiovasc Surg* 2017; 50: 47–49.
14. Crawford DA, Naidu SG, Shah AA, et al. Endovascular retrieval of an embolized atrial septal occluder device from the abdominal aorta. *Vasc Endovascular Surg* 2018; 52(8): 669–673.
15. Sato Y, Inaba Y, Hasegawa T, et al. Transcatheter retrieval of an amplatzer vascular plug. *Pol J Radiol* 2018; 83: e133–e136.
16. Cho JY, Kim KH, Yoon HJ, et al. Percutaneous retrieval of embolized Amplatzer septal occluder after treatment of double atrial septal defect: a case report. *J Korean Med Sci* 2015; 30(9): 1361–1366.
17. Ferrero E, Ferri M, Viazzo A, et al. Migration of an AMPLATZER septal occluder to the abdominal aorta. *Am J Cardiol* 2013; 112: 612–613.