



# A case of laryngeal atresia accompanied by persistent pharyngotracheal ductus

Persistan faringeotrakeal kanalın eşlik ettiği laringeal atrezi olgusu

Levent Korkmaz<sup>1</sup>, Işın Güneş<sup>2</sup>, Hülya Halis<sup>1</sup>, İbrahim Ketenci<sup>3</sup>, Osman Baştuğ<sup>1</sup>, Mehmet Said Doğan<sup>4</sup>, Mustafa Ali Akın<sup>5</sup>

<sup>1</sup>Division of Neonatology, Department of Pediatrics, Erciyes University, Faculty of Medicine, Kayseri, Turkey

<sup>2</sup>Department of Anesthesiology and Reanimation, Erciyes University, Faculty of Medicine, Kayseri, Turkey

<sup>3</sup>Department of Otolaryngology, Erciyes University, Faculty of Medicine, Kayseri, Turkey

<sup>4</sup>Department of Radiology, Erciyes University, Faculty of Medicine, Kayseri, Turkey

<sup>5</sup>Neonatology Unit, Department of Pediatrics Kayseri Training and Research Hospital, Kayseri, Turkey

**Cite this article as:** Korkmaz L, Güneş I, Halis H, et al. A case of laryngeal atresia accompanied by persistent pharyngotracheal ductus. Turk Pediatri Ars 2019; 54(1): 57–60.

## Abstract

Laryngeal atresia is generally a fatal congenital anomaly with an incidence of 1: 50,000 births. This congenital anomaly is a condition of multifactorial inheritance, in which the fetus has a dilated trachea, enlarged echogenic lungs, an inverted or flattened diaphragm, fetal hydrops, and ascites. Diagnosis is usually made when there is failure to perform endotracheal intubation in a neonate with severe respiratory distress and absence of audible cry. Here, we present a very rare case of a newborn with laryngeal atresia who had respiratory distress and was sustained for the first few minutes of life using partial ventilation via a persistent pharyngotracheal duct. We would like to draw the attention of all physicians to this issue by reporting a rare fatal case of a newborn with a congenital presentation.

**Keywords:** Laryngeal atresia, newborn, persistent pharyngotracheal ductus,

## Öz

Laringeal atrezi, 50.000 doğumda bir görülen ve üst hava yolu tıkanıklığı ile giden ölümcül bir doğuştan anomalidir. Çok etmenli kalıttır. Fetal ultrasonografide trakeada genişleme, akciğerlerde genişleme ve hiperekojenite, diyafragmada düzleşme ya da tersine dönme, hidrops ve asit saptanır. Doğumda ağır solunum sıkıntısı olan yenidoğanlarda endotrakeal entübasyonun başari lamaması ve ağlama çabasına rağmen ses duyulmaması ile tanı konulur. Bu yazıda doğumdan sonra solunum sıkıntısı gelişen, ancak entübe edilemeyen, yaşamın ilk dakikalarında persistan faringeotrakeal kanal yardımıyla kısmi solunum yaparak hayatta kalabilen laringeal atrezili bir preterm olgu klinisyenlerin dikkatine sunuldu.

**Anahtar sözcükler:** Laringeal atrezi, persistan faringeotrakeal kanal, yenidoğan

## Introduction

Laryngeal atresia (LA) is a congenital cause of upper airway obstruction that may lead to mortality immediately after delivery. Failed endotracheal intubation and absence of audible cry despite crying effort are significant findings in the diagnosis of the disease in newborns who require intubation because of severe respiratory distress following delivery (1).

Presence of findings of congenital high airway obstruction syndrome (CHAOS) including enlargement and increased echogenicity in the lungs, enlargement in the upper airways, shift of the heart to the midline, hydrops fetalis and flattened or depressed diaphragm on antenatal ultrasonography, suggests LA. In patients without antenatal diagnosis, the diagnosis is sometimes made by autopsy (2, 3).

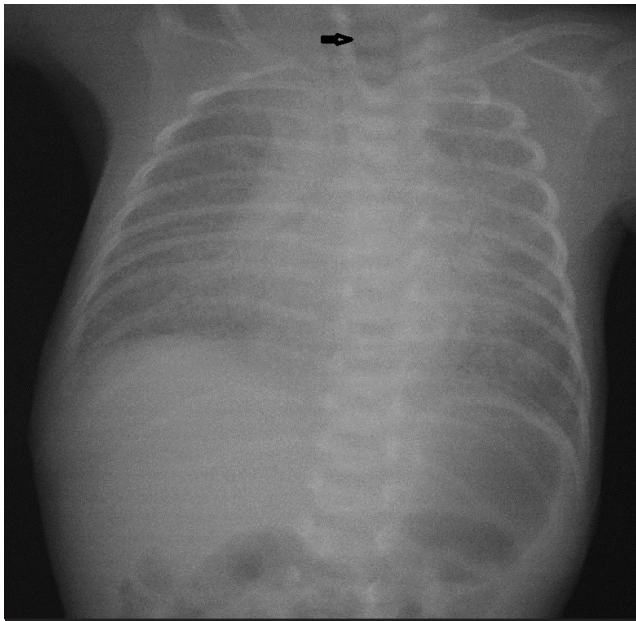
**Corresponding Author / Sorumlu Yazar:** Mustafa Ali Akın E-mail / E-posta: mustafaaliakin@hotmail.com

**Received / Geliş Tarihi:** 12.07.2016 **Accepted / Kabul Tarihi:** 13.01.2017

©Copyright 2019 by Turkish Pediatric Association - Available online at [www.turkpediatriarsivi.com](http://www.turkpediatriarsivi.com)

©Telif Hakkı 2019 Türk Pediatri Kurumu Derneği - Makale metnine [www.turkpediatriarsivi.com](http://www.turkpediatriarsivi.com) web adresinden ulaşılabilir.

DOI: 10.5152/TurkPediatriArs.2018.4619



**Figure 1. Atresic enlarged upper esophagus as a sign of esophageal atresia on lung radiography (arrow)**

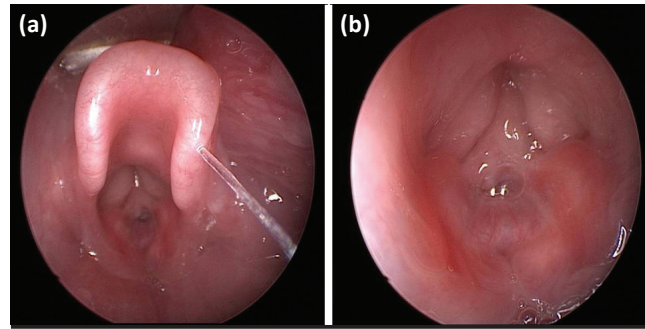
In patients with LA who survive, breathing is provided with partial ventilation generally via proximal tracheoesophageal fistula (TEF) by way of the esophagus or through persistent pharyngotracheal duct (PTD), which enables a thin connection between the pharynx and trachea (3, 4).

In this article, we aimed to remind physicians that patients with fatal LA who do not have antenatal diagnosis and whose breathing is enabled by partial ventilation via persistent pharyngotracheal duct may survive without sequela if airway patency is rapidly provided in delivery room.

### Case

First and fifth minute Apgar scores were found to be 3 and 6 in a female baby who was born from the first pregnancy of a 32-year-old woman by cesarean section at the 32nd gestational week with a birth weight of 1220 g (10 p). An audible cry could not be heard despite crying effort in the baby who developed marked respiratory distress and cyanosis immediately after birth. It was learned that polyhydramnios was found in the antenatal follow-up and preterm delivery occurred because of unstoppable preterm labor.

Ventilation was applied via a balloon mask because of respiratory distress and cyanosis, but a sufficient response could not be obtained. Endotracheal intubation was attempted, but was unsuccessful. During intubation, the larynx was visualized and a membrane that caused severe



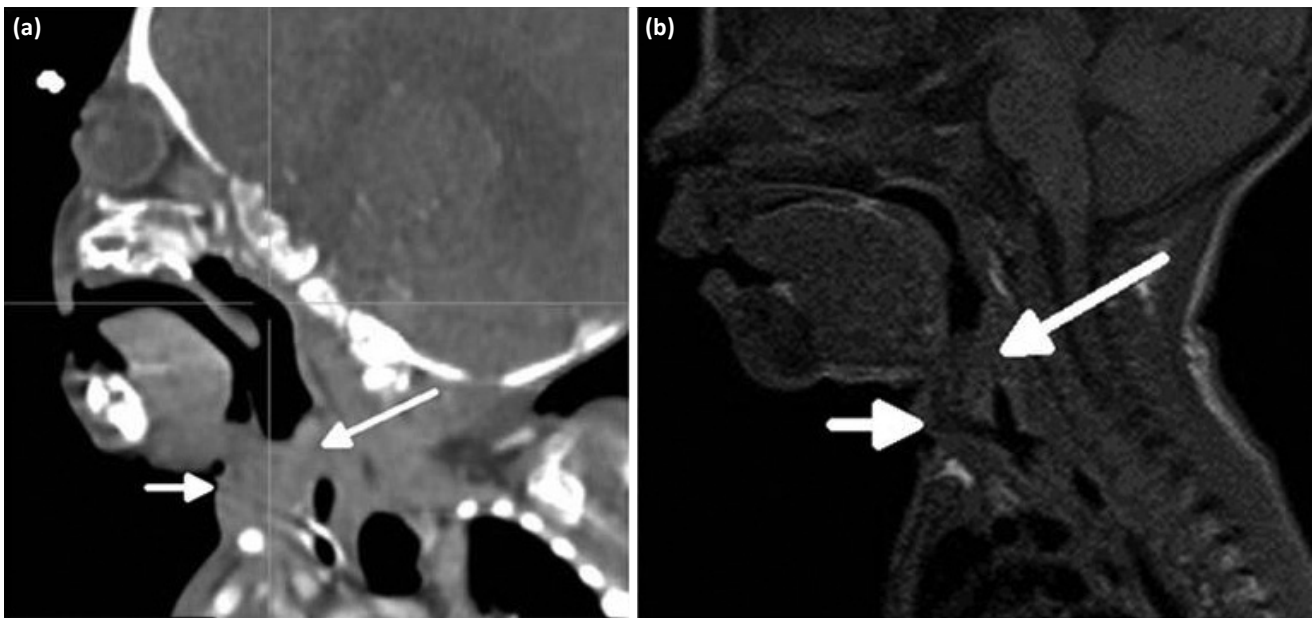
**Figure 2. Laryngoscopic examination findings: Thin fibrotic band at the level of the vocal cords and small patency showing presence of persistent pharyngotracheal duct (a). Air bubble appearance in the subglottic lesion showing that a lung connection (PTD) and partial ventilation exist (b)**

laryngeal stenosis was observed at the level of the vocal cords. The department of otolaryngology was consulted to provide patency of the airway and continuance of patency and an urgent laryngoscopy was performed. Laryngoscopic examination revealed a fibrotic layer in the form of a band, which completely inhibited visualization of the vocal cords and a small patency compatible with pharyngo-tracheal duct at the level of the posterior commissure of the larynx, and an urgent tracheostomy was performed.

The patient was internalized in the neonatal intensive care unit (NICU) after tracheostomy and a orogastric catheter could not be advanced to the stomach on routine examination. Posteroanterior lung radiography revealed upper atresic tracheal enlargement due to esophageal atresia (Fig. 1) and a few air bubbles showing that the patency at the level of the posterior commissure enabled partial ventilation of the baby (Fig. 2a, b).

During a TEF repair operation performed on the third day of life, it was observed that distal esophageal atresia also accompanied the picture. The patient, who was followed up in NICU, was separated from mechanical ventilation three days after the operation and continued her breathing by way of tracheostomy without any problem. Computed tomography (CT) and magnetic resonance imaging (MRI) performed after her general status was stabilized revealed that the size of the LA was 0.7 cm (Fig. 3a, b).

The patient, who was followed up in our hospital with the diagnoses of prematurity, LA accompanied by PTD and TEF, was discharged with transient tracheostomy after family education was given. Currently, she is in her first year of life and her somatic and neurodevelopmental follow-up findings are near normal. She has been included in a permanent tracheostomy program. Written consent was obtained from the patient's parents.



**Figure 3.** Laryngeal atresia (long arrow) and tracheostomy tube (short arrow) on sagittal CT (a) and sagittal T1-weighted (b) MRI

### Discussion

Laryngeal atresia is the most common and primary member of the disease group defined by Hedrick et al. (5) named CHAOS. Although CHAOS may be observed in association with tracheal atresia, laryngeal cyst leading to stenosis and tumors of the oropharynx or cervical region leading to stenosis, it is most commonly associated with LA (2). In these patients, antenatal ultrasonography may show enlargement and hyperechogenicity in the lungs, enlargement of the upper airways, flattened or depressed diaphragm, hydrops fetalis, and polyhydramnios (2, 4, 6).

In cases of laryngeal atresia, distal TEF accompanying the picture may cause obscure antenatal CHAOS findings and missed diagnosis by draining the fetal lung fluid into the stomach via a fistula (4). It was thought that the distal TEF found during surgery might have made it difficult to detect CHAOS findings in the antenatal follow-up in our patient.

In cases of pure LA where partial ventilation cannot be provided, the mortality rate after birth is high if the diagnosis is not known antenatally. The survival rate increases in patients in whom PTD accompanies laryngeal atresia and partial ventilation is enabled in this way, as observed in our case. In addition, PTD protects the fetal lung from the increased pressure caused by the fetal lung fluid, which is not drained because of LA in the intrauterine period. In the literature, anomalies that accompany LA have been reported to include TEF, EA, urinary tract anomalies, extremity anomalies, encephalocele, horseshoe kidneys,

and low-set ears (4, 7–9). Our patient had distal TEF and proximal EA among these findings.

Most patients with CHAOS are restored to life by way of urgent airway surgery including tracheostomy. In patients with CHAOS, ex-utero intrapartum treatment (EXIT), which has been performed since 1998, increases treatment success. Accurate antenatal diagnosis is essential for a patient with CHAOS to have a chance for successful EXIT application (2, 4, 6, 10, 11). However, presence of distal TEF may make it difficult to detect antenatal findings of CHAOS, as observed in our case. In patients with LA who have no chance for EXIT because of obscure antenatal findings, irregular-inadequate antenatal follow-up or absence of an appropriate center, providing airway patency urgently, and continuing patency are very important in terms of decreasing mortality and morbidity rates. In patients with LA in whom partial ventilation is possible, the mortality rate is relatively low, but the risk of hypoxic injury is increased if an appropriate urgent intervention is not performed.

Laryngeal atresia is a rare fatal disease when antenatal diagnosis is not possible. Laryngeal atresia should be considered in patients who develop respiratory distress, who do not have audible cry despite crying effort, and in whom endotracheal intubation fails after delivery. Presence of accompanying PTD increases the possibility of survival of the newborn because of partial ventilation in cases of LA without antenatal diagnosis, as observed in our case. To decrease mortality and morbidity rates in these cases, airway patency should be enabled urgently immediately after birth and continued.

**Informed Consent:** Verbal informed consent was obtained from the patients' parents.

**Peer-review:** Externally peer-reviewed.

**Author Contributions:** Concept - L.K., I.G.; Design - L.K.; Supervision - L.K., M.S.D.; Data Collection and/or Processing - I.G., İ.K.; Analysis and/or Interpretation - L.K., O.B.; Literature Review - L.K., H.H., M.A.A.; Writing - L.K.; Critical Review - M.A.A., L.K.

**Conflict of Interest:** The authors have no conflicts of interest to declare.

**Financial Disclosure:** The authors declared that this study has received no financial support.

**Hasta Onamı:** Sözlü hasta onamı hastanın ebeveynlerinden alınmıştır.

**Hakem Değerlendirmesi:** Dış bağımsız.

**Yazar Katkıları:** Fikir - L.K., I.G.; Tasarım - L.K.; Denetleme - L.K., M.S.D.; Veri Toplanması ve/veya İşlemesi - I.G., İ.K.; Analiz ve/veya Yorum - L.K., O.B.; Literatür Taraması - L.K., H.H., M.A.A.; Yazıyı Yazan - L.K.; Eleştirel İnceleme - M.A.A., L.K.

**Çıkar Çatışması:** Yazarlar çıkar çatışması bildirmemişlerdir.

**Mali Destek:** Yazarlar bu çalışma için mali destek almadıklarını beyan etmişlerdir.

## References

- De Luca D, De Carolis MP, Capelli A, et al. Tracheal agenesis without esophageal fistula: genetic, resuscitative, and pathological issues. *J Pediatr Surg* 2008; 43: e29–32.
- Aslan H, Ekiz A, Acar DK, Aydiner B, Kaya B, Sezer S. Prenatal diagnosis of congenital high airway obstruction syndrome (CHAOS). Five case report. *Med Ultrason* 2015; 17: 115–8.
- de Groot-van der Mooren MD, Haak MC, Lakeman P, et al. Tracheal agenesis: approach towards this severe diagnosis. Case report and review of the literature. *Eur J Pediatr* 2012; 171: 425–31.
- Okuyama H, Kubota A, Kawahara H, Oue T, Tazuke Y. Congenital laryngeal atresia associated with esophageal atresia and tracheoesophageal fistula: a case of long-term survival. *J Pediatr Surg* 2006; 41: e29–32.
- Hedrick MH, Ferro MM, Filly RA, Flake AW, Harrison MR, Adzick NS. Congenital high airway obstruction syndrome (CHAOS): a potential for perinatal intervention. *J Pediatr Surg* 1994; 29: 271–4.
- Onderoglu L, Saygan Karamürsel B, Bulun A, Kale G, Tunçbilek E. Prenatal diagnosis of laryngeal atresia. *Prenat Diagn* 2003; 23: 277–80.
- Smith II, Bain AD. Congenital Atresia Of The Larynx. A Report Of Nine Cases. *Ann Otol Rhinol Laryngol* 1965; 74: 338–49.
- Okada T, Ohnuma N, Tanabe M, Iwai J, Yoshida H, Takahashi H. Long-term survival in a patient with congenital laryngeal atresia and multiple malformations. *Pediatr Surg Int* 1998; 13: 521–3.
- Wyatt ME, Hartley BE. Laryngotracheal reconstruction in congenital laryngeal webs and atresias. *Otolaryngol Head Neck Surg* 2005; 132: 232–8.
- Cohen MS, Rothschild MA, Moscoso J, Shlasko E. Perinatal management of unanticipated congenital laryngeal atresia. *Arch Otolaryngol Head Neck Surg* 1998; 124: 1368–71.
- Glynn F, Sheahan P, Hughes J, Russell J. Successful ex utero intrapartum treatment (EXIT) procedure for congenital high airway obstruction syndrome (CHAOS) owing to a large oropharyngeal teratoma. *Ir Med J* 2006; 99: 242–3.